

See discussions, stats, and author profiles for this publication at: <https://www.researchgate.net/publication/281928667>

# A study of the effect of prostodin and hydroalcoholic extract of *Malva neglecta* on kidney histopathology and renal...

Article in *Advances in Environmental Biology* · January 2014

CITATIONS

10

READS

71

3 authors, including:



**Majid Asadi-Samani**

Shahrekord University of Medical Sciences

95 PUBLICATIONS 466 CITATIONS

SEE PROFILE

Some of the authors of this publication are also working on these related projects:



isolation and evaluation of the biological activities of some isolated phytoconstituents from medicinal plants used in South South Nigeria [View project](#)




Anti-cancer activity of medicinal plants [View project](#)



AENSI Journals

## Advances in Environmental Biology

ISSN-1995-0756 EISSN-1998-1066

Journal home page: <http://www.aensiweb.com/aeb.html>

## A study of the effect of prostodin and hydroalcoholic extract of *Malva neglecta* on kidney histopathology and renal factors in female rats

<sup>1</sup>Amineh Beyrami-Miavagi, <sup>1</sup>Farah Farokhi, <sup>2</sup>Majid Asadi-Samani

<sup>1</sup>Biology Dept., Urmia University, Urmia, I.R. Iran.

<sup>2</sup>Medical Plants Research Center, Shahrekord University of Medical Sciences, Shahrekord, I.R. Iran.

## ARTICLE INFO

**Article history:**

Received 15 April 2014

Received in revised form 22 May 2014

Accepted 25 May 2014

Available online 15 June 2014

**Keywords:**

*Malva neglecta*, Prostodin, Kidney, Female rat

## ABSTRACT

**Background:** Prostodin is often used to terminate the pregnancy, but frequently it causes free radicals development in and oxidative damages to the body tissues including kidneys. *Malva neglecta* with antioxidant and contraceptive properties could be an appropriate alternative to synthetic drugs. This study was designed and conducted to compare the side effects of *M. neglecta* hydroalcoholic extract with those of prostodin on kidney tissue of rats. **Methods:** In this experimental study, 24 rats were assigned into four groups of six each; the group 1 as control received water and normal food. The groups 2 and 3 received oral *M. neglecta* hydroalcoholic extract at respectively 200 and 500 mg/kg/day and the group 4 was intraperitoneally injected with prostodin at 2 mg/kg/day. After 18 days of treatment, the rats were anesthetized, and after the blood was taken for biochemical experiments, their kidneys were isolated and studied using optical microscope after the tissue fragments were prepared and stained with hematoxylin and eosin. **Results:** Creatinine and urea levels decreased significantly in the groups treated with *M. neglecta* extract and increased significantly in the group receiving prostodin ( $p < 0.05$ ). In histopathologic studies, glomerular hypertrophy was observed in the rats treated with prostodin. In the groups receiving *M. neglecta* glomeruli structure was normal, while tubular damage was seen in some tubules. **Conclusions:** Prostodin caused severe damages to the kidneys through developing glomerular hypertrophy, decreasing urinary space, and increasing creatinine and urea of blood serum, but *M. neglecta* extract developed no adverse changes in glomeruli form and general structure of the kidney compared with the control group; therefore, *M. neglecta* could be a suitable alternative to prostodin thanks to its contraceptive property and fewer side effects.

© 2014 AENSI Publisher All rights reserved.

**To Cite This Article:** Amineh Beyrami-Miavagi, Farah Farokhi, Majid Asadi-Samani, A study of the effect of prostodin and hydroalcoholic extract of *Malva neglecta* on kidney histopathology and renal factors in female rats. *Adv. Environ. Biol.*, 8(9), 942-947, 2014

### INTRODUCTION

Prostaglandins naturally are saturated lipid acids and comprise three types, PGE1, PGE2, and PGF2a, each with a different function. Prostodin is one of artificial PGF2a analogues [1]. Prostodin is a chemical medication which may be used to terminate pregnancy. It has a series of side effects [2]. Prostodin is likely to contribute adversely to the body's organs including kidney, as well.

Nowadays, use of herbal medicines, instead of chemical ones, has been taken into consideration due to stupendous costs of chemical drugs and their adverse side effects on the body. With the advances in science and technology, various experiments have been conducted on plants in order to identify curative effects of the plants and the specific effect of each plant on a particular tissue and/or organ. Medicinal plants possibly cause fewer side effects thanks to containing natural substances, leading to health and decreasing the diseases, which is possibly due to various herbal chemical compounds with the antioxidant properties [3,4].

*Malva neglecta* is from the family Malvaceae. This family occurs in most regions worldwide, except the poles. *M. neglecta* contains malvin, mucilage, tannin, and glucose compounds as well as flavonoids and anthocyanins. Its leaves have a higher proportion of phenolic compounds. The therapeutic properties of this plant include relief of gastrointestinal and respiratory disorders, hemorrhoids, swollen eyes, some tumors and disorders, and renal diseases. *M. neglecta* is diuretic and sedative with anti-inflammatory properties [5-7].

Kidney contributes basically to filtration, metabolism, and excretion of metabolic products. Nephron is the main unit of kidney and blood infiltrator. Any change in different parts of nephron could be due to the damage to kidney. The substances excreted by the kidneys include urea, creatinine, and external ones like medications. Urea is produced from ammonia in the body. Its amount depends on the appropriate function of liver in its

**Corresponding Author:** Majid Asadi-Samani, Vice Chancellery for Research and Technology, Shahrekord University of Medical Sciences, Shahrekord, I.R. Iran. Tel.: 00983813349509, E-mail: [biology\\_2011@yahoo.com](mailto:biology_2011@yahoo.com)

synthesis and that of kidneys in its excretion. Creatinine is one of the products produced from phosphate creatinine decomposition in the muscles at a fixed rate [8]. The serum level of urea and creatinine is considered as one of the indices for measuring kidney function. The studies indicate that prostodin results in free radicals and oxidative damages to the body tissues [1].

Regarding the contraceptive property of *M. neglecta* as well as its antioxidant activity, this plant was used in the present work. In this study, the effect of prostodin and hydroalcoholic *M. neglecta* extract was studied and compared on renal tissue and serum level of urea and creatinine in rats.

#### *Methods:*

##### *The animals and experiment conditions:*

In this experimental study, 24 female rats weighing 150 to 150gr were used. The animals were obtained from the growth and maintenance center of animals, the Faculty of Sciences, University of Urmia. The diet was standard and water was freely placed at their disposal. The room conditions were 12h light/12h darkness cycle, 20-25°C temperature, and relative humidity 25-30%. To do this research, we assigned the rats into four groups of six each.

##### *Preparation of the hydroalcoholic extract:*

To prepare alcoholic extract of the plant, we supplied the plant's leaves and had Herbarium of Biology Department, Faculty of Sciences, University of Urmia approve them (Herbarium No:4904). Then, we dried the leaves in a dark room and pulverized them using an electronic mill. 100 gr of the prepared powder was mixed with ethanol at 1:8 proportion and placed on the shaker at laboratory temperature for 48 hours [9, 10]. Then, the solution was infiltrated using filter paper and the obtained fluid was concentrated using rotary and incubator for solvent evaporation. Finally, a black, highly consistent extract with was obtained, and then different required concentrations were prepared at mg/kg body weight dose using normal saline.

##### *Test step:*

The mice were randomly assigned into 4 groups of 6 each. One group was determined as control and received normal food and water. Groups 2 and 3 received *M. neglecta* extract at respectively 200 and 300 mg/kg/day as oral (gavage) [11]. Group 4 received prostodin at 2 mg/kg/day as intraperitoneal injection [12]. The treatment was on a daily basis, continued for 18 days, and was done at a predetermined hour for all groups.

##### *Blood taking and biochemical factors assessment:*

All rats were anesthetized using chloroform after treatment completion and blood was taken from the hearts. Blood samples were centrifuged (3000 rounds per 15 minutes) in heparinized tubes and serum samples were isolated. Serum levels of urea and creatinine were measured per instructions of specific kits (Zist Chemi, Iran) using spectrophotometry method.

##### *Histopatologic study:*

Tissue samples were isolated from the kidneys and placed in a fixed formalin 10% buffer. After fixation, the tissues were dehydrated using alcohol, made transparent in xylol, and after preparation of paraffin blocks, the fragments with 6 $\mu$  in diameter were prepared and studied using an optical microscope after staining with hematoxylin-eosin.

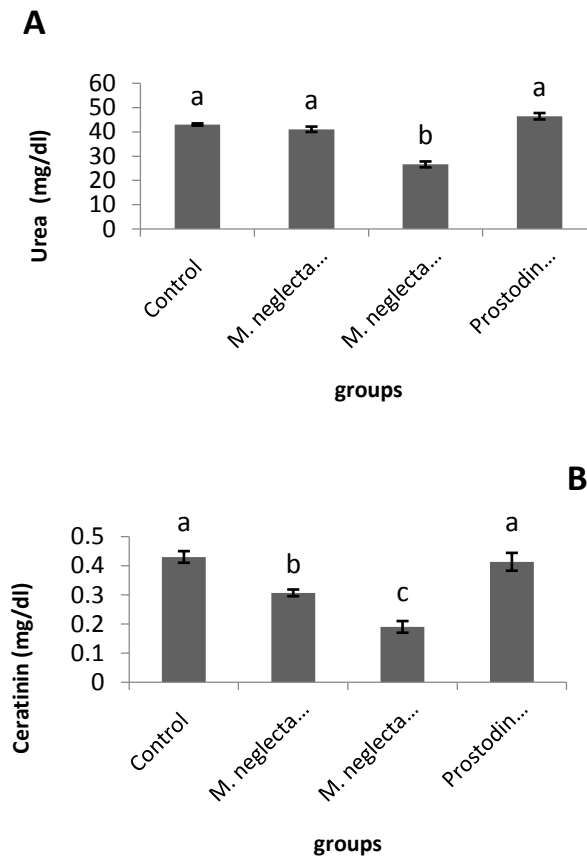
##### *Data analysis:*

Data were analyzed by SPSS13 using one-way ANOVA and Tukey's test.  $P < 0.05$  was considered as the level of significance.

#### *Results:*

##### *Biochemical findings:*

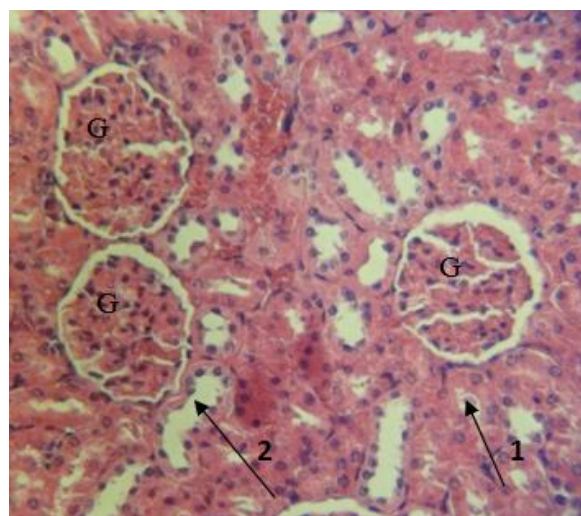
The results obtained from biochemical experiments of blood serum factors indicated that creatinine level in the groups treated with *M. neglecta* extract decreased significantly ( $P < 0.05$ ), in a way that the decrease was more remarkable in the group receiving the extract at 500 mg/kg/day than the extract at 200 mg/kg/day. In the prostodin group, a significant increase ( $P < 0.05$ ) was observed in serum level of creatinine compared to the control (Figure 1a). Urea level in the *M. neglecta* group at 500 mg/kg/day dose had a significant increase ( $P < 0.05$ ), but in the *M. neglecta* group at 200 mg/kg/day and prostodin group, no significant increase was noted in blood serum level of urea (Figure 1b).



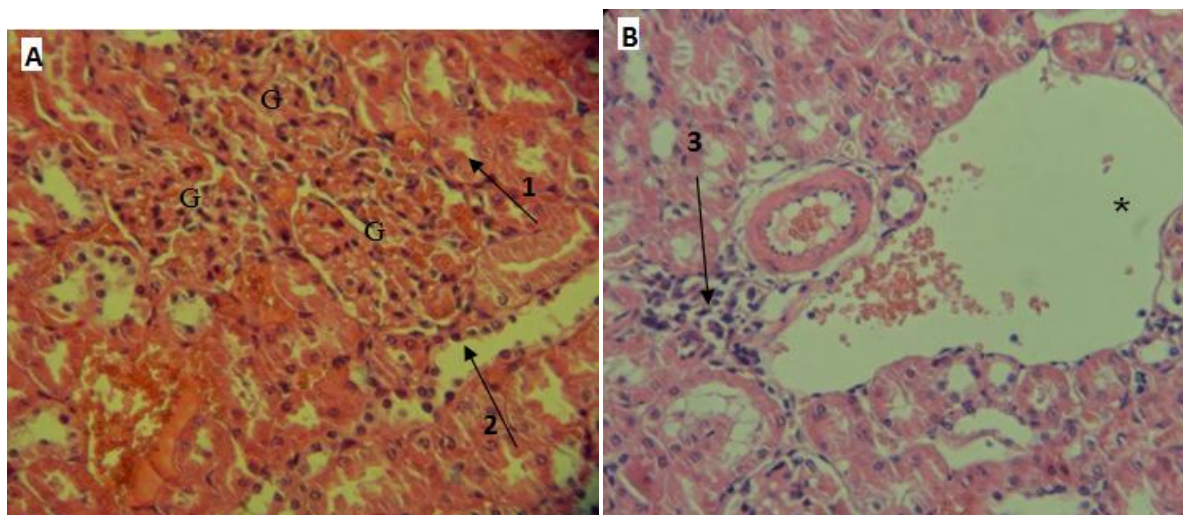
**Fig. 1:** The blood serum level of creatinine (A) and urea (B) in the groups under treatment

*Histopathologic findings:*

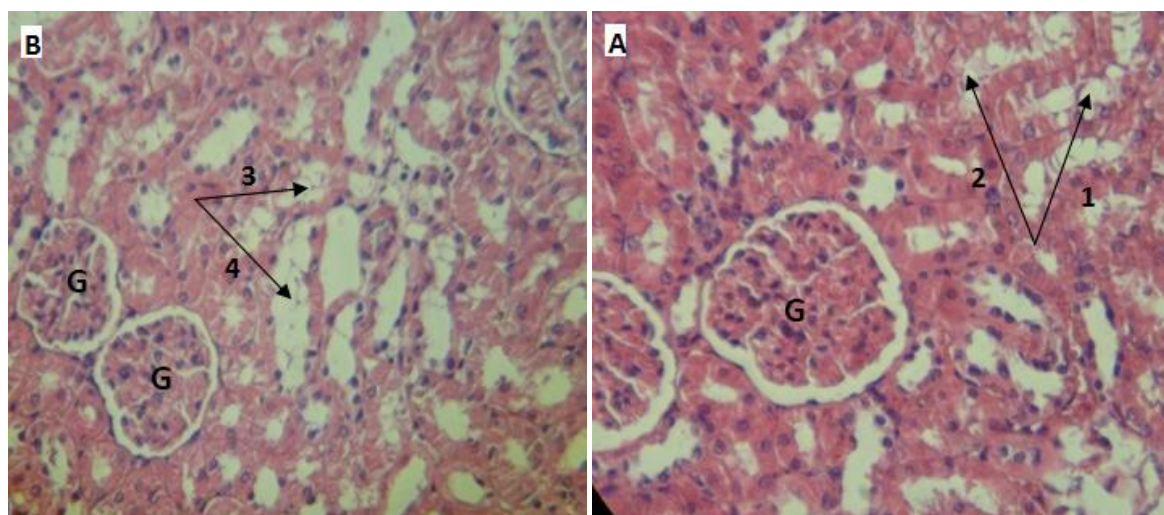
According to the conducted microscopic investigations of the profile obtained from kidney tissue, the structure and morphology of glomeruli and renal tubules were normal in the control group (Figure 1). In the prostodin group, glomerular hypertrophy and vascular dilation were noted and urinary space declined, in a way that in some points in glomeruli network, Bowman capsule was seen due to increased size in vicinity of external wall (Figure 2). In addition, dilation of blood vessels and accumulation of lymphoid cells around glomeruli network was observed. The presence of lymphoid cells in this region is the reason for inflammation in the interstitial tissue (Figure 3). But, in the groups receiving *M. neglecta*, the structure of glomeruli was natural and a small tubular damage was observed in some of the tubes (Figures 4).



**Fig. 2:** Profile of kidney tissue in the control group; G (normal glomeruli); Arrow 1 (proximal tube); arrow 2 (distal tube); hematoxylin and eosin staining at 40X magnification.



**Fig. 3:** Profiles of kidney tissue in the prostodin-treated group; A: Arrow 1 (proximal tube), arrow 2 (distal tube), G (dilated glomeruli); B: Arrow 3 (lymphoid cells accumulation and inflammation development); \* (Blood vessels dilation); hematoxylin and eosin staining at 40X magnification.



**Fig. 4:** Profiles of kidney tissue in the *M. neglecta*-treated group; A: *M. neglecta* group at 200 mg/kg/day dose; B: *M. neglecta* group at dose 500 mg/kg/day; G (normal glomeruli), arrow tips (1-4): samples of tubular analysis; hematoxylin and eosin staining at 40X magnification.

#### Discussion:

Prostodin, as an artificial compound from F2a prostaglandins causes adverse complications including destruction of body tissues. According to the conducted studies, prostaglandin causes development of free radicals in and oxidative damages to the body tissues [8]. By the study conducted by Sharma *et al.* (2010) PGF2a in the individuals with endometriosis increased significantly and led to oxidative stress [14]. The latest works indicate that oxidative stress results in kidney damage. Kidneys are one of the most important organs damaged throughout animal experiments using chemical compounds [13].

The serum level of urea and creatinine is considered as one of the important indices of kidney function measurement. Mora *et al* reported that creatinine serum level signaled the risk of chronic renal failures [15]. The findings of the present study indicated that prostodin caused increased serum level of creatinine. The increase in blood creatinine is caused by the damage to and disorder in nephrons' function and hence disorder in the process of kidney treatment.

According to the experiments, the increased prostaglandins caused damages to the kidney tissue [1, 16]. Some of researchers reported that excessive intake of proteins increased prostaglandins in the body and hence the kidneys size and glomerular hypertrophy [17, 18], which is consistent with the present study.

Dilation of glomeruli and increase in their size could cause vasodilatation and hence decrease in blood pressure in the vessels. Reported that prostaglandins caused decrease in blood pressure [1]. This study compared

the effects of *M. neglecta* with those of prostodin on kidneys because of the contribution of *M. neglecta* and prostodin to abortion.

*M. neglecta* is rich in antioxidant substances including flavonoids [6, 19]. Antioxidants, directly and/or indirectly, protect the cells against the damages to free radicals [20]. The important biological activities of plant flavonoids, particularly anti allergic, anti-inflammatory, and anti cancer, have been already demonstrated [21, 22]. According to the investigations on the flavonoids, these compounds cause recovery and protection of the damaged cells through increasing capacity of antioxidant enzymes such as glutathione, glutathione reductase, glutathione peroxidase, and catalase [23].

The works indicate that *M. neglecta* contribute importantly to treatment of kidney stone and relief of the pain due to it thanks to being diuretic. In addition to being diuretic, this plant is astringent and laxative [5, 6, 24]. In this study, a significant decrease was observed in urea and creatinine levels in the groups treated with *M. neglecta*, indicating lack of serious damages to kidneys. Histopathologically, *M. neglecta* caused tubular damage in some regions, but no damage and/or change was observed in the structure of glomeruli and Bowman capsule as the most important parts of the kidneys. In addition, no inflammation and/or accumulation of lymphoid cells was observed in the kidneys in the groups treated with *M. neglecta*, in contrast to the prostodin group, which could be explained by anti-inflammatory property of *M. neglecta*. Marouane et al found that treatment with vanadium caused damage to the kidneys, in a way that vanadium led to glomerular hypertrophy, decreased urinary space in kidney nephrons' Bowman capsule, and increased serum creatinine through inducing lipid peroxidation and increasing serum creatinine. But, the mice treatment with *M. sylvestris* species decreased free radicals and tissue damages developed by vanadium as well as serum creatinine and kidneys protection against oxidative damages due to the presence of antioxidant compounds like flavonoids in this plant [25].

#### Conclusions:

Biochemical and histopathologic investigations of this study indicated that prostodin caused increased blood serum creatinine and urea and Bowman capsule diameter, decreased urinary space, as well as glomerular dilation (glomerular hypertrophy), resulting in disorder in renal function, lack of proper blood treatment, and finally further increase in serum creatinine. However, *M. neglecta* caused decline in serum creatinine and no damage to the glomeruli as the most important parts of nephrons and protected the kidneys against serious damages. Therefore, it could be concluded that *M. neglecta* might be a suitable alternative to chemical drugs in abortion therapy thanks to its contraceptive property and fewer side effects (lack of obvious complications).

#### Funding/Support:

This research study was supported by Urmia University of Medical Sciences, Urmia, Iran.

#### REFERENCES

- [1] Dwivedi, C., K. Chandrakar, S.P. Tiwari, T. Satapathy, A. Roy, 2013. Systematic review of the role of prostaglandins. *World J Pharm Pharm Sci.*, 3(2): 2249-69.
- [2] Baduni, N., M.K. Sanwal, A. Jain, 2011. Acute pulmonary edema after intramyometrial prostodin. *J Anaesthesiol Clin Pharmacol.*, 27(2): 275-7.
- [3] Asadi-Samani, M., M. Rafieian-Kopaei, N. Azimi, 2013. *Gundelia*: a systematic review of medicinal and molecular perspective. *Pak J Biological Sci.*, 16(21): 1238-47.
- [4] Kooti, W., M. Ghasemiboroon, M. Asadi-Samani, A. Ahangarpour, M. Noori Ahmad Abadi, R. Afrisham, et al., 2014. The effects of hydro-alcoholic extract of celery on lipid profile of rats fed a high fat diet. *Adv Environ Biol.*, 8(9): 325-330.
- [5] Choi, C.W., S.C. Kim, S.S. Hwang, B.K. Choi, H.J. Ahn, M.Y. Lee, et al. 2002. Antioxidant activity and free radical scavenging capacity between Korean medicinal plants and flavonoids by assay-guided comparison. *Plant Sci.*, 163(6): 1161-8.
- [6] Dalar, A., M. Türker, I. Konczak, 2012. Antioxidant capacity and phenolic constituents of *Malva neglecta* Wallr. and *Plantago lanceolata* L. from Eastern Anatolia Region of Turkey. *J Herb Med.*, 2(2): 42-51.
- [7] Mojab, F., M. Kamalinejad, N. Ghaderi, H.R. Vahidipour, 2010. Phytochemical screening of some species of Iranian plants. *Iran J Pharm Res.*, 2(2): 77-82.
- [8] Gill, N., J.V. Nally, R.A. Fatica, 2005. Renal failure secondary to acute tubular necrosis: epidemiology, diagnosis, and management. *Chest.*, 128(4): 2847-63.
- [9] Satari, M., N. Shahbazi, S. Najar Pirayeh, 2005. An assessment of antibacterial effect of alcoholic and aquatic extracts of eucalyptus leaves on *Pseudomonas aeruginosa*. *Modares J Med Sci.*, 8(1): 23-19.
- [10] Ahmad, I., A.Z. Beg, 2001. Antimicrobial and phytochemical studies on 45 Indian medicinal plants against multi-drug resistant human pathogens. *J Ethnopharmacol.*, 74(2): 113-23.
- [11] Arzi, A., Z. Nazari-Khorasgani, M. Rahmani, 2013. Study the effects of *Malva sylvestris* hydro-alcoholic extract on carrageenan-induced inflammation in male rat paw. *Jentashapir.*, 4(1): 1-10.

- [12] Mala, Y., M. Gupta, S. Batra, 2011. Case Discussions in Obstetrics and Gynecology. In: Sharma R, Behera S, editors. Septic Abortion: A Clinical Review. 1ed. New Delhi: Jaypee Brothers Medical.
- [13] Mansour, S.A., A-T.H. Mossa, 2010. Oxidative damage, biochemical and histopathological alterations in rats exposed to chlorpyrifos and the antioxidant role of zinc. *Pesticide Biochem Physiol.*, 96(1): 14-23.
- [14] Sharma, I., L.K. Dhaliwal, S.C. Saha, S. Sangwan, V. Dhawan, 2010. Role of 8-iso-prostaglandin F<sub>2α</sub> and 25-hydroxycholesterol in the pathophysiology of endometriosis. *Fertil Steril.*, 94(1): 63-70.
- [15] Mora LdO, Antunes LMG, Francescato HsDC, Bianchi MdLP., 2003. The effects of oral glutamine on cisplatin-induced nephrotoxicity in rats. *Pharmacol Res.*, 47(6): 517-22.
- [16] Hostetter, T., 2001. Hypertrophy and hyperfunction of the diabetic kidney. *J Clin Invest.*, 107(2): 161-2.
- [17] Wang, M-H., A. Smith, Y. Zhou, H-H. Chang, S. Lin, X. Zhao, et al., 2003. Downregulation of renal CYP-derived eicosanoid synthesis in rats with diet-induced hypertension. *Hypertension.*, 42(4): 594-9.
- [18] Metges, C.C., C.A. Barth, 2000. Metabolic consequences of a high dietary-protein intake in adulthood: assessment of the available evidence. *J Nutr.*, 130(4): 886-9.
- [19] Güder, A., H. Korkmaz, 2012. Evaluation of in-vitro antioxidant properties of hydroalcoholic solution extracts *Urtica dioica* L., *Malva neglecta* Wallr. and their mixture. *Iran J Pharm Res.*, 11(3): 913-23.
- [20] Biesalski, H., J. Frank, 1995. Antioxidants in nutrition and their importance in the anti-oxidative balance in the immune system. *Immun Infekt.*, 23(5): 166-73.
- [21] Adewusi, E., A. Afolayan 2010. A review of natural products with hepatoprotective activity. *J Med Plants Res.*, 4(13): 1318-34.
- [22] Nasri, H., 2013. Comment on: A model for prediction of cisplatin induced nephrotoxicity by kidney weight in experimental rats. *J Res Med Sci.*, 18(12): 1119-20.
- [23] Bahrami-Karkevandi, M., S.J. Moshtaghian, P. Mahzoni, S. Adibi, S. Kazemi, 2011. The effects of hydroalcoholic extract of *Artemisia aucheri* on bleomycin induced pulmonary fibrosis in rats. *J Shahrekord Univ Med Sci.*, 12(4): 33-40.
- [24] Blanco, E., M. Macia, R. Morales, 1999. Medicinal and veterinary plants of El Caurel (Galicia, northwest Spain). *J Ethnopharmacol.*, 65(2): 113-24.
- [25] Marouane, W., A. Soussi, J-C. Murat, S. Bezzine, A. El Feki, 2011. The protective effect of *Malva sylvestris* on rat kidney damaged by vanadium. *Lipids Health Dis.*, 10(1): 65.