

# *Acta Medica Okayama*

---

*Volume 63, Issue 4*

2009

*Article 1*

AUGUST 2009

---

## No-reflow Phenomenon in Patients with Acute Myocardial Infarction: Its Pathophysiology and Clinical Implications

Hiroshi Ito\*

\*Department of Cardiovascular Medicine, Okayama University Graduate School of Medicine, Dentistry and Pharmaceutical Sciences, itomd@md.okayama-u.ac.jp

Copyright ©1999 OKAYAMA UNIVERSITY MEDICAL SCHOOL. All rights reserved.

# No-reflow Phenomenon in Patients with Acute Myocardial Infarction: Its Pathophysiology and Clinical Implications

Hiroshi Ito

## Abstract

For patients with acute myocardial infarction (MI), the immediate therapeutic goal is to establish the patency of the infarct-related artery. Prolonged myocardial ischemia, however, often breaks down the coronary microvasculature, and the flow to the infarct myocardium may be markedly reduced. This is called the no-reflow phenomenon. This phenomenon is important not solely because it correlates with infarct size but because it provides additional prognostic information. With recent advances in imaging modalities, the no-reflow phenomenon is observed more frequently than when clinical judgment alone is used. Patients with this phenomenon are associated with poor functional and clinical outcomes. Now, the no-reflow phenomenon can be a parameter with which to predict high-risk patients. The focus of reperfusion therapy has shifted toward the improvement of myocardial perfusion. The improvement of myocardial perfusion could promote the functional recovery of viable muscle and reduce infarct expansion, which is associated with favorable clinical outcomes. For this purpose, pharmacological interventions and catheter-based devices to retrieve embolic materials have been proposed. Advances in our understanding of the pathophysiology of microvascular dysfunction would aid the development of therapeutic strategies for its prevention and treatment.

**KEYWORDS:** cardiac function, coronary intervention, microcirculation, myocardial infarction, reperfusion

*Review*

## No-reflow Phenomenon in Patients with Acute Myocardial Infarction: Its Pathophysiology and Clinical Implications

Hiroshi Ito\*

*Department of Cardiovascular Medicine, Okayama University Graduate School of Medicine,  
Dentistry and Pharmaceutical Sciences, Okayama 700-8558, Japan*

For patients with acute myocardial infarction (MI), the immediate therapeutic goal is to establish the patency of the infarct-related artery. Prolonged myocardial ischemia, however, often breaks down the coronary microvasculature, and the flow to the infarct myocardium may be markedly reduced. This is called the no-reflow phenomenon. This phenomenon is important not solely because it correlates with infarct size but because it provides additional prognostic information. With recent advances in imaging modalities, the no-reflow phenomenon is observed more frequently than when clinical judgment alone is used. Patients with this phenomenon are associated with poor functional and clinical outcomes. Now, the no-reflow phenomenon can be a parameter with which to predict high-risk patients. The focus of reperfusion therapy has shifted toward the improvement of myocardial perfusion. The improvement of myocardial perfusion could promote the functional recovery of viable muscle and reduce infarct expansion, which is associated with favorable clinical outcomes. For this purpose, pharmacological interventions and catheter-based devices to retrieve embolic materials have been proposed. Advances in our understanding of the pathophysiology of microvascular dysfunction would aid the development of therapeutic strategies for its prevention and treatment.

**Key words:** cardiac function, coronary intervention, microcirculation, myocardial infarction, reperfusion

After acute myocardial infarction (MI), the immediate therapeutic goal is to establish the patency of the infarct-related artery. The successful restoration of epicardial coronary artery patency, however, does not necessarily translate into improved tissue perfusion. In the so-called no-reflow phenomenon, coronary microvasculature is often disrupted structurally, significantly reducing the flow to the previously ischemic myocardium. If this phenomenon occurs before or because of the percutaneous coronary

intervention (PCI) procedure, coronary flow is significantly reduced. With the advancement of imaging modalities, the percentage of patients in whom microvascular obstruction is detected has increased compared to the percentage detected by clinical judgment alone.

Patients with the no-reflow phenomenon have a poor clinical prognosis [1]. Therefore, our attention has shifted from just epicardial artery patency to the status of the coronary microvasculature. A better understanding of the pathophysiology of the no-reflow phenomenon in acute MI patients could aid the development of preventive and therapeutic strategies. In this review, I attempt to provide an in-depth under-

Received April 8, 2009; accepted May 28, 2009.

\*Corresponding author. Phone: +81-86-235-7346; Fax: +81-86-235-7353  
E-mail: itomd@md.okayama-u.ac.jp (H. Ito)

standing of the no-reflow phenomenon from the bench to the bedside.

### Pathophysiology of the No-reflow Phenomenon

The no-reflow phenomenon in the myocardium was originally described in 1974 by Kloner *et al.* [2]. The capillary structure is completely destroyed in the no-reflow zone as a result of endothelial swelling, compression by tissue, myocyte edema, and neutrophil infiltration. This pathologic process can be accelerated by coronary reperfusion [3]. Coronary reperfusion promotes several mechanisms, involved in this process, including tissue edema, endothelial disruption, plugging of capillaries by neutrophils and microthrombi, inflammation due to the generation of oxygen-free radicals and the activation of complements, and contracture of neighboring myocytes (Fig. 1). Thus, the no-reflow phenomenon results partly from reperfusion injury. In patients with acute MI, PCI potentially accelerates this pathological process. Mechanical stress to the coronary arterial plaque may accelerate the liberation of microthromboemboli and plaque gruel particles, which are thought to be show-

ered downstream, thus obstructing small arteries and arterioles, which in turn increases coronary arterial resistance and causes small MI.

The factors related to the development of the no-reflow phenomenon vary based on whether the cause is capillary destruction or microemboli to small arteries. Factors related to capillary destruction are similar to those of myocardial necrosis after acute MI, such as the duration of coronary occlusion, the extent of infarct risk area, the patency of the infarct-related artery, the development of collateral circulation, and the presence or absence of pre-infarction angina [4]. Pre-infarction angina produces a preconditioning-like effect and may promote collateral development. The quality of collateral channels is important for maintaining microvascular integrity.

Microemboli are likely to be generated during PCI to lipid-rich vulnerable plaques. The liberation of plaque components, including platelet-fibrin complex, macrophages, and cholesterol crystals, could obstruct resistance arteries and provoke arteriole spasms, leading to microvascular congestion. Coronary angiography shows sluggish coronary flow, but the reduction in coronary blood flow is usually transient [5, 6]. We can detect and quantify embolic particles in patients.

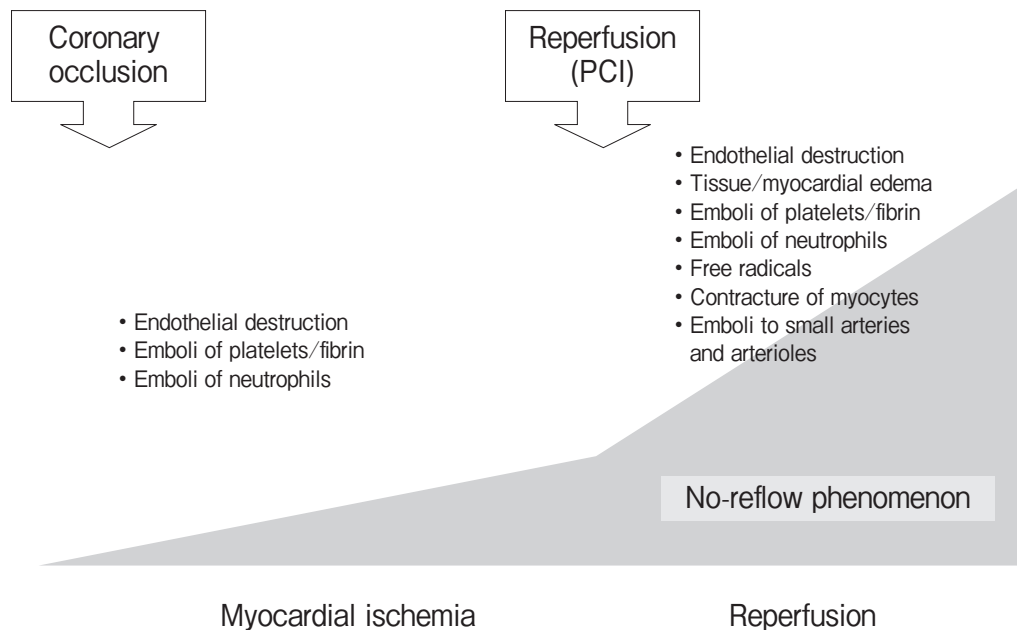


Fig. 1 Mechanisms of the no-reflow phenomenon in acute myocardial infarction.

Okamura *et al.* [7] used a Doppler guidewire to detect high-intensity transient signals, which allowed them to count the number of embolic particles. The average number of embolic particles was 20–30 throughout the PCI procedure in patients with acute MI. If the number of embolic particles is within this range, any notable derangement of coronary microcirculation is unlikely. Embolic particles can provoke myocardial damage and reduce myocardial blood flow only if they are large ( $> 200\mu\text{m}$  diameter) or their numbers are huge.

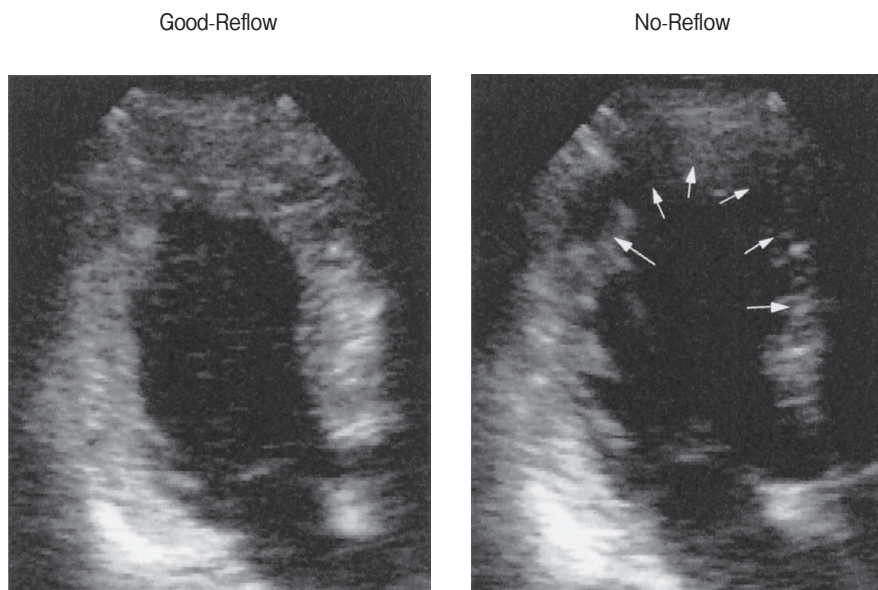
### Diagnosis of the No-reflow Phenomenon

#### *Myocardial contrast echocardiography.*

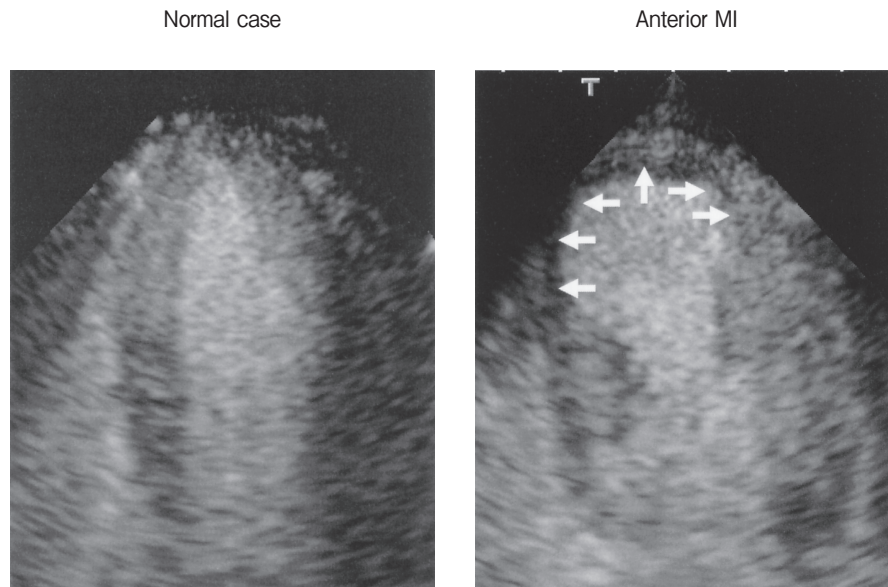
Myocardial contrast echocardiography (MCE) uses intravascular contrast agents that contain microbubbles as blood tracers. This modality can assess microvascular perfusion (Fig. 1), and hence has become the gold standard for investigating the no-reflow phenomenon. Initially, we performed MCE during coronary angiography by injecting sonicated

microbubbles into recanalized infarct-related arteries. Contrast perfusion defects of substantial size, implying the presence of no-reflow zones, were seen in 25–30% of patients with acute MI, even though coronary angiography showed open arteries (Fig. 2) [8]. At present, we can perform MCE at the bedside with intravenous injection of commercially available contrast agents (Fig. 3). The contrast perfusion defects appear in the center of the infarct zone, and may lead to the underestimation of the ultimate infarct size. They can match the infarct size after the vasodilator stress.

We can quantify the microvascular damage by measuring regional myocardial blood volume fraction. Since 90% of myocardial blood volume exists in capillaries, myocardial blood volume reflects capillary integrity as well as myocardial viability. The background-subtracted acoustic intensity for the myocardium correlates with the number of microbubbles. When the intensity is normalized to acoustic intensity for the adjacent left ventricular cavity, myocardial blood volume fraction can be measured. We developed



**Fig. 2** Myocardial contrast echocardiograms in patients with acute anterior wall myocardial infarction: good reflow and no reflow. Both patients had total occlusion in the proximal left anterior descending coronary artery. After percutaneous coronary intervention, both patients had patent coronary artery. We injected sonicated contrast medium into the left coronary artery. In the case on the left, all of the myocardium shows contrast enhancement, implying the success of coronary reperfusion at the myocardium level. In the right case, substantially sized contrast perfusion defects were observed in the distal septum and in the cardiac apex (arrows), implying the occurrence of the no-reflow phenomenon.



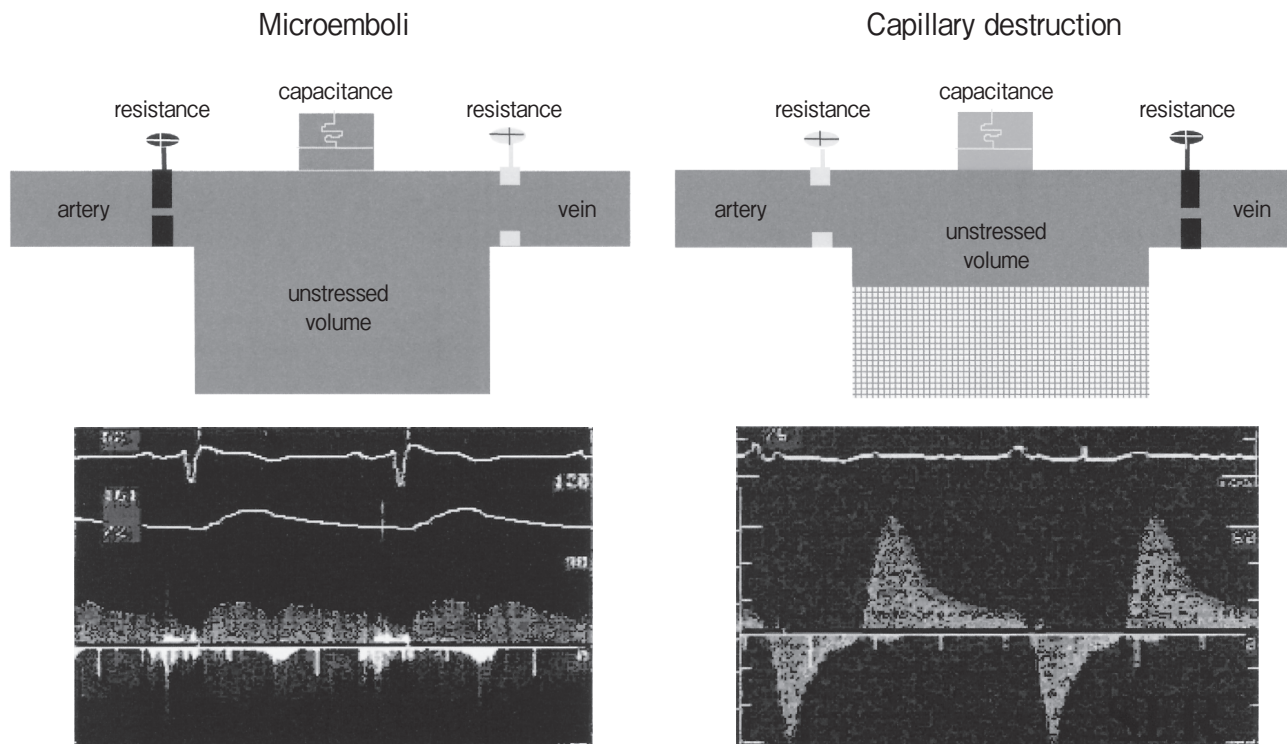
**Fig. 3** Myocardial contrast echocardiograms in a normal case and in a patient with anterior myocardial infarction. We can perform myocardial contrast echocardiography with intravenous injection of commercially available contrast medium. In the normal subject, all of the left ventricular myocardium shows contrast enhancement. In the case of anterior myocardial infarction (MI), contrast perfusion defects were observed from the distal septum to the cardiac apex (arrows).

software to show the distribution of myocardial blood volume of the left ventricle in a colour-coded fashion. One MCE image provides enough data for the analysis, and shows the map of capillary integrity of the left ventricle [9].

**Coronary angiography.** Microvascular dysfunction reduces coronary blood flow, and appears on coronary angiography as sluggish coronary. Thrombolysis In Myocardial Infarction (TIMI) blood flow grades are used to evaluate the quality of coronary flow [10]. This method measures the coronary artery clearance of radiographic dye. Historically, TIMI-0/1 flow was considered a failure of reperfusion and TIMI-2/3 flow indicates successful reperfusion. In practice, however, TIMI-2 flow is associated with poor clinical outcomes, similar to the outcomes for patients with TIMI-0/1 flow [11]. Our study using MCE indicated that TIMI-2 flow is associated with substantial no-reflow phenomenon; therefore, only TIMI-3 flow indicates reperfusion success [12]. Even after stenting, patients with acute MI do not necessarily achieve TIMI-3 flow; this underscores the fact that the major cause of sluggish flow is unrelated to the degree of epicardial stenosis but rather is related to decreased

perfusion in the microvasculature.

**Doppler assessment of coronary blood flow velocity pattern (Fig. 4).** We can monitor coronary blood flow velocity with a Doppler guidewire and transthoracic Doppler technique. The no-reflow phenomenon has a characteristic coronary blood flow pattern, with 3 main components: systolic flow reversal; reduced antegrade systolic flow; and forward diastolic flow with a rapid deceleration slope [13]. Because of this to-and-fro nature, coronary forward flow is reduced. The coronary blood flow velocity pattern is caused by extensive capillary damage, which is associated with increased capillary resistance and a reduced myocardial blood pool. The coronary blood flow velocity pattern differs in individuals with microemboli from those without, and is characterized with slow forward flow and an increase in the diastolic-to-systolic flow ratio, indicating increased coronary arterial resistance. At least 2 different coronary blood flow velocity patterns can, therefore, be seen in patients with slow coronary flow after PCI.



**Fig. 4** Coronary blood flow velocity patterns in a case of microemboli (left) and in a case of capillary obstruction. In a case of microemboli to coronary resistance vessels, coronary flow velocity falls during the cardiac cycle. In a case of capillary destruction, the myocardial blood volume decreases significantly, and thus coronary flow rapidly fulfills the unstressed volume of coronary microcirculation to cause rapid deceleration of diastolic flow velocity. Due to the obstruction of capillaries and venules, an increase in systolic myocardial stress causes the reverse flow, called systolic flow reversal.

### Clinical Implications of the No-reflow Phenomenon

The no-reflow phenomenon is important not solely because it correlates with infarct size but also because it provides additional prognostic information [14]. Because the no-reflow phenomenon occurs after the myocytes in the area are already dead, the presence of the no-reflow zone virtually rules out later recovery of function. A large no-reflow zone is associated with reduced left ventricular contractile function. In addition to predicting the recovery of systolic function, the presence of no-reflow predicts acute complications after acute MI. Patients with the no-reflow phenomenon are in the highest-risk subgroup of patients undergoing reperfusion, with increased associated risks of early and more protracted congestive heart failure, and of death. A large no-reflow zone may impede the infarct's ability to heal and prevent deliv-

ery of pharmacological agents into the infarct zone. No-reflow zones sustain transmural damage, and in large zones infarct expansion and early left ventricular dilation are likely to occur. The no-reflow phenomenon was also linked to ventricular arrhythmias and even cardiac rupture. There is also evidence that it may have an adverse effect on left ventricular remodeling after MI. This elevated risk has implications for therapy.

### Treatment of the No-reflow Phenomenon

The focus of reperfusion therapy is shifting toward improving the patency of the wider vasculature in the affected area rather than merely that of the target vessel. The improvement of tissue perfusion could promote the functional recovery of viable muscle, reduce infarct expansion, and possibly enhance the delivery of blood-borne components. Bone marrow

components contain endothelial precursors with phenotypic and functional characteristics of embryonic hemangioblasts, and these can be used to directly induce new blood vessel formation in the infarct bed (vasculogenesis) and the proliferation of pre-existing vasculature (angiogenesis) after experimental myocardial infarction [15]. Neovascularization of ischemic myocardium by human bone marrow-derived angioblasts prevents cardiomyocyte apoptosis, reduces remodeling, and improves cardiac function.

**Treatment of microemboli.** Promising adjunctive therapies to reduce microemboli include intensive anti-platelet therapy with aspirin and clopidogrel, platelet glycoprotein IIb/IIIa receptor inhibitors, coronary vasodilators, and devices to protect against embolization. Thrombolytic agents seem not to improve microvascular function.

Aggressive treatment of platelet microembolism with glycoprotein IIb/IIIa receptor inhibitors has yielded encouraging results. The Abciximab before Direct Angioplasty and Stenting in Myocardial Infarction Regarding Acute and Long-Term Follow-up (ADMIRAL) trial [16] provided preliminary evidence that intravenous abciximab is associated with a high incidence of TIMI-3 flow and with an 80% reduction in adverse cardiac events compared with control among acute MI patients undergoing primary PCI. However, it remains unknown whether the improvement in coronary flow is mediated by the inhibition of platelet aggregation or by faster establishment of epicardial artery recanalization.

A more direct method to reduce the thrombus or plaque burden is to retrieve embolic materials with catheter-based devices. Some devices directly aspirate thrombus and plaque contents at the occlusion site, and others are distal protection devices designed to trap embolic materials. These systems effectively retrieve embolic debris in most patients with acute MI undergoing emergent PCI. Nonetheless, distal embolic protection has failed to show improved microvascular flow, greater reperfusion success, reduced infarct size, or enhanced event-free survival [17, 18]. The patients in whom these devices are to be used should, therefore, be selected carefully. Identification of ruptured plaque by intravascular angioscopy might be useful for identifying patients who could respond to distal protection [19].

**Treatment of capillary dysfunction.** If

pharmacologic intervention could protect myocytes and the microvasculature against ischemic injury, reperfusion injury, or both, post-ischemic microvascular flow would be augmented and functional and clinical outcomes improved. Adenosine yields benefits beyond simple vasodilation that make it a potential therapy to achieve this goal. Adenosine lowers neutrophil counts in infarct zones, maintains endothelial integrity and may exert a cardioprotective effect that is related to ischemic preconditioning. In patients with acute MI, intracoronary administration of 24–48  $\mu\text{g}$  adenosine is well tolerated and improves microvascular and ventricular function in the infarct zone, leading to an improved clinical course after PCI [20]. Intravenous administration of adenosine, however, is not powerful enough to reduce infarct size. The AMISTAD II trial assessed clinical outcomes and infarct size in 21,118 patients with ST-segment elevation MI undergoing reperfusion therapy, with adenosine as an adjunct therapy [21]. The clinical outcomes were not significantly improved with adenosine, although infarct size was reduced with a high-dose infusion ( $70 \mu\text{g kg}^{-1} \text{min}^{-1}$ ). Nicorandil is a hybrid between mitochondrial potassium-channel opener and NO, and has showed promising results in patients with acute MI when given before reperfusion. This drug reduces preload and afterload, dilates coronary resistance vessels, reduces  $\text{Ca}^{2+}$  overload of myocytes, and attenuates neutrophil activation. Since the mitochondrial potassium channel is an end-effector of the ischemic preconditioning pathway, nicorandil could protect myocardium against ischemic injury. Studies have demonstrated that among reperfused patients who received intravenously administered nicorandil, infarct size was reduced and clinical outcome improved [22, 23]. An associated improvement in microvascular perfusion was observed in the nicorandil treatment group.

The use of vasodilators, including nitrates, verapamil, papaverine, nicardipine, and sodium nitroprusside may also have a role in improving post-ischemic microvascular function. Intracoronary nitroprusside or verapamil was associated with a significant improvement in coronary flow, with an increase in TIMI flow grade [24, 25]. Intracoronary verapamil was associated with better functional recovery in wall motion abnormalities. These strategies are not formally approved for treating no-reflow. In cases of TIMI-2 flow after PCI, we should attempt this



strategy to restore coronary blood flow, which is essential for improved left ventricular function and better cardiac outcomes.

Sodium-hydrogen pump inhibitors have the potential to reduce reperfusion injury by attenuating intracellular  $\text{Ca}^{2+}$  overload. In an experimental study, the use of such an agent improved microvascular function and myocardial blood flow, and reduced infarct size [26]. Large-scale, multicenter trials did not, however, show any benefit of cariporide or eniporide on functional and clinical outcomes in patients with a wide range of ischemic risk [27, 28]. Other adjunctive agents, including monoclonal antibodies to leukocytes, complement receptor inhibitors, adhesion molecule antibodies, endothelin-A selective antagonists, and erythropoietin, might have potential therapeutic roles. Double-blind, randomized multicenter trials should be conducted to assess the potential of these agents to treat the no-reflow phenomenon or to determine the appropriate dosage.

Catheter-based techniques can exert cardio-protective effects. Experimental studies have demonstrated that multiple, short induced coronary occlusions immediately after sustained myocardial ischemia are associated with reduced MI size compared with sudden reperfusion [29]. This cardio-protective intervention is called post-conditioning. The mechanism of protection involves the activation of extracellular-signal-regulated kinase, production of nitric oxide, opening of mitochondrial potassium channels, and inhibition of the opening of the mitochondrial permeability transition pore. A similar approach could be applied in cardiac catheterization laboratories to protect reperfused myocardium after primary angioplasty in patients with acute MI. Staat *et al.* [30] performed postconditioning during PCI for acute MI in humans, starting within 1 min of reflow, and achieved by inflating an angioplasty balloon for 1 min followed by deflation for 1 min 4 times. Improvements were seen in myocardial perfusion and functional outcomes compared with those in patients who did not undergo post-conditioning. This catheter-based technique may be clinically applicable in PCI, CABG, organ transplantation, and peripheral revascularization where reperfusion injury is expressed.

## Conclusions

The no-reflow phenomenon occurs in a notable proportion of patients with acute MI, despite aggressive reperfusion therapy, and is associated with a poor prognosis. To stratify risk among acute MI patients, it is useful to look beyond epicardial artery patency and to assess microvascular perfusion. The identification of a mechanism of microvascular dysfunction is the key to defining specific therapeutic strategies for reperfusion. To accelerate the development of new reperfusion regimens, an integrated approach that incorporates multiple efficacy variables to assess the success or failure of tissue perfusion could be required.

## References

1. Kaul S and Ito H: Microvasculature in acute myocardial ischemia: Part II. Evolving concepts in pathophysiology, diagnosis, and treatment. *Circulation* (2004) 109: 310-315.
2. Kloner RA, Ganote CE and Jennings RB: The 'no reflow' phenomenon after temporary occlusion in the dog. *J Clin Invest* (1974) 54: 1496-1508.
3. Villanueva FS, Glasheen WP, Sklenar J and Kaul S: Characterization of spatial patterns of flow within the reperfused myocardium by myocardial contrast echocardiography. Implication in determining extent of myocardial salvage. *Circulation* (1993) 88: 2596-2606.
4. Nakagawa Y, Ito H, Kitakaze M, Kusuoka H, Hori M, Kuzuya T, Higashino Y, Fujii K and Minamino T: Effect of angina pectoris on myocardial protection in patients with reperfused anterior wall myocardial infarction: Retrospective clinical evidence of "Preconditioning" *J Am Coll Cardiol* (1995) 25: 1076-1083.
5. Tanaka A, Kawarabayashi T, Nishibori Y, Sano T, Nishida Y, Fukuda D, Shimada K and Yoshikawa J: No-reflow phenomenon and lesion morphology in patients with acute myocardial infarction. *Circulation* (2002) 105: 2148-2152.
6. Kotani J, Nanto S, Mintz GS, Kitakaze M, Ohara T, Morozumi T, Nagata S and Hori M: Plaque gruel of atheromatous coronary lesion may contribute to the no-reflow phenomenon in patients with acute coronary syndrome. *Circulation* (2002) 106: 1672-1677.
7. Okamura A, Ito H, Iwakura K, Kawano S, Inoue K, Maekawa Y, Ogihara T and Fujii K: Detection of embolic particles with the Doppler guide wire during coronary intervention in patients with acute myocardial infarction. Efficacy of distal protection device. *J Am Coll Cardiol* (2005) 45: 212-215.
8. Ito H, Tomooka T, Sakai N, Yu H, Higashino Y, Fujii K, Masuyama T, Kitabatake A and Minamino T: Lack of myocardial perfusion immediately after successful thrombolysis: a predictor of poor recovery of left ventricular function in anterior myocardial infarction. *Circulation* (1992) 85: 1699-1705.
9. Yano A, Ito H, Iwakura K, Kimura R, Tanaka K, Okamura A, Kawano S, Masuyama T and Fujii K: Myocardial contrast echocardiography with a new calibration method can estimate myocardial viability in patients with myocardial infarction. *J Am Coll Cardiol* (2004) 43: 1799-1806.

10. Zijlstra F, de Boer MJ, Hoorntje JC, Reiffers S, Reiber JH and Suryapranata H: A comparison of immediate coronary angioplasty with intravenous streptokinase in acute myocardial infarction. *N Engl J Med* (1993) 28: 680-684.
11. Simes RJ, Topol EJ, Holmes DR Jr, White HD, Rutsch WR, Vahanian A, Simoons ML, Morris D, Betriu A and Califf RM: Link between the angiographic substudy and mortality outcomes in a large randomized trial of myocardial reperfusion: Importance of early and complete infarct artery reperfusion. *Circulation* (1995) 91: 1923-1928.
12. Ito H, Okamura A, Iwakura K, Masuyama T, Hori M, Takiuchi S, Negoro S, Nakatsuchi Y, Taniyama Y, Higashino Y, Fujii K and Minamino T: Myocardial perfusion patterns related to thrombolysis in myocardial infarction perfusion grades after coronary angioplasty in patients with acute anterior wall myocardial infarction. *Circulation* (1996) 93: 1993-1999.
13. Iwakura K, Ito H, Takiuchi S, Taniyama Y, Nakatsuchi Y, Negoro S, Higashino Y, Okamura A, Masuyama T, Hori M, Fujii K and Minamino T: Alternation in the coronary blood flow velocity pattern in patients with no reflow and reperfused acute myocardial infarction. *Circulation* (1996) 94: 1269-1275.
14. Ito H, Maruyama A, Iwakura K, Takiuchi S, Masuyama T, Hori M, Higashino Y, Fujii K and Minamino T: Clinical implications of the "no reflow" phenomenon. A predictor of complications and left ventricular remodeling in reperfused anterior wall myocardial infarction" *Circulation* (1996) 93: 223-228.
15. Kocher AA, Schuster MD, Szabolcs MJ, Takuma S, Burkoff D, Wang J, Homma S, Edwards NM and Itescu S: Neovascularization of ischemic myocardium by human bone marrow-derived angioblasts prevents cardiomyocyte apoptosis reduces remodeling and improves cardiac function. *Nat Med* (2001) 7: 430-436.
16. Montalescot G, Barragan P, Wittenberg O, Ecollan P, Elhadad S, Villain P, Boulenc JM, Morice MC, Maillard L, Pansieri M, Choussat R and Pinton P: Platelet glycoprotein IIb/IIIa inhibition with coronary stenting for acute myocardial infarction. *N Engl J Med* (2001) 344: 1895-1903.
17. Stone GW, Webb J, Cox DA, Brodie BR, Qureshi M, Kalynych A, Turco M, Schultheiss HP, Dulas D, Rutherford BD, Antoniucci D, Krucoff MW, Gibbons RJ, Jones D, Lansky AJ and Mehran R: Distal microcirculatory protection during percutaneous coronary intervention in acute ST-segment elevation myocardial infarction: a randomized controlled trial. *JAMA* (2005) 293: 1063-1072.
18. Gick M, Jander N, Bestehorn HP, Kienzle RP, Ferenc M, Werner K, Comberg T, Peitz K, Zohlhoffer D, Bassignana V, Buettner HJ and Neumann FJ: Randomized evaluation of the effects of filter-based distal protection on myocardial perfusion and infarct size after primary percutaneous catheter intervention in myocardial infarction with and without ST-segment elevation. *Circulation* (2005) 112: 1462-1469.
19. Mizote I, Ueda Y, Ohtani T, Shimizu M, Takeda Y, Oka T, Tsujimoto M, Hirayama A, Hori M and Kodama K: Distal protection improved reperfusion and reduced left ventricular dysfunction in patients with acute myocardial infarction who had angiographically defined ruptured plaque. *Circulation* (2005) 112: 1001-1007.
20. Marzilli M, Orsini E, Marraccini P and Testa R: Beneficial effects of intracoronary adenosine as an adjunct to primary angioplasty in acute myocardial infarction. *Circulation* (2000) 101: 2154-2159.
21. Ross AM, Gibbons RJ, Stone GW, Kloner RA and Alexander RW: A randomized, double-blinded, placebo-controlled multi-center trial of adenosine as an adjunct to reperfusion in the treatment of acute myocardial infarction (AMISTAD-II). *J Am Coll Cardiol* (2005) 45: 1775-1780.
22. Ito H, Taniyama Y, Iwakura K, Nishikawa N, Masuyama T, Kuzuya T, Hori M, Higashino Y, Fujii K and Minamino T: Intravenous nicorandil can preserve microvascular integrity and myocardial viability in patients with reperfused anterior wall myocardial infarction. *J Am Coll Cardiol* (1999) 33: 654-666.
23. Ishii H, Ichimiya S, Kanashiro M, Amano T, Imai K, Murohara T and Matsubara T: Impact of a single intravenous administration of nicorandil before reperfusion in patients with ST-segment-elevation myocardial infarction. *Circulation* (2005) 112: 1284-1288.
24. Taniyama Y, Ito H, Iwakura K, Masuyama T, Hori M, Takiuchi S, Nishikawa N, Higashino Y, Fujii K and Minamino T: Beneficial effect of intracoronary verapamil on microvascular and myocardial salvage in patients with acute myocardial infarction. *J Am Coll Cardiol* (1997) 30: 1193-1199.
25. Pasceri V, Pristipino C, Pelliccia F, Granatelli A, Speciale G, Roncella A, Pironi B, Capasso M and Richichi G: Effects of the nitric oxide donor nitroprusside on no-reflow phenomenon during coronary interventions for acute myocardial infarction. *Am J Cardiol* (2005) 95: 1358-1361.
26. Theroux P: Myocardial cell protection: a challenging time for action and a challenging time for clinical research. *Circulation* (2000) 101: 2874-2876.
27. Theroux P, Chaitman BR, Danchin N, Erhardt L, Meinertz T, Schroeder JS, Tognoni G, White HD, Willerson JT and Jessel A: Inhibition of the sodium-hydrogen exchanger with cariporide to prevent myocardial infarction in high-risk ischemic situations. Main results of the GUARDIAN trial. *Circulation* (2000) 102: 3032-3038.
28. Zeymer U, Suryapranata H, Monassier JP, Opolski G, Davies J, Rasmanis G, Linssen G, Tebbe U, Schröder R, Tiemann R, Machnig T and Neuhaus KL: The Na(+)/H(+) exchange inhibitor eniporide as an adjunct to early reperfusion therapy for acute myocardial infarction. Results of the evaluation of the safety and cardioprotective effects of eniporide in acute myocardial infarction (ESCAMI) trial. *J Am Coll Cardiol* (2001) 38: 1644-1650.
29. Tsang A, Hausenloy DJ, Mocanu MM and Yellon DM: Postconditioning: a form of "modified reperfusion" protects the myocardium by activating the phosphatidylinositol 3-kinase-Akt pathway. *Circ Res* (2004) 95: 230-232.
30. Staat P, Rioufol G, Piot C, Cottin Y, Cung TT, L'Huillier I, Aupetit JF, Bonnefoy E, Finet G, André-Fouët X and Ovize M: Postconditioning the human heart. *Circulation* (2005) 112: 2143-2148.