

Acta Medica Okayama

Volume 60, Issue 6

2006

Article 2

DECEMBER 2006

Assessment of Head Wear More Than Ten Years after Total Hip Arthroplasty: 22-mm Zirconia VS. Metal Heads.

Atsushi Inoue*

Koji Asaumi†

Hirosuke Endo‡

Kazuo Fujiwara**

Shigeru Mitani††

Toshifumi Ozaki‡‡

*Okayama University,

†Okayama University,

‡Okayama University,

**Okayama University,

††Okayama University,

‡‡Okayama University,

Assessment of Head Wear More Than Ten Years after Total Hip Arthroplasty: 22-mm Zirconia VS. Metal Heads.*

Atsushi Inoue, Koji Asaumi, Hirosuke Endo, Kazuo Fujiwara, Shigeru Mitani,
and Toshifumi Ozaki

Abstract

The present retrospective study assessed radiographs to determine socket wear in total hip arthroplasty (THA) with 22-mm zirconia or COP (Cobalt-Chrome alloy rich in Cobalt and Phosphorous) heads, and in cemented stems at more than 10 years after operation. Sockets of ultra high molecular weight polyethylene were used in each of two THA groups (13 hips each) in a clinical trial in our hospital between 1989 and 1990. Three observers carried out masked assessments of the radiographs. Upon final examination, there was no remarkable loosening in the zirconia or COP group, and no case had required revision surgery as of 2005. There was a statistically significant difference between the 2 groups in average annual linear wear, at 0.093 mm/year and 0.046 mm/year in the zirconia and COP groups, respectively. Volume wear and average annual volume wear were also significantly greater in the zirconia group despite its superior mechanical strength and toughness in vitro. Our present findings do not confirm early expectations of lower wear in long-term results of 22-mm zirconia femoral heads used in THA.

KEYWORDS: total hip arthroplasty, zirconia head, COP head, polyethylene, wear

*PMID: 17189974 [PubMed - in process]

Original Article

Assessment of Head Wear More Than Ten Years after Total Hip Arthroplasty: 22-mm Zirconia vs. Metal Heads

Atsushi Inoue, Koji Asaumi*, Hirosuke Endo, Kazuo Fujiwara,
 Shigeru Mitani, and Toshifumi Ozaki

Department of Orthopaedic Surgery, Okayama University Graduate School of Medicine,
 Dentistry and Pharmaceutical Sciences, Okayama 700–8558, Japan

The present retrospective study assessed radiographs to determine socket wear in total hip arthroplasty (THA) with 22-mm zirconia or COP (Cobalt-Chrome alloy rich in Cobalt and Phosphorous) heads, and in cemented stems at more than 10 years after operation. Sockets of ultra high molecular weight polyethylene were used in each of two THA groups (13 hips each) in a clinical trial in our hospital between 1989 and 1990. Three observers carried out masked assessments of the radiographs. Upon final examination, there was no remarkable loosening in the zirconia or COP group, and no case had required revision surgery as of 2005. There was a statistically significant difference between the 2 groups in average annual linear wear, at 0.093 mm/year and 0.046 mm/year in the zirconia and COP groups, respectively. Volume wear and average annual volume wear were also significantly greater in the zirconia group despite its superior mechanical strength and toughness *in vitro*. Our present findings do not confirm early expectations of lower wear in long-term results of 22-mm zirconia femoral heads used in THA.

Key words: total hip arthroplasty, zirconia head, COP head, polyethylene, wear

More than 30 years have passed since Charnley [1, 2] established the theory of low friction arthroplasty, and numerous researchers have reported excellent long-term results. Charnley-type total hip arthroplasty (THA) has been modified over the years in terms of the employed surgical techniques and implants, and is still considered the gold standard. Reports with revision surgery as the end-point have shown that mean survival of the arthroplasty is approximately 90% at 20 years after operation [3, 4]. In the long term, the most critical issue is aseptic loosening of the implants caused by histio-

cytes and foreign body giant cells, which engulf minute wear particles such as polyethylene, resulting in the formation of harmful granulomas between bones and artifacts, as well as bone absorption and destruction [5–10]. In our institute, we have tried to develop a cemented Charnley-type THA implant that provides lower friction and is more wear-tolerant.

Since 1972, when Boutin [11] first clinically applied THA with alumina ceramic components, alumina ceramic has been used in a number of implant designs because of its wear tolerance and excellent biocompatibility. However, it is fragile and will break when exposed to pressures greater than the elasticity threshold. Furthermore, it is not impact resistant [12]. Zirconia ceramic (zirconia) has recently attracted attention because it has greater

Received April 24, 2006; accepted July 12, 2006.

*Corresponding author. Phone: +81-86-235-7273; Fax: +81-86-223-9727
 E-mail: kasaumi103@yahoo.co.jp (K. Asaumi)

strength and elasticity than alumina. Like alumina, zirconia is bioinert and has excellent biocompatibility; no safety problems were detected in a number of tests on endoprostheses [12].

To the best of our knowledge, this study is the first report on long-term outcomes of THA with 22-mm zirconia heads in cases that have been followed for more than 10 years. This study compares long-term polyethylene wear in cases of cemented THA with 22-mm zirconia heads with that in cases with 22-mm COP heads.

Materials and Methods

The subjects of the present study were the same patients as those in a previously reported clinical trial conducted in our department between 1989 and 1990 for whom all follow-up radiographs were available [12]. Informed consent for participation in the present study was also required for inclusion. The original study was approved by the research ethics review board of the authors' institution. All of the patients had undergone cemented THA with a combination of a socket made of ultra high molecular weight polyethylene (UHMWPE) and a 22-mm zirconia head or a COP (Cobalt-Chrome alloy rich in Cobalt and Phosphorous) head. The first group of subjects was composed of 13 hips in 13 patients who had received a 22.225-mm zirconia head (the zirconia group: follow-up rate, 86.7%), while the second included 13 hips in 13 patients who had received a 22.225-mm COP head (the COP group: follow-up rate, 81.3%). Two members of the zirconia group had bilateral THA, but only the first side treated was included in the present analysis. The zirconia group had 7 hips with osteoarthritis (OA), 2 hips with avascular necrosis of the femoral head, and 4 hips with rheumatoid arthritis (RA). The patients were 12 women and 1 man with an average age of 57 years (range: 42–70 years) at the time of operation, and the average follow-up period after operation was 11.8 years (range: 10.3–13.2 years). The COP group was composed of 11 hips with OA and 2 hips with RA in 12 women and 1 man with an average age of 58 years (range: 43–66 years) at the time of operation, with an average follow-up period of 12.1 years (range: 10.9–12.9 years).

Socket. The UHMWPE socket had a flange,

an inner diameter of 22.25 mm, and an outer diameter of 40 mm or 44 mm, with the polyethylene thickness maintained at 9 mm or more. The socket was not sterilized with γ radiation before implantation. Since the flange and socket were made separately, they were circular and spherical, with a greatly improved contact surface [13]. Before cementation, subchondral bone on the acetabular side was preserved and multiple anchoring holes were made for the injection of cement.

Heads. The zirconia heads (Nippon Tokushu Tougyou Co, Nagoya, Japan) were made of partially stabilized zirconia (Y2O3-ZrO2), which is a ceramic high in strength and elasticity. They were 22.225 mm in diameter and 0.004 μ m in surface roughness, and had a low-friction design with high wear tolerance [14–19]. Biomechanical tests revealed that they had low-friction torque because they were hard, circular and spherical, with a surface roughness comparable to that of conventional alumina heads [14, 19]. The COP heads (Mizuho Ikakogyo Co., Tokyo, Japan) were 22.225 mm in diameter and were as circular and spherical as the zirconia heads. COP is an alloyed metal whose main constituents are Co, Cr, Ni and Mo. Both types of implant heads and stems were sterilized with ethylene oxide gas.

Stem. The stem was made of Ti-6Al-4V in the same design as the Charnley type. The titanium stem used in the present study did not interfere with magnetic resonance imaging (MRI) examination. The stem was fixed using second-generation or more recent cement techniques including a distal femur plug and cement injection using the two-thumb method.

Radiographic evaluation

(1) Wear. We measured linear wear, average annual linear wear, volume wear and average annual volume wear using a computer-aided technique. Linear wear was measured on radiographs taken soon after operation, at several time points during the follow-up period (6 months and 1, 3, 5, 7 and 10 years after operation), and at the final examination. Average annual linear wear and average annual volume wear were calculated by dividing the measurement by the number of years of follow-up from the operation to the final examination.

(2) Wear calculation method. Radiographs were scanned and the resulting images were stored

on a personal computer at a resolution of 600 dpi and 256 gray scale. The calculation software Vector Works 10.5 for Macintosh (A&A Co., Ltd., Tokyo, Japan) was used. Three points on the outer edge of the head were selected to determine the center of the head, and image magnification was calculated based on the diameter of the head (22.225 mm). The deviation of the location of the head center was approximately 0.05 mm in this calculation. This value was similar to that of the image resolution, and variation in the diameter of the head had little effect on the adjustment of the magnification of the radiographs.

A template of the socket, which was constructed according to a radiographic image magnification calculation based on the head diameter, was placed on the radiograph against the outer rim of the socket (boundary with the cement) to determine the center of the socket. The coordinates of the socket center and the center of the head were marked. On radiographs taken within 2 weeks after operation, a teardrop line was drawn between the bilateral lower teardrop points, and placed along the horizontal direction of the coordinate system. The adjustment was made with the wire image of the socket rim. According to the method used to calculate the least-squares ellipse from 30 measurement points, the

ellipse was projected on the assumption that the wire formed a circle, which was then converted to the arbitrary coordinate system (Fig. 1). Using these techniques, the measurements were converted to radiographic coordinates for comparison during the follow-up in order to calculate relative movement. The volume wear of the socket was calculated according to the equation given by Kabo *et al.* [20] using the defined linear wear (Fig. 2). The position of the head relative to the edge of the opening was assumed to indicate the direction of wear.

(3) Loosening. Loosening was evaluated on final follow-up radiographs according to Hodgkinson's classification [21] of the socket side, and Harris's classification [22] of the stem side. Hodgkinson's classification defines 5 levels of loosening based on the socket, irrespective of the distribution of gap width around the circumference of the socket: Type 0 corresponds to no demarcation; Type 1, demarcation of the outer one-third only; Type 2, demarcation of the outer and middle thirds; Type 3, complete demarcation; and Type 4, socket migration. Harris defines 3 classes of loosening which require the following evidence on one or more radiographs: 1) definite, migration of the component or cement; 2) probable, a complete radiolucent zone

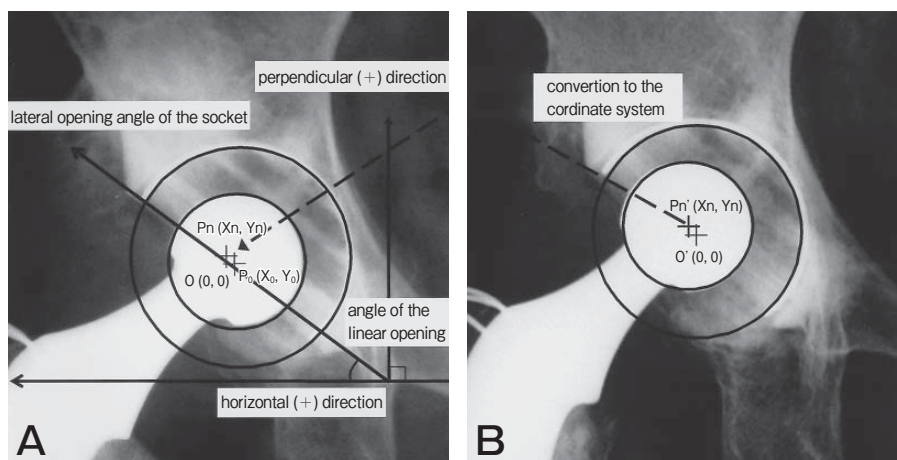


Fig. 1 Method of measurement of linear wear.

A, Anteroposterior (AP) X-ray image taken immediately postoperation; **B**, AP X-ray image at follow-up (6 months and 1, 3, 5, 7 and 10 years after operation, and at the final examination). The measurements were converted to radiographic coordinates immediately after operation (P_o), and the head center (P_n) during the follow-up was plotted on the initial radiographs taken immediately after operation to calculate relative movement. For these calculations, the relative movement of the head center compared with the radiograph taken immediately postoperation (P_o-P_n) was defined as linear wear.

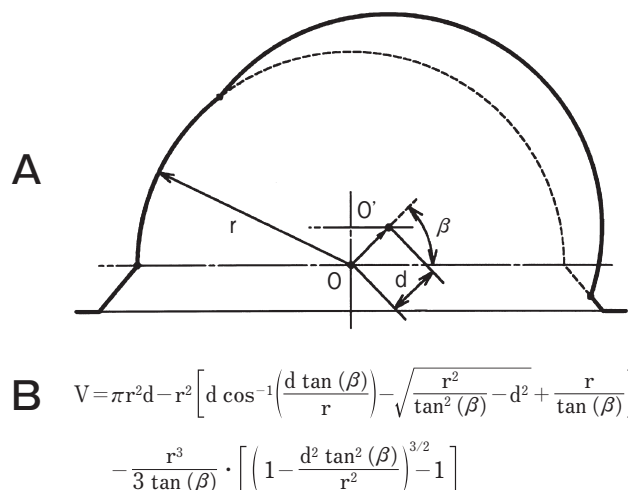


Fig. 2 Method of measurement of volume wear.

A: Volume wear of the socket was calculated according to the equation given by Kabo *et al.* [20]: O, center of the femoral head immediately postoperation; O', center of the femoral head at each follow-up; r , radius of the femoral head; d , deviated distance of the femoral head; β , angle of the direction of linear wear measured from the base on the plane of the socket. **B:** Mathematical equation for volume wear (volumetric material lost). The correct expression for the volume of material lost (V) is given by the equation.

around the cement mantle; and 3) possible loosening, a radiolucent zone of more than 50% but less than 100% of the cement-bone interface. A classification of "none" is assigned in the absence of the above radiographic evidence.

In the present study, 3 observers performed masked assessments of radiographic outcome. The observed agreement, Cohen's kappa coefficient [23] and the weighted kappa coefficient [24] were evaluated to assess the inter- and intra-observer reliability of the classifications.

Clinical evaluation

(1) Harris hip score. The Harris hip score (HHS) was evaluated just before the operation, at specific points during the follow-up period (6 months and 1, 3, 5, 7 and 10 years after operation), and upon final examination. The present study analyzed the association between the HHS and linear wear.

(2) Statistical methods. Linear wear, average annual linear wear, volume wear, average annual volume wear and the HHS at final examination were statistically analyzed with particular attention to

comparison between the zirconia and COP groups. Statistical comparisons between the 2 groups were performed using the non-paired *t*-test with StatView software for Macintosh, version 5.0 (SAS Institute, Cary, NC, USA).

Results

Radiographic evaluation

(1) Wear. Linear wear did not differ significantly between the groups at 6 months after operation (Fig. 3); however, it was significantly greater in the zirconia group (1.1 mm) than in the COP group (0.55 mm) ($p = 0.004$) upon final examination. The average rates of linear wear were 0.093 mm/year in the zirconia group and 0.046 mm/year in the COP group (Table 1). Upon final examination, volume wear and average annual volume wear also differed significantly between the 2 groups (volume wear, $p = 0.027$; average annual volume wear, $p = 0.023$). Volume wear was 310 mm³ and 172 mm³ in the zirconia and COP groups, respectively, and the average annual volume wear was 26 mm³/year and 14 mm³/year. Clinical examples are shown in Figs. 4 and 5.

(2) Loosening. There were 8 Type 0 hips, 4 Type 1 hips, and 1 Type 2 hip in each of the zirconia and COP groups on the socket side, while there were 10 "none" hips and 3 "possible" hips in the zirconia group and 12 "none" hips and 1 "possible" hip in the COP group on the stem side. Upon final examination, there was no remarkable loosening in either group, and no cases had required revision surgery as of 2005.

With regard to inter-observer reliability, the mean observed agreement for Hodgkinson's classification was 81% (range: 71 to 85%) and that for Harris's classification was 84% (range: 74 to 88%). The mean Kappa value was 0.65 (range: 0.50 to 0.73) and the mean weighted kappa value was 0.70 (range: 0.56 to 0.77). The mean agreement in the analysis of intra-observer reliability using Hodgkinson's classification was 93% (range: 88 to 100%) while that using Harris's classification was 94% (range: 87 to 100%). The mean kappa value was 0.83 (range: 0.67 to 1.00) and the mean weighted kappa value was 0.88 (range: 0.75 to 1.00).

Clinical evaluation

(1) HHS. The average HHS was 35.6 and 40.8

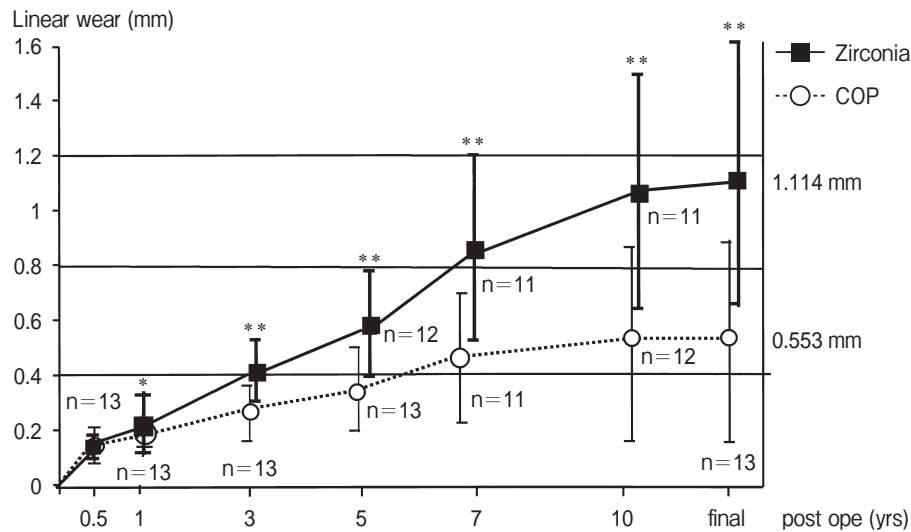


Fig. 3 Graphic comparison of linear wear between the zirconia and COP groups. Sequential measurement of linear wear showed that the zirconia group had statistically greater wear than the COP group at each follow-up after that performed at 6 months after operation. Upon final examination, linear wear was about 2-fold greater in the zirconia group than in the COP group. * $p < 0.05$; ** $p < 0.01$

Table 1 Mean rates of linear wear and volumetric rate of wear at the final examination (The parameters of wear (mean \pm SD))

	Zirconia group	COP group	P-value
Linear wear (mm)	1.1 \pm 0.48	0.55 \pm 0.38	0.004
Annual linear wear (mm/yr)	0.093 \pm 0.035	0.046 \pm 0.032	0.002
Volumetric wear (mm ³)	310 \pm 171	172 \pm 120	0.027
Annual volumetric wear (mm ³ /yr)	26 \pm 13	14 \pm 10	0.023

in the zirconia and COP groups, respectively, just before operation, and 81.6 and 85.2 upon final examination, indicating an improvement in both groups. The HHS did not differ significantly between the 2 groups at any follow-up examination. There was no significant association between HHS and linear wear.

Discussion

Zirconia heads showed superior mechanical strength and toughness to metal heads *in vitro*, and low friction and low wear have been confirmed by hip simulator tests [14–18]. Compared with COP heads, zirconia heads likewise exhibit lower friction torque, and a more than 2-fold bending strength and fracture resistance [17, 18, 25]. These characteristics make it possible to reduce the size of the head to 22 mm, which attenuates friction torque and was expected to provide an advantage in reducing polyethylene wear

[14–16, 21, 26]. Implant heads of 28-mm zirconia have been used in Europe since 1985 [27], and several reports of intermediate- and long-term outcomes of THA with 28-mm zirconia heads have been published [28–31]. However, despite initial expectations, there has been no evidence of low wear.

Some short- and intermediate-term (approximately 5 years) outcomes of THA with 22-mm zirconia heads have been reported to date [32–36]. Usui *et al.* [32] report low rates of 0.38 mm of average linear wear and 0.068 mm/year of average annual linear wear after 5.3 years of postoperative follow-up. Additionally, Takahara *et al.* [33] report an average annual linear wear of 0.022 mm/year after 5.5 years of follow-up. The rates found by Kim *et al.* [34] are even higher at 1.25 mm of average linear wear and 0.21 mm/year of average annual linear wear after 6.4 years of postoperative follow-up. High rates have

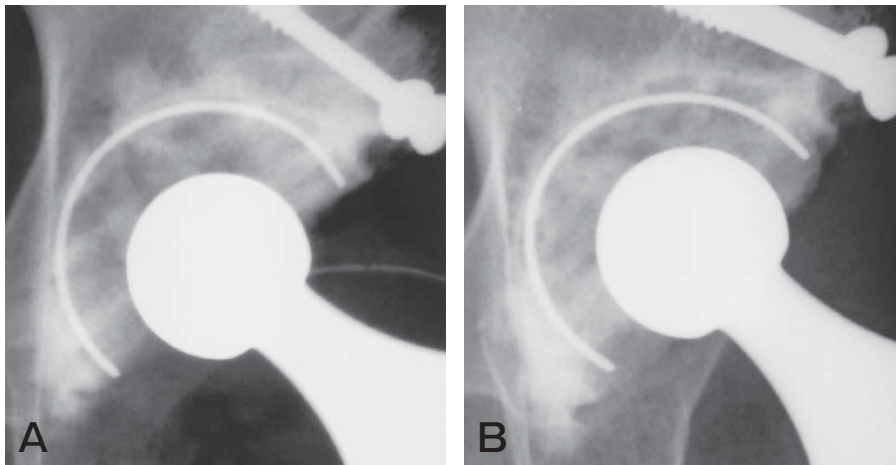


Fig. 4 Radiographs of a 64-year-old woman who underwent THA with a bone graft and zirconia head for the right hip (OA) when she was 53 years old. No loosening was observed in the socket or the stem side at the final examination 11.2 years after operation. **A**, Radiographs of the socket after primary THA with bone graft; these images were taken immediately following operation; **B**, At 11.2 years after primary THA, the head had apparently moved to the upper side and the average annual linear wear was 0.111 mm/year.

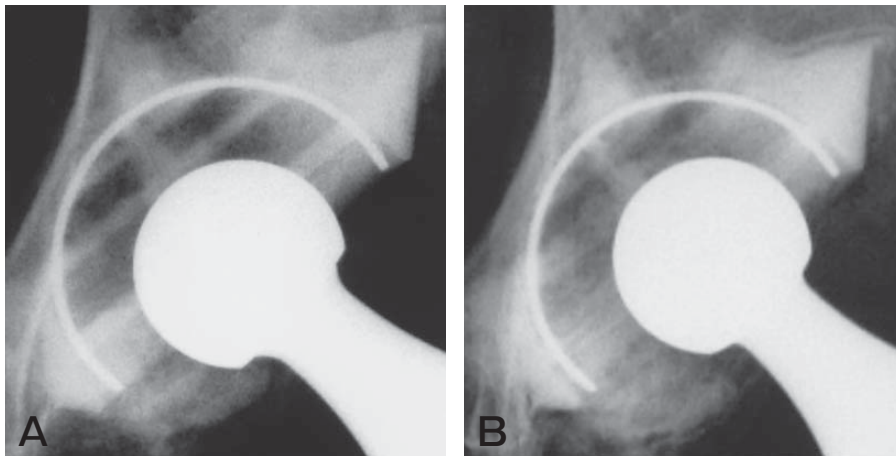


Fig. 5 Radiograph of a 70 year-old female who underwent THA with a zirconia head for the right hip joint (OA) when she was 57 years old. No remarkable loosening was observed in the socket or the stem side at the final examination 13.2 years after operation. **A**, Radiographs of the socket after primary THA; these images were taken immediately after operation; **B**, At 13.2 years after primary THA, the head had moved remarkably to the upper side and the average annual linear wear was 0.139 mm/year.

also been reported by Nishioka *et al.* [35] (0.179 mm/year of average annual linear wear after 2.8 years of postoperative follow-up) and Matsumoto *et al.* [36] (0.17 mm/year average annual linear wear). However, because the studies by Nishioka and Matsumoto examined cases of cementless THA and used different measurement methods, a direct comparison of

their results is difficult. In the present study, the average annual linear wear was found to be 0.093 mm/year in the zirconia group and 0.046 mm/year in the COP group after 11.8 years (range: 10.3–13.2 years) of postoperative follow-up, which was approximately 2-fold higher in the zirconia group than in the COP group (Fig. 3). To the best of our

knowledge, the present study is the first report of wear after THA with 22-mm zirconia heads at more than 10 years after operation.

In the present study, the relative movement of the center of the head soon after operation was defined as linear wear, which included creep penetration. Relative movement is greatly affected by the creep phenomenon of polyethylene soon after operation [37, 38]. Here, linear wear increased even after the early period and at higher levels in the zirconia group than in the COP group. The differences between the groups may be ascribed to differences in the properties of zirconia and COP.

The most probable cause of these differences is the phase transformation of the surface of the zirconia heads. Haraguchi *et al.* [39] discovered this phase transformation of zirconia *in vivo*, and report that phase transformation of the surface of zirconia heads results in wear and increased roughness, eventually leading to loosening. When zirconia is exposed to friction in artificial joints, the contact pressure produces high temperature and causes the crystal phase transformation from stable tetragonal crystals into monoclinic crystals, resulting in surface wear. In a study using a hip simulator, Lu and McKellop [40] found that the surface temperature of alumina heads rose to only 45 °C while that of zirconia heads reached 99 °C, and suggest that high friction heat and low heat conductivity might accelerate the phase transformation of zirconia. Hernigou and Bahrami [28] encouraged the sterilization of zirconia heads with γ -irradiation and the addition of Y_2O_3 (yttrium oxide) to the heads because phase transformation might be caused by autoclave sterilization. The zirconia heads in the present study included Y_2O_3 . More recently, it has been reported that the addition of Ce (cerium) and minimal amounts of alumina can prevent this phase transformation [41]. It is essential to continue the long-term follow-up of changes in wear and loosening in the THA cases with 22-mm zirconia heads examined in the present study. Additionally, it would be interesting to compare performance in the present cases to that in phase transformation-resistant zirconia heads of the same size. The early expectations of lower wear in long-term results of the 22-mm zirconia femoral head for THA were not confirmed in the present study.

Acknowledgments. The authors would like to thank Dr. Hajime Inoue of professor emeritus from Okayama University for valuable discussion. No benefits in any form have been received or will be received from any commercial party related directly to this article.

References

1. Charnley J: The long term results of low friction arthroplasty of the hip performed as a primary intervention. *J Bone Joint Surg Br* (1972) 54: 61-76.
2. Charnley J: Low friction arthroplasty of the hip. Theory and practice, Springer-Verlag, Berlin (1979) pp 20-24.
3. Wroblewski BM: Charnley low-friction arthroplasty of the hip. Long term results. *Clin Orthop Relat Res* (1993) 292: 191-201.
4. Sawai K: 20 year's experience with Charnley low friction arthroplasty: Striving for durability and future prospects. *J Jpn Orthop Assoc* (1997) 71: 684-697 (in Japanese).
5. Harris WH, Schiller AL, Scholler JM, Freiberg RA and Scott R: Extensive localized bone resorption in the femur following total hip replacement. *J Bone Joint Surg Am* (1976) 58: 612-618.
6. Jasty MJ, Floyd WE 3rd, Schiller AL, Goldring SR and Harris WH: Localized osteolysis in stable, non-septic total hip replacement. *J Bone Joint Surg Am* (1986) 68: 912-919.
7. Willert HG: Reaction of the articular capsule to wear products of artificial joint prosthesis. *J Biomed Mater Res* (1977) 11: 157-164.
8. Maloney WJ, Jasty M, Rosenberg A and Harris WH: Bone lysis in well-fixed cemented femoral components. *J Bone Joint Surg Br* (1990) 72: 966-970.
9. Willert HG, Bertram H and Buchhorn GH: Osteolysis in alloarthroplasty of the hip: The role of ultra-high molecular weight polyethylene wear particles. *Clin Orthop Relat Res* (1990) 258: 95-107.
10. Schmalzried TP, Kwong LM, Jasty M, Sedlacek RC, Haire TC, O'Connor DO, Bragdon CR, Kabo JM, Malcolm AJ and Harris WH: The mechanism of loosening cemented acetabular components in total hip arthroplasty. *Clin Orthop Relat Res* (1992) 274: 60-78.
11. Boutin P, Christel P, Dorlot JM, Meunier A, de Roquancourt A, Blankaert D, Herman S, Sedel L and Witvoet J: The use of dense alumina-alumina ceramic combination in total hip replacement. *J Biomed Mater Res* (1988) 22: 1203-1232.
12. Hanakawa S, Inoue H, Yokoyama Y, Koura H, Takagi K, Kataoka Y, Nakane O, Kawakami T and Yamamoto H: Clinical application of the zirconia ceramics endoprosthesis; in Kiso to Rinshou, Kawagishi T ed, 26th ED, Yubunsha, Tokyo (1992) pp 5131-5137 (in Japanese).
13. Araki K: Development of SH type total hip prosthesis. *Okayama Ishi* (1996) 108: 1-12 (in Japanese).
14. Cales B: Zirconia as a sliding material: histologic, laboratory, and clinical data. *Clin Orthop Relat Res* (2000) 379: 94-112.
15. McKellop H, Lu B and Benya P: Friction lubrication and wear of cobalt-chromium, alumina and zirconia hip prostheses compared on a joint simulator. *Trans 38th Orthop Res Soc* (1992) 17: 402.
16. Derbyshire B, Fisher J, Dowson D, Hardaker C and Brummitt K: Comparative study of the wear of UHMWPE with zirconia ceramic and stainless steel femoral heads in artificial hip joints. *Med Eng Phys* (1994) 16: 229-236.
17. Kumar P, Oka M, Ikeuchi K, Shimizu K, Yamamuro T, Okumura H and Kotoura Y: Low wear rate of UHMWPE against zirconia ceramic (Y-PSZ) in comparison to alumina ceramic and SUS 316L alloy. *J Biomed Mater Res* (1991) 25: 813-828.

18. Smith SL and Unsworth A: A comparison between gravimetric and volumetric techniques of wear measurement of UHMWPE acetabular cups against zirconia and cobalt-chromium-molybdenum femoral heads in a hip simulator. *Proc Instn Mech Engrs* (1999) 213: 475-483.
19. Tateishi T and Yunoki H: Research and development of alumina and zirconia artificial hip joint. *Clin Mater* (1993) 12: 219-225.
20. Kabo JM, Gebhard JS, Loren G and Amstutz HC: In vivo wear of polyethylene acetabular component. *J Bone Joint Surg Br* (1993) 75: 254-258.
21. Hodgkinson JP, Shelley P and Wroblewski BM: The correlation between the roentgenographic appearance and operative findings at the bone cement junction of the socket in Charnley low friction arthroplasty. *Clin Orthop Relat Res* (1988) 228: 105-109.
22. Harris WH, McCarthy JC Jr and O'Neill DA: Femoral component loosening using contemporary techniques of femoral cement fixation. *J Bone Joint Surg Am* (1982) 64: 1063-1067.
23. Cohen J: A coefficient of agreement for nominal scales. *Educator and Psychol Measure* (1960) 20: 37-46.
24. Cohen J: Weighted kappa: Nominal scale agreement with provision for scaled disagreement or partial credit. *Psychol Bull* (1968) 70: 213-220.
25. Shimizu K, Oka M, Kumar P, Kotoura Y, Yamamuro T, Makinouchi K and Nakamura T: Time-dependent changes in the mechanical properties of zirconia ceramic. *J Biomed Mater Res* (1993) 27: 729-734.
26. Ma SM, Kabo JM and Amstutz HC: Friction torque in surface and conventional hip replacement. *J Bone Joint Surg Am* (1983) 65: 366-370.
27. Piconi C and Maccauro G: Zirconia as a ceramic biomaterial. *Biomaterials* (1999) 20: 1-25.
28. Hernigou P and Bahrami T: Zirconia and alumina ceramics in comparison with stainless-steel heads. *J Bone Joint Surg Br* (2003) 85: 504-509.
29. Dambreville A, Phillipe M and Ray A: Zirconia ceramics or "by night, all cats are grey". *Maitrise Orthop* (1999) 78: 1-11.
30. Jenny JY, Boeri C, Tavan A and Schlemmer B: Results versus wear couple. *Proc Société Française Chir Orthop Traumatol* (1997): 111-113.
31. Allain J, Mouel SL, Goutallier D and Voisin MC: Poor eight-year survival of cemented zirconia-polyethylene total hip replacements. *J Bone Joint Surg Br* (1999) 81: 835-842.
32. Usui M, Inoue H, Satou T and Mitani S: Total hip arthroplasty using zirconia ceramic head. *The Japanese Society for Replacement Arthroplasty* (1998) 28: 61-62 (in Japanese).
33. Takahara S, Umehara T, Nakano S, Ikeda Y and Kinoshita I: Short-term results of total hip arthroplasty using 22 mm zirconia. *Cent Jpn J Orthop Traumat* (2001) 44: 119-120 (in Japanese).
34. Kim YH, Kim JS and Cho SH: A comparison of polyethylene wear in hips with cobalt-chrome or zirconia heads. *J Bone Joint Surg Br* (2001) 83: 742-750.
35. Nishioka T, Ohkubo H, Yagi S, Mitsuhashi M, Katou Y, Ohba K and Sinkyo M: Wear of UHMWPE insert cementless total hip arthroplasty with 22 mm zirconia head. *The Japanese Society for Replacement Arthroplasty* (2001) 31: 183-184 (in Japanese).
36. Matsumoto K, Okumura H, Morino T, Miyamoto Y, Ishimaru K and Shibata T: Wear of UHMWPE inserts against zirconia ceramic heads in cementless total hip prosthesis. *Journal of Musculoskeletal System* (1999) 12: 1151-1155 (in Japanese).
37. Wroblewski BM, Siney PD, Dowson D and Collins SN: Prospective clinical and joint simulator studies of a new total hip arthroplasty using alumina ceramic heads and cross-linked polyethylene cups. *J Bone Joint Surg Br* (1996) 78: 280-285.
38. Willmann G, Fruh HJ and Pfaff HG: Wear characteristics of sliding pairs of zirconia [Y-TZP] for hip endoprostheses. *Biomaterials* (1996) 17: 2157-2162.
39. Haraguchi K, Sugano N, Nishii T, Miki H, Oka K and Yoshikawa H: Phase transformation of a zirconia ceramic head after total hip arthroplasty. *J Bone Joint Surg Br* (2001) 83: 996-1000.
40. Lu Z and McKellop H: Frictional heating of bearing materials tested in a hip joint wear simulator. *Proc Inst Mech Eng* (1997) 211: 101-108.
41. Yamamuro T: Wear characteristics of various biomaterials used in the bearing mechanism of hip prosthesis. *Kansetsugeka* (2003) 22: 17-21 (in Japanese).