

# Liver Transplantation for the Budd-Chiari Syndrome

GLENN HALFF, M.D., SATORU TODO, M.D., ANDREAS G. TZAKIS, M.D.,  
ROBERT D. GORDON, M.D., and THOMAS E. STARZL, M.D., Ph.D.

A retrospective study was performed that analyzed 23 patients who had an orthotopic liver transplantation for the Budd-Chiari syndrome with end-stage liver disease. Patient follow-up was as long as 14 years. The technical considerations relevant to the Budd-Chiari syndrome were discussed. There have been no serious complications of postoperative anticoagulation. Three patients, all of whom died, had recurrence of the Budd-Chiari syndrome. No other patient has had evidence of recurrent Budd-Chiari syndrome on postoperative liver biopsies. One-, 3-, and 5-year actuarial survival was 68.8%, 44.7%, and 44.7%, respectively. It was concluded that orthotopic liver transplantation is the most effective treatment for patients with the Budd-Chiari syndrome and end-stage liver disease.

**T**HE BUDD-CHIARI SYNDROME is a poorly defined spectrum of disease ranging from a veno occlusive disorder with small vessel occlusion to thrombosis of the major hepatic veins and/or inferior vena cava. A wide variety of underlying disorders and risk factors such as paroxysmal nocturnal hemoglobinuria (PNH), polycythemia vera and other myeloproliferative diseases, tumors, amoebic abscesses, congenital venal caval webs, oral contraceptives, and pregnancy have been reported to cause the syndrome, although most cases of the syndrome have been attributed to cryptogenic causes.<sup>1,2</sup> More recently antithrombin III deficiencies, lupus anticoagulants, and occult myeloproliferative diseases have been suggested to comprise a part of the cryptogenic category.<sup>3-5</sup> Attempts at treatment have included anticoagulation, thrombolysis, portasystemic shunts, and liver transplantation. Although liver transplantation removes the cirrhotic liver disease, it may not cure the underlying thrombotic disorder. Re-

*From the Department of Surgery, University Health Center of Pittsburgh, University of Pittsburgh, and the Veterans Administration Medical Center, Pittsburgh, Pennsylvania*

currence of Budd-Chiari lesions in a transplanted liver has been previously described.<sup>6</sup> In an additional report of 17 patients from Cambridge who had liver transplants for Budd-Chiari, only one patient who was on anticoagulation therapy had a late death that may have been related to the underlying thrombotic disorder.<sup>7</sup> We have described another large group of patients who have had liver transplants for end-stage liver disease secondary to the Budd-Chiari syndrome to discuss the long-term prognosis, to report the results of postoperative anticoagulation therapy, and to describe the technical problems associated with this disease.

## Materials and Methods

### *Patients*

Twenty-three patients were transplanted for the Budd-Chiari syndrome between 1974 and 1988. The transplants performed before 1981 were performed at the University of Colorado Medical Center in Denver, Colorado, and those after 1981 were performed at the Presbyterian-University Hospital in Pittsburgh, Pennsylvania. This represented 1.3% of patients undergoing liver transplantation during this time period. The diagnosis was confirmed by postresection pathologic examination in all patients. The ages at time of transplantation varied from 13 to 48 years, with a median age of 30 years. Three patients were male and 20 were female.

The patients were diagnosed with the Budd-Chiari syndrome an average of 2.3 years (SD  $\pm$  2.7 years) before their transplants. The underlying etiologies (Table 1) included paroxysmal nocturnal hemoglobinuria in 1, polycythemia vera in 3, essential thrombocytosis in 1, and

Supported by Research Grants from the Veterans Administration and Project Grant DK 29961 from the National Institutes of Health, Bethesda, Maryland.

Correspondence and reprint requests to Thomas E. Starzl, M.D., Ph.D., Department of Surgery, 3601 Fifth Avenue, Falk Clinic 4 West, Pittsburgh, PA 15213.

Accepted for publication: April 19, 1989.

TABLE 1. Summary of Patient Data

OLTx No.	At Op.	OLTx	Etiology	Status	Comments
92	22	11/28/74	Polycythemia vera	Alive	No anticoagulation, 2 children post-transplant, liver biopsy 1986 normal
174	20	3/25/80	Oral contraceptive lupus anticoagulant thrombocytosis		Died 6/81 multiple thrombotic postoperative events without anticoagulation, no thrombotic events for 1 year on anticoagulation; recurrent Budd-Chiari when anticoagulation stopped for a procedure
179	21	6/5/80	Oral contraceptive	Alive	No anticoagulation, no thrombotic events
181	16	8/23/80 3/17/82 3/25/82	Unknown	Died 4/82	Retransplanted for chronic rejection, no recurrent Budd-Chiari, died of candidiasis
270	28	12/11/82	Oral contraceptive	Died 1/83	Aspergillus pneumonia
371	31	3/18/84	Unknown	Died 1/87	Died from recurrent Budd-Chiari; one episode of subtherapeutic anticoagulation
385	40	4/20/84	Unknown	Alive	Liver biopsy 4/86 normal
511	22	4/4/85	Oral contraceptive	Alive	Hepatic artery thrombosis 9/85, subtherapeutic anticoagulation, not retransplanted
624	35	10/9/85	Polycythemia vera; oral contraceptive	Died 12/85	Pseudomonas pneumonia
733	38	3/2/86	Polycythemia vera	Died 3/86	Candidiasis
735	36	3/4/86	Unknown	Died 4/86	Cecal perforation
736	13	3/4/86	Cysteamine	Alive	No anticoagulation, no thrombotic events
919	40	10/12/86	Unknown	Alive	Liver biopsy 2/87, normal
1151	30	7/4/87	Unknown	Alive	
1230	35	9/13/87	Essential thrombocytosis	Died 11/87	Pseudomonas pneumonia
1247	25	9/25/87	Oral contraceptive	Died 9/87	Intraoperative death from pulmonary emboli
1281	29	10/31/87 11/1/87 11/5/87	PNH	Died 11/87	OLTx #1: primary nonfunction OLTx #2: thrombosed hepatic artery OLTx #3: thrombosed hepatic and portal vein, Aspergillus in thrombus artery
1478	48	4/12/88	Unknown	Alive	
1487	25	4/19/88	Oral contraceptive	Alive	
1693	21	9/9/88	Oral contraceptive	Alive	
1709	35	9/22/88 9/24/88	Unknown	Alive	OLTx #1: primary nonfunction
1755	42	10/30/88	Unknown	Alive	
1774	32	11/10/88	Lupus anticoagulant	Alive	

OLTx, orthotopic liver transplantation.

PNH, paroxysmal nocturnal hemoglobinuria.

cysteamine administration for the treatment of cystinosis in 1. Seven of the patients had a significant history of oral contraceptive use. Two of these patients had an anti-thrombin III deficiency and two had a protein C deficiency, but each of these had an accompanying deficiency of other coagulation factors that made a decrease in hepatic synthetic function the likely cause. Two patients had associated lupus anticoagulants. The cause in the remaining nine (39%) patients was cryptogenic.

The patient with PNH was diagnosed 10 years before symptoms of end-stage liver disease began. The patients with myeloproliferative disorders were diagnosed 6 years before liver disease became clinically significant in 1, during the work-up for Budd-Chiari syndrome, which was 1 year before operation, in 1, and 7 years after operation in 1 patient who had no known cause at the time of transplantation.

The Budd-Chiari syndrome was initially diagnosed by clinical presentation and a liver biopsy with or without a venogram in 74%, and only by a venogram in 26%. An ultrasound added diagnostic confirmation in 14 of 15 (93%) of the patients in whom it was used.

In more recent patients the venogram was not performed unless there was a diagnostic question after liver biopsy and ultrasound had been performed. Nuclear magnetic resonance imaging has added additional confirmation in all eight patients it was used on during the last 2 years.

Five of the patients had a history of previous portal caval shunts and four had had peritoneal venous shunts placed. Three patients had been treated unsuccessfully with anticoagulants and thrombolysis. Prior thrombotic events had occurred in 3 patients (a deep venous thrombosis in 1, a pulmonary emboli in 2, 1 of whom required thoracotomy and embolectomy, and a sagittal sinus thrombosis in 1). The sagittal sinus thrombosis presented as a severe headache.

Indications for orthotopic liver transplantation included end-stage liver disease with intractable ascites in 52%, recurrent variceal bleeds in 43%, encephalopathy in 47%, spontaneous bacterial peritonitis in 9%, and hepatorenal failure in 34%. One of the patients was intubated in the intensive care unit and was placed on vasopressors immediately before transplantation. The decrease in synthetic function of the liver was not as severe as that in many other causes of end-stage liver disease. The average prothrombin time was 14.9 seconds (SD  $\pm$  0.7), the average bilirubin was 4.3 mg/dL (SD  $\pm$  3.2), and the average albumin was 2.8 am/dL (SD  $\pm$  0.69).

#### Technical Considerations

At operation 30% of the patients were found to have dense adhesions between the liver and diaphragm surrounding the suprahepatic inferior vena cava (IVC). Almost all of the patients had severe portal hypertension.

The dissection was usually very difficult due to the large liver size and typically enlarged caudate lobe. The average liver volume on preoperative Cat scan was 2441 cc (SD  $\pm$  752 cc). Portal bypass was usually instituted early in the operation before most of the liver dissection to decrease the blood loss related to the severe portal hypertension. In some cases the connective tissue around the suprahepatic IVC was so dense that it could not be safely encircled to apply a clamp. In these cases the infrahepatic IVC was ligated and oversewn and the liver was then dissected in a retrograde fashion up to the suprahepatic inferior vena cava, as has been previously described,<sup>8</sup> with the remainder of the operation preceding in the standard fashion.<sup>9</sup> The suprahepatic vena caval cuff was fashioned in some cases by dissecting superiorly up to the right atrium. This was done through the diaphragm (Fig. 1). A thoracic extension was not necessary in any of the patients. The average intraoperative blood loss was 21.8 units (SD  $\pm$  17.6).

#### Anticoagulation

Most patients within the last 5 years were given dextran 40 at 20 cc/hour beginning immediately after operation and continuing for five days. Twenty-five hundred units of subcutaneous heparin BID was begun on postoperative day 1 if the prothrombin time was less than 18 seconds and there was no postoperative bleeding. When the patients' clinical courses were stable with no future plans for invasive procedures, the patients' were converted to Warfarin anticoagulation. This was done an average of 4.6 days (SD  $\pm$  6.2) after operation. Two patients who had early deaths and were never put on Coumadin

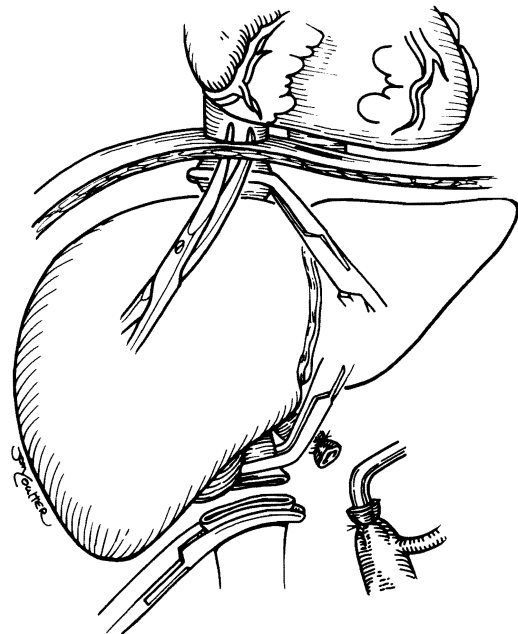


FIG. 1. Suprahepatic venous caval cuff construction by dissection through the diaphragm.

(DuPont, Wilmington, DE) due to a coagulopathy were excluded from this calculation. When an invasive procedure such as a liver biopsy or operation was planned, the patients were converted to heparin anticoagulation with a partial thromboplastin time between 1.5 and 2 times control, which was stopped shortly before the procedure and restarted 6 hours after the procedure if there seemed to be no significant bleeding.

## Results

### *Pathologic Findings In the Native Liver*

Thrombosed main hepatic veins were found in the native liver pathologic specimens in 83% of the patients. Four (17%) also had nonocclusive thrombus in their IVC. One of these four livers had membranous webs in the retrohepatic IVC in addition to thrombosed hepatic veins and cirrhosis. Typical histologic findings were central lobular congestion and necrosis with dilation of the sinusoids, obliteration of central veins, varying degrees of central-to-central and central-to-portal bridging fibrosis, and organized thrombus in branches of the main hepatic veins.

### *Recipient Survival*

Overall 16 of 23 (69.5%) of the patients survived the initial hospitalization, including all six operated on during 1988. One-, 3-, and 5-year actuarial survival was 68.8%, 44.7%, and 44.7%, respectively. This compared with 1-, 3-, and 5-year survivals of 69%, 61%, and 57.6%, respectively, in the age-matched population of all transplanted patients in the Pittsburgh-Denver experience. This difference did not achieve statistical significance using the generalized Wilcoxon (Breslow) Method. The *P* value was 0.50. Using this method, the patients transplanted within the last year were excluded from the calculation. Included were Colorado patients from the precyclosporine era in which 1-year overall survival in adults was approximately 25%.

### *Causes of Death*

Causes of early death included *Pseudomonas*, *Candida*, and *Aspergillus* pneumonias, sepsis from a cecal perforation secondary to an ileus despite colonoscopic decompression, an intraoperative death from a massive pulmonary emboli and, in one patient, a thrombosed hepatic artery and portal vein. Late deaths were caused by systemic candidiasis after a retransplant for chronic rejection in one patient and recurrent Budd-Chiari in two patients.

### *Disease Recurrence*

Recurrence of the Budd-Chiari Syndrome or postoperative thrombotic complications of the hepatic vessels occurred in three patients who were studied at autopsy.

One patient suffered thrombosis of her hepatic artery and portal vein 1 week after operation. The thrombus in both grew aspergilli. This patient, with an underlying etiology of PNH, had thrombosed the hepatic artery in a previous graft four days after operation despite therapeutic levels of anticoagulation. In a second patient, the recurrent Budd-Chiari syndrome occurred acutely after Coumadin was held for a procedure without interim heparin therapy. On autopsy, more than 1 year after transplantation, the liver showed evidence of previous recurrent Budd-Chiari syndrome with fibrous occlusion of multiple central and sublobular hepatic veins, old thrombi in the hepatic artery and left renal vein, as well as recent thrombi in the portal vein, IVC, hepatic veins, and pulmonary artery. This patient had been started on Coumadin after transplantation after she had recurrent postoperative mesenteric thromboses with intestinal infarction, multiple pulmonary emboli, and thrombosis of the superior vena cava. She had remained asymptomatic on Coumadin for more than 1 year despite several subtherapeutic prothrombin times. An initial extensive evaluation did not show an etiology for her hypercoagulability and repeated evaluation just before stopping her Coumadin dosage for the procedure showed a thrombocytosis possibly related to a myeloid stem disease and a lupuslike inhibitor of the coagulation system. This patient has been previously reported.<sup>6</sup>

The third patient, who died from a recurrent Budd-Chiari syndrome, was therapeutically anticoagulated except for one four-day period 4 months before she was admitted with a fever and elevated liver enzymes. After admission she had a rapid clinical deterioration. On autopsy she was found to have severe old and recent intrahepatic hepatic vein thrombosis. The other vessels were patent. She had a cryptogenic etiology for her Budd-Chiari syndrome.

The patient who died of candidiasis after a retransplant for chronic rejection 1.5 years after her first transplant had no evidence of recurrent Budd-Chiari syndrome on pathologic exam of her first allograft.

Biopsy of the liver has been performed in a number of the patients after operation. Patient 93 had a liver biopsy 12 years after operation that showed no evidence of recurrence of Budd-Chiari despite not being treated with anticoagulation. She was diagnosed with polycythemia vera 7 years after transplantation. Patient 385 had a liver biopsy 2 years after operation that showed no evidence of recurrent Budd-Chiari. No other patient has had evidence of recurrent Budd-Chiari in a biopsy. However most of their biopsies were done within 1 month of transplantation.

### *Anticoagulation and Thrombosis*

No patient has had a serious complication caused by anticoagulation. The patients' anticoagulation treatment

has been followed closely either in the liver transplantation clinic or by their local physicians. The prothrombin times have been steadily maintained between 18 and 20 seconds with occasional drops to 15 and peaks to 24 seconds.

Postoperative thrombotic events occurred in the three patients previously mentioned and in two additional patients. One had a splenic vein thrombosis that led to variceal bleeding and was successfully treated with a splenectomy. This was the earliest patient with the longest follow-up, now 14.5 years. Her transplantation was on November 28, 1974.<sup>10</sup> She was not treated with anticoagulation medication. Another patient suffered thrombosis of her hepatic artery 5 months after operation. Her prothrombin time was 14 to 15 seconds at that time. She developed multiple hepatic abscesses and was treated with surgical drainage after refusing retransplantation. She is now doing well 4 years after the hepatic artery thrombosed.

### Discussion

Budd-Chiari is a syndrome of decreased hepatic outflow caused by varying degrees of hepatic venous occlusion. It may present acutely with right upper quadrant pain, ascites, and hepatomegaly, or gradually over a period of months or years, with slowly increasing ascites and/or variceal bleeds. The liver becomes progressively more congested and the majority of untreated patients eventually die from the complications of end-stage liver disease.<sup>11</sup> In the study by Tavill et al.,<sup>12</sup> the mortality rate in 19 patients was 89%, with all 17 deaths occurring within 3.5 years of symptom onset.

Medical treatment with thrombolysis and/or anticoagulation has been successful in a small number of patients. Warren et al.<sup>13</sup> reported successful treatment with streptokinase in one patient with 4 months of follow-up. Greenwood<sup>14</sup> reported an initially successful outcome in one patient treated with urokinase who later rethrombosed and died of a variceal bleed 1.5 years later. Although there have been reports of successful thrombolytic therapy months after symptoms began,<sup>15</sup> thrombolysis usually works better if used soon after thrombosis has occurred. This is not practical in most Budd-Chiari patients because they generally present with a long history of symptoms. In Parker's study<sup>11</sup> only 20% of the patients presented with less than a 1-month history of symptoms. Powell-Jackson et al.<sup>16</sup> described streptokinase or heparin treatment in five patients with a 1-to-6 week history of symptoms. Treatment was successful in only one of the five patients and this patient was found to have cirrhosis on liver biopsy 10 years later. Her Budd-Chiari occurred secondary to trauma and she was treated with heparin. McDermott et al.<sup>17</sup> reported two patients with Budd-Chiari secondary to oral contraceptives who gradually improved with only anticoagulant treatment. Millikan et al.<sup>18</sup> described one patient who experienced recanalization

of his hepatic veins after only diuretic treatment. This patient initially only had partial hepatic vein occlusion.

Surgical alternatives to treatment have included peritoneal venous shunts, portal-systemic shunts, and orthotopic liver transplantation. Peritoneal venous shunts have palliated the symptoms of massive ascites but have been unsuccessful in decreasing the mortality rate from the underlying progressive liver disease. Cameron<sup>19</sup> documented two patients who developed histologic liver fibrosis after being treated with working Leveen shunts, as well as one patient who died of liver failure with a Leveen shunt. Some of these patients survived for several years.

Surgical treatment with portal systemic shunts has been considered the treatment of choice in patients well enough to undergo surgery, although in some studies comparing medical and surgical treatment the groups were acknowledged not to be comparable, with the sickest nonoperable patients receiving medical treatment only. McCarthy<sup>20</sup> reported an 86% mortality rate after a mean survival of 6 months in 14 medically treated patients *versus* a 31% mortality rate in a very mixed group of 16 surgically treated patients with another four of the surgically treated patients having ongoing hepatic disease. In Ahn's study<sup>21</sup> of 30 patients, the 2-year survival rate in the medically treated group was 9%, *versus* 54% in the surgically treated group. This did not achieve statistical significance due to the small numbers, but a subgroup of surgically treated patients in which the IVC obstruction was also treated did have a significantly better survival rate (77% at 2 years). The number of different surgical procedures to treat Budd-Chiari has been reported to be as high as 23<sup>21</sup> and the results reported from different institutions have varied greatly. Inferior vena caval webs are common in the Orient and can often be treated with different types of membranotomy,<sup>22</sup> but this form of Budd-Chiari is very uncommon in the United States and was not represented at all in our series. The most commonly used procedures in the United States are the side-to-side portacaval shunt and the mesocaval shunt, when the IVC and portal vein are patent, and the mesoatrial shunt when the IVC is stenosed or thrombosed, with a patent portal vein. The mesocaval shunt has often been used when the enlarged caudate lobe made portacaval exposure very difficult.

The successful results with these surgical procedures range from 30% to 92%, with the majority having survival rates in the 60%-to-75% range. In Cameron's report<sup>19</sup> of 12 patients operated on for Budd-Chiari, two of five patients with mesocaval shunts did well with some improvement in sinusoidal congestion on postoperative biopsy. Of seven patients given mesoatrial shunts, three of seven were successful, but two of these three thrombosed and had to be redone. Of six patients who had portacaval shunts for Budd-Chiari reported in Milan,<sup>23</sup> two of six died of liver failure and four are alive at 6, 25, 27, and 29 months without encephalopathy. Ahn<sup>21</sup> had estimated

1- and 2-year survival rates with surgical treatment for Budd-Chiari of 61% and 54%. Vons<sup>24</sup> reported nine patients with Budd-Chiari; seven were treated with a mesocaval shunt and two with a portal-atrial shunt. One died and one was lost to follow-up, but the remaining seven are known to be alive without encephalopathy with a median follow-up of 23 months. The operative indications were ascites and right upper-quadrant pain. He reported that three of the patients had resolution of sinusoidal congestion on liver biopsy 1.5 to 2 years after operation.

Mitchell et al.<sup>1</sup> compiled a report of 27 patients in the literature who had side-to-side portacaval shunts. Only 30% survived and improved clinically for more than 1 year. This group included the six patients in Orloff's report, of whom five were alive after 8 months to 7 years without ascites or encephalopathy.<sup>25</sup> Follow-up biopsy in this group showed resolution of sinusoidal congestion with persistence of mild-to-moderate fibrosis. In some patients operated on before fibrosis was present on histologic examination, or in whom the fibrosis was mild, the congestion and sinusoidal dilatation resolved to a large degree on subsequent postshunt biopsies and the patients did well. In 1986 Orloff<sup>26</sup> reported a total of 13 patients treated with portacaval shunts for the Budd-Chiari Syndrome. Ninety-two per cent were alive without ascites with follow-up from 3 to 16 years. None of the patients had encephalopathy and 10 of the 12 were reported to have had return of normal liver function. The degree of preoperative liver disease was not described. Millikan et al.,<sup>18</sup> however, reported on the status of a patient 6 years after portacaval shunt for Budd-Chiari who was doing well but developed fibrosis with nodular regeneration on biopsy. This raises the question of the long-term progression of liver disease in patients who have portosystemic shunts. Five of our 23 (22%) recipients were treatment failures with this approach; their shunts were all widely patent.

In patients with end-stage liver disease manifested by cirrhosis on biopsy and by clinical symptoms, the treatment of choice, in our opinion, is orthotopic liver transplantation. The first successful orthotopic liver transplantation for Budd-Chiari was in 1974.<sup>10</sup> This patient is still alive and well and has had two children since her transplant. Campbell et al.<sup>7</sup> described 17 patients treated with orthotopic liver transplantation for the Budd-Chiari syndrome. They emphasized the importance of postoperative anticoagulant treatment and reported 1- and 3-year survival rates of 88% in the group that was anticoagulated. Their overall 1-year actuarial survival rate was 73%. Three additional patients died between 3 and 5 years after operation, one from liver failure whose portal vein had thrombosed 6 months after operation, one from lymphoma, and one from chronic rejection. Their indications for transplantation included transient encephalopathy in three patients, progressive encephalopathy in one patient, and a progressive downhill course in the rest.

In our own series the 1-, 3-, and 5-year actuarial survival rates were 68.8%, 44.7%, and 44.7%, respectively. This group of patients had many high risk problems, including previous failed shunt surgery, thrombosed portal veins, and severe portal hypertension. Most of the deaths have occurred during the initial hospitalization, most often from pneumonia and other forms of sepsis. There has been a trend of improvement with no deaths during the initial hospitalization in the six patients transplanted for Budd-Chiari during 1988.

There was a second mortality rate peak during the first 2 years after operation from thrombotic complications, but this was seen in the earlier years of the study and was at least partially due to anticoagulant management.

The technical aspects of a liver transplantation for Budd-Chiari have sometimes differed from transplantation for other diseases. Dense adhesions around the suprahepatic IVC often make a retrograde hepatic dissection the safest method and have allowed the dissection to be done without extension of the operation into the chest in all patients. The development of veno-venous bypass in 1983 had a major impact in this subgroup of transplant patients due to the severe portal hypertension that is usually found with Budd-Chiari. For this reason the veno-venous bypass is usually instituted before the liver dissection is undertaken.

Recurrence of the Budd-Chiari syndrome was seen in two resected liver allografts examined 2.8 and 1.2 years after transplant. Both of these patients had at least one documented period of subtherapeutic anticoagulant treatment. One other allograft in a patient adequately anticoagulated was examined after 1.5 years and had no evidence of Budd-Chiari recurrence. In patient 93 the biopsy at 12 years showed no sign of Budd-Chiari recurrence despite no anticoagulant treatment. It is not possible to know if recurrent Budd-Chiari would have been prevented in those patients who developed recurrence if they had been anticoagulated adequately at all times or if the underlying disease would have caused the problem anyway. It is clear that anticoagulant treatment was essential in some of the patients based on the experience of thrombotic episodes occurring with anticoagulant withdrawal, as well as with reported thrombotic episodes without anticoagulation therapy that did not recur with anticoagulation. If the Budd-Chiari syndrome is caused by anti-thrombin-III or protein C deficiency or by another protein made in the liver, then liver transplantation may be curative in this group of patients and they may not require postoperative anticoagulation. A patient with homozygous protein C deficiency who was cured with liver transplantation has been reported from Pittsburgh.<sup>27</sup>

However, until a subgroup is well defined that does not require anticoagulation, all post-transplant Budd-Chiari patients should be therapeutically anticoagulated. We experienced no anticoagulant complications with close fol-

low-up of all patients. Based on the Cambridge experience in which only 1 of 16 anticoagulated patients had a late thrombotic-related death and in our experience in which 3 of 23 patients had recurrent Budd-Chiari syndrome, at least one of which was not adequately anticoagulated, it certainly seems that liver transplantation is indicated for the Budd-Chiari syndrome when associated end-stage liver disease is present. The underlying disease should be treated as much as is possible.

In summary 23 patients in our experience who had liver transplantation for the Budd-Chiari syndrome were reviewed. Orthotopic liver transplantation for the Budd-Chiari syndrome can be done with acceptable morbidity and mortality rates that seem to be improving. In patients with end-stage liver disease and Budd-Chiari it is the treatment of choice. Further long-term follow-up of patients with shunt surgery for Budd-Chiari, as well as with transplantation for Budd-Chiari, will be needed to determine the best treatment for patients with the Budd-Chiari syndrome and intermediate degrees of liver failure.

### References

- Mitchell MC, Boitnoff JK, Kaufman S, et al. Budd-Chiari Syndrome: etiology, diagnosis and management. *Medicine* 1982; 61:199-218.
- Ualla D, Le MG, Poynard T, et al. Risk of hepatic vein thrombosis in relation to recent use of oral contraceptives. *Gastroenterology* 1986; 90:807-811.
- Das M, Carroll SF. Antithrombin III deficiency: an etiology of Budd-Chiari syndrome. *Surgery* 1985; 97:242-245.
- Valla D, Casa deuval N, Lacombe C, et al. Primary myeloproliferative disorders and hepatic vein thrombosis. *Ann Internal Med* 1985; 103:329-334.
- Disney TE, Sullivan SN, Haddad RG, et al. Budd-Chiari syndrome with inferior vena cava obstruction associated with systemic lupus erythematosus. *J Clin Gastroenterol* 1984; 6:253-256.
- Seltman JH, Dekker A, Van Thiel DH, et al. Budd-Chiari syndrome recurring in a transplanted liver. *Gastroenterology* 1983; 84:640-643.
- Campbell DA, Rolles, K, Tamieson N, et al. Hepatic transplantation with perioperative and long term anti-coagulation as treatment for the Budd-Chiari syndrome. *Surg Gynecol Obstet* 1988; 166: 511-518.
- Starzl TE, Porter KA, Putnam CW, et al. Orthotopic liver transplantation in ninety-three patients. *Surg Gynecol Obstet* 1976; 142:487-505.
- Starzl TE, Iwatsuki S, Esquivel CO, et al. Refinements in the surgical technique of liver transplantation. *Semin Liver Dis* 1985; 5:349-356.
- Putnam CW, Porter KA, Weil R III, et al. Liver transplantation for Budd-Chiari syndrome. *JAMA* 1976; 236:1142-1143.
- Parker RGF. Occlusion of the hepatic veins in man. *Medicine* 1959; 38:369-402.
- Tavill AS, Wood EJ, Kreef L, et al. The Budd-Chiari syndrome: correlation between hepatic scintigraphy and the clinical, radiological and pathological findings in 19 cases of hepatic venous outflow obstruction. *Gastroenterology* 1975; 68:509-518.
- Warren RL, Schlant RC, Wenjer NK, Galambos JT. Treatment of Budd-Chiari syndrome with streptokinase. *Gastroenterol* 1972; 62:200.
- Greenwood LH, Yrizarry JM, Hallett JW, Scoville GS. Urokinase treatment of the Budd-Chiari syndrome. *AJR* 1983; 141:1057-1059.
- Malt RA, Dalton JC, Johnson RE, Gurewich V. Side-to-side portacaval shunt versus nonsurgical treatment of Budd-Chiari syndrome. *Am J Surg* 1978; 136:387-389.
- Powell-Jackson PR, Melia W, Canalese J, et al. Budd-Chiari syndrome: Clinical patterns and therapy. *Quarterly J Med* 1982; 201:79-88.
- McDermott WV, Stone MD, Bothe A, Trey C. Budd-Chiari syndrome: historical and clinical review with an analysis of surgical corrective procedures. *Am J Surg* 1984; 147:463-467.
- Millikan WJ, Henderson JM, Sewell CW, et al. Approach to the spectrum of Budd-Chiari syndrome: which patients require portal decompression? *Am J Surg* 1985; 149:167-176.
- Cameron JL, Herlong HF, Sanfey H, et al. The Budd-Chiari syndrome. *Ann Surg* 1983; 198:335-336.
- McCarthy PM, Van Heerden JA, Adson MA, et al. The Budd-Chiari syndrome. *Arch Surg* 1985; 120:657-662.
- Ahn SS, Yellin A, Shenj FC, et al. Selective surgical therapy of the Budd-Chiari syndrome provides superior survivor rates than conservative medical management. *J Vasc Surg* 1987; 5:28-37.
- Hirooka M, Kimura C. Membranous obstruction of the hepatic portion of the inferior vena cava. *Arch Surg* 1970; 100:656-663.
- Pezzuolo G, Spina GP, Opocher E, et al. Portacaval shunt in the treatment of primary Budd-Chiari syndrome. *Surgery* 1985; 98: 319-323.
- Vons C, Smadja C, Bourstyn E, et al. Results of portal systemic shunts in Budd-Chiari syndrome. *Ann Surg* 1986; 203:366-370.
- Orloff MJ, Johansen KH. Treatment of Budd-Chiari syndrome by side-to-side portacaval shunt: experimental and clinical results. *Ann Surg* 1978; 188:494-512.
- Orloff MJ, Girard B. Treatment of Budd-Chiari syndrome by side-to-side portacaval shunt: long term results. *Hepatology* 1986; 6: 1181.
- Casella JF, Bontempo FA, Markel H, et al. Successful treatment of homozygous protein C deficiency by hepatic transplantation. *Lancet* 1988; i:435-437.