



Središnja medicinska knjižnica

Lukšić I., Virag M., Manojlović S., Macan D. (2012) *Salivary gland tumours: 25 years of experience from a single institution in Croatia.* Journal of Cranio-Maxillofacial Surgery, 40 (3). pp. e75-81. ISSN 1010-5182

<http://www.elsevier.com/locate/issn/10105182>

<http://www.sciencedirect.com/science/journal/10105182>

<http://dx.doi.org/10.1016/j.jcms.2011.05.002>

<http://medlib.mef.hr/1596>

University of Zagreb Medical School Repository

<http://medlib.mef.hr/>

SUMMARY

Introduction

The aim of this study was to determine the types, frequency, distribution, and demographic characteristics of salivary gland tumours in a large representative sample.

Patients and Methods

We retrospectively analysed the medical records of 779 patients with tumours of the salivary glands surgically treated from 1985 and 2009 at a single institution.

Results

Of all cases, there were 500 benign and 279 malignant tumours. The average age of patients with benign and malignant salivary gland tumours was 50 and 56 years, respectively. No differences in age and incidence of tumours existed between males and females. The majority of the tumours occurred in the parotid gland (509), followed by the minor salivary glands (212), the submandibular gland (51) and lastly, the sublingual gland (7). Minor salivary gland tumours most frequently occurred on the palate, the pleomorphic adenoma being the most frequent benign tumour type and the adenoid cystic carcinoma being the most prevalent malignant tumour. Tumours of the sublingual gland were very rare, but all were malignant. Malignant tumours were more common in minor salivary glands and the submandibular gland.

Conclusion

This large study of salivary gland tumours in Croatia could improve our understanding of the significant differences in the global distribution of salivary gland tumours which have been reported.

Key words: salivary gland neoplasm, epidemiology, malignant tumour, benign tumour, surgery

INTRODUCTION

"The usual tumour of the salivary gland is a tumour in which the benign variant is less benign than the usual benign tumour and the malignant tumour is less malignant than the usual malignant tumour." (*Ackerman and Del Regato, 1970*). Salivary gland tumours are uncommon and constitute 2 - 6.5% of all head and neck neoplasms (*Auclair et al., 1991; Ellis and Auclair, 1996*). As the incidence of these various tumours is low and their histologic classification is comparatively difficult because of the tumours' morphologic heterogeneity, epidemiologic studies are often based on limited clinical numbers. Reports from several parts of the world have shown differences in the incidence of salivary gland tumours and variations in the frequency of each histologic type have also been reported (*Eveson and Cawson, 1985; Spiro, 1986; Auclair et al., 1991; Wahlberg et al., 2002; Poomsawat et al., 2004; Li et al., 2008; Subhashraj, 2008; Tian et al., 2010*).

The salivary glands are the site of origin of a wide variety of neoplasms. The histopathology of these tumours is said to be the most complex and diverse of any organ in the body (*Subhashraj, 2008*). Unlike parotid and submandibular salivary gland tumours, the majority of tumours arising from the minor salivary glands are malignant (*Spiro, 1986*). Tumours arising from the sublingual gland are as a rule malignant (*Speight and Barrett, 2002*).

Several studies exist involving large series of salivary gland tumours, but this is the first report on a large series of salivary gland tumours in Croatia. The present paper is a retrospective study representing 25 years of experience of salivary gland tumours from a single institution. The aim of this study was to determine the types, frequency, distribution, and demographic characteristics of salivary gland tumours in a large representative sample.

MATERIAL AND METHODS

The medical records of patients with salivary gland tumours who were referred to the Department of Maxillofacial Surgery of the University Hospital Dubrava, the University of Zagreb, School of Medicine, were reviewed retrospectively. The period of review covered 25 years, from January 1, 1985 to December 31, 2009. Patients with primary salivary gland tumours that underwent surgical treatment were included. The exclusion criteria were as follows: patients that did not undergo surgical treatment; patients with metastatic salivary gland tumours, patients who underwent surgical treatment with resection of the salivary gland due to extension of a primary skin cancer into the salivary gland, and patients who underwent resection of the salivary gland as part of an *en bloc* resection for oral or oropharyngeal carcinoma (Commando procedure). All cases were classified according to The World Health Organization's histologic typing of salivary gland tumours classification (*Barnes et al., 2005*). Furthermore, we have reviewed the histopathology of the tumours previously termed "monomorphic adenoma" and "adenocarcinoma of nasal cavity" and reclassified them according to the same WHO Classification. The clinical features, including age, gender, histologic type, and localisation of the tumours were obtained from clinical records. Nominal data were presented with absolute and relative frequencies and distributions were compared using a chi-square test. Numerical data were presented as the median value and data range, i.e., with minimal and maximal values, or when appropriate, using 5th and 95th percentiles, and compared using an ANOVA test with $p < 0.05$ considered significant.

RESULTS

During the 25-year period, 779 patients with salivary gland tumours underwent surgery (392 males [50.3%] and 387 females [49.7%]). The mean age of patients was 52 years (range, 1-93 years; 5th-95th percentile, 21-76 years). The age distribution is presented in Figure 1. The average age of patients with benign tumours was 50 years (5th-95th percentile, 21-75 years) and for patients with malignant tumours, the average age was 56 years (5th-95th percentile, 21-80 years), a significant difference ($F=7.6$, $p<0.001$). There was no difference in age between males and females.

The distribution of salivary gland tumours according to localisation and histology is presented in Table 1. The most common site was the parotid gland (509 cases [65.3%]), followed by the minor salivary glands (212 cases [27.2%]). There were 51 (6.6%) tumours of the submandibular gland and only 7 tumours of the sublingual gland (0.9%). Five hundred sixty-seven (72.8%) tumours occurred in the major salivary glands.

Among tumours of the parotid gland, 5 accessory parotid gland tumours were included (2 pleomorphic adenomas, and one of each of adenoid cystic carcinoma, high-grade mucoepidermoid carcinoma, and myoepithelioma). Accessory parotid tumours comprised 1% of overall parotid tumours (5/509) and had a malignancy rate of 40% (2/5). Two patients were female and three were male, and their ages ranged from 14 to 68 (mean 33 years).

Of all cases, there were 500 (64.2%) benign and 279 (35.8%) malignant tumours. Two-thirds of parotid gland tumours were benign and the rest were malignant (383 vs. 126; Table 1). In the submandibular gland, there were 30 (58.8%) benign and 21 (41.2%) malignant tumours (Table 1). No benign tumours were found among the 7 sublingual gland tumours.

The distribution of tumour histology is presented in Table 2. Among the benign tumours of the parotid gland, pleomorphic adenomas were predominant (66.8%), followed by Warthin's tumour (22.8%). Among malignant tumours of the parotid gland, 32.5% were mucoepidermoid carcinomas,

15.9% adenoid cystic carcinomas, 13.5% carcinoma ex-pleomorphic adenomas and 10.3% acinic cell carcinomas.

Among the benign tumours of the submandibular gland, pleomorphic adenomas were predominant (93.4%). One case of sebaceous adenoma and one case of inverted ductal papilloma were found in the submandibular gland. Of the malignant tumours of the submandibular gland, adenoid cystic carcinoma was the most common histologic type (42.8%), followed by mucoepidermoid carcinoma (23.8%), carcinoma ex-pleomorphic adenoma (14.3%), and adenocarcinoma not otherwise specified, (9.5%). In the sublingual gland all tumours were malignant, 3 were mucoepidermoid carcinomas, 3 were adenoid cystic carcinomas, and one was carcinoma ex-pleomorphic adenoma. Of all minor salivary gland tumours, 87 (41.0%) were benign and 125 (59.0%) were malignant (Table 1). The distribution of 212 minor salivary gland tumours according to histological type and localisation is presented in Tables 2 and 3. The palate was the most frequent site (52.8%), followed by the maxillary sinus (17%), and the buccal mucosa (10.4%; Table 3). Of the benign tumours of the minor salivary gland, 96.7% were pleomorphic adenomas and among the malignant tumours, 49.6% were adenoid cystic carcinomas, followed by mucoepidermoid carcinomas (14.4%), and carcinomas ex-pleomorphic adenomas (9.6%; Table 2).

Tumour histology was dependent on anatomic localisation (Table 3). Benign tumours were frequent in the lip (64.3%), palate (53.6%), and the parapharynx (6 of 9), while malignant tumours were predominant in the maxillary sinus (97.2%), the rest being from rare sites (nasal cavity mucosa, upper and lower gingiva, tongue, ethmoid sinus and epipharynx). All 9 benign tumours of lips were pleomorphic adenomas, 7 of which were in the upper lip. Among the malignant tumours of the lips, 4 of 5 were in the lower lip. The most frequent tumours of the palate were pleomorphic adenomas (53.6%) and adenoid cystic carcinomas (21.4%; Table 3). Adenoid cystic carcinoma was the most common minor salivary gland tumour of the maxillary sinus and pleomorphic adenoma was the most common tumour of the buccal mucosa, lip, and parapharynx.

DISCUSSION

The salivary glands stand out as probably the tissue with the most diverse pathology in the human body. The WHO salivary gland tumour classification lists at least 38 subtypes of epithelial tumours alone, as well as several stromal types (*Barnes et al., 2005*). Regardless of this diversity, salivary gland tumours are rare; and most of them occur in the major glands (75-91%), (*Eveson and Cawson, 1985*). The literature to date reports that the site of the tumours is distributed mainly between the parotid gland (about 80%) and submandibular gland (20%), while very rarely are tumours found in the sublingual gland. Minor salivary gland tumours of the lips, oral cavity, pharynx, larynx, trachea, nasal mucosa, and paranasal sinuses are reported as uncommon (9-23%), (*Eveson and Cawson, 1985*). Malignant tumours of the salivary glands are rare as compared to benign tumours and they are more frequent in the smaller glands. The most frequent malignant tumour of the parotid gland is mucoepidermoid carcinoma (30-50%), followed by adenoid cystic carcinoma (25%), carcinoma ex-pleomorphic adenoma (15%), and acinic cell carcinoma (5%), (*Ito et al., 2005; Rapidis et al., 2007*). This study reviewed 779 salivary gland tumours and showed a predominance of benign tumours (64.2%), similar to most published series (*Batsakis, 1983; Eveson and Cawson, 1985; Wahlberg et al., 2002*). Non-epithelial salivary gland tumours were very rare (Table 2). Also, this study demonstrated that the frequency of malignant tumours increases with age after the third decade and that the peak incidence of all patients with salivary gland tumours is in the sixth and seventh decades. Most studies have shown that salivary gland tumours are more common in females, but some studies have shown predominance in the male group and in the fourth decade of life (*Jansisyant et al., 2002; Vuhahula, 2004; Otoh et al., 2005; Ansari, 2007*). We did not find such a discrepancy in the occurrence of tumours between females and males.

Something which is not specifically addressed in table 2 are five accessory parotid gland tumours which are included among our results for parotid gland tumours. There were 2 pleomorphic

adenomas, 1 adenoid cystic carcinoma, 1 myoepithelioma, and 1 high-grade mucoepidermoid carcinoma. In general, 21-60% of people are estimated to have an accessory parotid gland which is normally not discovered unless a tumour is present, or as an incidental autopsy finding (*Frommer, 1977; Hamano et al., 2004*). Though the accessory parotid gland itself is common, tumours of this small organ are rare (*Klotz and Coniglio, 2000; Hamano et al., 2004*). Accessory parotid tumours have been reported to occur in 1-7.7% of overall parotid tumours, with a malignancy rate of 35-52%, though in some studies no malignancies have been reported (*Kumar et al., 2003; Hamano et al., 2004; Wax et al., 2008*). This incidence is comparatively larger than the standard expectation for malignancy in the parotid gland proper, which is 20-30%. This is in accordance with our findings of 1% of parotid tumours being of accessory parotid gland origin, with a malignancy rate of 40%. A proper statistical analysis of accessory gland tumours is difficult because of their apparent low incidence. *Klotz and Coniglio (2000)* reported only four accessory parotid gland neoplasms over a six year period, all of which were benign pleomorphic adenomas. *Lin et al. (2004)* reported eight cases over a ten year period, three of which had malignant diseases.

In some studies, no cases were found in the sublingual gland confirming the low prevalence in this site (*Ito et al., 2005; Spiro, 1986*). *Eveson and Cawson (1985)* found a proportion of one case of sublingual tumour to 100 parotid tumours. In contrast, *Satko et al. (2000)* reported sublingual tumours in 33 out of 1,021 salivary gland tumours. In this study, tumours of the sublingual gland were found to be very rare, and none of them were benign in our patients. Malignant tumours were more common in the minor salivary glands and the submandibular glands than in the parotid gland. *Eveson and Cawson (1985)* showed that the frequency of malignant tumours increased with age after the third decade, was maximal in the eighth decade, and that malignant tumours were more common in the submandibular and minor salivary glands than in the parotid gland. Of 2410 tumours, they found only seven tumours in the sublingual gland and six of these were malignant.

In this study, an interesting result was that the average age of patients with benign and malignant tumours was 50 and 56 years, respectively. The difference was statistically significant ($F=7.6$, $p<0.001$). No difference in age and incidence rate was found between males and females. Some studies have reported that malignant tumours of the minor salivary glands are more common in males than females (*Chaudhry et al., 1961; Van Heerden and Raubenheimer, 1991*). However; other reports have indicated that this difference was not significant (*Pires et al., 2007*). In the literature, it has been reported that among submandibular gland tumours, 40% are malignant, the most frequent type being adenoid cystic carcinomas (40-50%), and followed by mucoepidermoid carcinomas (20-25%), (*Shaha et al., 1990; Ito et al., 2005; Preuss et al., 2007*). Some authors have reported that mucoepidermoid carcinomas are the most frequent malignancy of the minor salivary glands, accounting for 10-15% of all salivary tumours (*Locati et al., 2002; Triantafyllidou et al., 2006*). In this study, we found a different rate of occurrence of mucoepidermoid carcinoma depending on the localisation (i.e., 7.1% in the palate, 8.3% in the maxillary sinus, and 27.3% in the buccal mucosa). As expected, Warthin's tumour was found in the parotid glands only. Similar findings are observed in most published series (*Ito et al., 2005; Al-Khateeb and Ababneh, 2007*).

In the study by *Spiro* (1986), the parotid gland was the most frequent site, representing 70% of the cases, followed by the minor salivary glands and the submandibular gland with 22% and 8% of tumours, respectively. All large series of salivary gland tumours showed similar results (*Eveson and Cawson, 1985; Ellis and Auclair, 1996; Satko et al., 2000; Ito et al., 2005*). In this study, among the minor salivary gland tumours, 125 (59.0%) were malignant. Some authors in large series of salivary gland tumours showed different results with the incidence of malignant tumours in minor salivary glands ranging from 45-49% (*Eveson and Cawson, 1985; Auclair et al., 1991*). As shown in Table 3, the palate was the most common site for all minor salivary gland tumours, benign and malignant; about one-half of them (52.8%) were located in that region. The palate was followed by the maxillary sinus (17.0%), buccal mucosa (10.4%), lips (6.6%), and parapharynx (4.3%). All 9

benign tumours of the lips were pleomorphic adenomas and 7 were in the upper lip. Among the malignant tumours of the lips 4 of 5 were in the lower lip. The share of benign tumours of the lips is probably still higher, but some of the patients were operated as outpatients and histology for small surgical procedures is often not recorded in the tumour database. The remaining 19 cases were found in the nasal cavity mucosa, upper and lower gingiva, tongue, ethmoid sinus, and epipharynx, and all of those tumours were benign. The most frequent minor salivary gland malignant tumours were adenoid cystic carcinomas (62 cases [49.6 %]), followed by mucoepidermoid carcinomas (18 [14.4 %]), and carcinomas ex-pleomorphic adenomas (12 [9.6%]). There were only four polymorphous low grade adenocarcinomas (PLGA) in a minor salivary gland, all in the palate, and no cases were identified in the major glands. Many authors suggested that PLGA is a relatively common minor salivary gland tumour (*Ellis and Auclair, 1996; Barnes et al., 2005*). In this study, in minor salivary glands, adenoid cystic carcinoma was the most prevalent among all malignant tumours, as both these lesions are histological very similar, and based on the histological review performed by the authors. Pleomorphic adenoma was the most frequent tumour type in small salivary glands, with 84 cases, comprising 96.7 % of all benign minor salivary gland tumours of our series. The distribution of rare tumours of the minor salivary gland according to the histologic type and localisation is presented in Table 3. *Li et al. (2008)* concluded that most series reported in the literature included both major and minor salivary gland tumours, making it difficult to evaluate their actual frequency and site distribution. Very few series have focused solely on intra-oral minor salivary gland tumours (*Toida et al., 2005; Jaber, 2006; Pires et al., 2007; Bianchi et al., 2008*). *Pires et al. (2007)* demonstrated that from a total of 546 minor salivary gland tumours, 55.9% were benign, that the two most common tumours were pleomorphic adenomas (33.2%) and mucoepidermoid carcinomas (22.9%), and the most commonly affected site was the palate (33.2%). *Toida et al. (2005)* in a retrospective study, suggested that the minor salivary gland tumours in Japan may be characterized by a higher incidence of benign tumours, especially of pleomorphic

adenomas, with a more marked tendency for female predominance, a higher incidence of palatal involvement, and a rarer occurrence of PLGA in comparison with those reported in the non-Japanese studies. In the studies from outside of Japan, it has been reported that the most common malignant minor salivary gland tumours are adenoid cystic carcinomas and mucoepidermoid carcinomas. The incidence of adenoid cystic carcinomas and mucoepidermoid carcinomas has been reported to account for 7.7-48% and 6.5-41.3% of all tumours (11.5-51.1% and 16.7-73.6% of malignant tumours), respectively (*Rivera-Bastidas et al., 1996; Lopes et al., 1999; Jansisyanont et al., 2002*). In the largest series of intra-oral minor salivary gland tumours in 2007, *Buchner et al. (2007)* identified 380 tumours, of which 224 (59%) were benign and 156 (41%) were malignant. Of the benign tumours, pleomorphic adenomas were the most common (39.2%), and mucoepidermoid carcinomas were the most common malignant tumours (21.8%), followed by adenocarcinomas (7.1%) and adenoid cystic carcinomas (6.3%). In accordance with the literature, in minor salivary gland tumours, the most common benign tumour was the pleomorphic adenoma, whereas the most common malignant tumour was either the mucoepidermoid carcinoma or adenoid cystic carcinoma (*Eveson and Cawson, 1985; Auclair et al., 1991; Kokemueller et al., 2004; Poomsawat et al., 2004; Bianchi et al., 2008; Subhashraj, 2008; Tian et al., 2010*). Comparing data from different studies, some discrepancies exist in the frequency and distribution of these tumours, which is possibly influenced by race and geographic location of the population in question. However, some reports in the literature are based on results from oral surgery institutions (predominantly minor salivary glands affected), while others are based on results from head and neck surgery (maxillofacial surgery/ENT) institutions, therefore it is expected that the distribution of tumours are not necessarily in concordance. Also, due to the extreme pathological diversity of salivary gland tumours, (and the presence of overlapping morphologies or changes in classifications – for example, PLGA were commonly classified as adenoid cystic carcinoma before 1991) interpretation

of results may depend greatly on pathologists' interpretations (*Seifert and Sobin, 1992; Barnes et al., 2005*).

CONCLUSION

Thus far, this is the largest study of primary salivary gland tumours in Croatia. The demographic data of salivary gland tumours presented herein can be helpful for a better understanding of both clinical and pathological characteristics of salivary gland tumours, including the geographic variations in the frequency and distribution of the disease in comparison with other similar published data.

ACKNOWLEDGEMENTS

The study was supported in part by Project No.108-1080057-0043 of the Croatian Ministry of Science, Education and Sports. The authors would like to thank Mladen Petrovečki, MD, PhD, Professor of Medical Informatics, for his valuable comments and suggestions of data presentation in this paper.

REFERENCES

1. Ackerman LV, Del Regato JA. Cancer – Diagnosis, Treatment and Prognosis. St. Louis: C.V. Mosby Co, 1970.
2. Al-Khateeb TH, Ababneh KT. Salivary tumors in north Jordanians: a descriptive study. *Oral Surg Oral Med Oral Pathol Oral Radiol Endod* 103(5):e53-59, 2007.
3. Ansari MH. Salivary gland tumors in an Iranian population: a retrospective study of 130 cases. *J Oral Maxillofac Surg* 65(11):2187-2194, 2007.
4. Auclair PL, Ellis GL, Gnepp DR, Wenig BM, Janney CG. Salivary gland neoplasms: General considerations. In: Ellis GL, Auclair PL, Gnepp DR, editors. *Surgical Pathology of the Salivary Glands*. Philadelphia: W.B.Saunders Co, 135-164, 1991.
5. Barnes L, Eveson JW, Reichart P, Sidransky D, editors. World Health Organization Classification of Tumours. Pathology and Genetics of Head and Neck Tumours. Lyon: IARC Press, 209-281, 2005.
6. Batsakis JG. Parotid gland and its lymph node as metastatic sites. *Ann Otol Rhinol Laryngol* 92:209, 1983.
7. Bianchi B, Copelli C, Cocchi R, Ferrari S, Pederneschi N, Sesenna E. Adenoid cystic carcinoma of intraoral minor salivary glands. *Oral Oncol* 44(11):1026-1031, 2008.
8. Buchner A, Merrell PW, Carpenter WM. Relative frequency of intra-oral minor salivary gland tumors: a study of 380 cases from northern California and comparison to reports from other parts of the world. *J Oral Pathol Med* 36(4):207-214, 2007.
9. Chaudhry AP, Vickers RA, Gorlin RJ. Intraoral minor salivary gland tumors. An analysis of 1,414 cases. *Oral Surg Oral Med Oral Pathol* 14:1194-1226, 1961.
10. Ellis GL, Auclair PL. Atlas of Tumor Pathology. Tumors of the Salivary Glands. Washington (DC): Armed Forces Institute of Pathology, 468, 1996.

11. Eveson JW, Cawson RA. Salivary gland tumours. A review of 2410 cases with particular reference to histological types, site, age and sex distribution. *J Pathol* 146(1):51-58, 1985.
12. Frommer J. The human accessory parotid gland: its incidence, nature, and significance. *Oral Surg Oral Med Oral Pathol* 43(5):671-676, 1977.
13. Hamano T, Okami K, Sekine M, Odagiri K, Onuki J, Iida M, Takahashi M. A case of accessory parotid gland tumor. *Tokai J Exp Clin Med* 29(3):131-133, 2004.
14. Ito FA, Ito K, Vargas PA, de Almeida OP, Lopes MA. Salivary gland tumors in a Brazilian population: a retrospective study of 496 cases. *Int J Oral Maxillofac Surg* 34(5):533-536, 2005.
15. Jaber MA. Intraoral minor salivary gland tumors: a review of 75 cases in a Libyan population. *Int J Oral Maxillofac Surg* 35(2):150-154, 2006.
16. Jansisyant P, Blanchaert RH Jr, Ord RA. Intraoral minor salivary gland neoplasm: a single institution experience of 80 cases. *Int J Oral Maxillofac Surg* 31(3):257-261, 2002.
17. Klotz DA, Coniglio JU. Prudent management of the mid-cheek mass: revisiting the accessory parotid gland tumor. *Laryngoscope* 110(10 Pt 1):1627-1632, 2000.
18. Kokemueller H, Eckardt A, Brachvogel P, Hausamen JE. Adenoid cystic carcinoma of the head and neck - a 20 years experience. *Int J Oral Maxillofac Surg* 33(1):25-31, 2004.
19. Kumar V, Abbas AK, Fausto N, Mitchell RN, editors. *Robbins Basic Pathology*, 8th Ed. Philadelphia, PA: Saunders/Elsevier, 2007.
20. Li LJ, Li Y, Wen YM, Liu H, Zhao HW. Clinical analysis of salivary gland tumor cases in West China in past 50 years. *Oral Oncol* 44(2):187-192, 2008.
21. Lin DT, Coppit GL, Burkey BB, Nettekville JL. Tumors of the accessory lobe of the parotid gland: a 10-year experience. *Laryngoscope* 114(9):1652-1655, 2004.
22. Locati LD, Quattrone P, Pizzi N, Fior A, Cantù G, Licitra L. Primary high-grade mucoepidermoid carcinoma of the minor salivary glands with cutaneous metastases at diagnosis. *Oral Oncol* 38(4):401-404, 2002.

23. Lopes MA, Kowalski LP, da Cunha Santos G, Paes de Almeida O. A clinicopathologic study of 196 intraoral minor salivary gland tumours. *J Oral Pathol Med* 28(6):264-267, 1999.
24. Otoh EC, Johnson NW, Olasoji H, Danfillo IS, Adeleke OA. Salivary gland neoplasms in Maiduguri, north-eastern Nigeria. *Oral Dis* 11(6):386-391, 2005.
25. Pires FR, Pringle GA, de Almeida OP, Chen SY. Intra-oral minor salivary gland tumors: a clinicopathological study of 546 cases. *Oral Oncol* 43(5):463-470, 2007.
26. Poomsawat S, Punyasingh J, Weerapradist W. A retrospective study of 60 cases of salivary gland tumors in a Thai population. *Quintessence Int* 35(7):577-581, 2004.
27. Preuss SF, Klussmann JP, Wittekindt C, Drebber U, Beutner D, Guntinas-Lichius O. Submandibular gland excision: 15 years of experience. *J Oral Maxillofac Surg* 65(5):953-957, 2007.
28. Rapidis AD, Givalos N, Gakiopoulou H, Stavrianos SD, Faratzis G, Lagogiannis GA, Katsilieris I, Patsouris E. Mucoepidermoid carcinoma of the salivary glands. Review of the literature and clinicopathological analysis of 18 patients. *Oral Oncol* 43(2):130-136, 2007.
29. Rivera-Bastidas H, Ocanto RA, Acevedo AM. Intraoral minor salivary gland tumors: a retrospective study of 62 cases in a Venezuelan population. *J Oral Pathol Med* 25(1):1-4, 1996.
30. Satko I, Stanko P, Longauerová I. Salivary gland tumours treated in the stomatological clinics in Bratislava. *J Craniomaxillofac Surg* 28(1):56-61, 2000.
31. Seifert G, Sobin LH. The World Health Organization's Histological Classification of Salivary Gland Tumors. A commentary on the second edition. *Cancer* 70(2):379-385, 1992.
32. Shaha AR, Webber C, DiMaio T, Jaffe BM. Needle aspiration biopsy in salivary gland lesions. *Am J Surg* 160(4):373-376, 1990.
33. Speight PM, Barrett AW. Salivary gland tumours. *Oral Dis* 8(5):229-240, 2002.
34. Spiro RH. Salivary neoplasms: overview of a 35-year experience with 2,807 patients. *Head Neck Surg* 8(3):177-184, 1986.

35. Subhashraj K. Salivary gland tumors: a single institution experience in India. *Br J Oral Maxillofac Surg* 46(8):635-638, 2008.
36. Tian Z, Li L, Wang L, Hu Y, Li J. Salivary gland neoplasms in oral and maxillofacial regions: a 23-year retrospective study of 6982 cases in an eastern Chinese population. *Int J Oral Maxillofac Surg* 39(3):235-242, 2010.
37. Toida M, Shimokawa K, Makita H, Kato K, Kobayashi A, Kusunoki Y, Hatakeyama D, Fujitsuka H, Yamashita T, Shibata T. Intraoral minor salivary gland tumors: a clinicopathological study of 82 cases. *Int J Oral Maxillofac Surg* 34(5):528-532, 2005.
38. Triantafillidou K, Dimitrakopoulos J, Iordanidis F, Koufogiannis D. Mucoepidermoid carcinoma of minor salivary glands: a clinical study of 16 cases and review of the literature. *Oral Dis* 12(4):364-370, 2006.
39. Van Heerden WF, Raubenheimer EJ. Intraoral salivary gland neoplasms: a retrospective study of seventy cases in an African population. *Oral Surg Oral Med Oral Pathol* 71(5):579-582, 1991.
40. Vuhahula EA. Salivary gland tumors in Uganda: clinical pathological study. *Afr Health Sci* 4(1):15-23, 2004.
41. Wahlberg P, Anderson H, Biörklund A, Möller T, Perfekt R. Carcinoma of the parotid and submandibular glands - a study of survival in 2465 patients. *Oral Oncol* 38(7):706-713, 2002.
42. Wax MK, Gross ND, Andersen PE. Carcinoma of the Salivary Glands. In: Genden EM, Varvares MA, editors. *Head and Neck Cancer: An evidence-based team approach*. Stuttgart: Thieme Medical Publishers, 105-117, 2008.

FIGURES AND TABLES LEGENDS

FIGURE (1) Age distribution according to patients' sex and tumour type

TABLE (1) Benign and malignant salivary gland tumours according to gland localisation, presented with number (N) and table percentages ($\chi^2 = 80.4$, DF = 2, P < 0.001, calculated for parotid glands vs. minor salivary glands vs. both submandibular and sublingual glands as a third group)

TABLE (2) Histologic types of benign and malignant salivary gland tumours, presented with number (N) and column percentages^a

TABLE (3) Localisation and histologic types of 212 minor salivary glands tumours, presented with number (N) and percentages^a

Figure 1. Age distribution according to patients' sex and tumour type

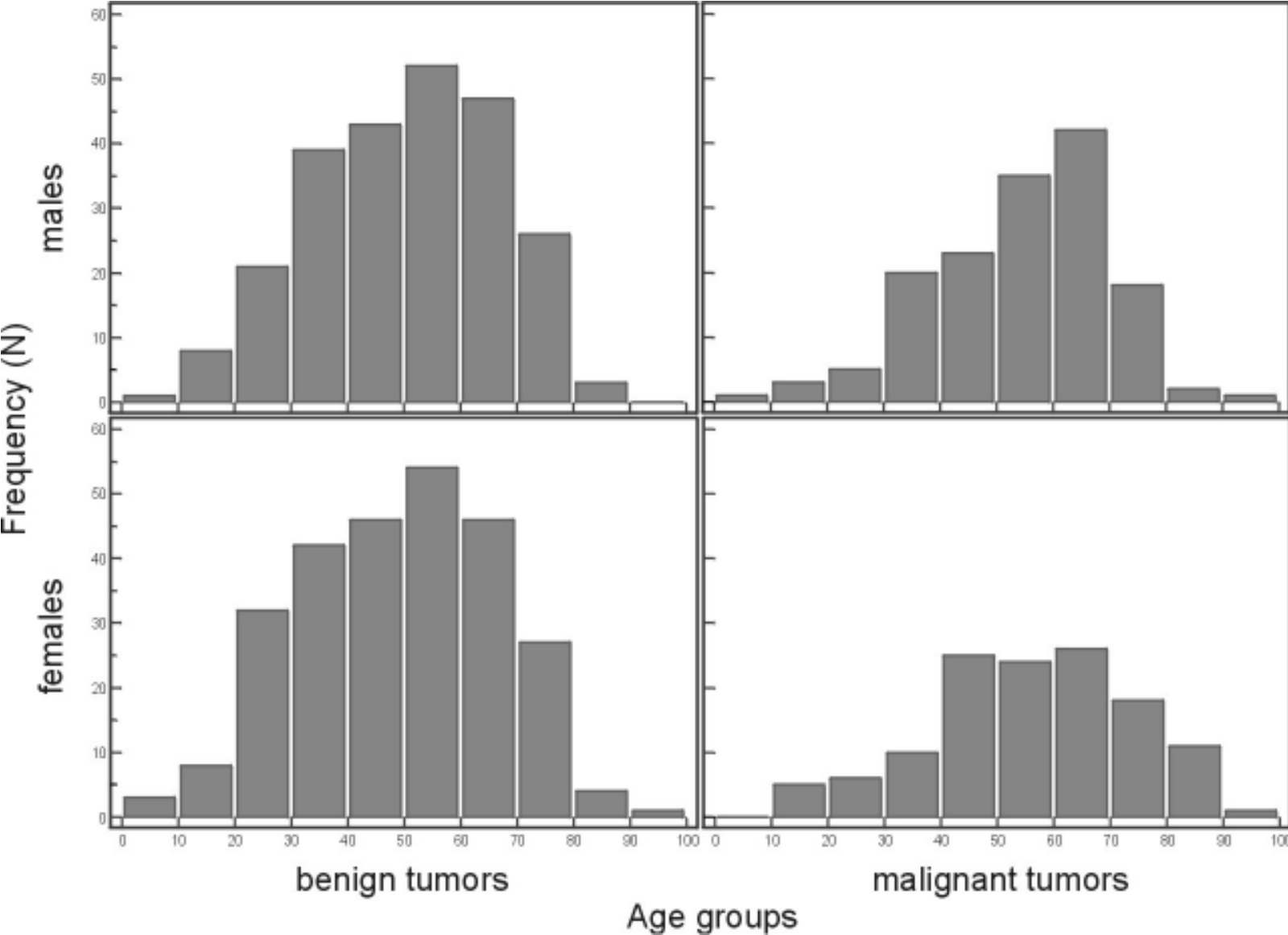


Table 1. Benign and malignant salivary gland tumours according to the gland localisation, presented with number (N) and table percentages ($\chi^2 = 80.4$, DF = 2, P < 0.001, calculated for parotid glands vs. minor salivary glands vs. both submandibular and sublingual glands as a third group)

Localisation	Benign tumours N (%)	Malignant tumours N (%)	Total N (%)
Parotid gland	383 (49.1)	126 (16.2)	509 (65.3)
Minor salivary gland	87 (11.2)	125 (16.0)	212 (27.2)
Submandibular gland	30 (3.9)	21 (2.7)	51 (6.6)
Sublingual gland	0	7 (0.9)	7 (0.9)
Total	500 (64.2)	279 (35.8)	779 (100.0)

Table 2. Histological types of benign and malignant salivary gland tumours, presented with number (N) and column percentages^a

Tumour type	Parotid gland N (%)	Minor glands N (%)	Submandibular gl. N (%)	Sublingual gland N (%)
Benign tumours				
Pleomorphic adenoma	256 (66.8)	84 (96.7)	28 (93.4)	
Warthin's tumour	87 (22.8) ^b			
Myoepithelioma	9 (2.4) ^c	1 (1.1)		
Cystadenoma	7 (1.8)	1 (1.1)		
Basal cell adenoma	6 (1.6)			
Sebaceous adenoma	5 (1.3)	1 (1.1)	1 (3.3)	
Oncocytoma	4 (1.0)			
Sebaceous lymphadenoma	3 (0.8)			
Haemangioma	3 (0.8)			
Lymphangioma	2 (0.5)			
Pseudotumour	1 (0.2)			
Inverted ductal papilloma			1 (3.3)	
All benign tumours	383 (100.0)	87 (100.0)	30 (100.0)	0
Malignant tumours				
Mucoepidermoid carcinoma	41 (32.5) ^d	18 (14.4) ^d	5 (23.8) ^d	3 ^d
Adenoid cystic carcinoma	20 (15.9)	62 (49.6)	9 (42.8)	3
Ca ex-pleomorphic adenoma	17 (13.5)	12 (9.6)	3 (14.3)	1
Acinic cell carcinoma	13 (10.3)	10 (8.0)	1 (4.8)	
Adenocarcinoma (NOS*)	6 (4.7)	9 (7.2)	2 (9.5)	
Basal cell adenocarcinoma	5 (3.9)			
Clear cell carcinoma	4 (3.2)	8 (6.4)		
Myoepithelial carcinoma	3 (2.4)		1 (4.8)	
Salivary duct carcinoma	3 (2.4)			
Lymphoepithelial carcinoma	3 (2.4)			
Squamous cell carcinoma	2 (1.6)			
Oncocytic carcinoma	2 (1.6)			

Sebaceous carcinoma	2 (1.6)			
Malignant fibrous histiocyoma	2 (1.6)			
Haemangiopericytoma	1 (0.8)	2 (1.6)		
Rhabdomyosarcoma	1 (0.8)			
Synovial sarcoma	1 (0.8)			
PLGA**		4 (3.2)		
All malignant tumours	126 (100.0)	125 (100.0)	21 (100.0)	7

Total	509	212	51	7

^aPercentages are presented only for columns with N>10 tumours.

^bFrom those 8 were bilateral.

^cFrom those 2 were bilateral.

^dOut of 41 mucoepidermoid carcinomas in parotid gland, 13 were low-grade, 6 intermediate-grade and 22 high-grade. Out of 5 in submandibular gland, 2 were low-grade, 1 intermediate-grade and 2 high-grade. Out of 3 in sublingual gland, 1 was low-grade and 2 were high-grade. Out of 18 mucoepidermoid carcinomas in minor salivary glands, 2 were low-grade, 4 intermediate-grade and 12 high-grade.

* Not otherwise specified

** Polymorphous low-grade adenocarcinoma

Table 3. Localisation and histological types of 212 minor salivary glands tumours, presented with number (N) and percentages^a

Localisation	Benign tumours N (%)	Malignant tumours N (%)	Total per localisation N (%)	Total for all tumours (%)

Palate				
Pleomorphic adenoma	60 (53.6)			
Adenoid cystic carcinoma		24 (21.4)		
Mucoepidermoid carcinoma		8 (7.1)		
Ca ex-pleomorphic adenoma		7 (6.2)		
Acinic cell carcinoma		5 (4.5)		
PLGA		4 (3.6)		
Clear cell carcinoma		3 (2.7)		
Adenocarcinoma		1 (0.9)		
All	60 (53.6)	52 (46.4)	112 (100.0)	(52.8)

Maxillary sinus				
Adenoid cystic carcinoma		22 (61.0)		
Mucoepidermoid carcinoma		3 (8.3)		
Clear cell carcinoma		3 (8.3)		
Ca ex-pleomorphic adenoma		2 (5.6)		
Acinic cell carcinoma		2 (5.6)		
Adenocarcinoma		2 (5.6)		
Pleomorphic adenoma	1 (2.8)			
Haemangiopericytoma		1 (2.8)		
All	1 (2.8)	35 (97.2)	36 (100.0)	(17.0)

Buccal mucosa				
Pleomorphic adenoma	9 (41.0)			
Cystadenoma	1 (4.5)			
Sebaceous adenoma	1 (4.5)			
Mucoepidermoid carcinoma		6 (27.3)		
Adenoid cystic carcinoma		4 (18.2)		
Acinic cell carcinoma		1 (4.5)		

All	11 (50.0)	11 (50.0)	22 (100.0)	(10.4)
<hr/>				
Lip				
Pleomorphic adenoma	9 (64.3)			
Adenoid cystic carcinoma		2 (14.3)		
Clear cell carcinoma		2 (14.3)		
Adenocarcinoma		1 (7.1)		
All	9 (64.3)	5 (35.7)	14 (100.0)	(6.6)
<hr/>				
Parapharynx				
Pleomorphic adenoma	5			
Myoepithelioma	1			
Ca ex-pleomorphic adenoma		1		
Adenoid cystic carcinoma		1		
Haemangiopericytoma		1		
All	6	3	9	(4.3)
<hr/>				
Nasal cavity mucosa				
Adenoid cystic carcinoma		4		
Adenocarcinoma		3		
All		7	7	(3.3)
<hr/>				
Upper gingiva				
Acinic cell carcinoma		2		
Adenoid cystic carcinoma		1		
Adenocarcinoma		1		
All		4	4	(1.9)
<hr/>				
Lower gingiva				
Ca ex-pleomorphic adenoma		2		
Mucoepidermoid carcinoma		1		
All		3	3	(1.4)
<hr/>				

Tongue				
	Adenoid cystic carcinoma	2		
	All	2	2	(0.9)

Ethmoid sinus				
	Adenoid cystic carcinoma	1		
	Adenocarcinoma	1		
	All	2	2	(0.9)

Epipharynx				
	Adenoid cystic carcinoma	1		
	All	1	1	(0.5)

Total	87	125	212	(100.0)

^aPercentages are presented only for localisation groups with N>10 tumours.