



ISSN:2250-0359

Volume 3 Issue 3 2013

Crouzon's syndrome with adenotonsillitis: conventional surgery in altered anatomy.

Sudhir M Naik¹, Mohan Appaji², Ravishankar S³, Goutham MK⁴, Annapurna SM⁵, N Pinky Devi⁶, Sarika S Naik⁷

¹ Fellow, Department of Head and Neck Oncosurgery, KMIO, Bangalore.

² Professor & Head of Department of ENT, Head and Neck surgery, KVG Medical College, Sullia, Karnataka.

³ Associate Professor, Department of ENT, Head and Neck surgery, KVG Medical College, Sullia, Karnataka.

^{4,5,6} Junior resident, Department of ENT, Head and Neck surgery, KVG Medical College, Sullia, Karnataka.

⁷ Senior resident, Department of Anaesthesia and Critical care, Narayana Hrudayalaya, Bangalore.

Abstract:

Background/Objectives: Crouzon's syndrome is characterized by premature closure of the cranial sutures, midface hypoplasia, orbital deformities & other associated abnormalities. Children with Crouzon syndrome frequently have obstructive sleep apnea due to the underdevelopment of the midface.

Case report: A 12 year old boy of Crouzon's syndrome with chronic adeno-tonsillitis was managed by adeno-tonsillectomy under general anaesthesia by scalpel cautery method. The boy responded well to surgery & the mild sleep disorder disappeared within a week uneventfully.

Conclusion: Sleep disorders in this condition can be treated by improving the airway by selective procedures like midface advancement, mandibular expansion, adeno-tonsillectomy, uvulo-palatopharyngoplasty, anterior tongue reduction & endoscopic tracheal granuloma excision.

Introduction:

Crouzon's syndrome is a rare autosomal dominant skeletal disorder caused by multiple mutations in the fibroblast growth factor receptor 2 (FGFR2) gene.¹ Paternal age older than 35 years is associated with the 60% of all new mutations leading to this condition.¹ It occurs in one of every 25,000 live births & accounts for 5% of cases of craniosynostosis.¹

Crouzon syndrome has 2 variants, the classic variant is caused by a mutation of the fibroblast growth factor receptor gene FGFR-2, located on chromosome 10 & the second variant, notable for the presence of abnormal skin pigmentation called acanthosis nigricans, is the result of a mutation in FGFR-3, located on chromosome 4.² Nucleotide alterations causing amino-acid substitutions at the FGFR2 gene on chromosome 10 lead to the Crouzon phenotype.¹

It is commonly inherited as an autosomal dominant trait, with complete penetrance & variable expressivity,³ but 30 to 60% of cases are sporadic & represent fresh mutations.⁵ It accounts for approximately 4.8% of all cases of craniosynostosis, with the prevalence of approximately 1/25,000 live births worldwide.^{3,4} Clinical findings include brachycephalic craniosynostosis, significant hypertelorism, proptosis, maxillary hypoplasia, beaked nose & possibly, cleft palate. Intracranial anomalies include hydrocephalus, Chiari 1 malformation & hindbrain herniation.¹

It is characterized by premature closure of the cranial sutures, midface hypoplasia, orbital deformities & other abnormalities.³ The diagnosis is based on clinical findings and radiological examination.³ Early recognition and specific therapeutic intervention are essential to guide the growth & development of the craniofacial region.³ Pathology of the ear & cervical spine is common.² Infants with Crouzon's syndrome do not have anomalies of the hands & feet as do infants with Apert's syndrome.²

The abnormal skull shape is usually noted in the newborn period although, occasionally, it may be detected either prenatally or not until later in infancy. The appearance of an infant with Crouzon's syndrome can vary in severity depending on the order and rate of the fusion of the sutures.³ Despite tremendous advances in the establishment of inheritance mode of this condition and its prevention & treatment, it remains a significant cause of morbidity worldwide.³

It is important to be aware of the syndrome so as to impart better care.³ Genetic testing & individual study of each patient with suspected syndrome are essential for early diagnosis and management & to differentiate the condition from other syndromic and non-syndromic craniosynostosis.³

We report a rare case of Crouzon's syndrome in a 12-year-old boy with characteristic features of maxillary hypoplasia, proptosis with minimal cranial cranial deformity & chronic adenotonsillitis.

Case report:

A 12-year-old boy presented with complains of sore throat painful swallowing since a week with similar episodes since 3 year. He incidentally had features suggestive of midfacial hypoplasia with no complains of obstructive sleep disorders.

No difficulty in speech but occasional difficulty in swallowing due to enlarged tonsils was reported. All other family members were normal. At the time of birth father was 37 years and his mother 29 year old & they had a non-consanguineous marriage. History from his parents revealed that his facial features were different from other children of his age. They had noticed the gradual bulging of his eyes after the age of 1 year. Parents complained of chronic mouth breathing and snoring at sleep with chronic denasal speech.

His developmental milestones were normal, but he appeared smaller than other children of his age. At clinical examination cranial vault was regular with no undue prominence. No brachycephaly, flatness of forehead or occiput was seen with normal frontal hairline. No ridging of the skull was seen in regions of coronal, lambdoid sutures & anterior to the vertex. Midface flattening, with maxillary hypoplasia and a relatively large mandible was seen. The upper lip was small compared to the everted lower lip. (fig1,2,3)

Ophthalmologic evaluation revealed shallow orbits, hypertelorism, bilateral proptosis, mild exotropia, no papillary edema or optic atrophy. His nasal bridge was normal with right septal

deviation. His nose was slightly pointed with dorsal hump with normally set ears with normal hearing. No abnormalities seen in hands and feet and dentition.

Oral cavity showed U-shaped dental arches with a high-arched palate with hard and soft palate being normal. There was no evidence of temporomandibular dysfunction. Ortho-pantomographic view confirmed the clinical findings.

A retruded maxilla with a relatively large mandible was seen on x-ray lateral view of the skull. The widely spaced orbits, hypoplastic maxilla and zygoma are due to early fusion of coronal and lambdoid sutures. Cardiovascular, respiratory, and abdominal examinations were normal. Routine hematological and biochemical tests were normal.(fig4,5)

Based on the above clinical and radiological findings and in the absence of hand and feet anomalies, a diagnosis of Crouzon's Syndrome was made. Clinically normal airway within normal cardiac and respiratory functions was seen on pre-anaesthetic examination. He was accepted for adenotonsillectomy in ASA II under general anaesthesia. Initially difficulty was seen in fixing the mouth gag with large tongue and retruded maxilla. The surgery was done in 45 minutes under scalpel cautery method.

Discussion:

Crouzon's syndrome was first described by Octave Crouzon in a mother & son with the characteristic triad of calvarial deformities, facial anomalies & proptosis.⁶ Mutation of the FGFR gene is also responsible for other cranio-synostosis such as Apert's, Pfeiffer's, Jackson-Weiss', and Saether-Chotzen's syndromes.⁷ Rarely, acanthosis nigricans may coexist with Crouzon syndrome & is caused by mutation in the transmembrane region of the FGFR3 gene.⁸ The sporadic cases are postulated to be associated with advanced paternal age & some investigators have found that this mutation is more common in the sperm of older men.⁹

Due to variability of phenotypic expression, some patients exhibit complete phenotypic penetrance, whereas other family members may appear normal & still carry a Crouzon mutation as seen in our patient.¹⁰ Crouzon's syndrome has no racial or sex predilections.¹⁰ The craniosynostosis of sagittal or metopic types are more predominant in boys, while coronal craniosynostosis is more common in girls.¹¹ The condition is usually detected in the first year of life & sometimes congenital forms are seen at birth due to synostosis in the uterus itself.¹¹

Here the coronal sutures usually close first and eventually all cranial sutures close early.¹¹ The coronal and sagittal sutures are most commonly involved.¹¹ As the skull grows in planes perpendicular to the cranial sutures, premature suture closure causes skull growth to cease in the plane perpendicular to the closed suture & to proceed parallel to the suture.¹¹ The skull shape becomes asymmetric, with the shape depending on the sutures involved.¹² The characteristic cranial shapes are brachycephaly (disproportionate shortness of the head), scaphocephaly (boat-shaped head), trigonocephaly (triangle-shaped head) or, in severe disease, cloverleaf skull deformity.¹²

The facial malformations consist of hypoplasia of the maxilla with mandibular prognathism, high-arched palate, bilateral palatal swelling, rarely cleft palate, exaggerated facial angle, nose appears prominent & pointed (beak-like nose), recalling a 'parrot beak' due to short & narrow maxilla.¹³ Conductive hearing loss and ear infections are common due to middle ear deformities.¹¹ Upper airway obstruction may occur due to midfacial hypoplasia & a narrow epipharynx.¹¹ Ocular abnormalities such as bilateral ocular proptosis due to extremely shallow orbits and hypertelorism due to decrease in the growth of sphenozygomatic & sphenotemporal sutures.¹⁴

Optic atrophy is frequently seen in 30 to 80% of patients.¹⁵ Other ocular abnormalities include divergent strabismus, conjunctivitis or exposure keratoconjunctivitis, as well as unexplained loss of visual accuracy.¹⁵ Mental ability and psychomotor development is generally within the normal limits. However, increased intracranial pressure can lead to mental retardation.¹¹ Sometimes headache & convulsions are also seen.¹¹ Thorough clinical, radiological, and genetic analysis is required for early recognition & diagnose of this syndrome.¹¹

X-rays show obliterated sutures, hypoplastic maxilla with shallow orbits, shortened cranial fossa, enlarged hypophyseal cavity & small paranasal sinuses.¹³ Prominent cranial markings of the inner surface of the cranial vault may be seen as multiple radiolucencies appearing as depressions (so called digital impressions) resulting in the hammered silver (beaten metal/copper beaten) appearance.¹³

A copper beaten skull indicating internal remodelling of the calvaria due to an increase in intracranial pressure as a result of premature cranial suture fusion may be seen.¹¹ On spine radiography, abnormal craniocervical junction, butterfly-shaped vertebrae, and fusion of the cervical vertebrae (C2-C3 and C5-C6) may be visible.¹¹ X-ray examination of the metacarpal bones & fingers may reveal slight achondroplasia.¹³ Ventriculomegaly is frequently noticed in central nervous system imaging, but is usually asymptomatic & does not require treatment.¹⁶ Corpus callosum agenesis & optic atrophy are rarely seen on MRI.¹⁶

3-dimensional ultrasonography and MRI aid early detection & diagnosis of fetal malformation.¹⁷ Prenatal diagnostic testing for a known FGFR gene mutation is a reasonable option for couples at risk for having a child with Crouzon syndrome due to germline mosaicism.¹⁷ The syndrome must be differentiated from simple craniosynostosis & other syndromic cranio-synostosis.¹⁸ Once craniosynostosis is seen radiographically, it is important to determine whether it occurred because of abnormal biology of the cranial suture, possibly caused by an FGFR mutation (primary cranio-synostosis).¹⁸

The features of Apert's syndrome are very similar but are characterized by craniosynostosis, midface hypoplasia, and symmetric syndactyly of the hands and feet.¹⁹ Differential diagnosis is also made with the other syndromes associated with features of craniosynostosis such as Pfeiffer's syndrome, Saethre-Chotzen's syndrome, and Jackson-Weiss' syndrome.¹⁹ All these syndromes involve craniofacial abnormalities as well as other abnormalities, including the hands & feet.¹⁹

The management requires a multidisciplinary approach to prevent early fusion of craniofacial suture, thus minimizing ICP & secondary craniofacial deformities.¹⁹ Early release of the synostotic sutures of the skull allows adequate cranial volume for brain growth.¹⁹ Skull reshaping may need to be repeated as the child grows.¹⁹ Depending on the severity of the deformity, midfacial advancement and jaw surgery can be done to provide adequate orbital volume & correcting the occlusion for appropriate function.¹⁹ The prognosis depends on the severity of the malformation and the timing of intervention. Patients usually have a normal lifespan.¹⁹

In a study of 244 children 20% of these children with syndromes with respiratory distress required tracheostomy.²⁰ Craniofacial synostosis patients (Crouzon, Pfeiffer, or Apert syndrome) had the highest rate of tracheotomy (48%), mandibulofacial dysostoses patients (Treacher Collins or Nager syndrome) being the next highest rate (41%) & patients with oculo-auriculo-vertebral sequence were less likely to undergo tracheotomy (22%).²⁰ Children with craniosynostosis rarely required a surgical airway, unless there was marked associated facial dysmorphism (1%).²⁰

The presence of a cleft palate correlated with reduced risk for tracheotomy. We performed adeno-tonsillectomy to improve the snoring & sleep disorder problem. Other procedures done to improve airway are midface advancement, mandibular expansion, uvulopalato-pharyngoplasty, anterior tongue reduction, and endoscopic tracheal granuloma excision.²⁰

Conclusions:

Crouzon syndrome can present with a wide range of clinical features. The affected boy here presents with varying degrees of craniosynostosis, ocular proptosis, hypertelorism, hypoplastic maxilla & chronic tonsillitis. The diagnosis is usually based on clinical & radiographic findings of the craniofacial region.

Molecular genetic testing for mutations in the FGFR2 gene may be useful adjuncts, particularly when prenatal detection in subsequent family members is desired. Sleep disorders in this condition can be treated by improving the airway by selective procedures like midface

advancement , mandibular expansion , adeno-tonsillectomy, uvulo-palatopharyngoplasty, anterior tongue reduction & endoscopic tracheal granuloma excision.

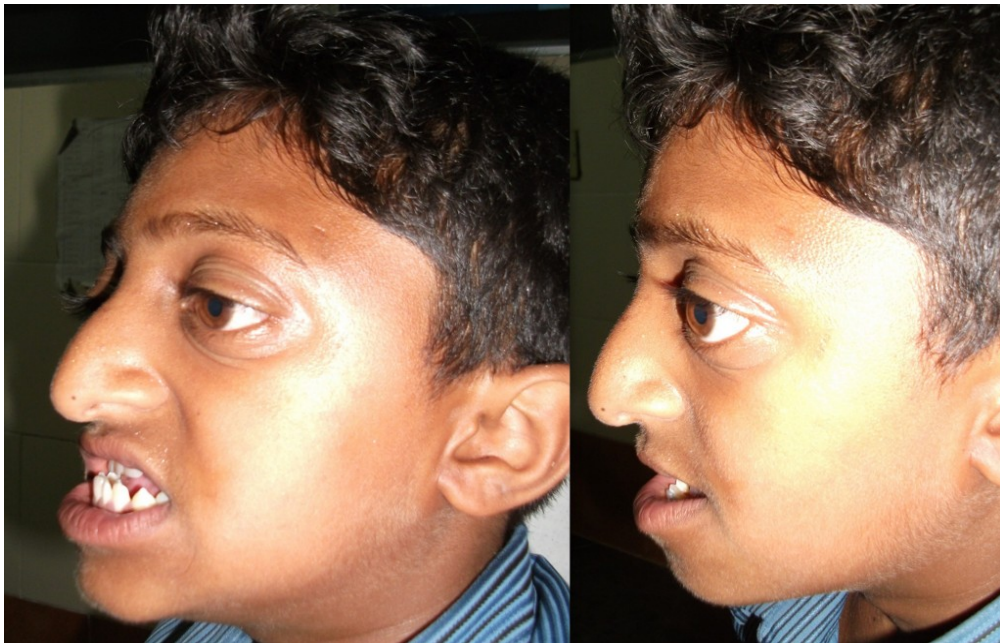

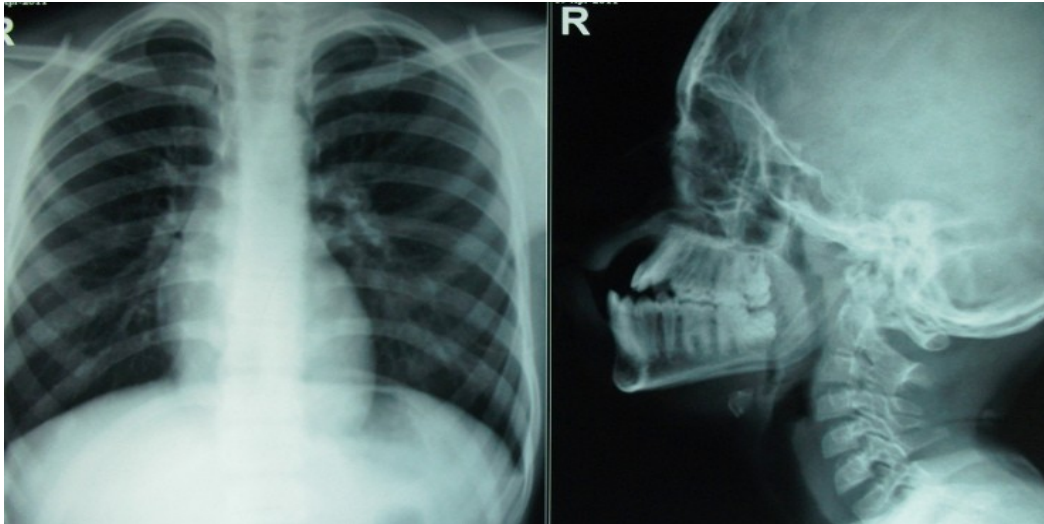
Figure showing Protrusion of the mandible seen with no maxillary prominence

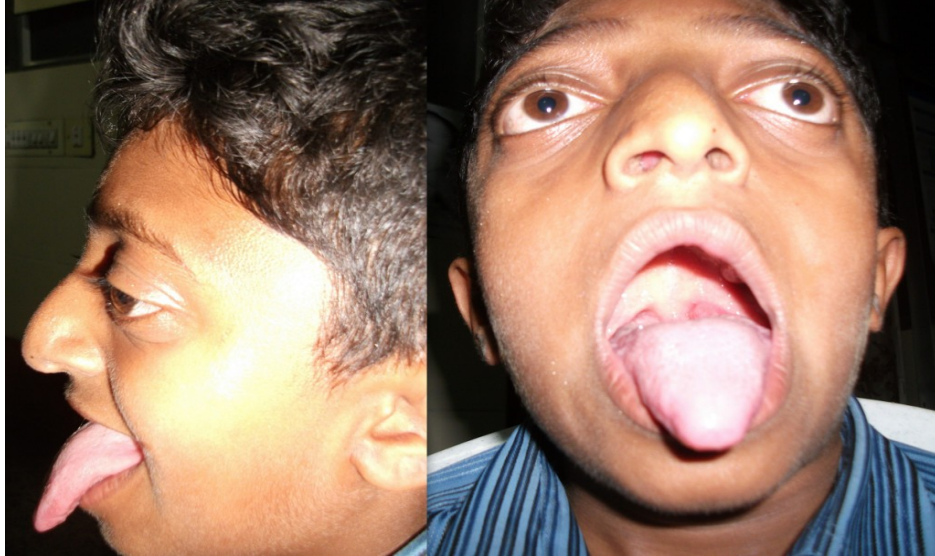
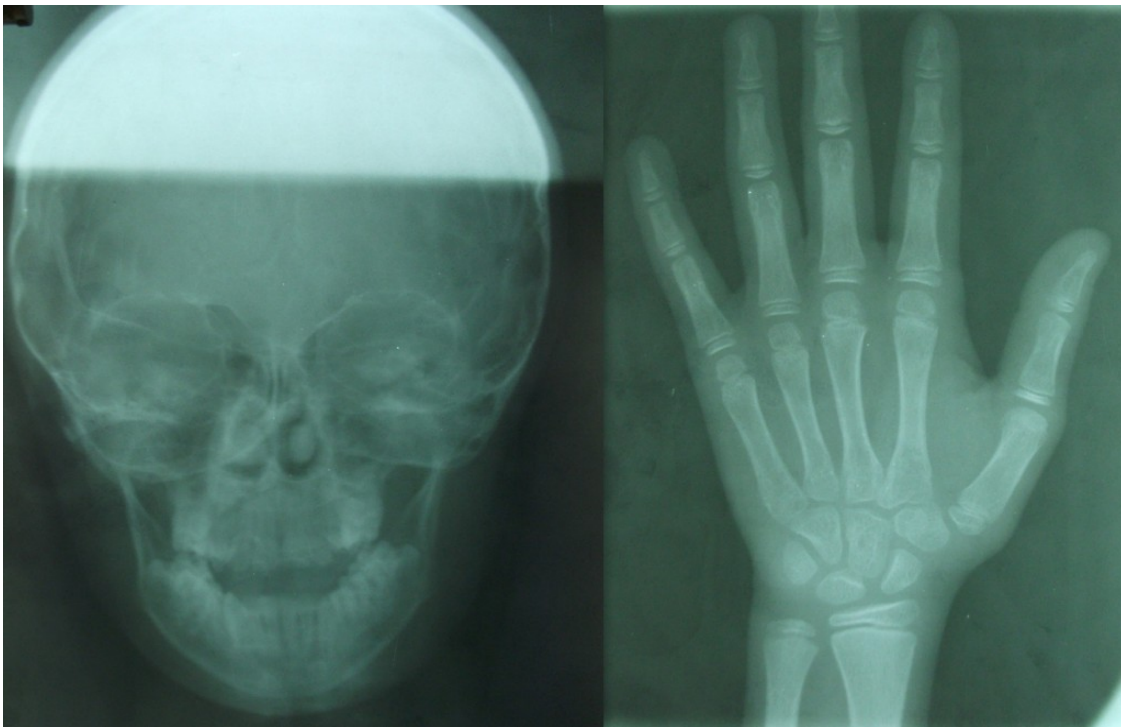
Figure showing No deformity of the palate but a large tongue compared to the mouth cavity.



Normal x-ray of the hand & cranial vault with maxillary hypoplasia seen



Normal chest x-ray with maxillary hypoplasia seen.

References:

1. Corde Mason A, Bentz ML, Losken W. Craniofacial syndromes. In: Zitelli BJ, Davis HW, eds. Atlas of pediatric physical diagnosis. 4th ed. St. Louis: Mosby, 2002:803-17.
2. Reardon W, Winter RM, Rutland P, Pulleyn LJ, Jones BM, Malcolm S. Mutations in the fibroblast growth factor receptor 2 gene cause Crouzon syndrome. *Nat Genet* 1994;8:98-103.
3. Bowling EL, Burstein FD. Crouzon syndrome. *Optometry* 2006;77:217-22.
4. Kaur H, Waraich HS, Sharma CM. Crouzon syndrome: a case report and review of literature. *Indian J Otolaryng Head Neck Surg* 2006;58:381-2.
5. Al-Qattan MM, Phillips JH. Clinical features of Crouzon's syndrome patients with and without a positive family history of Crouzon's syndrome. *J Craniofac Surg* 1997;8:11-3.
6. Crouzon O. Dysostose cranio-faciale hereditaire [in French]. *Bull Mem Soc Hop Paris* 1912;33:545-55.
7. Preising MN, Schindler S, Friedrich M, Wagener H, Golan I, Lorenz B. On the effect of mutations of the fibroblast growth factor receptors as exemplified by three cases of craniosynostoses. *Klin Monbl Augenheilkd* 2003;220:669-81.

8. Meyers GA, Orlow SJ, Munro IR, Przylepa KA, Jabs EW. Fibroblast growth factor receptor 3 (FGFR3) transmembrane mutation in Crouzon syndrome with acanthosis nigricans. *Nat Genet* 1995;11:462-4.
9. Glaser RL, Jiang W, Boyadjiev SA, et al. Paternal origin of FGFR2 mutations in sporadic cases of Crouzon syndrome and Pfeiffer syndrome. *Am J Hum Genet* 2000;66:768-77.
10. Cohen MM Jr. Crouzon syndrome. In: Cohen MM Jr, editor. *Craniosynostosis: diagnosis, evaluation, and management*. 2nd ed. New York, Oxford University Press; 2000: 361.
11. da Silva DL, Palheta Neto FX, Carneiro SG, et al. Crouzon's syndrome: literature review. *Intl Arch Otorhinolaryngol*, São Paulo 2008;12:436-41.
12. Developmental defects of the oral and maxillofacial region. In: Neville BW, Damm DD, Allen CM, Bouquet JE, editors. *Oral and maxillofacial pathology*. 2nd ed. Elsevier Publishers; 2004: 40.
13. Shafer WG, Hine MK, Levy BM. *A text book of oral pathology*. 5th ed. Elsevier Publishers; 2006: 984-6.
14. Ahmed I, Afzal A. Diagnosis and evaluation of Crouzon syndrome. *J Coll Physicians Surg Pak* 2009;19:318-20.
15. Abdallah AM. A severe form of Crouzon's syndrome: clinical and radiological correlation. *Saudi Journal of Ophthalmology* 2003;17:183-5.
16. Gupta AK, Koley S, Choudhary S, Bhake A, Saoji V, Salodkar A. A rare association of acanthosis nigricans with Crouzon syndrome. *Indian J Dermatol Venereol Leprol* 2010;76:65-7.
17. Jaczyńska R, Kutkowska-Kaźmierczak A, Obersztyn E, et al. Prenatal diagnosis of Crouzon syndrome—actual diagnostic possibilities [in Polish]. *Ginekol Pol* 2006;77:138-45.
18. Tsai FJ, Yang CF, Wu JY, Tsai CH, Lee CC. Mutation analysis of Crouzon syndrome and identification of one novel mutation in Taiwanese patients. *Pediatr Int* 2001;43:263-6.
19. Katzen JT, McCarthy JG. Syndromes involving craniosynostosis and midface hypoplasia. *Otolaryngol Clin North Am* 2000;33:1257-84.

20. Sculerati N, Gottlieb MD, Zimble MS, Chibbaro PD, McCarthy JG. Airway management in children with major craniofacial anomalies: Laryngoscope. 1998 Dec;108(12):1806-12.