



## **A CHEESY AFFAIR! - REPORT OF A CASE OF AN EPIDERMOID CYST OF PAROTID**

**Srikamakshi Kothandaraman Balasubramanian Thiagarajan**

**Stanley Medical College**

### **ABSTRACT:**

This article is a report of a case of epidermoid cyst of the deep lobe of the left parotid, being reported and described for the benefit of the readers in view of the rarity of the condition.

### **INTRODUCTION:**

Like how cholesteatoma of the middle ear and mastoid is described, this also seemed to be a case of “skin in the wrong place” ! The incidence of salivary gland tumours is reported to be about 6% of head and neck tumours. Of which 70-90% have been encountered in the parotid gland. Among these, 80% are benign. Similarly while epidermoid cysts under the skin over other locations like face, chest, trunk are quite common place, reports of epidermoid cysts in the parotid gland have been very few and far between, which was the case with our patient. Also, since the mass was present in the deep lobe of the parotid gland, it became necessary to do a total parotidectomy. The responsibility remained however, to ensure disease

clearance without causing any injury to the facial nerve, as it obviously seemed to be a benign mass, and no nerve infiltration would be expected which could justify its damage/sacrifice.

## **CASE REPORT:**

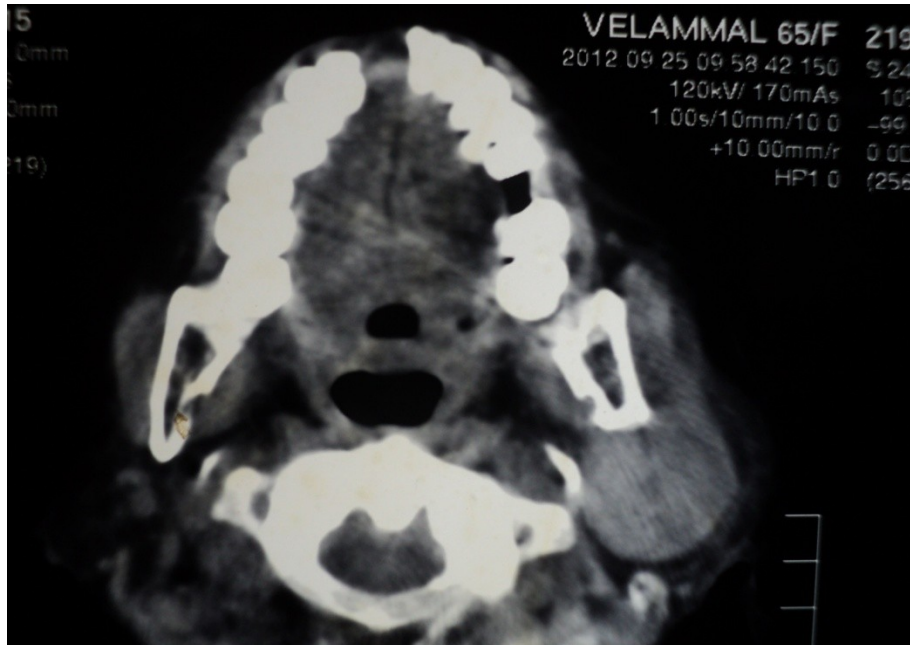
60 Years female patient came with complaints of swelling over angle of left mandible for the last 3 months, which was insidious in onset, progressive in nature and associated with pain over the swelling and fever in the last couple of weeks.

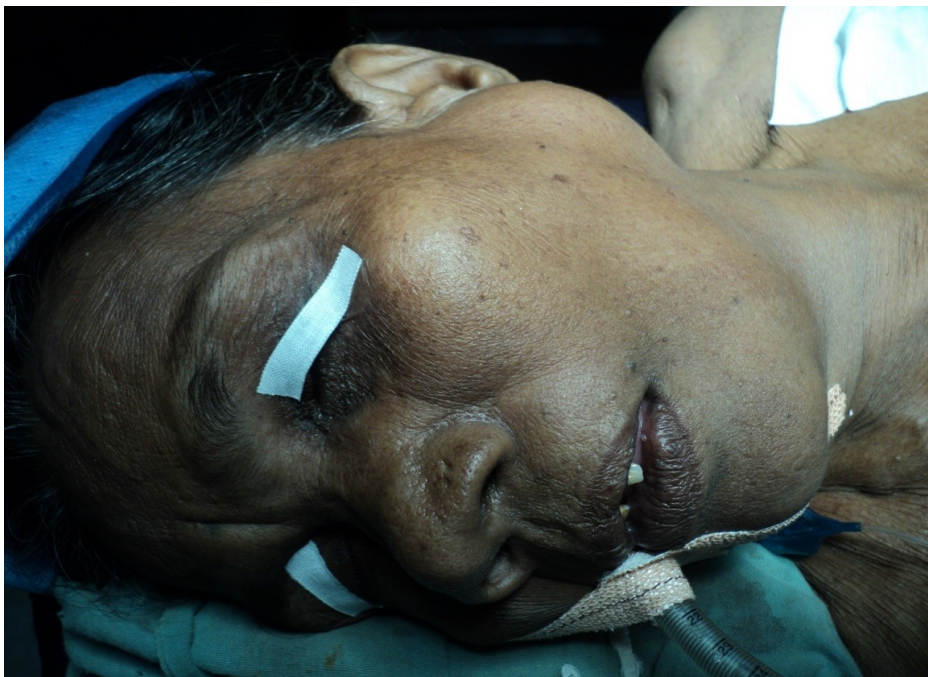

Figure showing the mass involving left parotid gland

The pain over the swelling was associated with left earache. The patient also had trismus. Bilaterally facial nerves were clinically intact. Local examination revealed an approximately 6x5 cm swelling over the region of the left angle of the mandible, located about 2cm below the lobule of the left ear, extending about 2cm anterior to the tragus and upto 2cm behind the left retro-auricular groove. On palpation the mass was found to be non-tender, mobile, and firm

in consistency with well-defined margins. The skin over the swelling was normal and pinchable. The mass was not bidigitally palpable. Multiple bilateral submandibular lymph nodes could be palpated, all of them non-tender, mobile and firm in consistency. No other glandular swellings were palpable. Ultrasonogram of the left parotid revealed a solid mass. CT neck reported a mixed density left parotid mass.



CT scan axial cut showing mass involving the deep lobe of parotid gland

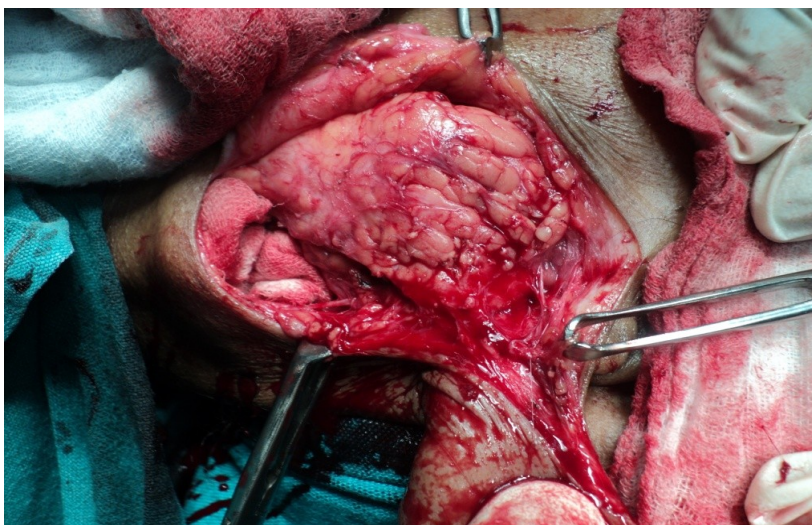
FNAC of the mass was performed 2 times at about a month's interval. The 1<sup>st</sup> one was reported as epidermal cyst. However the 2<sup>nd</sup> one showed up atypical epithelial cells. Hence it was decided to proceed with left total parotidectomy after obtaining fitness for general anaesthesia. Under GA with orotracheal intubation with patient in supine position with head turned to the right side, parts were painted and draped. Infiltration was given all over and around the mass. Lazy 'S' incision was made extending from the left pre-auricular area around the lobule of the left ear upto the mastoid tip and extended downwards upto a neck crease (along the anterior border of the left sternocleidomastoid muscle). Successive layers of skin, subcutaneous tissue and fascia were divided and flaps elevated anteriorly and posteriorly until a fat layer was identified and inferiorly into the neck until the sternocleidomastoid and platysma muscles were identified.



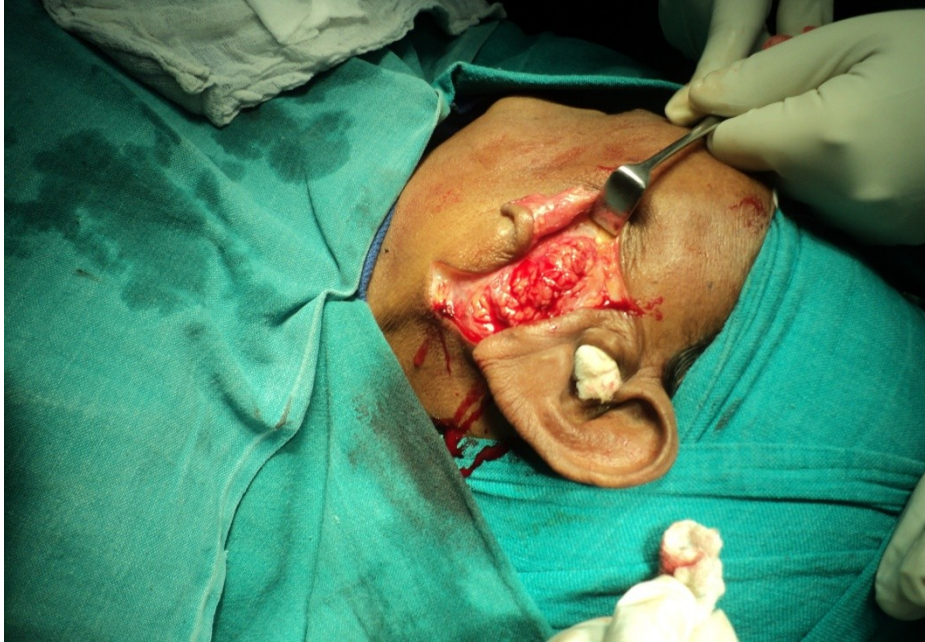

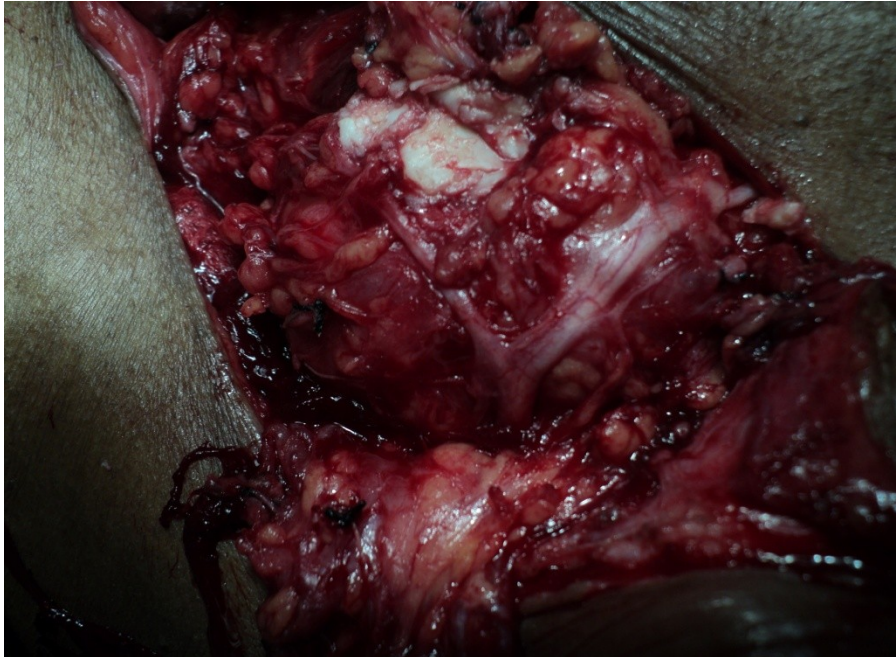
Figure showing the incision made to expose the parotid gland

The greater auricular nerve was identified over the sternocleidomastoid muscle and preserved. The superficial lobe of the left parotid was dissected free from surrounding soft tissues.



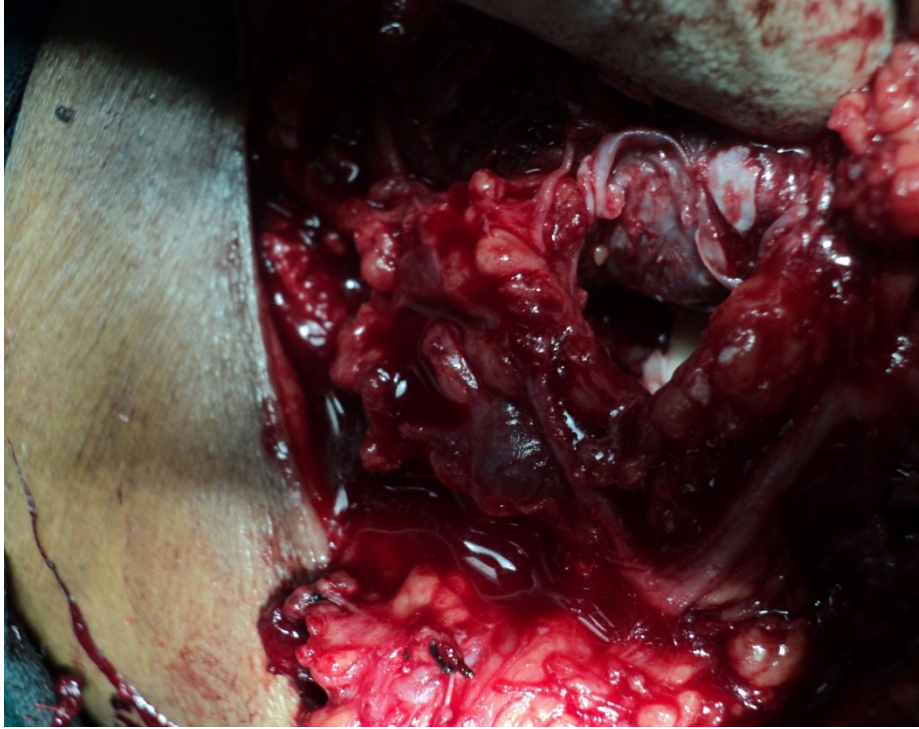
Parotid gland exposed

The external facial vein was located and ligated. The zygomatico-temporal branch of the left facial nerve was the 1<sup>st</sup> branch identified and it was traced to locate the main trunk of the left facial nerve. The other branches(cervical, buccal, marginal mandibular) of the facial nerve were subsequently identified and preserved. We then turned our attention to the deep lobe of the parotid. It was found to be full of pultaceous cheesy debris.



Cheesy material seen in the deep lobe of parotid gland

The cavity that remained after removing the pultaceous debris along with the cyst wall. Some cyst wall and a little cheesy debris that is yet to be removed can be seen.



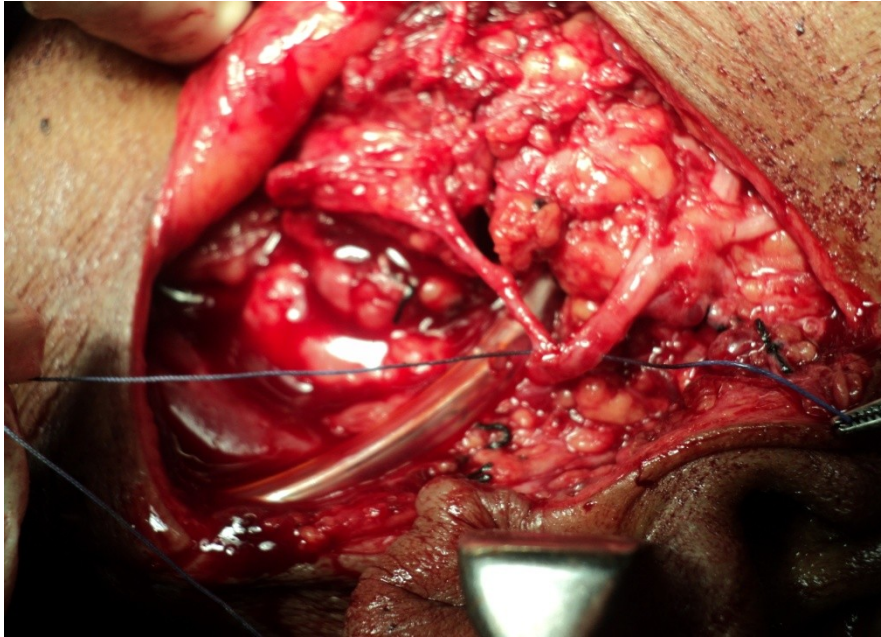
Cavity seen after extrusion of cheesy material

The same was removed completely including the deep lobe of the parotid, taking care not to injure the facial nerve . Some amount of similar cheesy material was found over the retomandibular vein. The same was removed carefully. The parotid tissue overlying the carotid sheath was removed as far as safely feasible. Romovac suction drain was placed into wound and fixed in position. Complete haemostasis was secured.

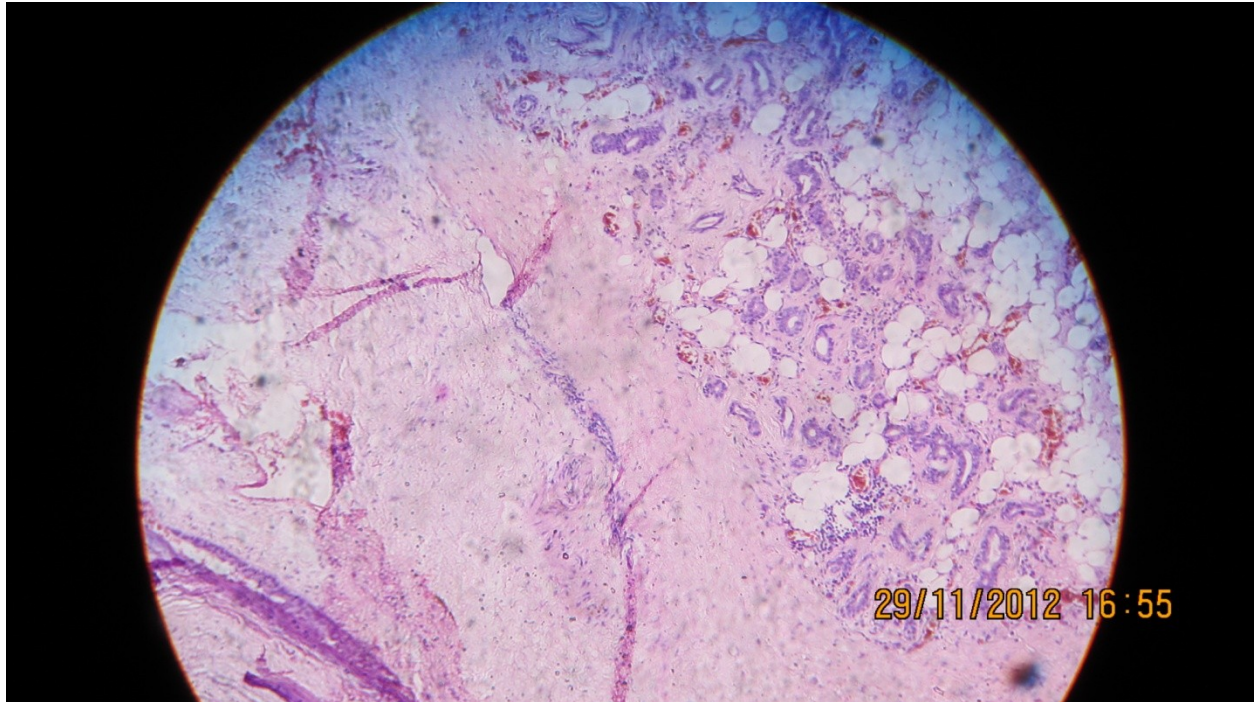
The following is a photo of the main trunk of the left facial nerve and its main branches- temporo-zygomatic, cervico-facial, taken at surgery, delineated in



this foto with a string of vicryl:



The wound was closed in layers with 3-0 vicryl and prolene. Mastoid compression dressing was applied. The patient was extubated and shifted to ward. Post-operatively, b/l facial nerves were clinically intact. The specimen was sent for histo-pathological examination. About 20 ml of blood was collected in the drain on the 1<sup>st</sup> post-operative day. The drain was removed on the 2<sup>nd</sup> post-operative day . Sutures were removed on the seventh post-operative day. The excision biopsy specimen confirmed the diagnosis of epidermoid cyst of parotid.



Histopathology showing epidermal cells within parotid tissue

## **DISCUSSION:**

### **RELEVANT ANATOMY:**

The parotid is the largest of the three **major salivary glands**. It is a compound tubulo-alveolar gland of the serous variety. It weighs from 14 to 28 grams and is approximately triangular in shape. It is bounded posteriorly by the mastoid process, anteriorly by the ramus of the mandible, superiorly by the zygomatic arch and inferiorly by a line connecting the tip of the mastoid process with the angle of the mandible. The gland is enclosed in a fibrous capsule which sends septa into the glandular substance dividing it into lobules. Anatomically, the gland is divided into subdivisions as superficial (or lateral) and deep lobes by a neurovascular bundle. However, Gaughran, in his comprehensive study of parotid anatomy has pointed out that the gland is actually unilobar. The **deep lobe** extends inwards towards the pharyngeal wall and lies in close approximation to the great vessels of the parapharyngeal space. It extends medial to the level of the ramus of the mandible. The presence of the mandibular ramus constricts the gland at this



point. Deep to the deep lobe, minor salivary glands are present in the parapharyngeal space. The bulk of the parotid gland (the 'tail') extends inferiorly between the mandible and the upper part of the sternocleidomastoid muscle. The parotid is easily recognized on CT and MRI in adult patients due to its fatty content. The superficial lobe is seen between the external auditory canal and the angle of the mandible, lateral to the masseter muscle. The deep lobe is located medial to the mandible, extending towards the pre-styloid parapharyngeal space, best seen on axial images. The **parotid (Stenson's) duct** arises from the superficial lobe of the parotid gland, and courses anteriorly over the masseter muscle, a finger breadth below the zygomatic arch and pierces the buccal pad of fat and buccinator muscle to end in the mucosa of the mouth at the level of the second upper molar. The intra-oral course provides a valve-like mechanism preventing reflux. In about 20% of individuals, **Accessory parotid glands** may be present along the parotid duct. They can also get affected by the same disease processes affecting the major gland. A pitfall in CT imaging is the possibility of artefacts in the parotid region due to dental restoration. Although radiological imaging can differentiate between inflammatory pathologies and tumours, they cannot reliably differentiate between benign and malignant tumours of the parotid. The **FNAC** is the preferred diagnostic tool for the same. Histologically, the gland is composed of serous secretory units (acini) which drain into intercalated (terminal) ducts. These converge to form striated (intralobular) ducts, which in turn converge to form secretory (interlobular) ducts found within connective tissue septa. These secretory ducts drain into the main parotid duct. The main trunk of **the facial nerve** enters the parotid gland through its posterior surface and quickly bifurcates into upper and lower divisions. The upper division generally gives rise to the frontal, zygomatic and upper buccal branches while the lower division gives rise to the lower buccal, marginal mandibular and cervical branches. The upper division branches tend to be thicker and more resilient than the lower division ones and take a more superficial course through the gland before exiting. The lower division branches are thinner, more delicate and lie deeper. Neuropraxia more commonly affects the lower division branches following surgical manipulation. The facial nerve and its branches arbitrarily define the superficial and deep lobes of the parotid gland, though there is no histological demarcation between these two lobes. **The retromandibular vein** traverses the parotid gland deep to the facial nerve branches. It is frequently encountered in the inferior part of the gland, where classically, the marginal mandibular and cervical branches cross directly over it. The

terminal branches of the external carotid artery are deep to the retromandibular vein and are less frequently encountered during surgery.

## **RELEVANT PATHOLOGY:**

Cysts are closed sacs that have a lining and contents that are either liquid or semi-solid. An epidermoid cyst is a cyst with an epidermal lining with granular layer, no adnexa and filled with a cheesy material made up of soggy keratin. Epidermoid cysts are usually dome-shaped lumps that occur just beneath the skin usually over the face, neck, chest or trunk. However there are also reports of them occurring in the genital areas. A rare occurrence is an intracranial epidermoid cyst. These are usually congenital lesions (rarely acquired post-surgery or post-traumatic implantation) that account for about 1% of intracranial tumours. Pathologically they are considered to be identical to middle ear congenital cholesteatomas. They are most commonly intradural in location (90%) with 40-50% of these located at the cerebello-pontine angle. Epidermoid cysts are usually painless and grow slowly. However, they can become painful, warm, red and tender if they become infected and start discharging foul smelling cheesy pus. Microscopically, these are cystic lesions lined by cornified epithelium, containing lamellated keratin without calcification. Epidermoid cysts do not enhance on CT. They are usually iso-intense to CSF on MRI, in both T1 and T2 weighted images. There have been very few reports of malignant transformation of an epidermoid cyst into squamous cell carcinoma. Even in those cases, complete excision of the mass sufficed.

## **REVIEW OF LITERATURE:**

Here, specifically, we encountered a case of epidermoid cyst in the deep lobe of the parotid gland. This condition is so rare that only 6 cases have been reported in English literature. In these case reports, the possibility of the extension of cholesteatoma from the mastoid bone to the parotid gland was suggested because most of these patients had a history of previous middle ear/mastoid surgery. In such cases of iatrogenic epidermal cysts following ear surgery, especially those done utilising an endaural incision, it seemed that squamous epithelium gets implanted into the underlying tissue. Hence it has been suggested that if a cystic mass is encountered in the parotid of a patient with a previous history of otologic

surgery, an epidermal origin of the mass must be considered. However our patient had no such past history of ear surgery. There has been a reported case of peripheral facial nerve palsy due to an infected epidermoid cyst. The mode of spread was believed to be through the stylomastoid foramen from the parotid gland into the Fallopian canal with a pathophysiology similar to Bell's palsy. After incision and drainage and adequate antibiotic coverage, the palsy recovered completely after a few weeks. Since there is a tendency to recurrent infections of epidermoid cysts, it is recommended to excise the mass in such a scenario. However, such a situation was not encountered by us with respect to our patient.

## **CONCLUSION:**

This case has been reported simply on account of the uniqueness of the clinical scenario. While epidermoid cysts and parotid masses as separate unrelated entities are quite common, the occurrence of an epidermoid cyst in the deep lobe of parotid gland is very rare. The take home message is to keep this differential in mind also when dealing with parotid masses. Also, considering the benign nature of the mass, it becomes important to take every effort to preserve the facial nerve and undertake a meticulous dissection to ensure that the patient gets complete disease clearance leaving no chances for a recurrence.

## **REFERENCES:**

1. Walshe P et al. Parotid masses in patients with previous ear surgery. *Ir.Med.J.* 2005 Apr; 98(4):110-1.
2. Ozcan KM et al. An epidermal cyst in the parotid gland following ear surgery- a case report. *B-ENT*, 2006; 2(4):193-5.
3. Islam S et al. Parotid dermoid cyst: a rare entity. *J Laryngol Otol* 2009 Feb; 123(2):7.
4. Jas et al. dermoid cyst of the parotid gland: 1<sup>st</sup> pediatric case. *Int. J Pediatric Otorhinolaryngol.* 2010 Feb; 74(2): 216-7.
5. C Naujoks et al. Dermoid cyst of the parotid gland-a case report and brief review of literature. *Internal J of Oral and Maxillofacial Surgery.* Vol 36, Issue 9, pages 861-863; Sep 2007.
6. Manz D et al. Epidermal cyst of the parotid gland. *HNO*, Jan 2011; 59(1):64-7.



7. Omer AUDIN et al. Iatrogenic multiloculated epidermoid parotid cyst following middle ear surgery. KBB ue BBC; Dergisi; 17(3):104-107; 2009.
8. Nicole JM Freling. Imaging of the salivary glands. Scott Brown 7<sup>th</sup> edition, volume 2, chapter 146.
9. Patrick Sheahan and Ashok R Shaha. Salivary gland tumours. Stell and Maran's textbook of head and neck surgery and Oncology. Chapter 37.
10. William W Montgomery, Mack L Cheney, Mark A Varvares. Surgery of the Salivary Glands. Chapter 3.
11. Streppel M, Thomas JP et al. Infected epidermoid cyst as cause of peripheral facial palsy. A case report. Laryngorhinootologie. 2001 Oct; 80(10): 617-9.