



Odontogenic Cysts of upper jaw an analysis

Balasubramanian Thiagarajan Geetha Ramamoorthy

Stanley Medical College

Abstract:

This article attempts to analyze all cases of odontogenic cysts involving upper jaw who presented at Stanley Medical college during 2007 – 2012. This article analyzes the incidence of these cysts during the above said period, age of occurrence, sex predilection if any, clinical presentations and optimal treatment modality. Common complaints with which patients presented to our Institution was swelling over jaw, next was loosening of dentition, paresthesia. 30 patients had presented with cysts involving upper jaw out of which 29 were females and one was male. All these patients underwent surgical removal of the cystic lesion.

Introduction:

International Classification of Diseases (ICD 10) classifies odontogenic cysts involving upper jaw into:

1. Radicular cysts
2. Dentigerous cysts
3. Primordial cyst
4. Lateral periodontal cyst
5. Residual cyst
6. Odontogenic keratocyst
7. Calcifying odontogenic cyst (Gorlin cyst)
8. Globulomaxillary cyst

These cysts are the most common cystic lesions involving maxillofacial area¹. Cystic lesions are common in the jaw bones than anywhere else in the body because of the presence of epithelial cell rests which are commonly left behind following odontogenesis².

Radicular cysts:

Synonyms – Periapical cyst, dental cyst

This is the commonest of all odontogenic cysts³. These cysts could also be considered as an inflammatory cyst originating from Malassez's cell rests⁴. These cysts are caused by root infections involving roots of teeth closely related to maxillary sinus antrum. Infections / inflammation releases toxins at the apex of the tooth leading on to periapical inflammation. They stimulate the Malassez's cell rests which can be found in the periodontal ligament resulting in periapical granuloma which could either be infected or sterile. These cysts could well be sterile if the patient had received antibiotic therapy for dental infections. Radiological differentiation between granuloma and cyst could prove to be rather difficult. The general rule of the thumb being if the lesion is large in radiological imaging then it should be considered as cyst. These cysts increase in size at the expense of the surrounding bony barrier. This expansion is caused by pressure effects and effects of inflammatory enzymes over the surrounding bone. These cysts are lined by stratified squamous epithelium without keratin formation. Evidence of inflammation can be seen along the cyst wall.

Pathophysiology of radicular cysts:

1. Inflammatory mediators / enzymes
2. Bacterial toxins

These two factors have been implicated as the probable factors contributing to Radicular cysts. Among these two Bacterial toxins play a rather vital role. Bacterial endotoxins have been found in large amounts in and around necrotic tooth. These toxins have been shown to be mitogenic⁵. These endotoxins also stimulate expression of cytokines and chemokines⁶. Inflammatory mediators and proinflammatory cytokines released by the host tissue are known to modulate the biochemical activity of epidermal growth factor (EGF) there by causing increased proliferation of cellular elements. They also stimulate local fibroblasts into hyperactivity by expressing Keratinocyte growth factor. The epithelial cell rests of Malassez are usually quiescent / stable cells. These cells are in the G0 phase⁷ of their cell cycle. These cells need to be exposed to extracellular signals to push them into the cell cycle proper. These extracellular signals are collectively known as Mitogen. Experimentally a cell can be identified to be in the proliferative phase by their ability to express markers like PCNA and Ki-67. Ki-67 marker is present in cells belonging to all phases of cell division except G0 phase. Studies reveal increased levels of PCNA and Ki-67 markers in the epithelial lining of radicular cysts⁸.

The actual binding of Mitogen (growth factor) to receptors present on the cell membrane surface initiates a series of intracellular reactions pushing the cell into mitotic phase.

Probable growth factors (Mitogen) involved in the pathogenesis of radicular cysts include:

1. EFG & KGF – released by stromal fibroblast
2. TGF- α – released by macrophages and lymphocytes
3. IGF (Insulin like growth factor) – released by stromal fibroblasts

In the pathophysiology of formation of radicular cysts mediators released by inflammatory cells

(macrophages and lymphocytes) play a vital role⁹.

Enlargement of radicular cyst:

This invariably occurs at a rather slow pace. Various factors influence the rate of expansion. These factors include:

1. Mural growth
2. Hydrostatic enlargement
3. Bone resorbing factor¹⁰

Rapid expansion of radicular cyst is associated with increase in hydrostatic pressure within the cyst. The hydrostatic pressure within the cyst is higher than that of capillary pressure, causing fluid to enter from the capillaries into the cyst cavity. This high hydrostatic pressure within the cyst has been attributed due to the amount of high molecular weight protein present in the cyst fluid. This protein is released by inflammatory cells in response to inflammatory stimulus.

Role played by mast cells in radicular cyst enlargement:

Mast cells play a significant role in radicular cyst enlargement¹¹. Studies reveal that there are increased number of mast cells in the subepithelial zone of these cysts. Mast cells contribute to increase in the size of these cysts in the following manner:

1. By directly releasing heparin into the lumen
2. By releasing hydrolytic enzymes
3. By releasing histamine which causes transudation of serum proteins¹¹

Bone resorption by radicular cysts:

Radicular cysts causes resorption of alveolar process of maxilla. Osteoclasts have been known to cause this bone resorption. Osteoclasts need to be activated before it can reabsorb bone matrix. Osteoclasts can be activated by:

RANKL

This reaction can be blocked by:

Osteoprotegerin (OPG)

RANKL is the molecule which activates osteoclasts by binding to its receptor RANK which is expressed on the surface of osteoclast precursor cells, where as OPG blocks this very reaction preventing activation of osteoclasts.

Inflammatory mediators like cytokines and Interleukins stimulate proliferation of osteoclasts.

In response to inflammation host cells are known to produce Matrix Metallo Proteinase (MMP). This molecule is capable of degrading extracellular matrix like collagen, fibronectin and proteoglycans. Endotoxins released by bacteria also stimulates release of MMP. This substance helps osteoclasts in the bone resorption process.

Dentigerous cysts:

Also known as follicular cyst. This cyst is associated with unerupted tooth. This cyst is formed due to accumulation of fluid between the enamel epithelium and the completely formed tooth crown. This overlying cyst prevents teeth from erupting. This cyst is almost always associated with permanent dentition. In the upper jaw it is common in the canine tooth area. This cyst has its highest incidence during the 2nd and 3rd decades of life.

Radiologically the presence of pericoronal radiolucency is a diagnostic pointer. This tumor should be differentiated from ameloblastoma, odontogenic keratocyst and calcifying odontogenic cyst. All these lesions manifest with pericoronal radiolucency in routine radiographs.

Primordial cyst:

This cyst arises due to cystic changes that occur in a developing tooth bud before the actual formation of enamel and dentin matrix. Since this cyst arises from developing tooth bud the tooth would be missing from the dental arch, or if teeth are all present then the presence of supernumerary teeth should be suspected.

Lateral periodontal cyst:

This cyst develops from the periodontal ligament close to the lateral surface of erupted / unerupted teeth. This cyst is asymptomatic. The involved teeth is vital.

Residual cyst:

This cyst arises from remnants of epithelial cell rests left behind after extraction. This can also occur when a radicular cyst at the apex of the teeth is extracted. This cyst is commonly seen in the elderly.

Odontogenic Keratocyst:

This cyst has a keratinized epithelial lining. Major drawback of this condition is its propensity to

recur even after complete removal. This cyst can mimic any of the cysts described above. It needs to be identified radiologically and pathologically. This cyst is seen between wide age groups.

Calcifying odontogenic cyst (Gorlin's cyst):

This is a very rare slow growing benign tumor like cyst. This condition manifests the features of solid mass while displaying features of tumor and cystic lesion. This cyst has equal incidence in both maxilla and mandible.

Globulomaxillary cyst:

This is actually a fissural cyst arising from epithelial inclusions trapped at the line of fusion between the globular portion of the median nasal process and the maxillary process. Pathologists consider this cyst to be odontogenic rather than developmental. Radiographs show these cysts as pear shaped / circular shaped between the roots of maxillary lateral incisor and canine. Both these teeth are vital in these patients.

Results:

No of patients presented with cystic lesions involving upper jaw during study period – 30

Females – 29

Male – 1

Age of occurrence:

60-70 years – 22

40-50 years - 8

Type of cystic lesions:

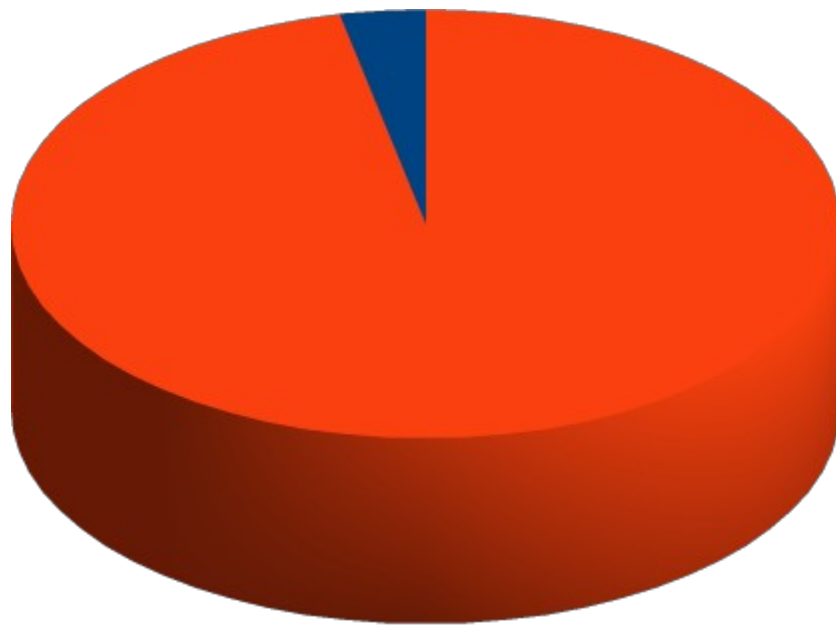
Radicular cyst – 18

Dentigerous cyst – 6

Lateral periodontal cyst - 3

Residual cyst – 1

Globulomaxillary cyst – 2



■ Male
■ Female

Chart showing the number of male and female patients who presented with cystic lesions of upper jaw

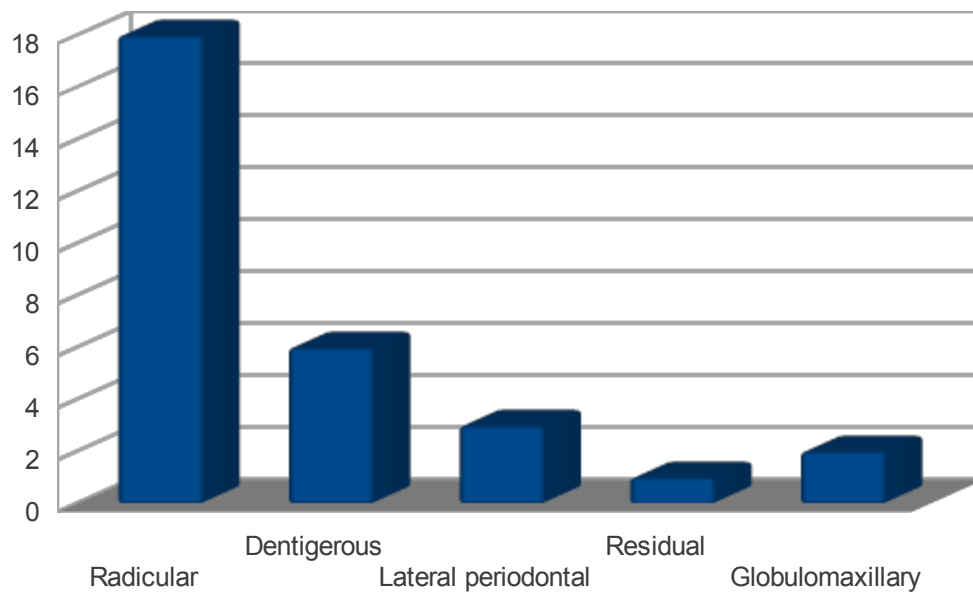


Chart showing the different types of cystic lesions encountered in our study

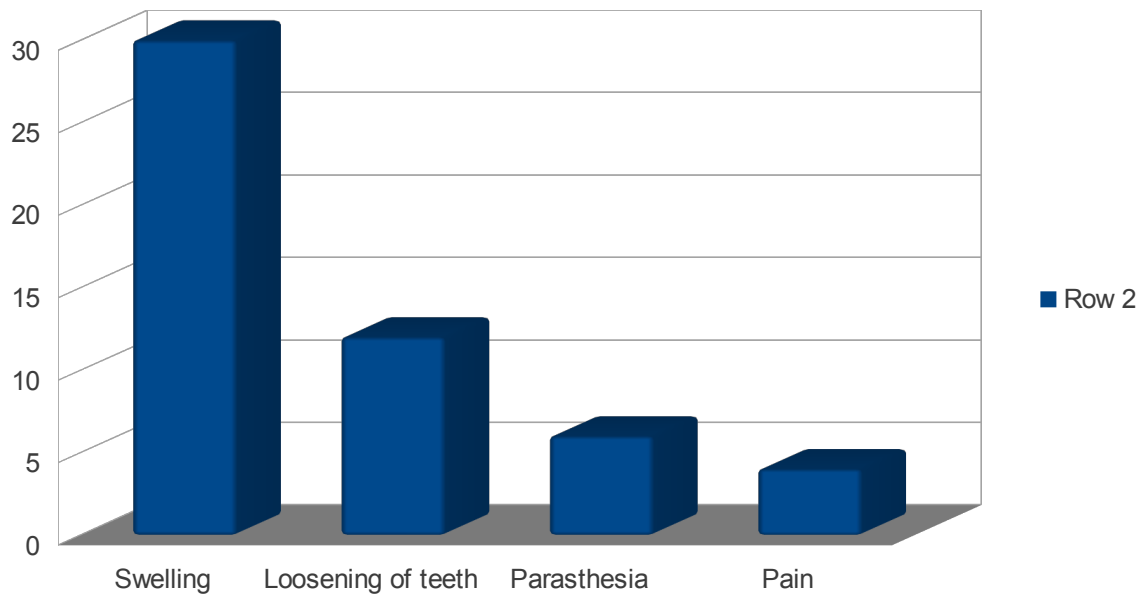
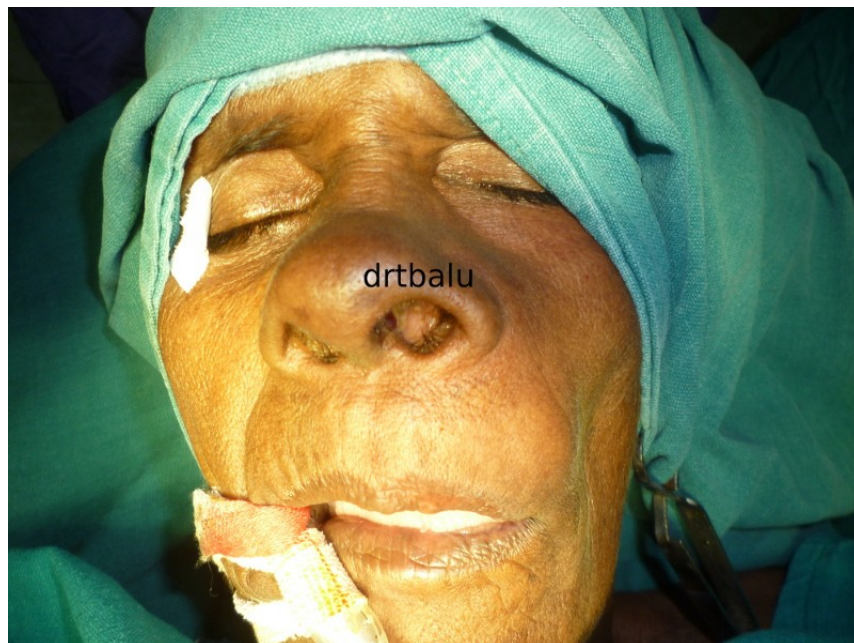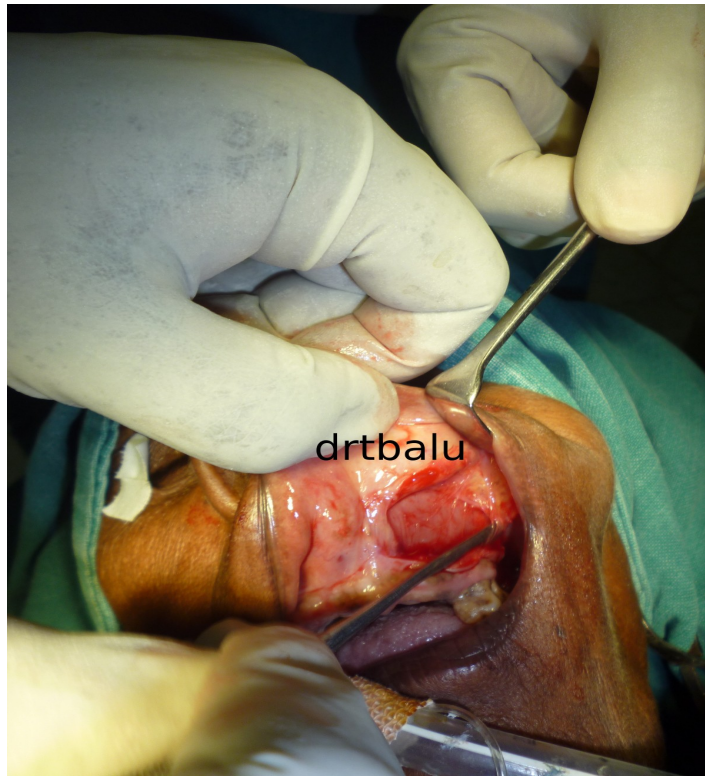


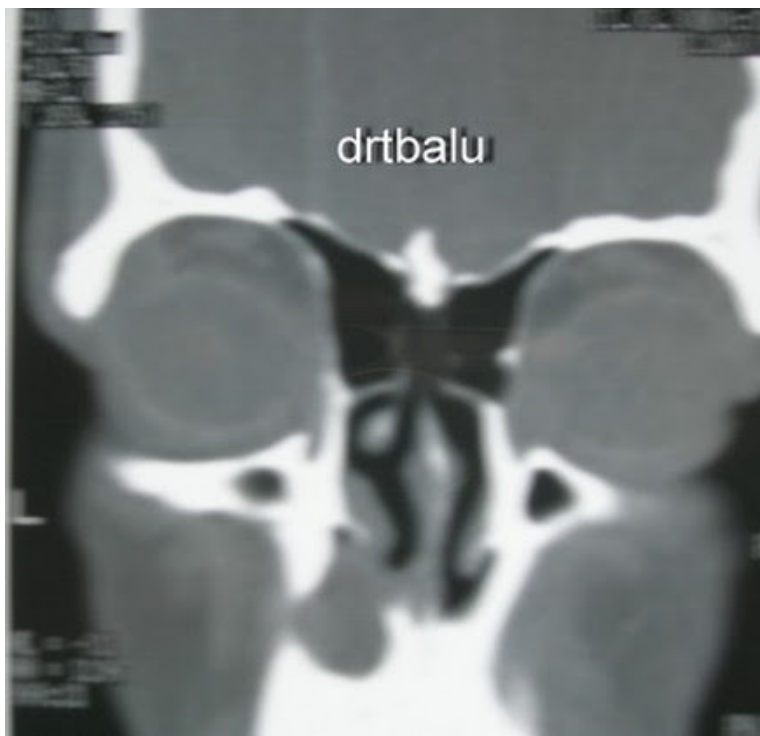
Chart showing the complaints with which these patients presented with



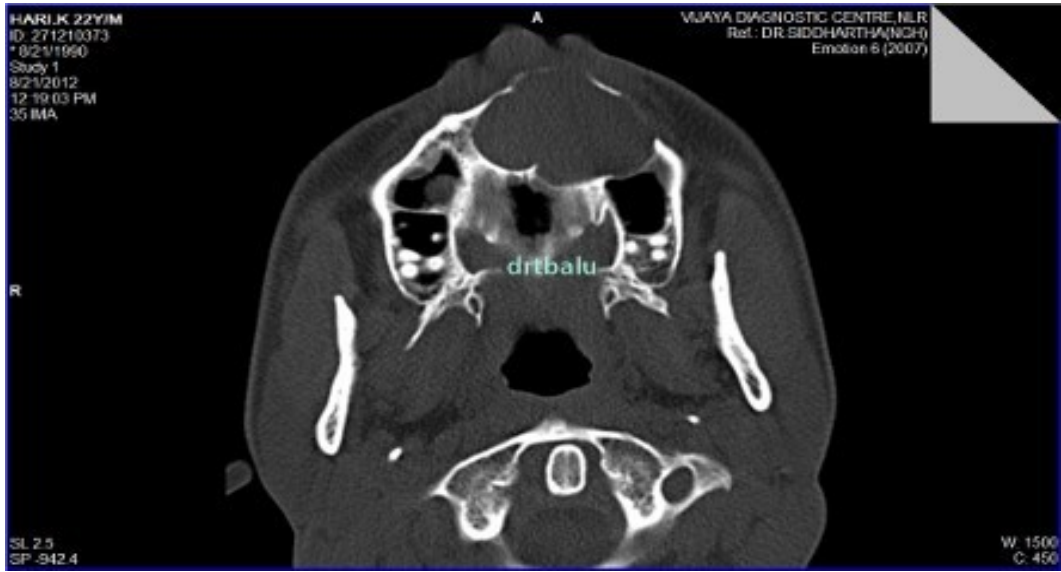
Clinical photograph of patient with swelling left upper jaw due to cystic expansion



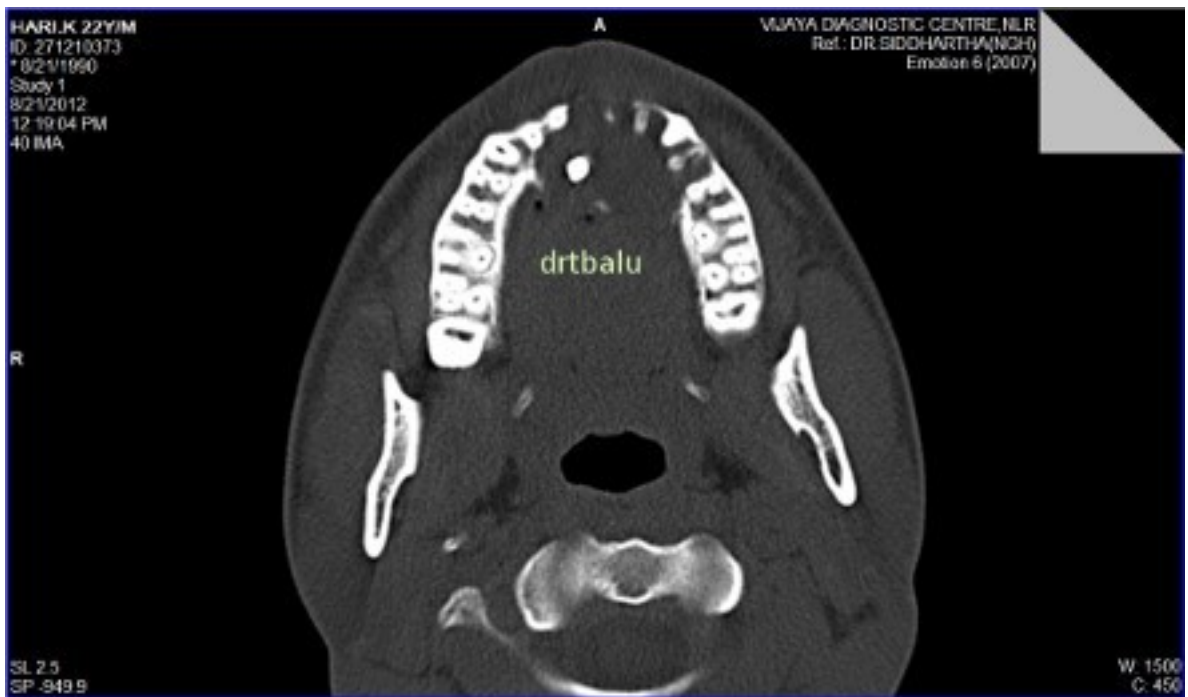
Clinical photograph showing radicular cyst maxilla being exposed via sublabial incision



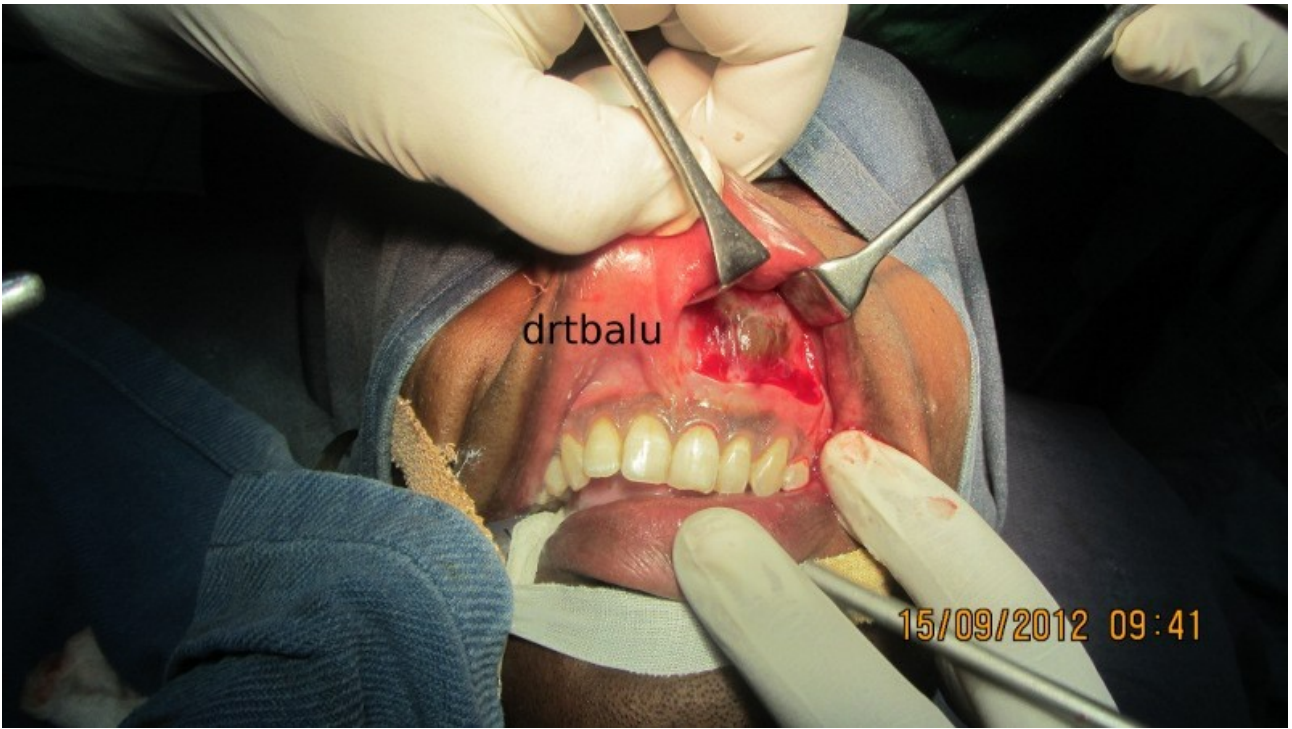
Coronal CT of nose and sinuses showing radicular cyst of upper jaw



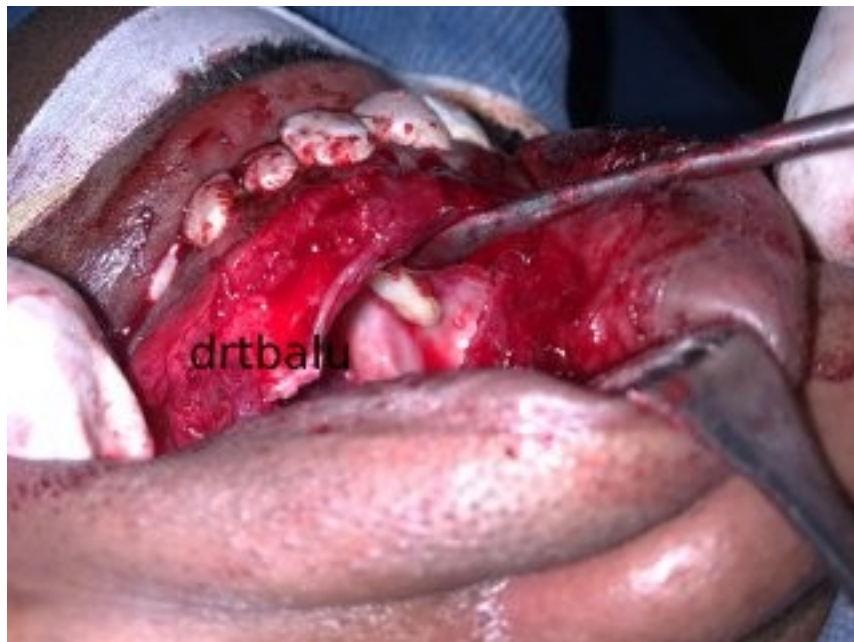CT scan axial cut of nose and sinuses showing globulomaxillary cyst



CT scan showing dentigerous cyst with unerupted teeth



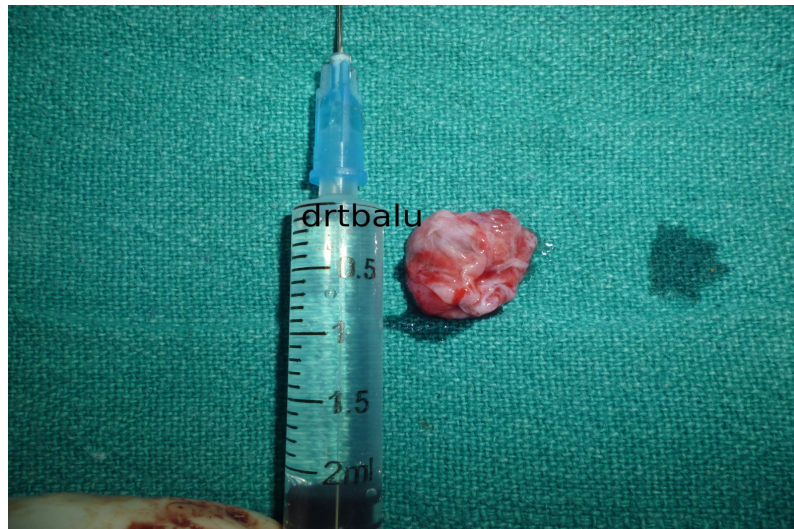Picture showing dentigerous cyst exposed via sublabial incision



Picture showing unerupted tooth within dentigerous cyst

Discussion:

All patients who reported to our hospital with cystic lesions of upper jaw were managed surgically. These cysts were accessed via sublabial approach.



Specimen of radicular cyst after removal

One patient in our study had a rapidly enlarging lesion involving the maxillary bone. The whole enlargement took place within a span of 3 weeks. This cyst was found to be filled with pus when aspirated. Acute infections of the cyst can lead to rapid enlargement of the cyst.

All specimen surgically removed from our patients were submitted for histopathological examination for final diagnosis.

As is the case in our study too radicular cysts of upper jaw constituted the majority.

Since majority of cystic lesions involving the maxilla are benign in nature, removal via sublabial approach would suffice.

Conclusion:

This retrospective study shows that the commonest cystic lesion of upper jaw happens to be radicular cyst. Considering the benign nature of the lesion complete extirpation of the cyst would suffice. In one patient the cyst was so large it had to be ruptured to ensure complete removal of the cyst wall. CT scan is virtually diagnostic. Histopathology remained the final say in the diagnosis. Age of presentation of our patients happens to be between 40-60. Almost all of them were females except for one patient (dentigerous cyst) who happened to be a male.

References:

1. Shear M (1994) Developmental odontogenic cysts. An update. *J Oral Pathol Med* 23,1-11
2. Regezi JA, Sciubba JJ, Jordan RCK (2003) *Oral Pathology: clinical pathologic correlations*. 4th ed, WB Saunders, St Louis, 241-254
3. Nakamura T, Ishida J, Nakano Y, Ishii T, Fukumoto M, Izumi H, Kaneko K (1995) A study of cysts in the oral region. *Cysts of the jaw. J Nihon Univ Sch Dent* 37, 33-40
4. Benn A, Altini M (1996) Dentigerous cysts of inflammatory origin. A clinicopathologic study. *Oral Surg Oral Med Oral Pathol Oral Radiol Endod* 81, 203-209
5. Kiss Csongor. Cell to cell interaction. *Endodontic Topic* 2004, 8:88-103.
6. Muglali M, Komerik N, Bulut E, Yarim GF, Celebi N, Sumer M. Cytokine and chemokine levels in radicular and residual cyst fluid. *J Oral Pathol Med* 2008, 37: 185-9.
7. Lin LM, Huang GTJ dan Rosenberg PA. Proliferation of epithelial cell rests, formation of apical cysts and regression of apical cysts after periapical wound healing. *JOE* 2007,33(8):908-16.
8. Oliveira MG, Lauxen IS, Chaves ACM, Rados PV, Filho MSA. Immunohistochemical analysis of the pattern of p53 and PCNA expression in odontogenic cystic lesions. *Med Oral Patol Oral Cir Bucal* 2008, 13(5):E275-80.
9. Hayashi M, Ohshima T, Ohshima M, Yamaguchi Y, Miyata H, Takeichi O, et al. Profiling of radicular cyst and odontogenic keratocyst cytokine production suggests common growth mechanisms. *JOE* 2008, 34(1):14-21.
10. Nair P, Sundqvist G, Sjogren U. Experimental evidence supports the abscess theory of development of radicular cysts. *Oral Surg Oral Med Oral Pathol Oral Radiol Endod* 2008, 106:294-303.
11. Shylaja S. Mast cells in odontogenic cysts. *Journal of Clinical and Diagnostic Research [serial online]* 2010 April [cited: 2011 October 15]; 4:2226-2236.