



Volume 3 Issue 1 2013

ISSN: 2250-0359

## Thyroglossal cyst our experience

Balasubramanian Thiagarajan <sup>1</sup> Ulaganathan Venkatesan <sup>2</sup> Geetha Ramamoorthy <sup>1</sup><sup>1</sup> Stanley Medical College <sup>2</sup> Meenakshi Medical College

### Abstract:

This study shares our experiences in managing patients with thyroglossal cysts. These are common midline tumors of neck. Characteristically these masses move on protrusion of tongue due to their intimate relationship with hyoid bone. Adults commonly presented with this lesion eventhough literature review suggests it to be common in children. All these patients underwent surgery because of the presence of mass rather than any symptoms. All 30 patients taken up in this study had a normal functioning thyroid in the normal position in addition to the cystic lesion.

### Introduction:

Literature lists thyroglossal cyst to be the most common congenital neck mass accounting for more than 70% of congenital neck lesions. It is also the most common benign mass to appear in the neck second only to cervical lymphadenitis <sup>1</sup>. Embryologically thyroglossal cyst is supposed to arise from the persistent thyroglossal duct. <sup>2</sup> Thyroglossal cyst usually present as a painless midline cystic lump. This lump is invariably smooth and is present in the hyoid region. If the lesion is painful then superadded infection should be suspected.

### Embryology:

Discussion of thyroglossal cyst is not complete without a study of development of thyroid gland. Studies reveal that between 4<sup>th</sup> – 7<sup>th</sup> weeks of intrauterine life the thyroid gland descends from foramen caecum (present at the junction of anterior 2/3 and posterior 1/3 of tongue) to take up its final position anterior and lateral to trachea <sup>3</sup>. The thyroglossal tract which connects the thyroid gland with foramen caecum degenerates and disappears by 10<sup>th</sup> week of gestation. During the descent of thyroid gland this thyroglossal tract passes through lingual muscles, then commonly passes anterior to hyoid bone and larynx. It is intimately related to the central portion of hyoid bone. <sup>4</sup> Anamolies involving development of thyroid gland could lead to formation of thyroglossal cysts which are nothing but cystic remnants of thyroglossal duct, and ectopic thyroid gland which could result from incomplete descent of thyroid gland. These anomolous structures can be found anywhere along the path of descent of thyroid gland <sup>5</sup>. Thyroglossal cysts typically move upwards on protrusion of tongue.

Differential diagnosis of midline neck swellings include <sup>6</sup>:

1. Ectopic thyroid tissue
2. Dermoid cyst

3. Branchial cyst
4. Cystic hygroma
5. Lymph node
6. Lipoma
7. Sebaceous cyst

Indications for surgery in these patients according to literature include:

1. Cosmetic
2. Infections
3. Sinus / fistula formation
4. Risk of malignant transformation

Aim of the study:

1. To ascertain whether there is sex preponderance in these patients
2. To ascertain the age of presentation
3. To evaluate Investigation modalities performed in our patients
4. To identify common site of these cysts
5. To ascertain the relationship of thyroglossal duct to hyoid bone in our patients
6. To analyze the common presenting features

Literature review suggests <sup>7</sup>:

1. Thyroglossal cysts are equally distributed among both sexes
2. This disorder is commonly identified in childhood / adolescent age groups. It is rather rare for these cysts to be identified in patients above 30 years <sup>8</sup>.
3. Unique situation where 3-4 consecutive generations of females in the same family manifested with this condition <sup>9</sup>.

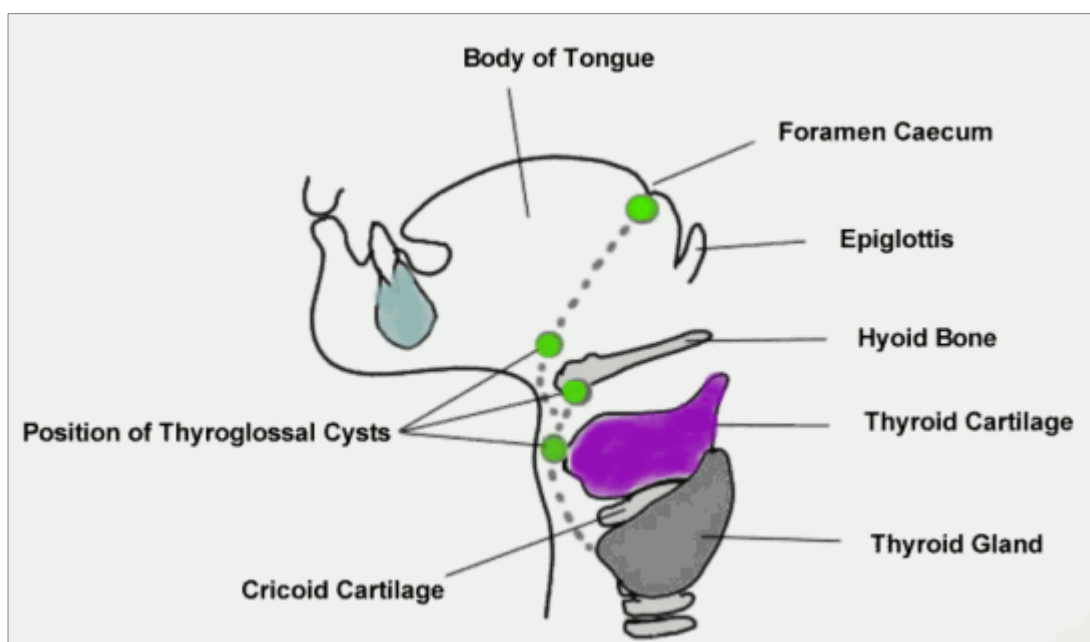


Figure showing common sites of thyroglossal cysts

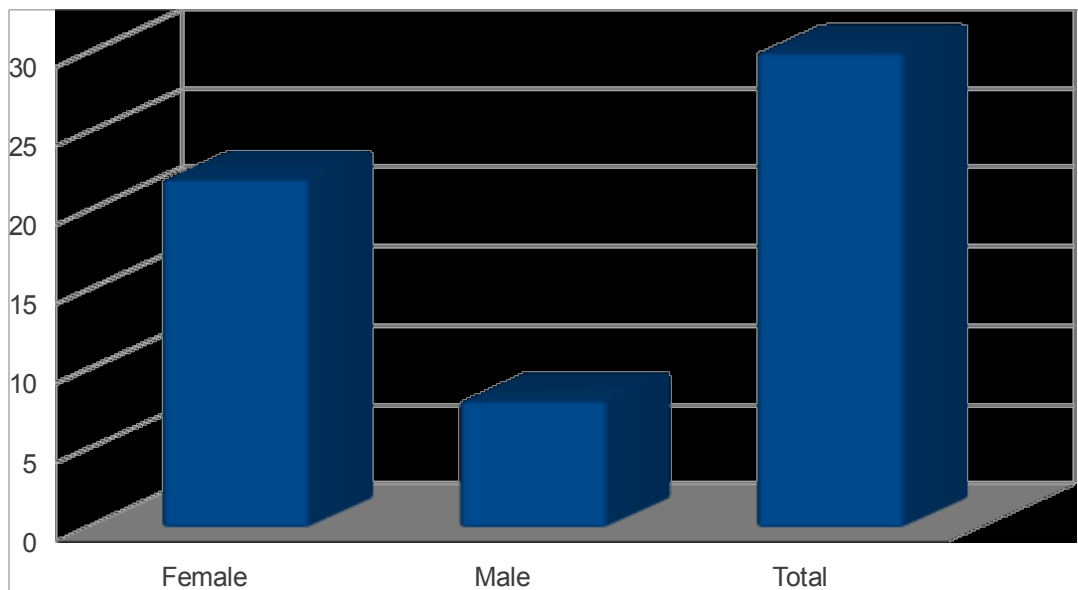
Cases operated by the author during the period 2005-2010 were taken up for study.

Results:

Total Number of thyroglossal cyst patients operated during 2005-2010 = 30

Number of female patients: 22

Number of male patients: 8



Graph showing Female preponderance in this study

Age of presentation:

Majority of patients in our study were in the age group of 30 – 40. This is actually rather rare according to published literature<sup>8</sup> in this topic.

Table showing age of presentation

Age group	No of patients
5-10 years	2
11-15 years	6
16-20 years	3
21-25 years	2
30-40 years	17

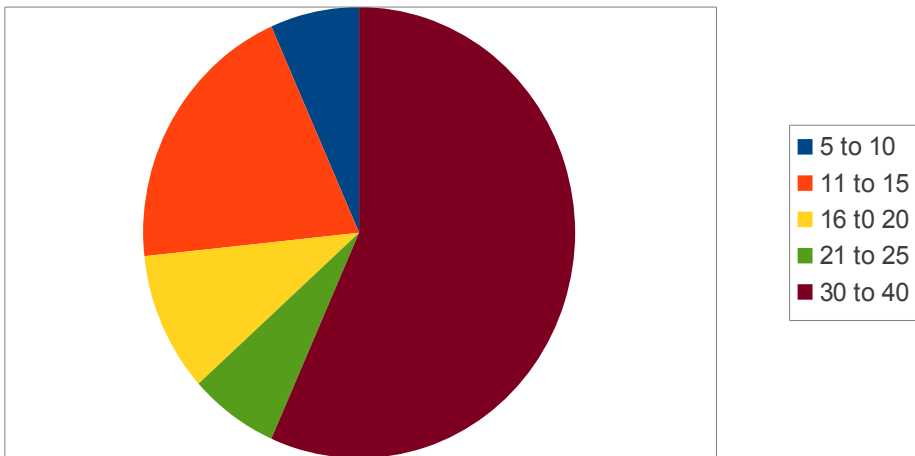


Chart showing age distribution of patients on presentation

Common presentation:

1. Midline neck swelling – 29
2. Pain in midline of neck – 2
3. Fistula midline of neck – 1

On examination:

29 patients had midline swelling which moved up and down during swallowing. One patient had a fistula over midline of neck.

Previous history of surgery for thyroglossal cyst was present for 2 patients.

One patient had a rapidly enlarging mass in the midline of neck associated with pain. Pain and rapid increase in size of the mass are attributed to infection / inflammation <sup>10</sup>.

Anatomy of thyroglossal cyst as demonstrated in the operation table:

1. All these masses were related to hyoid bone
2. In 20 patients the duct could be seen traversing behind the hyoid bone
3. In 1 patient the duct could be seen travelling anterior to hyoid bone
4. In the rest 9 cases the clear cut relationship could not be demonstrated. The mass was found just attached to the hyoid bone without any superior suprahyoid extension.

All these patients had normal functioning thyroid in the neck. They were all euthyroid. Routine ultrasound was performed in all cases in order to demonstrate normal thyroid gland in the neck.

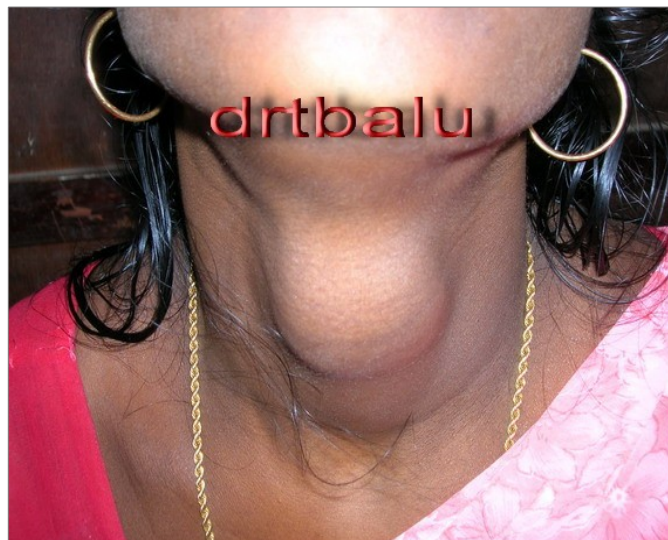

Figure showing midline swelling in the neck

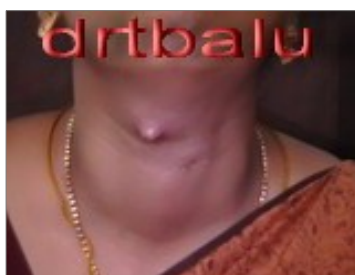
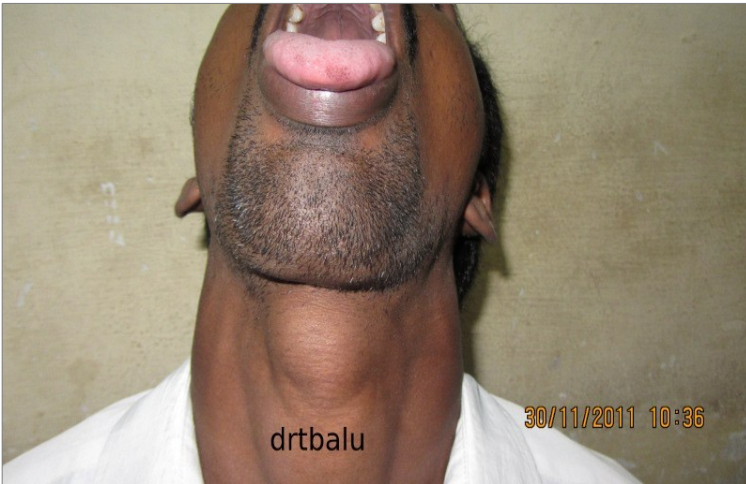

Figure showing thyroglossal fistula



Thyroglossal cyst in a male moving on protrusion of tongue

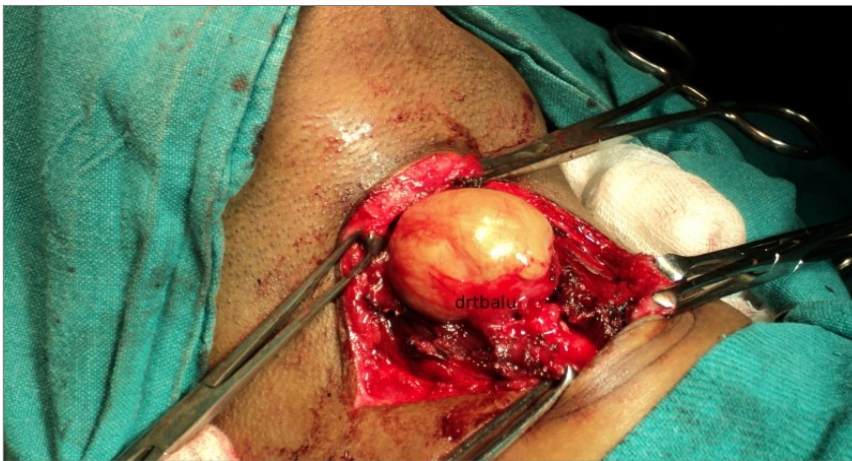

Figure showing thyroglossal cyst being exposed during surgery

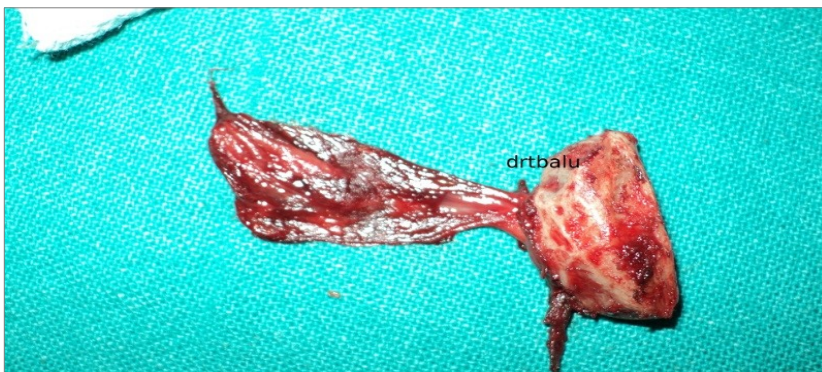

Figure showing thyroglossal cyst along with middle portion of hyoid bone after removal

Histopathology:

Thyroid follicle cells could be seen only in 3 of the 30 operated specimen.

12 cyst specimen demonstrated ciliated columnar epithelial lining, and the rest 18 demonstrated squamous epithelial lining.

Discussion:

Our study reveals that thyroglossal cyst is more common in females. All our patients were euthyroid with normal thyroid gland present in the neck. All these patients except for one presented with midline swelling of neck which moved on protrusion of tongue. One patient presented with fistula in midline of neck. There was also prior history of surgery in that patient. One patient presented with rapidly enlarging midline swelling of neck associated with tenderness and pain. Ultrasound was performed in all these patients not only to confirm the cystic nature of the mass but also to ascertain whether normal thyroid gland was present in the neck.

These patients were taken up for surgery. Surgery was performed via transverse skin crease incision in the neck. Cyst was mobilized and removed in toto. In only one patient the track had obvious extension up to the posterior third of tongue, necessitating core out procedure. One patient who had recurrence of the lesion following surgery gave history of infection at least twice before surgery was performed. This obviously accounts for the recurrence because infections usually obliterate these tracts and distorts normal anatomy<sup>11</sup>. Studies have revealed that monocystic lesions have less recurrence rate when compared to multicystic ones<sup>12</sup>.

Pathologically these cysts have been classified as monocystic and polycystic lesions. On aspiration they usually demonstrate mucoid / gelatinous material. If mucopurulent material is aspirated then it indicates active infection in the cyst. Histopathologically these cysts are commonly lined by ciliated columnar epithelium / squamous epithelium. Thyroid follicles may / may not be seen in the cyst wall. Review of literature reveal that thyroid follicles are present only in about half of the studied specimen<sup>13</sup>. In our study only 3 specimen out of the 30 studied demonstrated thyroid follicles in the cyst wall.

Conclusion:

Thyroglossal cyst presents as midline neck swelling which moves on protrusion of tongue. If it is associated with pain / tenderness then infection should be suspected. All these patients should undergo ultrasound examination of neck to identify whether normal thyroid gland is present in the neck. FNAC aspirate will reveal mucoid / gelatinous material. If the aspirate is purulent then infection in the cyst should be suspected. Complete cyst excision along with the tract if present should be the ideal treatment goal. Recurrence rate is high in patients with multicystic diseases and infected cysts.

## References:

1. Park Y. Evaluation of neck masses in children. *Am Fam Phy* 1995;51:1904-12
2. [http://www.drtdbalu.co.in/thyro\\_cyst.html](http://www.drtdbalu.co.in/thyro_cyst.html)
3. Skandalakis JE, Gray GN. *Embryology For Surgeons*. Baltimore: Williams & Wilkins, 1994
4. Ellis PDM, Van Nostrand AWP. The applied anatomy of thyroglossal tract remnants. *Laryngoscope* 1977;87:765±70
5. Noyek AM, Friedberg J. Thyroglossal duct and ectopic thyroid disorders. *Otolaryngol Clin N Am* 1981;14:187±201
6. Ward PH, Strahan RW, Acquarelli M, Harris PF. The many faces of cysts of the thyroglossal duct. *Trans Am Acad Ophthalmol Otolaryngol* 1970;74:310±18
7. ALLARD, R. H. B.: The thyroglossal cyst. *Head and Neck Surg.* 1982; 5: 134-146.
8. Rood, S.R. Johnson, J.T. Myers: Congenital masses of the head and neck. *Postgraduate Med* 1982; 72; 141-149
9. ASHWORTH, J. W.: Three generations of thyroglossal duct remnant in one family. *J. of Family Practice* 1979; 8: 624-625.
10. Brousseau VJ, Solares CA, Xu M, Krakovitz P, Koltai PJ. Thyroglossal duct cysts: presentation and management in children versus adults. *Int J Pediatr Otorhinolaryngol* 2003;67: 1285-90.
11. Y. Ducic, S. Chou, J. Drkulec, H. Ouellette, A. Lamothe, Recurrent thyroglossal duct cysts: a clinical and pathologic analysis, *Int. J. Pediatr. Otorhinolaryngol.* 44 (1998) 47-50.
12. Risk factors for thyroglossal duct remnants after Sistrunk procedure in a pediatric population R. Marianowski et al *International Journal Pediatric Otorhinolaryngology* (2003) 67, 19-23
13. Chandra RK, Maddalozzo J, Kovarik P. Histological characterization of the thyroglossal tract: implications for surgical management. *Laryngoscope* 2001;111:1002–5