

Sarah B. Lumpkins¹, Kathleen M. Garcia², Ashot E. Sargsyan², Douglas R. Hamilton², Michael D. Berggren³, and Douglas Ebert²

¹Harvard-MIT Division of Health Sciences and Technology, Cambridge, MA

²Wyle Integrated Science and Engineering, Houston, TX

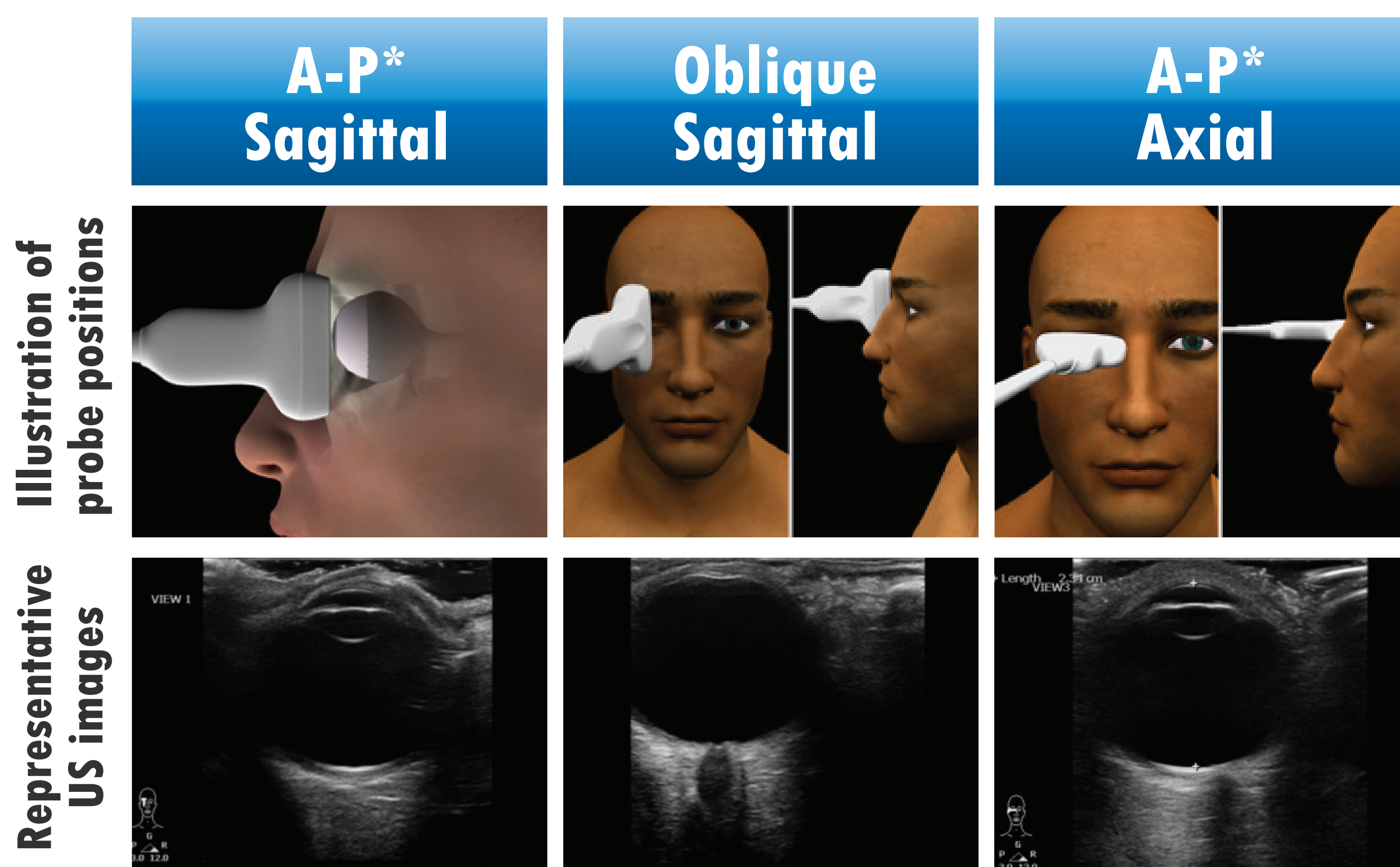
³Purdue University, West Lafayette, IN

Introduction

Microgravity exposure affects visual acuity in a subset of astronauts, and mechanisms may include structural changes in the posterior globe and orbit. Particularly, posterior globe flattening has been implicated in the eyes of several astronauts. This phenomenon is known to affect some terrestrial patient populations and has been shown to be associated with intracranial hypertension. It is commonly assessed by magnetic resonance imaging (MRI), computed tomography (CT), or B-mode ultrasound (US), without consistent objective criteria. NASA uses a semi-quantitative scale of 0-3 as part of eye/orbit MRI and US analysis for occupational monitoring purposes. The goal of this study was to initiate development of an objective quantification methodology to monitor small changes in posterior globe flattening.

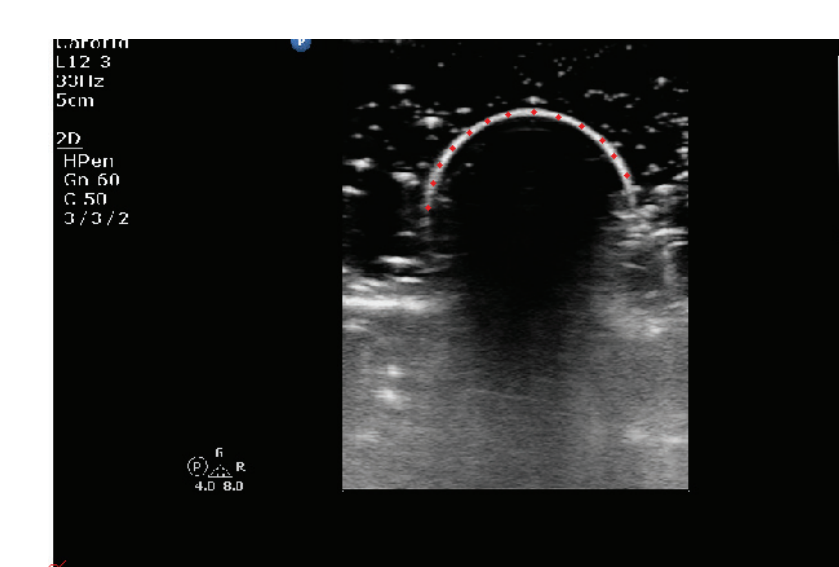
Methods

- US images were obtained from 36 preflight, 10 in-flight and 31 post flight US examinations. Several images using various US probe positions (as illustrated below) were taken during each exam, and the image displaying the greatest degree of flattening was chosen for analysis. All images were blinded prior to analysis.



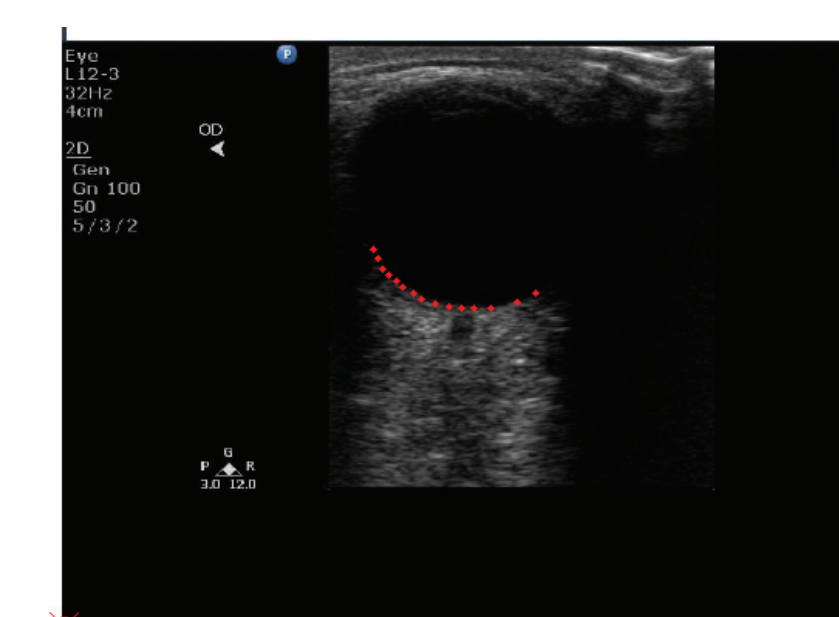
*A-P: anterior-posterior

- Posterior globe shapes were scored qualitatively on a scale from 0 (round) to 3 (flat).



** Software validation using objects of known radius

- The radius of eye curvature (ROC) of each eye was quantitatively evaluated by digitizing the US images using a validated software program**.

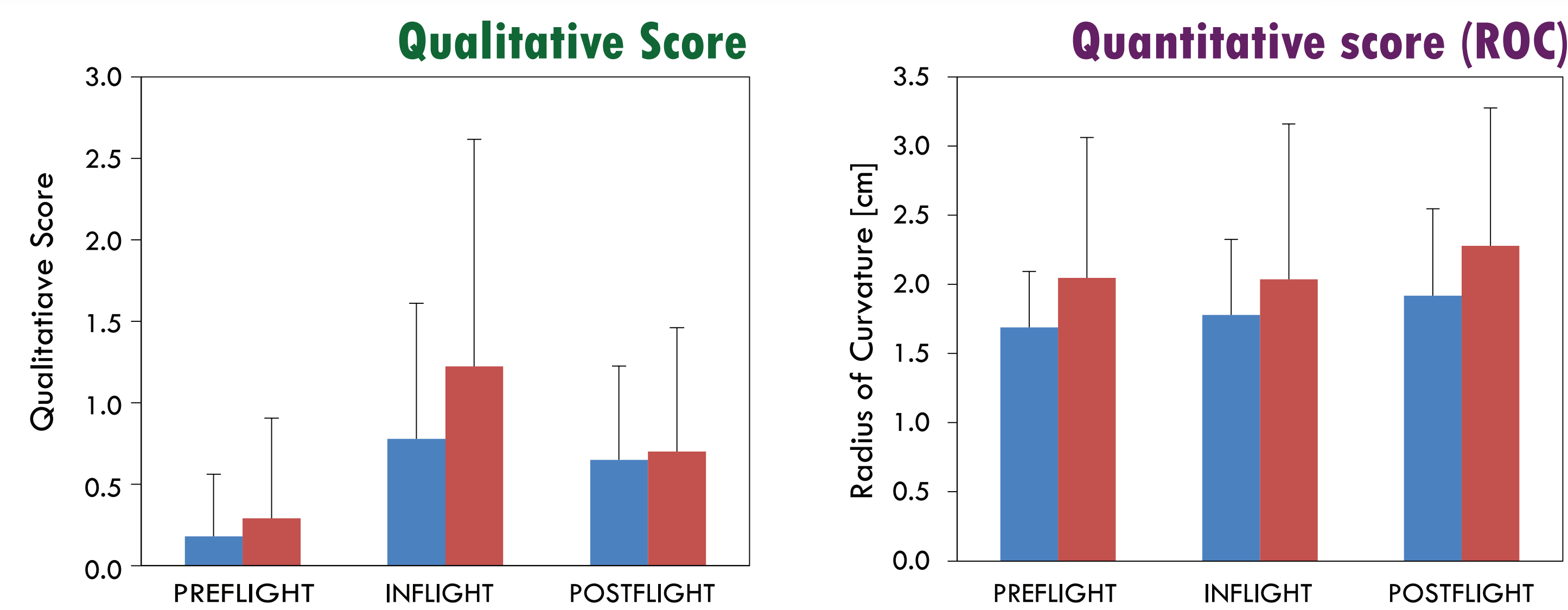


Digitized contour of astronaut eye

- Preflight, in-flight, and post flight scores and ROCs were analyzed. The preflight and post flight changes in the scores and ROCs were also evaluated.

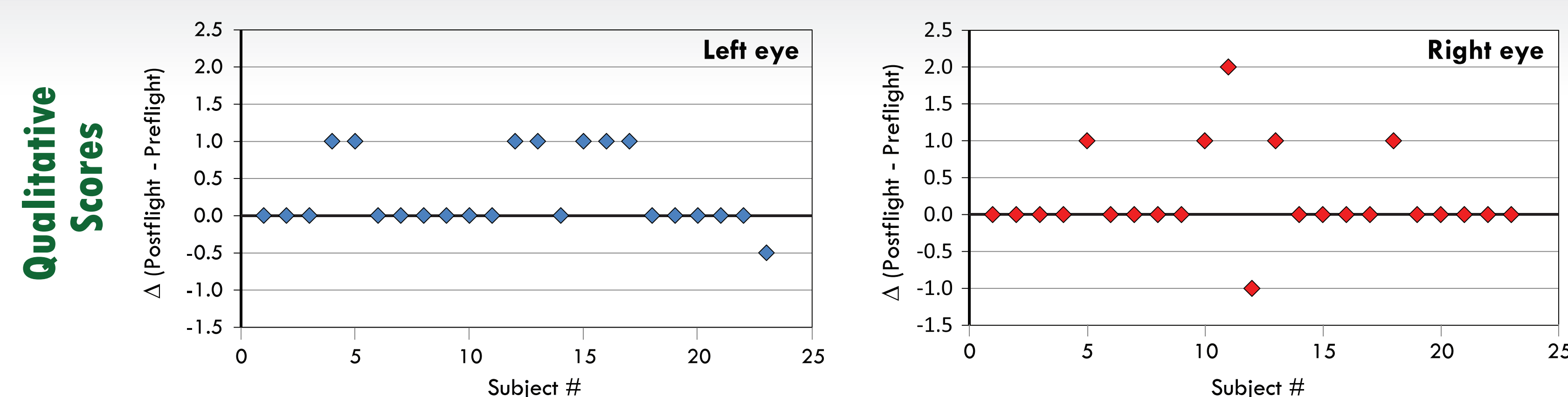
Results

Globe flattening in all US eye images

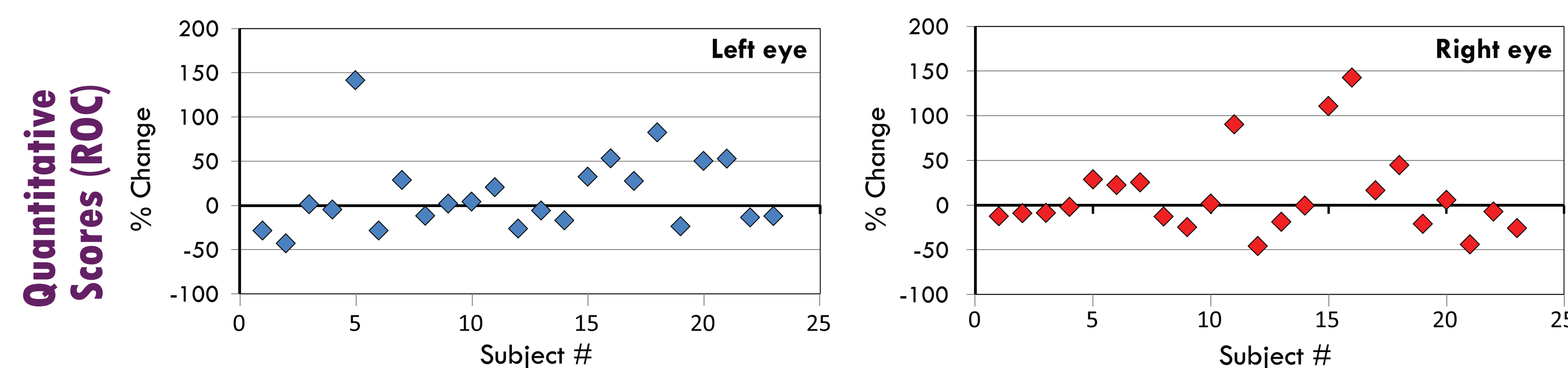


Comparison of qualitative (left) and quantitative (right) scores. No significant differences were found between preflight, in-flight and post flight images using either metric. Results are presented as the mean +/- standard deviation.

Preflight to post flight changes in globe flattening



The left eyes of 7 of the 23 subjects (30.4%) became flatter post flight compared to preflight, and the right eyes of 5 of the 23 subjects (21.7%) became flatter post flight.

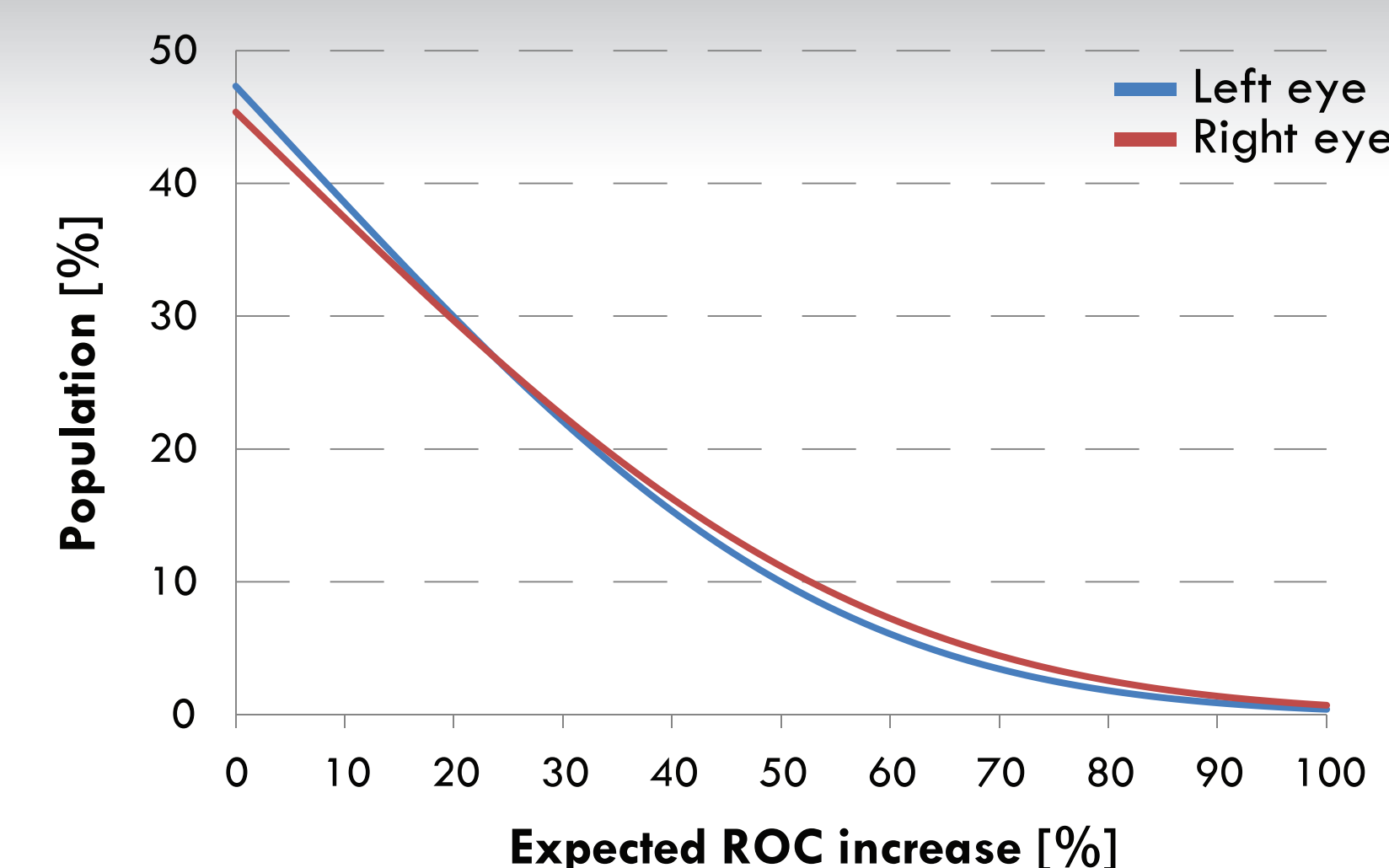


The left eyes of 12 of the 23 astronauts (52.2%) became flatter post flight, and the right eyes of 10 astronauts (43.5%) became flatter post flight.

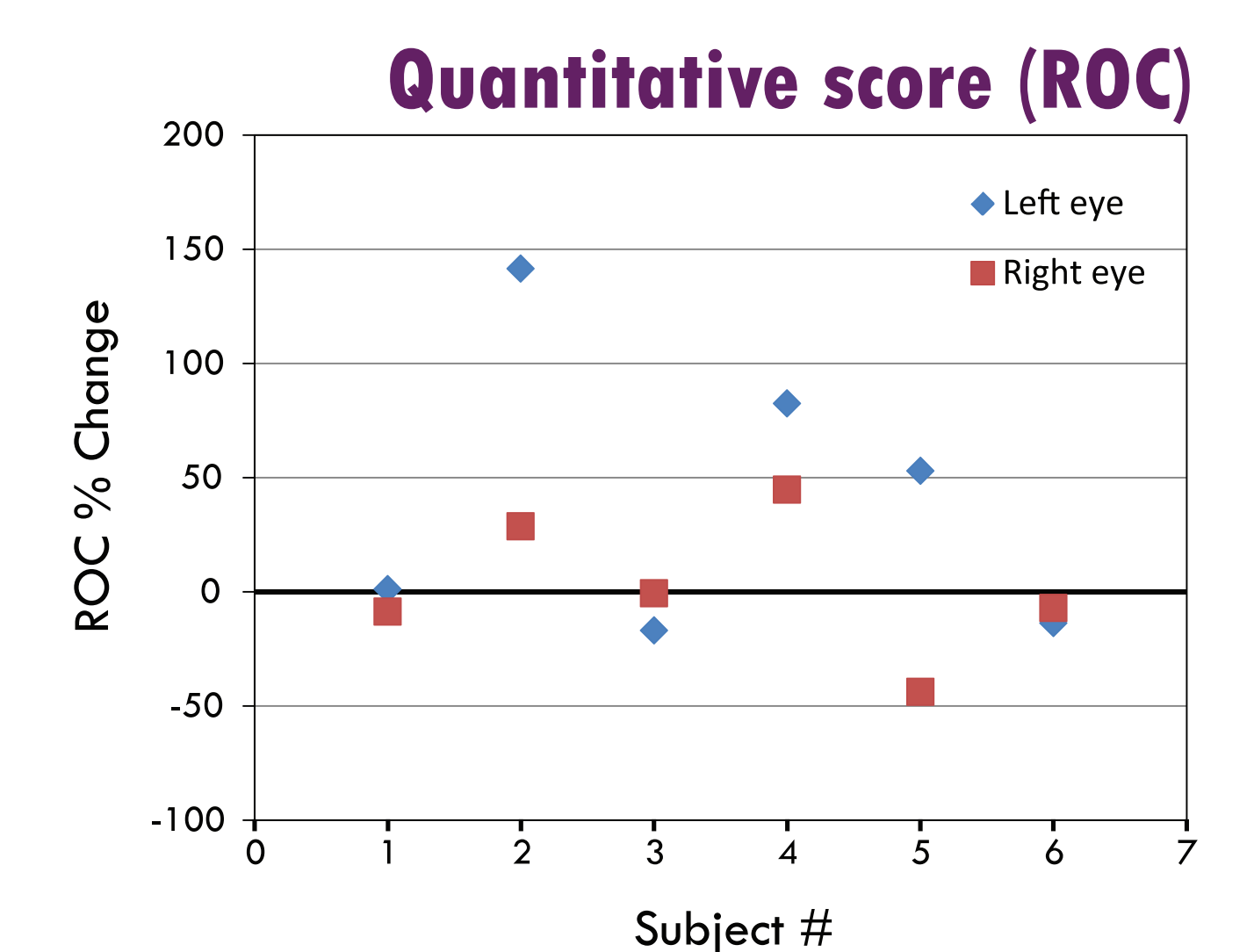
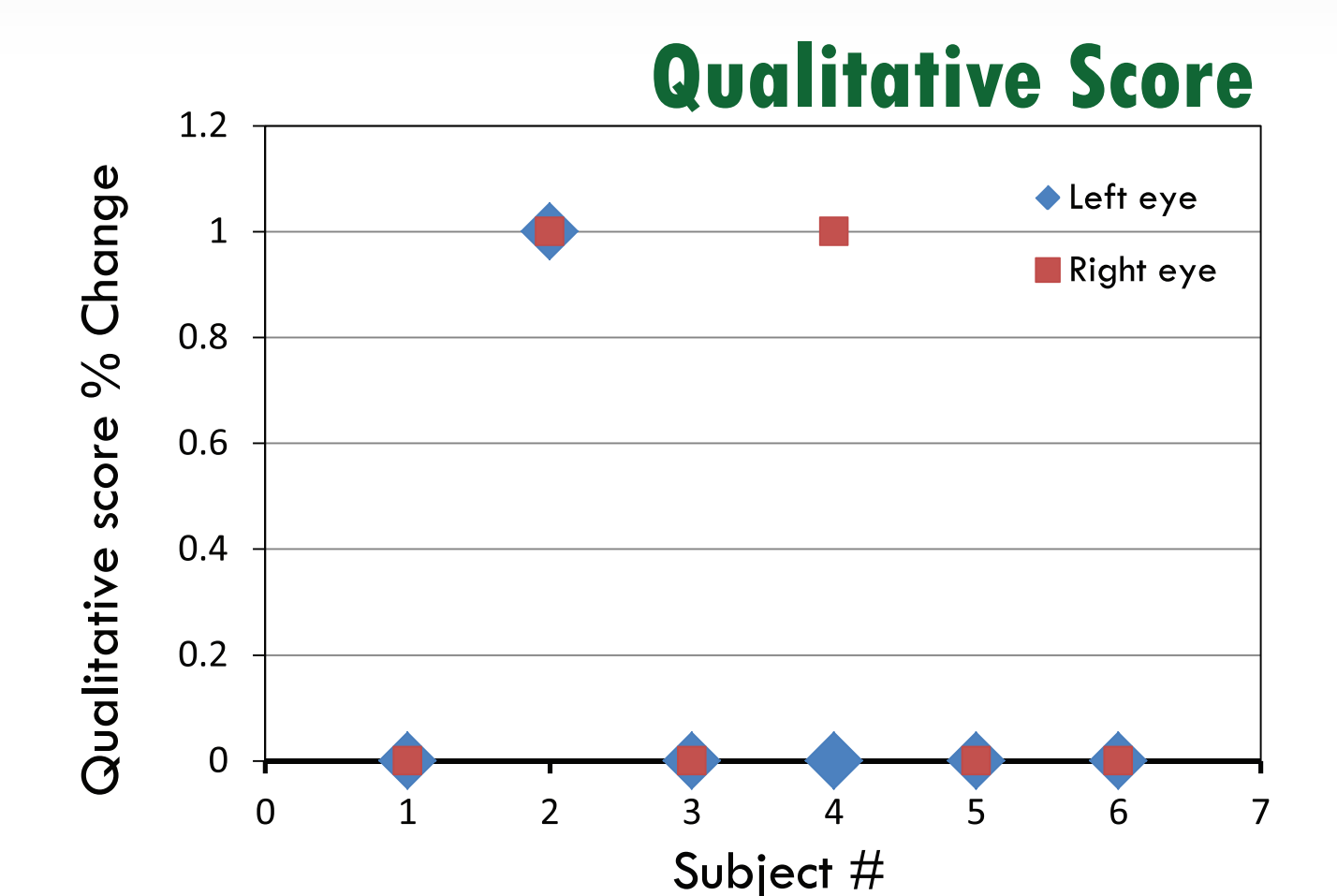
Expected eye flatness in the astronaut population

Non-parametric tolerance analysis (95% confidence)

The expected degree of globe flattening as a function of percentage of the astronaut population is shown.



Globe flattening in long-duration astronauts



Two of the right eyes and 1 left eye of long-duration astronauts demonstrated globe flattening post flight based on the qualitative scores. Based on the ROC, the left eyes of 4 of the 6 astronauts became flatter postflight, and the right eyes of 3 astronauts became flatter.

Conclusions

The image analysis and mathematical tools of this study appear effective in assessing the shape of the posterior globe in the context of space flight and form a basis for automated image analysis. In this sample set, they showed trends similar to ratings by highly trained sonographers. Future work will focus on these and other metrics in the context of the imaging techniques, including standardized image acquisition and strict definition of measurement area. Objective determination of flattening appears to be a promising monitoring tool in astronauts and in some clinical populations; this and future techniques can be easily adapted for other tomographic images such as MRI or CT.