

Pages: 11
Words: 1021
Tables & Figures: 2
Photos: 2
References: 11
Contact: Maj Kirkpatrick
Guarantor: Maj Kirkpatrick

Rapid diagnosis of an ulnar fracture with portable hand-held ultrasound.

Major (Res) Andrew W Kirkpatrick MD FACS¹
Commander Ross Brown MD FACS¹
Lawrence N. Diebel MD FACS²
Savvas Nicolaou MD FRCR¹
Tom Marshburn MD³
Scott A Dulchavsky MD PhD^{2,3}

¹Canadian Forces Trauma Training Centre – West, Vancouver Hospital & Health Sciences Centre, Vancouver, British Columbia

²Wayne State University School of Medicine, Detroit, Michigan.

³National Aeronautics and Space Administration, Houston, Texas

(Address for Correspondence)
Maj (Res) AW Kirkpatrick MD FRCSC
Trauma Services
Vancouver Hospital & Health Sciences Centre
3rd Floor, 855 West 10th Avenue
Vancouver, British Columbia
V5Z 1L7
(604) 875-4559
(604) 875-5348 (fax)
akirkpat@vanhosp.bc.ca

Keywords: injuries, fractures, sonography,
military medicine, operational medicine,
space flight

Abstract

Orthopedic fractures are a common injury in operational activities, injuries that often occur in isolated or hostile environments. Clinical ultrasound devices have become more user friendly and lighter allowing them to be easily transported with forward medical teams. The bone-soft tissue interface has a very large acoustic impedance, with a high reflectance that can be used to visualize breaks in contour including fractures. Herein reported is a case of an ulnar fracture that was quickly visualized in the early phase of a multi-system trauma resuscitation with a hand-held ultrasound device. The implications for operational medicine are discussed.

Introduction

Orthopedic fractures are common in injured patients. The diagnosis is suggested by history and physical examination findings, and routinely confirmed radiologically. However, in critically injured or unstable patients, transport to radiologic facilities is often delayed in military or aerospace settings. Injuries may occur in remote locations or evacuation may be delayed by combat, weather, or mass casualties overwhelming the evacuation system. Advances in ultrasound technology have expanded the clinical use of ultrasound to the real-time trauma resuscitation, and provided reliable hand-held units that can easily be hand carried by mobile medical teams. Reports have suggested that ultrasound may provide an additional modality to diagnose orthopedic injury. We report the use of a portable ultrasound device to diagnose a non-displaced ulnar fracture during an emergency room resuscitation.

Case Report

A 54 year old female pedestrian was struck by a motor vehicle and sustained a closed head injury, multiple rib fractures, a pelvic fracture, and localized pain in the right forearm. Real time sonography was performed utilizing a hand-held portable ultrasound device (Sonosite 180™, Bothell WA.) utilizing a 10-5 MHz linear array transducer. This skeletal assessment examination complemented the early sonographic examination of her thoraco-abdominal cavities that is part of the institutional trauma protocols. The cortex of the non-injured ulna was visualized as a continuous echogenic uninterrupted line. In contrast, a minimally displaced fracture of the ulna was readily demonstrated as a cortical irregularity with swelling in the overlying soft tissues (Figure 1). A comminuted, mid-shaft fracture of the ulna was confirmed radiographically (Figure 2). The ulnar fracture was treated with a long arm cast.

Discussion

Physical examination remains the primary mode of identification of orthopedic skeletal injuries. The absence of immediate radiographic capabilities complicates the diagnosis of extremity fracture, especially in situations where care is provided in remote areas. This concern is particularly evident in military situations such as far-forward, special forces and naval operations, as well as in aerospace medicine. In operation medicine radiographic examinations are impractical not only because of the weight of the

radiographic equipment, but also of the lead shielding required by traditional mainstream terrestrial practice¹.

The ultrasonic diagnosis of bony injury is one exciting facet of the widespread expansion of sonography into almost all areas of medicine. The bone-soft tissue interface has a very large acoustic impedance, causing almost total reflectance of the acoustic waves^{2,3}. This high reflectance can be used to visualize contour imperfections such as steps and breaks in the bony cortex⁴. Soft tissue alterations including swelling and hematoma formation are often present which can further aid the diagnosis^{5,6}. Variable high frequency linear array probes have been found to be quite accurate at detecting occult fractures in stable clinical settings⁶. Williamson et al, reported that the use of ultrasound with high frequency probes (6-10MHz) to detect fractures appears to be a reliable technique^{3,5}. Katz et al described a series of clavicular fractures in newborn babies, and found no substantial differences in the detection rates between ultrasound and radiographic examinations⁷. A similar technique was used by Wang et al, to detect radiographically occult fractures in patients with foot and ankle injuries whose initial radiographs had been deemed normal by clinicians or radiologists⁸. Ten humeral fractures were seen sonographically in one series after being missed on initial radiographs². None of these reports though, have taken this diagnostic modality to the resuscitation arena, during the early phases of trauma care.

We report the use of a portable, hand-held ultrasound unit equipped with high frequency linear array transducer (Sonosite 180™ with a 10-5 linear array transducer,

Sonosite Inc, Bothel, WA) to aid diagnosis of an ulnar fracture. This light-weight device can easily be carried by a medical provider during the course of outdoor activities such as snow-boarding⁹, or other vigorous activities. The main-unit measures 33.8 by 19.3 by 6.1 cm, and with transducer weighs 2.4 kg, making it lighter than two and a half litres of crystalloid fluid. The device can operate on alternating current consuming 16 to 30 Watts provided by either a universal power adaptor, or rechargeable lithium ion batteries which may provide for up to 4 hours of scanning. A focused examination with this device can identify the presence of a cortical break of a fracture within seconds. This information is presented in a visual and digital form that might be amenable to tele-transmission depending on the communication resources present.

The use of this portable device facilitates prompt orthopedic investigations, especially in unstable individuals who cannot be transported to the radiographic suite and avoids exposure of the team and patient to radiation. This technique can be expanded to locations where radiography is unavailable such as military conflicts, rural medicine, maritime operations, and even in space medical applications. Once the concept of handheld sonography is validated any specific ultrasound unit utilized could presumably be built or adapted to specifications determined by the intended environment. Characteristics such as the degree of battle-hardening versus weight reduction could be adaptable depending on the mission. Potentially the electronic central components might fit within different carrier cases intended for regular, arctic, desert, airborne operations, etc. Whatever the environment, utilization of this device could conceivably facilitate the early diagnosis of a fracture without stressing or manipulating a limb, and can focus

specifically on the exact site of interest rather than requiring an examination of a field of interest.

In operational settings it would be valuable to the mission to differentiate fractures from weight-bearing soft tissue injuries. There is further impetus to examine this technique in space medicine. There is a risk of orthopedic injury during the construction phase of the International Space Station (ISS), due to potential kinetic impacts from large equipment or the spacecraft bulkhead^{10,11}. The Human Research Facility is a payload in the ISS laboratory module. This facility currently contains a ATL HDI-5000 (Phillips Medical Systems, Bothell WA) ultrasound machine intended for scientific research, but which could possibly be used operationally by an appropriately trained crew medical officer. Use of a small, robust ultrasound device such as this might allow on orbit verification of an orthopedic injury, as easily as it could non-invasively benefit injured patients on earth.

Sonography is very user dependant, but has many uses in different hands. The secondary survey of the trauma patient mandates a head to toe palpation for bony tenderness or abnormal movement¹². Clinicians resuscitating trauma patients may easily and quickly expand their physical examination using sonography. Further clinical studies are thus ongoing.

Acknowledgement

The authors acknowledge the generous support of an unrestricted educational donation from the Heathcliff Foundation, as well as the loan from the Sonosite Corporation of a Sonosite 180 ultrasound device for testing.

Figures

Figure 1.

Sonographic image of a mid-ulnar fracture utilizing a Sonosite 180™ with a 10-5 linear array transducer. There is a distinct cortical break at the site of maximal swelling and tenderness with evidence of soft tissue edema.

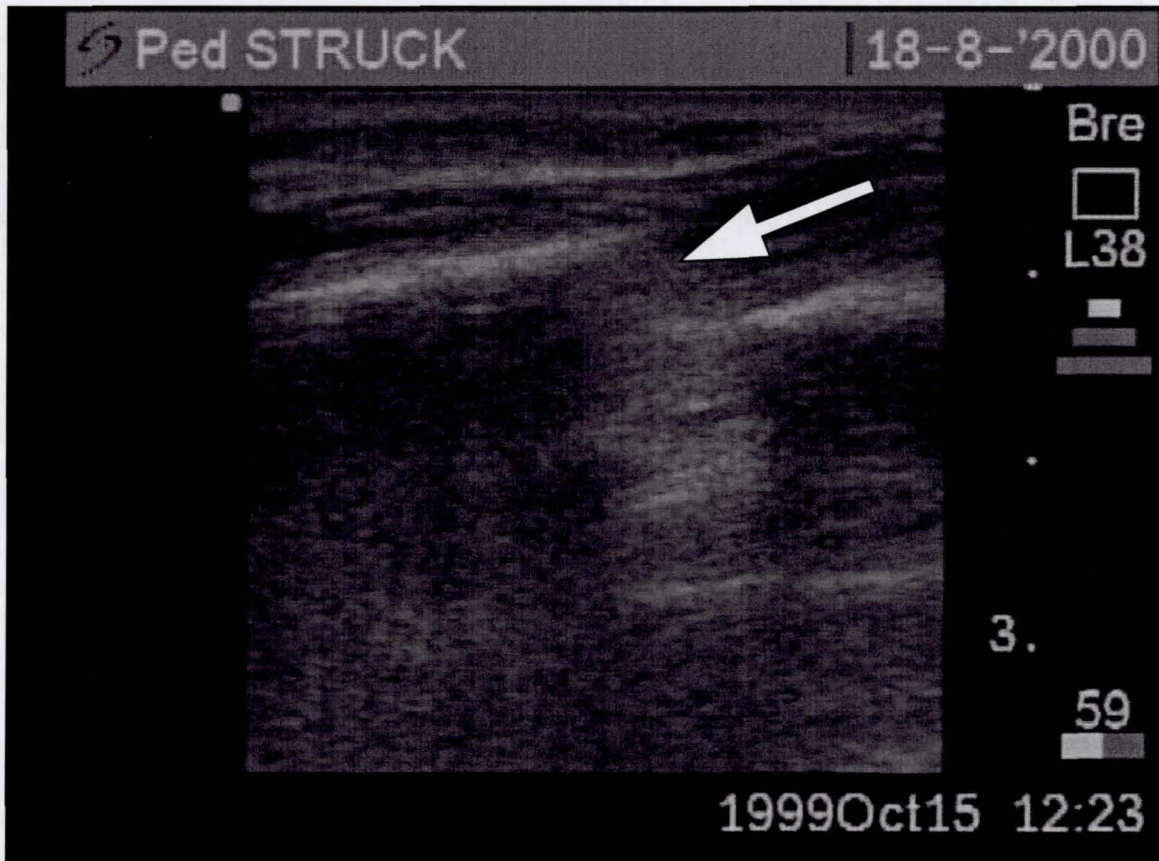
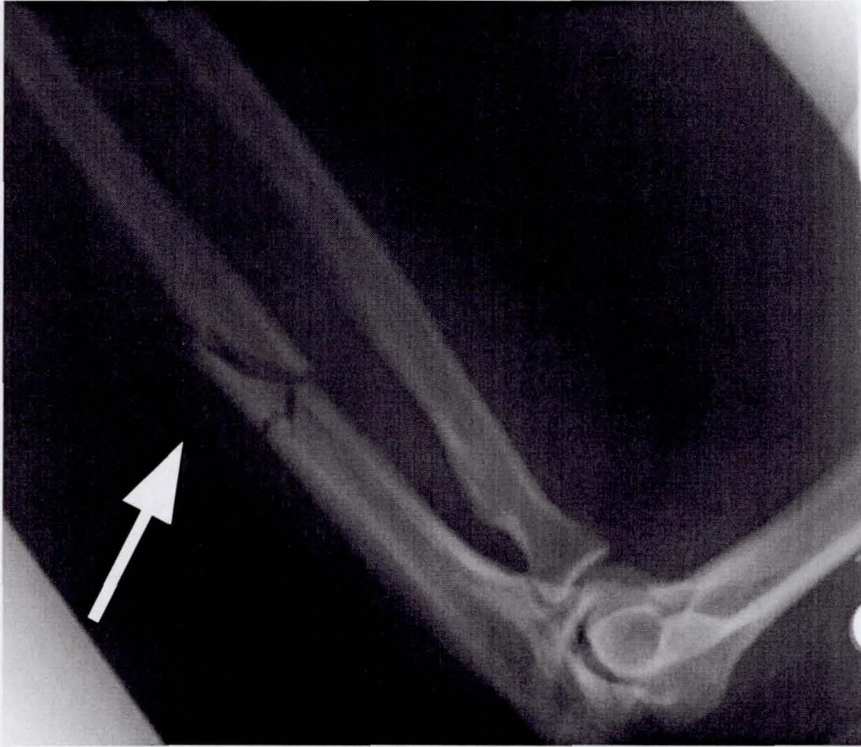


Figure 2.

Radiographic confirmation of a comminuted oblique fracture of the proximal ulnar shaft with minimal disruption between the fracture fragments corresponding to the site of maximal edema and tenderness.



Reference List

1. Hart R, Campbell MR. Digital radiography in space. *Aviat Space Environ Med* 2002;73:601-6.
2. Patten RM, Mack LA, Wang KY, Lingel J. Nondisplaced fractures of the greater tuberosity of the humerus: Sonographic detection. *Radiology* 1992;182:201-2-4.
3. Williamson D, Watura R, Cobby M. Ultrasound imaging of forearm fractures in children: a viable alternative? *J Accid Emerg Med* 2000;17:22-4.
4. Craig JG, Jacobson JA, Moed BR. Ultrasound of fracture and bone healing. *Rad Clin N Amer* 1999;37:737-51.
5. Hendrich C, Finkewitz U, Berner W. Diagnostic value of ultrasonography and conventional radiography for the assessment of sternal fractures. *Injury* 1995;26:601-4.
6. Ali S, Friedman L, Finlay K, Jurriaans E, Chhem RK. Ultrasonography of occult fractures: a pictorial essay. *Can Assoc Radiol J* 2001;52:312-21.
7. Katz R, Landman J, Dulitzky F, Bar-Ziv J. Fracture of the clavicle in the newborn. *J Ultrasound Med* 1988;7:21-3.
8. Wang CL, Shieh JY, Wang TG, Hsieh FJ. Sonographic detection of occult fractures in the foot and ankle. *J Clin Ultrasound* 1999;27:421-5.
9. Kirkpatrick AW, Brown DR, Crickmer S, Mohr BP, Hamilton DR, Cunningham J, et al. Hand-held portable sonography for the on-mountain exclusion of pneumothorax. *Wilderness Environ Med* 2001;12:270-2.
10. Kirkpatrick AW, Campbell MR, Novinkov O, Goncharov I, Kovachevich I. Blunt trauma and operative care in microgravity. *J Am Coll Surg* 1997;184:441-53.
11. Campbell MR. A review of surgical care in space. *J Am Coll Surg* 2002;194:802-12.
12. American College of Surgeons, Committee on Trauma. *Advanced Trauma Life Support Course for Doctors, Instructor Course Manual*. Chicago, 1997.