

Case Report for The Lancet

Maximum requested word count: 600

Actual word count: 809 (with refs, authors and affs), 586 (with text and Figure legend).

Persistent Seroconversion after Accidental Eye Exposure to Calcifying Nanoparticles

Neva Ciftcioglu¹, Katja M. Aho², David S. McKay³, E. Olavi Kajander^{2,4}

¹Nanobac Pharmaceuticals Inc. NASA Johnson Space Center, Houston TX

²University of Kuopio, Kuopio, Finland

³NASA Johnson Space Center, Houston TX

⁴Nanobac Pharmaceuticals Inc. Tampa, FL

Biosafety of nanomaterials has attracted much attention recently (1). We report here a case where accidental human eye exposure to biogenic nanosized calcium phosphate in the form of calcifying nanoparticles (CNP) raised a strong IgG immune response against proteins carried by CNP. The antibody titer has persisted over ten years at the high level. The IgG was detected by ELISA using CNPs propagated in media containing bovine and human serum as antigen.

The exposure incident occurred to a woman scientist (WS) at a research laboratory in Finland at 1993. CNP, also termed “nanobacteria”, is a unique self-replicating agent that has not been fully characterized and no data on biohazards were available at that time. Before the accident, her serum samples were negative for both CNP antigen and anti-CNP antibody using specific ELISA tests (Nanobac Oy, Kuopio, Finland). The accident occurred while WS was harvesting CNP cultures. Due to a high pressure in pipetting, CNP pellet splashed into her right eye. Both eyes were immediately washed with water and saline. The following days there was irritation and redness in the right eye. These symptoms disappeared within two weeks without any treatment. Three months after the accident, blood and urine samples of WS were tested for CNP cultures (2), CNP-specific ELISA tests, and blood cell counts. Blood cell counts were normal, CNP antigen and culture tests were negative. A high IgG anti-CNP antibody titer was detected (see Figure). The antibodies of this person have been used thereafter as positive control and standard in ELISA manufacturing (Nano-Sero IgG ELISA, Nanobac Oy, Kuopio, Finland).

Case Report for The Lancet

We described CNP as calcium phosphate (apatite) depositing nanoparticles in the size range of 100 -300 nm (2). Calcium-binding proteins from blood and tissues are immobilized in CNPs. Calcium phosphate deposition in soft tissue is common in inflammatory and autoimmune diseases, and is a threat for organ damage (3). Yet, apatite particles have recently been proposed for human use as a vehicle for vaccination, drug delivery, and stent medication (4). Apatite particles are also used as hard and soft tissue fillers and advocated as safe and biocompatible because apatite is present in human bones (4). However, apatite fillers frequently cause inflammation, macrophage infiltration and formation of giant multinucleated cells and fibrous capsule around the particles in soft tissue (4). Interestingly, the particles remain in their collagen-encapsulated stage for at least 5 years, without causing any soft tissue calcification beyond the original injected material (4). By analogy with WS's case report, insertion of apatite filler could very well cause long-term immunological activation towards proteins it can bind from the tissue and/or blood. Macrophage lineage cells ingest calcium phosphate particles potentially leading to elevated intracellular Ca^{++} levels that in turn activate the immune system and cause inflammation.

To date no extensive studies have been performed upon 'engineered' nanoparticles in relation to adsorption, biodistribution, metabolism and excretion. Potential toxic effects include oxidative stress, apoptosis, autoimmunity and thrombosis (5). Patients with silicosis and asbestosis develop macrophage-related problems and silicosis is often involving autoimmunity. Studies are needed for mechanisms of particle-mediated immunological reactions that are potentially pathogenic. Because of WS's documented strong immune response against CNP, we recommend testing and caution before using fine-grained apatite in applications requiring insertion into the human body.

Case Report for The Lancet

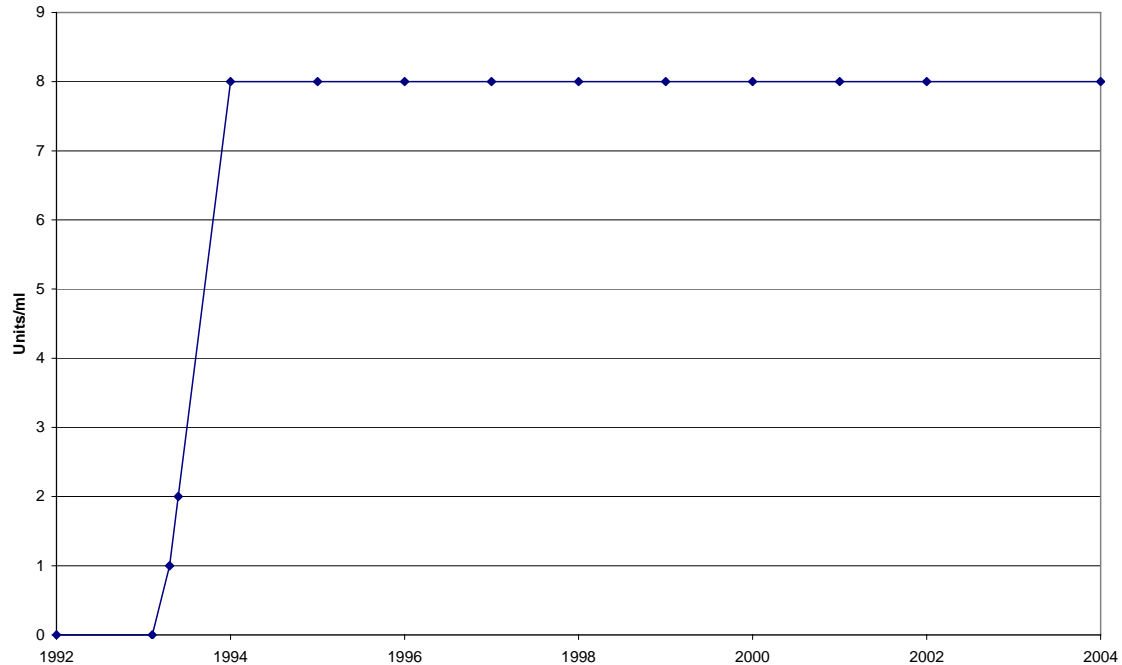


Figure. Follow-up of laboratory worker WS's anti-CNP antibodies during a 12 year-follow-up. Conjunctival pouch exposure to CNP occurred at 60 months. The ELISA test is performed for a serum dilution of 1:500. Measuring range is 0 – 8 Units/ml and values above 8 Units/ml are presented as 8.

References

- (1) Bergamaschi E, Bussolati O, Magrini A, Bottini M, Migliore L, Bellucci S, Iavicoli I, Bergamaschi A. Nanomaterials and lung toxicity: interactions with airways cells and relevance for occupational health risk assessment. *Int J Immunopathol Pharmacol*. 2006 Oct-Dec;19(4 Suppl):3-10.
- (2) Kajander EO, Ciftcioglu N. Nanobacteria: an alternative mechanism for pathogenic intra- and extracellular calcification and stone formation. *Proc Natl Acad Sci U S A*. 1998 Jul 7;95(14):8274-9.
- (3) Dalbeth N, Haskard DO. Inflammation and tissue damage in crystal deposition diseases. *Curr Opin Rheumatol*. 2005 May;17(3):314-8.
- (4) Marmur ES, Phelps R, Goldberg DJ. Clinical, histologic and electron microscopic findings after injection of hydroxyapatite filler. *J Cosmet Laser Ther* 2004 6: 223-226.
- (5) Arimura S, Kawahara K, Biswas KK, Abeyama K, Tabata M, Shimoda T, Ogomi D, Matsusaki M, Kato S, Ito T, Sugihara K, Akashi M, Hashiguchi T, Maruyama I. Hydroxyapatite formed on/in agarose gel induces activation of blood

Case Report for The Lancet

coagulation and platelets aggregation. J Biomed Mater Res Part B: Appl Biomater, 2006. DOI 10.1002/jbm.b.30684