



## Case Report

# Intralabyrinthine Vestibular Schwannoma Responsive to Intratympanic Gentamicin Treatment

Edoardo Covelli, Luigi Volpini, Chiara Filippi, Silvia Tarantini, Vania Marrone, Simonetta Monini, Maurizio Barbara

Department Neuroscience Mental Health and Sensory Organs (NESMOS), Sapienza University, Rome, Italy

**Cite this article as:** Covelli E, Volpini L, Filippi C, Tarantini S, Marrone V, Monini S, et al. Intralabyrinthine Vestibular Schwannoma Responsive to Intratympanic Gentamicin Treatment. *J Int Adv Otol* 2017; 13: 285-8.

Intralabyrinthine schwannoma (ILS) is a rare benign tumor that affects the ends of cochlear and vestibular nerves. In a majority of the cases, it occurs with unilateral progressive sensorineural hearing loss. Less frequent symptoms include tinnitus, imbalance, vertigo, or fullness. The advent of magnetic resonance imaging allows early diagnosis and enables an appropriate therapeutic protocol. This report describes a case of intravestibular schwannoma, with fluctuating hearing loss and intractable vertigo, treated with intratympanic gentamicin. The patient was a 28-year-old woman with intractable vertigo and fluctuating left-side hearing loss caused by left intravestibular schwannoma. Because surgery was temporarily rejected by the patient, a single dose of intratympanic gentamicin was administered. Following this, the patient showed a significant improvement in the symptoms. However, moderate to flat sensorineural hearing loss was also observed. Intratympanic gentamicin infiltration is a valid therapeutic option for patients with ILS, affected by intractable vertigo, when the patient refuses surgery.

**KEYWORDS:** Intralabyrinthine schwannoma, vertigo, intratympanic gentamicin, sensorineural hearing loss.

## INTRODUCTION

Intralabyrinthine schwannoma (ILS) is a rare benign tumor that affects the ends of cochlear and vestibular nerves. It involves the vestibule, cochlea, or semicircular canal<sup>[1]</sup>. ILS was first described by Meter in 1917 with a temporal bone study in a patient with Von Recklinghausen syndrome. In the same year, an autopsy-based report described a schwannoma isolated in the scala tympani of a patient with normal hearing<sup>[2]</sup>. ILS symptoms are rather unspecific. In a majority of cases it occurs with unilateral sensorineural hearing loss, which is frequently progressive and in some cases, sudden or fluctuating. Less frequent symptoms include tinnitus (51%), imbalance (35%), vertigo (22%), or fullness (2%), alone or in combination<sup>[3]</sup>. An accurate assessment for differential diagnosis from other inner ear disorders, such as Menière's disease or vestibular neuritis, is necessary. The lack of specific symptoms and slow growth pattern explain why the diagnosis is often delayed. Today, the advent of magnetic resonance imaging (MRI) allows early diagnosis, enabling an appropriate therapeutic protocol. The present report describes a case of intravestibular schwannoma confined to the vestibular cavity, without extension into the semicircular canals, with fluctuating hearing loss and intractable vertigo that demanded the use of intratympanic gentamicin.

## CASE PRESENTATION

A 28-year-old woman with intractable vertigo and fluctuating left-side hearing loss for 1 month was admitted to our clinic. There was no history of ear drainage or pain, and the otoscopic examination was negative on the left and right side. No spontaneous nystagmus was observed. Romberg test proved negative, and neurological functions were normal. Audiometric tests showed moderate sensorineural hearing loss at low frequencies (Figure 1a) and slight reduction of detection threshold without alteration in word discrimination on the left side (Figure 1b). Electrocochleography did not reveal a hydroptic component (summing potential/action potential=0.32). Video Head Impulse Test (vHIT) showed slight hyporeflexia on the affected side. Oral steroid treatment (1 mg/kg for 10 days) was immediately initiated with improvement of the patient's vertigo and hearing symptoms (Figure 2), which recurred at the end of the treatment. On enhanced T1-weighted images of a gadolinium-enhanced MRI (Gd-MRI), the presence of a 2x3 mm mass was observed to be confined to the vestibule on the left side without extension into the semicircular canals and with hyper-intensity on T2-weighted sequences (Figure 3a, b). Because surgery was temporarily excluded to avoid hearing loss and due to the patient's refusal, we proposed a single dose of 0.4 cc intratympanic gentamicin (40 mg/mL) [Gentamicina solfato, Fisipharma, Nucleo Industriale Palomonte (SA), Italy] buffered with sodium bicarbonate. The patient signed the informed consent form for treatment with intratympanic gentamicin. Following the treatment, the patient showed

**Corresponding Address:** Edoardo Covelli E-mail: [edoardo.covelli@uniroma1.it](mailto:edoardo.covelli@uniroma1.it)

**Submitted:** 02.07.2016

**Revision Received:** 02.05.2017

**Accepted:** 04.07.2017

©Copyright 2017 by The European Academy of Otolology and Neurotology and The Politzer Society - Available online at [www.advancedotology.org](http://www.advancedotology.org)

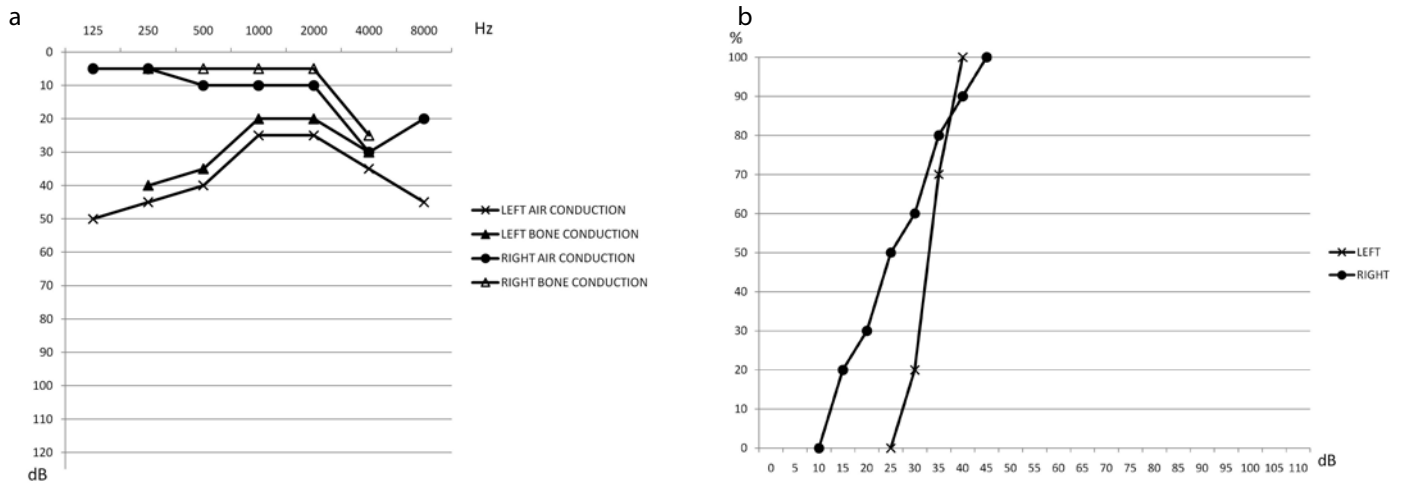


Figure 1. a, b. (a) Pure tone audiometry before treatment. (b) Headphone speech discrimination before treatment.

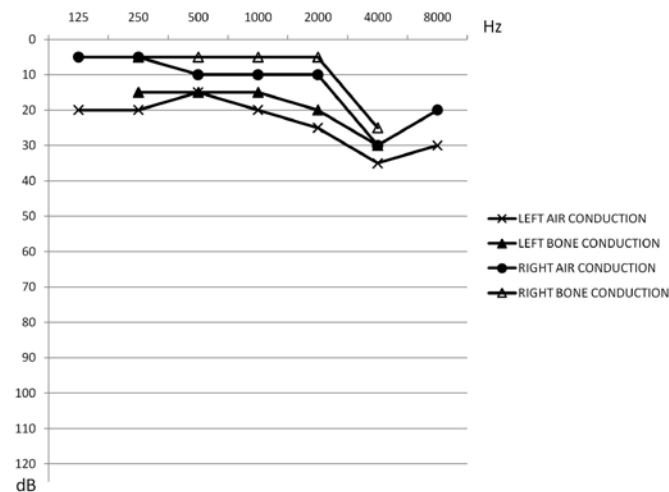


Figure 2. Pure tone audiometry after oral steroids.

a significant improvement in her symptoms with disappearance of vertigo. vHIT showed severe hyporeflexia on the affected side and contralateral normoreflexia; audiometric tests showed moderate, flat sensorineural hearing loss (Figure 4a) and a reduction in speech discrimination (90% at 85 dB) (Figure 4b). Vestibular symptoms were substantially unvaried. However, audiometric tests showed slight additional hearing and speech discrimination deterioration 3 months after treatment (Figure 5a, b). After 6 months, The patient reported no further vertigo episodes, a moderate improvement in hearing threshold, and speech discrimination of 90% at 60 dB (Figure 6a, b). After 1 year, she underwent an MRI that showed no growth of the tumor lesion (Figure 7) and stability of the auditory condition.

### DISCUSSION

Intralabyrinthine schwannoma is a rare pathology; however, its incidence has increased in recent years due to the advent of sophisticated imaging techniques. MRI is the current gold standard for its diagnosis, showing lesions with neat margins, hyperintense in T1 and hypointense in T2. MRI could be used for preoperative localization and surgical planning, as well as for following-up the eventual growth of tumors [1].

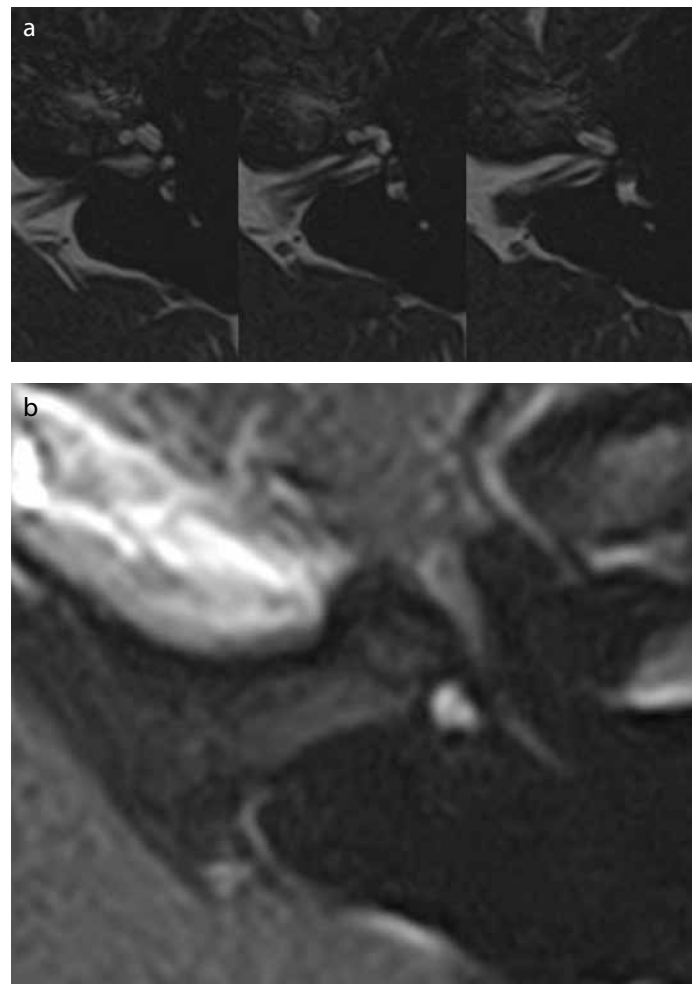


Figure 3. a, b. (a) Axial T1-weighted MR images show noticeable nodular vestibular mass enhancement after contrast administration. (b) Axial T2-weighted MR images of the internal auditory canal, cochlea, and eighth cranial nerve. It is possible to identify a lack of natural hyper-intense signal in the vestibule due to the presence of a small nodule.

Kennedy divided ILS into 7 types according to its localization: intracochlear, intravestibular, intracochleo-vestibular, transmacular, transmodiolar, tympano-labyrinthine, and transotic. In 2013, Van Abel et al. [3]

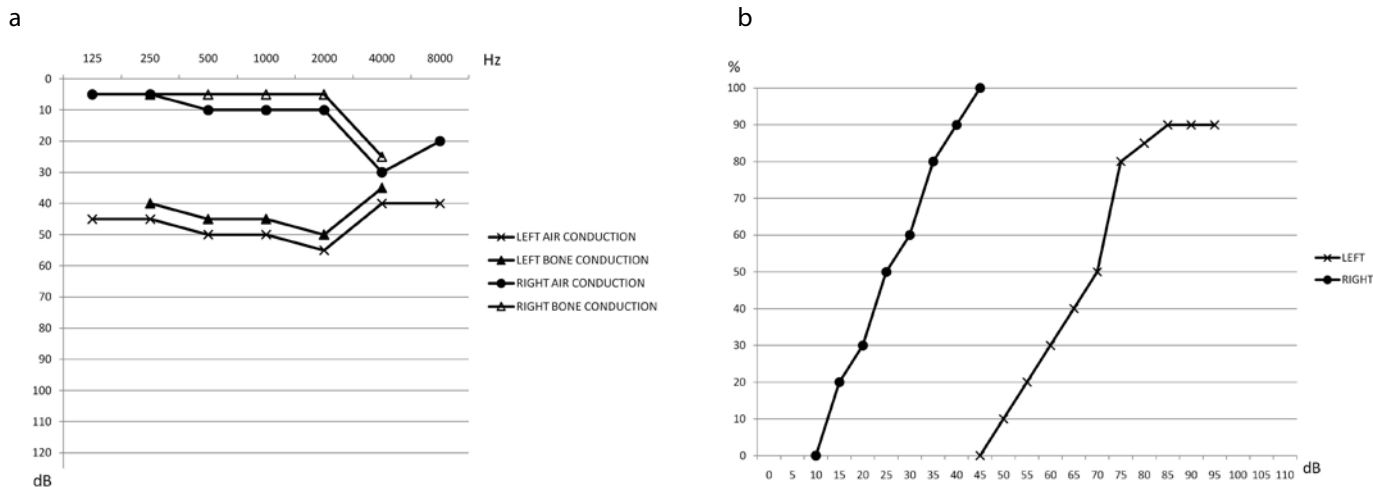


Figure 4. a, b. (a) Pure tone audiometry 1 month after gentamicin treatment. (b) Headphone speech discrimination 1 month after gentamicin treatment.

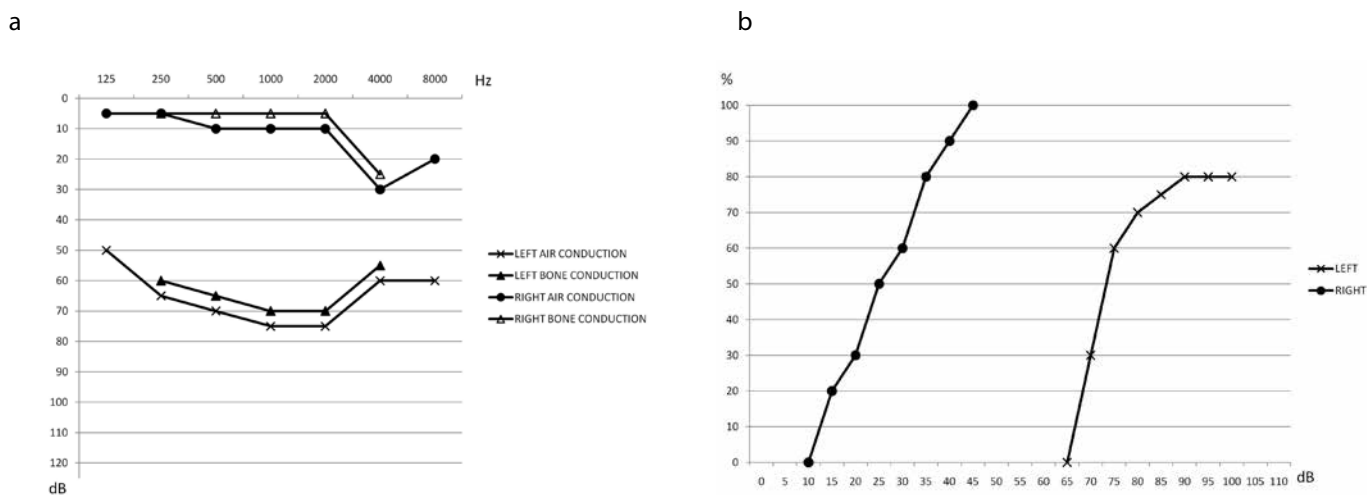


Figure 5. a, b. (a) Pure tone audiometry 3 months after gentamicin treatment. (b) Headphone speech discrimination 3 months after gentamicin treatment.

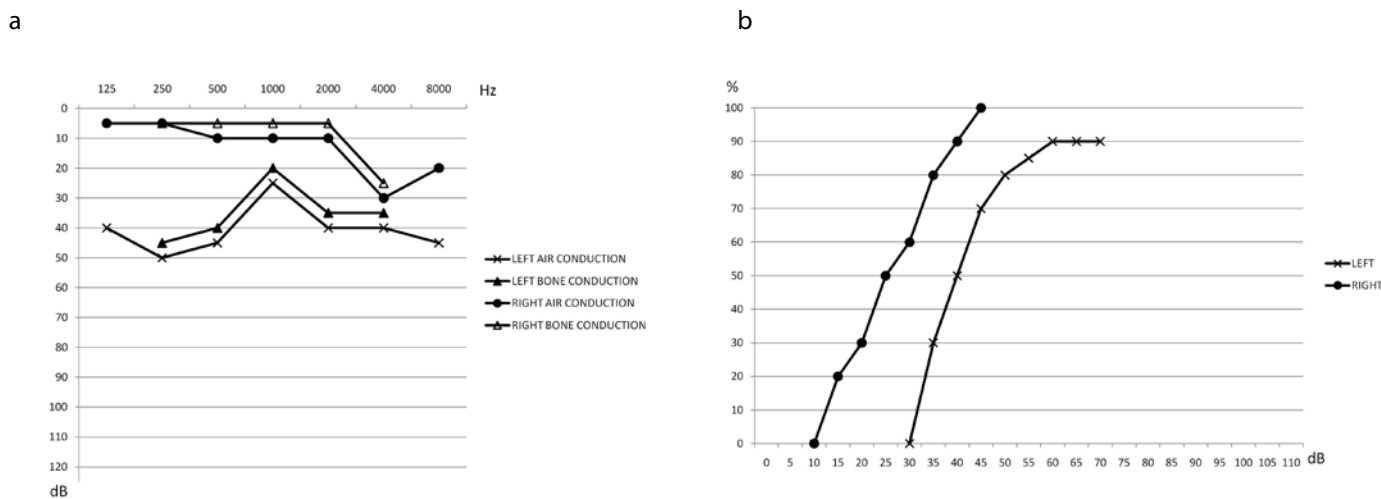



Figure 6. a, b. (a) Pure tone audiometry 6 months after gentamicin treatment. (b) Headphone speech discrimination 6 months after gentamicin treatment.



**Figure 7.** MRI After one year, which showed no growth of the tumor lesion

added 2 more types: trans-labyrinthine and transotic variant into the cerebellopontine angle.

Management options primarily include serial observations with MRI (wait and scan approach) because this tumor usually grows very slowly and with few symptoms.

Surgical removal is reserved to a limited number of cases and mostly depends on age, general condition of the patient, tumor size, location and growth (into the internal auditory canal or middle ear), and the presence of intractable symptoms (vertigo). Surgical ablative treatment would result in total hearing loss in 100% of cases, with some likelihood of facial nerve palsy in 4% of cases, cerebrospinal fluid leakage in 5.4% of cases, and meningitis in 1.8% of cases [4]. In a recent review regarding ILS, among 53% of patients (109 of 189) observed using serial MRI scans, only 3% required surgical removal [3], supporting the adoption of the wait and scan approach.

To the authors' knowledge, only 2 patients have been reported to receive stereotactic radiosurgery for ILS. This treatment has the same indication as surgical treatment and is mostly indicated for those patients who cannot undergo surgery due to general counter-indications. However, it does not seem to be effective for vertigo, adding to the possibility of neurological effects and malignant transformations of the tumor [5].

Transtympanic steroid injection has also been reported in a patient with ILS and sudden sensorineural hearing loss, without vertigo or dizziness [6]. The patient of the present report presented with intractable vertigo and fluctuating left-side hearing loss. Therefore, after the patient refused surgery, a single-dose of 40 mg/ml intratympanic gentamicin was administered. Intratympanic gentamicin is widely used for the control of vertigo in most Ménière's patients, with reported success rates of 83%–91% [7].

Gentamicin has a high affinity for type I vestibular hair cells (dark cells), and therefore, produces relatively more vestibular impairment than hearing loss [8]. In 2014, Daneshi et al. [9] showed that one-shot low dos-

age gentamicin causes complete vertigo cessation in 58.3%. In 2001, Magnusson treated a group of patients with brainstem tumors with remaining vestibular function, who required surgery, with trans-tympanic gentamicin injection before tumor surgery and then performed "prelesion rehabilitation" to ease postoperative symptoms [10].

In our case, gentamicin infiltration treatment provided excellent results for vestibular symptoms. However, a noxious effect on hearing is possible without the possibility to stop tumor growth. Consequently, accurate MRI follow-up to monitor tumor growth development is essential for patients who are suited for this treatment.

The disappearance of vestibular symptoms after gentamicin administration could also be attributed to the action of central compensation mechanisms. However, central compensation usually occurs after a longer period than the appearance of the symptoms. In the case described above, the disappearance of the symptoms occurred immediately after the administration of gentamicin and this implies that it is related to the effect of the treatment.

**Informed Consent:** Written informed consent was obtained from patient who participated in this study.

**Peer-review:** Externally peer-reviewed.

**Author Contributions:** Concept - E.C., M.B.; Design - E.C.; Supervision - M.B.; Resources - S.M., C.F.; Materials - E.C., L.V., V.M.; Data Collection and/or Processing - S.T., V.M. Analysis and/or Interpretation - C.F., M.B.; Literature Search - C.F., L.V., S.M.; Writing Manuscript - E.C., C.F.; Critical Review - E.C., L.V., M.B.; Other - V.M., S.T.

**Conflict of Interest:** No conflict of interest was declared by the authors.

**Financial Disclosure:** The authors declared that this study has received no financial support.

## REFERENCES

1. Doyle KJ, Brackmann DE. Intralabyrinthine Schwannomas. *Otolaryngol Head Neck Surg* 1994; 110: 517-23.
2. Nager FR. Zur Anatomie der endemischen Taubstummheit (mit einem Neurofibrom der Schneckenwindel). *Z Ohrenheilkd* 1917; 75: 349-64.
3. Van Abel KM, Carlson ML, Link MJ, Neff BA, Beatty CW, Lohse CM, et al. Primary inner ear schwannomas: a case series and systematic review of the literature. *Laryngoscope* 2013; 123: 1957-66.
4. Grayeli AB, Fond C, Kalamarides M, Bouccara D, Cazals-Hatem D, Cyna-Gorse F, et al. Diagnosis and management of intracochlear schwannomas. *Otol Neurotol* 2007; 28: 951-7.
5. Miller ME, Moriarty JM, Linetsky M, Lai C, Ishiyama A. Intracochlear schwannoma presenting as diffuse cochlear enhancement: diagnostic challenges of a rare cause of deafness. *Ir J Med Sci* 2012; 181: 131-4.
6. Iseri M, Ulubil SA, Topdag M, Oran A. Hearing loss owing to intralabyrinthine schwannoma responsive to intratympanic steroid treatment. *J Otolaryngol Head Neck Surg* 2009; 38: E95-7.
7. Bodmer D, Morong S, Stewart C, Alexander A, Chen JM, Nedzelski JM. Long term vertigo control in patients after intratympanic gentamicin instillation for Ménière's disease. *Otol Neurotol* 2007; 28: 1140-4.
8. Lyford-Pike S, Vogelheim C, Chu E, Della Santina CC, Carey JP. Gentamicin is primarily localized in vestibular type I hair cells after intratympanic administration. *J Assoc Res Otolaryngol* 2007; 8: 497-508.
9. Daneshi A, Jahandideh H, Pousti SB, Mohammadi S. One-shot, low-dosage intratympanic gentamicin for Ménière's disease: Clinical, posturographic and vestibular test findings. *Iran J Neurol* 2014; 13: 33-9.
10. Magnusson M, Karlberg M, Tjernstrom F. "PREAHAB": Vestibular prehabilitation to ameliorate the effect of a sudden vestibular loss. *Neuro Rehabilitation* 2011; 29: 153-6.