

The Vascular architecture. Phlebosomes do they exist ?

A Caggiati*

* Department of Anatomy, Sapienza University of Rome, Italy.

presented to: the Hemodyn2015, Nov 2015, Naples, Italy

submitted: May 18, 2016, accepted: Jul 11, 2016, EPub Ahead of Print: Nov 30, 2016, published: Dec 31, 2016

Conflict of interest: None

Corresponding author: Prof. Alberto Caggiati, alberto.caggiati@uniroma1.it

© 2016 Fondazione Vasculab impresa sociale ONLUS. All rights reserved.

Abstract The angiosome is a 3D structure which is perfused by a single perforating artery (arteriosome) and drained by a perforating vein (venosome). The concept of arteriosome is applied in plastic surgery and in the revascularization of ischemic limbs. Each venosome is also drained by longitudinal veins running in the subcutaneous layer. Accordingly, the concept of venosome cannot be applied in the field of the venous disorders of the limbs. The concept of phlebosome consider both paths of venous drainage.

Keywords angiosome, arteriosome, venosome, phlebosome

The integuments are perfused by perforating arteries running along muscular septa before piercing the muscular fascia. Each artery perfuses a limited area of skin surface with the underlying subcutaneous fat. This block is called "arteriosome". At the boundaries of each arteriosome are vessels connecting the peripheral arteries of neighboring blocks. The concept of arteriosome is applied in the daily

recently in the revascularization of ischemic limbs .

A similar arrangement was described with respect of the drainage of the cutaneous and subcutaneous layers¹. A perforating vein drains the plexuses of small veins running parallel to the skin surface into the dermis and into the subcutaneous layer (Figure 1).

These veins are valvulated and converge from all direction to form the root of the perforating vein. This vascular structure is more commonly stellate or medusoid

in shape, similarly to saphenous tributaries at the Sapheno-Femoral Junction. In other body areas, the collecting veins are polarized in one direction, as typically in the lateral thigh (Figure 2).

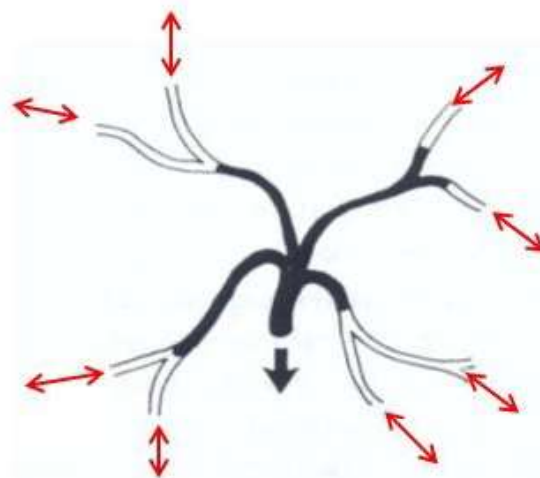


Figure 1 - bidirectional avaluvalated veins in red.

Differences in the arrangement and polarization of collecting veins are related to the location, structure, function, embryological growth and differentiation¹.

The valvulated perforator drains the same block of cutaneous and subcutaneous tissues perfused by the corresponding perforating artery. This territory was named "venosome"¹. At the boundaries of each venosome, avaluvalated veins connect the peripheral valvulated vein

of adjacent blocks. These veins, were defined "oscillating veins" because "...they allow free flow between the valvulated channels of adjacent venosomes, whose valves are oriented in an opposite direction..."¹.



Figure 2 - The collecting vein polarizes blood flow toward deeper veins.

The subdivision of the integuments in venosomes is related to the arrangement of the venous system in the embryo: the limb bud is drained by perforating veins which confluence into the primordial cardinal veins. In the next phase of embryo development, veins running along the major axis of the limb develop in the subcutaneous layer: firstly the (medial and lateral) marginal veins, then the great saphenous veins with their parallel accessories.

These subcutaneous longitudinal veins play a predominant role in the drainage of the limb bud until the development of the deep ones, and actively participate to the drainage of venosomes . At the end of the first trimester of intrauterine life the deep veins develop (firstly the sciatic, than the femoral) and the hemodynamic role of the longitudinal subcutaneous veins progressively reduces.

However in the adult a double systems of blood drainage persists: a vertical system (saphenous accessories, saphenous veins, the lateral plexus) and a transverse system (perforators). (Figure 3) This is why, at least in the inferior limb, the vascular arrangement of venosomes does not mirror that of arteriosomes. Moreover, the hemodynamic changes observed in pathological conditions (i.e., varicose disease) are not ascribable to the simple architecture of venosomes. For this reason, the term "phlebosome" looks to better correspond to the venous architecture

of the cutaneous and subcutaneous layers in the lower limbs. These structures are simultaneously drained by both perforating and longitudinal subcutaneous veins systems.

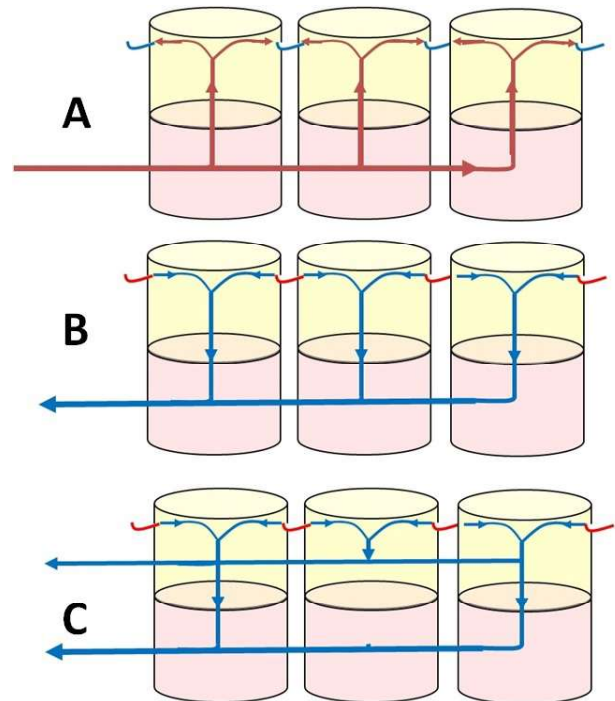


Figure 3 - A) the architecture of arteriosomes. Oscillating vessels in blu B) the architecture of venosomes. Avalvulated oscillating veins in red. C) the architecture of phlebosomes.

The peripheral arcades converge toward the respective perforator which pierces the muscular fascia to reach a deep vein. In other cases, it pierces the saphenous fascia to be drained by the saphenous veins. The peripheral arcades of each phlebosome are also connected by avalvulated veins to the peripheral ones of the neighboring phlebosomes (Figure 4). These avalvulated veins are responsible for equilibration of flow and pressure between neighboring phlebosomes.

In greater part of the phlebosomes of the inferior limbs it looks that the draining role of the perforator is overshadowed by that of the subcutaneous longitudinal vessels. This especially along the medial face of the limb and the posterior leg due to the presence of the saphenous veins. In greater part of varicose limbs, the venous changes are related to pathologic changes of longitudinal subcutaneous veins (Figure 5). Only in few cases, it is possible to observe a topographic relationship of signs and symptoms to a single "phlebosome": 1) the corona flebectatica, 2) the clusters of varicose veins originating from an incompetent perforator (escape point) and finally, 3) varicose vein of the lateral thigh drained by a lateral perforator.

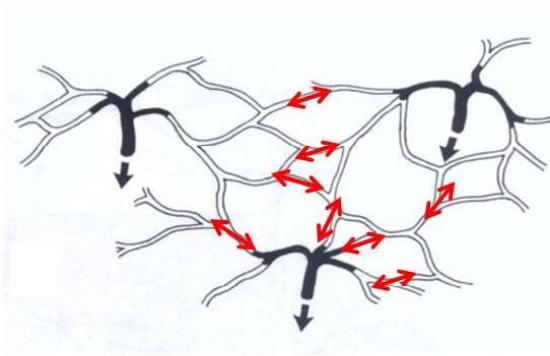


Figure 4 - Avalvulated oscillating veins connect the peripheral veins of neighboring venosomes.

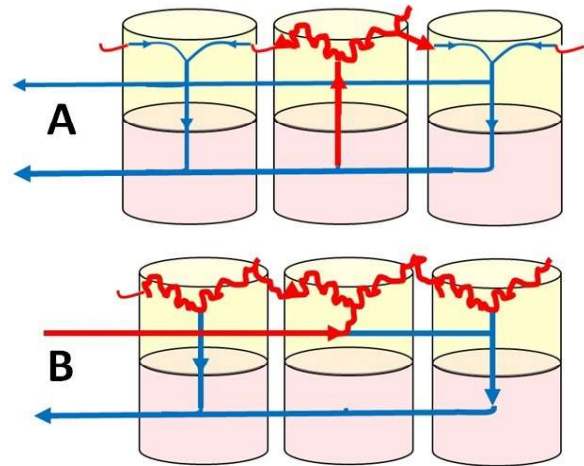


Figure 5 - A) reflux from an incompetent perforator with varicose veins limited to the related phlebosome. B) reflux from a longitudinal vein with varicose veins extended to same phlebosomes and drained by re-entry perforators.

References

- 1) Taylor GI, Caddy CM, Watterson PA, Crock JG. The venous territories (venosomes) of the human body: experimental study and clinical implications. *Plast Reconstr Surg* 1990 Aug;86(2):185-213.
- 2) Zheng XT, Zeng RC, Huang JY, Pan LM, Su X, Wu ZH, Yu GF. The Use of the Angiosome Concept for Treating Infrapopliteal Critical Limb Ischemia through Interventional Therapy and Determining the Clinical Significance of Collateral Vessels. *Ann Vasc Surg*. 2016 Apr;32:41-9. doi: 10.1016/j.avsg.2015.09.021.
- 3) Alexandrescu V. Angiosomes applications in critical limb ischemia. *Minerva Medica*, Torino, 2012. ISBN-13 978-88-7711-766-3.
- 4) Venermo M. Angiosome concept in the treatment of critical limb ischaemia. *Vascular News*, 21st June 2016. Available at <http://vascularnews.com/angiosome-concept-in-the-treatment-of-critical-limb-ischaemia/> at the date of May 18, 2016.