

Classification of Chimney EVAR-Related Endoleaks: Insights From the PERICLES Registry

Journal of Endovascular Therapy
 2017, Vol. 24(1) 72–74
 © The Author(s) 2016
 Reprints and permissions:
 sagepub.com/journalsPermissions.nav
 DOI: 10.1177/1526602816678994
 www.jevt.org
 SAGE

Konstantinos P. Donas, MD^{1,2}, Frank J. Criado, MD³, Giovanni Torsello, MD^{1,2}, Frank J. Veith, MD^{4,5}, and David J. Minion, MD,⁶ on behalf of the PERICLES Registry Collaborators

Keywords

abdominal aortic aneurysm, chimney graft, chimney technique, endograft, endoleak, stent-graft

Juxtarenal aortic aneurysms (JAAs) pose significant challenges for endovascular aneurysm repair (EVAR). A short or absent infrarenal neck typically excludes standard EVAR as a viable or reasonable treatment option. In this context, the use of chimney grafts (chEVAR) is gaining in popularity and applicability.^{1–12} These grafts are designed to course in the aortic lumen outside the main stent-graft to maintain normal perfusion to the involved target branches. As such, they may represent a promising and less resource-intensive option for management of JAAs. However, this technical strategy is not without challenges of its own, particularly the inevitable creation of “gutters” that result from the interaction of the chimney graft with the main aortic stent-graft. These gutters can become a conduit for type Ia endoleak formation, hence they represent the Achilles’ heel of chEVAR. Current reports point to a relatively wide-ranging incidence (0%–13%) of type Ia endoleaks related to chEVAR.⁸

The PERICLES Registry⁴ collected the global transatlantic experience of 13 European and US vascular centers reporting 517 patients with complex aneurysms treated with EVAR and chimney parallel grafts. Overall, 6% of PERICLES chEVAR patients had a type Ia endoleak at completion angiography,⁴ but the rate of persistent endoleaks was only 2.9% at a mean 17.1 months of follow-up.⁴ Close review of the postoperative computed tomography angiograms of these persistent endoleak patients revealed distinct types and patterns of chEVAR-related type Ia endoleaks and form the basis of a new classification proposed herein. It is hoped that these observations will lead to development of new treatment algorithms for effective management of chimney-related endoleaks and, in some cases, to prevent them from occurring in the first place.

Pattern A: Excessive Stent-Graft Oversizing (Figure 1)

Stent-graft oversizing by >30% compared with the diameter of the suprarenal aorta or malapposition to the aortic wall

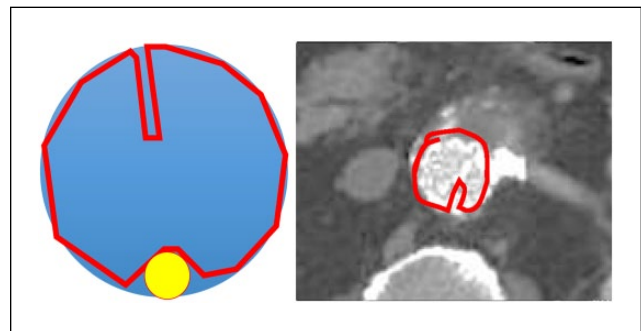


Figure 1. Pattern A: Infolding of the aortic stent-graft from excessive oversizing.

often leads to infolding of the endograft in the neck area and consequent type Ia endoleak. The observed cases of pattern A did not exhibit significant enlargement of the aneurysm sac, so conservative management of these patients with close imaging surveillance alone may be appropriate. If an

¹Department of Vascular Surgery, St Franziskus Hospital Münster, Germany

²Clinic of Vascular and Endovascular Surgery, University of Münster, Germany

³Division of Vascular Surgery, MedStar Union Memorial Hospital, Baltimore, MD, USA

⁴Department of Vascular Surgery, New York University Langone Medical Center, New York, NY, USA

⁵The Cleveland Clinic, Cleveland, OH, USA

⁶Department of Vascular Surgery, University of Kentucky, Lexington, KY, USA

Editorials published in the *Journal of Endovascular Therapy* reflect the opinions of the author(s) and do not necessarily represent the views of the *Journal*, the International Society of Endovascular Specialists, or SAGE Publications Inc.

Corresponding Author:

Konstantinos P. Donas, Department of Vascular Surgery, St. Franziskus Hospital Münster, Hohenzollernring 72, 48145 Münster, Germany.
 Email: konstantinos.donas@gmail.com

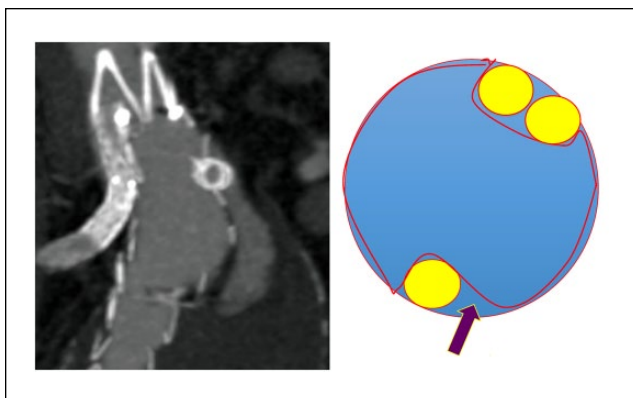


Figure 2. Pattern B: Undersized aortic stent-graft.

intervention is deemed necessary, reasonable first steps would be embolization using liquid agents or kissing-balloon dilation, with simultaneous inflation of balloons inserted in the main stent-graft and inside the chimney graft.

Pattern B: Insufficient Stent-Graft Oversizing (Figure 2)

Endoleaks have occurred as a result of excessive gutter formation caused by inadequate stent-graft oversizing. For instance, performing chEVAR with a 36-mm diameter aortic stent-graft when the pararenal seal zone measures 31 mm in diameter risks creating large gutters and a poor seal since the oversizing is <20%. This leaves insufficient excess stent-graft material to wrap around the chimney graft. Patients with pattern B endoleaks appear to have a proximal seal zone of sufficient length (ie, at least 20 mm); however, minimal stent-graft oversizing leads to the formation of excessive gutters and endoleaks. This is especially problematic when placing multiple chimney grafts.

The minimum amount of oversizing necessary is still controversial, and we hope to better delineate optimal sizing with further sophisticated evaluation of the PERICLES results. In general, 20% to 30% oversizing is recommended for standard chimney grafts to minimize the gutters without excessive infolding. The necessary amount of oversizing is less if the chimney graft is molded into an oval or lens shape.¹² Postimplantation management of pattern B endoleaks can be achieved through gutter embolization (using plugs, coils, and/or liquid agents), but expansion of the seal zone may also be required.

Pattern C: Inadequate Seal Zone Length (Figure 3)

The presence of a short sealing zone in chEVAR can result in early type Ia endoleak or predispose to downward migration of the abdominal device and delayed type Ia endoleak.

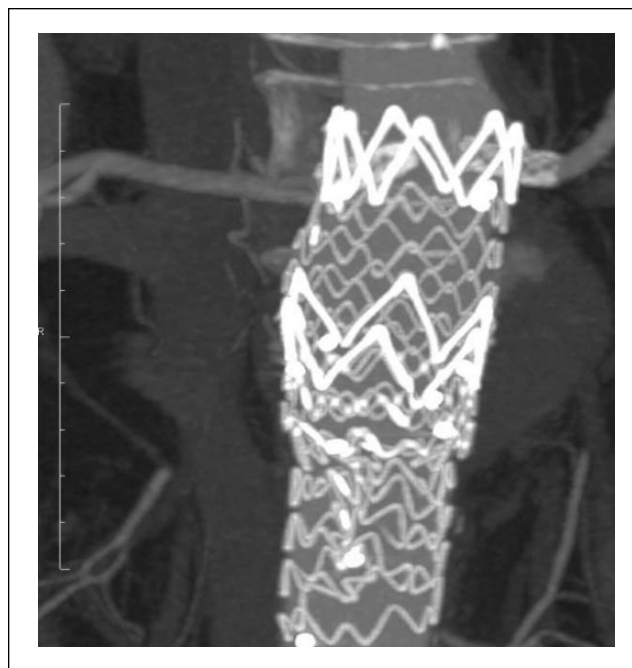


Figure 3. Pattern C: Inadequate sealing length, in this case, leading to migration of the abdominal stent-graft in a para-anastomotic aneurysm following open surgical repair 4 years previously.

Progressive degeneration and dilatation of the neck in a short seal zone can have the same result. Figure 3 illustrates a migrated tube endograft after single chimney graft placement in the left renal artery (in a para-anastomotic aneurysm following open surgical repair 4 years previously). The chEVAR seal zone measured only 9 mm in length. It should be emphasized that both the PERICLES⁴ and PROTAGORAS⁵ studies recommended a 20-mm minimum proximal sealing length to achieve durable results with this technique. When pattern C chEVAR endoleaks occur, the proximal fixation-seal zone must be extended upward, with implantation of additional chimney grafts as needed.

Conclusion

Systematic scrutiny of the large PERICLES patient cohort enhanced our understanding of chEVAR gutter-related endoleaks, and we have herein proposed a new classification that describes 3 distinct patterns for these phenomena and specific technical modifications for endoleak prevention or treatment. We encourage other authors to scrutinize their own chEVAR gutter-related type I endoleaks and determine if they show some of the same patterns. And ultimately, as experience grows, these concepts and new insights will hopefully lead to better techniques and optimal graft sizing strategies that will minimize their occurrence and help implement best management approaches when the problem is detected after EVAR.

Appendix

Additional PERICLES Collaborators: Zurich, Switzerland: Mario Lachat, Felice Pecoraro, Thomas Pfammatter; Münster, Germany: Theodosios Bisdas, Martin Austermann, Yukun Li; Rome, Italy: Nicola Mangialardi, Sonia Ronchey, Stefano Fazzini; Tampere, Finland: Suominen Velipekka, Juha Salenius; Chemnitz, Germany: Sven Seifert; Stanford, CA, USA: Jason T. Lee, Ronald Dalman, Kenneth Tran; Gainesville, FL, USA: Salvatore T. Scali, Adam W. Beck; Philadelphia, PA, USA: Scott M. Damrauer; Trieste, Italy: Roberto Adovasio, Fabio Pozzi Mucelli; Udine, Italy: Daniele Gasparini, Paolo Frigatti; Barcelona, Spain: Vincent Riambau, Gaspar Mestres; Ourense, Spain: Nilo Mosquera.

Declaration of Conflicting Interests

The author(s) declared no potential conflicts of interest with respect to the research, authorship, and/or publication of this article.

Funding

The author(s) received no financial support for the research, authorship, and/or publication of this article.

References

- Greenberg RK, Clair D, Srivastava S, et al. Should patients with challenging anatomy be offered endovascular aneurysm repair? *J Vasc Surg.* 2003;38:990–996.
- Criado FJ. Chimney grafts and bare stents: aortic branch preservation revisited [letter]. *J Endovasc Ther.* 2007;14:823–824.
- Lindblad B, Bin Jabr A, Holst J, et al. Chimney grafts in aortic stent grafting: hazardous or useful technique? Systematic review of current data. *Eur J Vasc Endovasc Surg.* 2015;50:722–731.
- Donas KP, Lee JT, Lachat M, et al. Collected world experience about the performance of the snorkel/chimney endovascular technique in the treatment of complex aortic pathologies: the PERICLES registry. *Ann Surg.* 2015;262:546–553.
- Donas KP, Torsello GB, Piccoli G, et al. The PROTAGORAS study to evaluate the performance of the Endurant stent graft for patients with pararenal pathologic processes treated by the chimney/snorkel endovascular technique. *J Vasc Surg.* 2016;63:1–7.
- Donas KP, Eisenack M, Panuccio G, et al. The role of open and endovascular treatment with fenestrated and chimney endografts for patients with juxtarenal aortic aneurysms. *J Vasc Surg.* 2012;56:285–290.
- Schiro A, Antoniou GA, Ormisher D, et al. The chimney technique in endovascular aortic aneurysm repair: late ruptures after successful single renal chimney stent grafts. *Ann Vasc Surg.* 2013;27:835–843.
- Katsargyris A, Oikonomou K, Klonaris C, et al. Comparison of outcomes with open, fenestrated, and chimney graft repair of juxtarenal aneurysms: are we ready for a paradigm shift? *J Endovasc Ther.* 2013;20:159–169.
- Lachat M, Bisdas T, Rancic Z, et al. Chimney endografting for pararenal aortic pathologies using transfemoral access and the lift technique. *J Endovasc Ther.* 2013;20:492–497.
- Usai MV, Torsello G, Donas KP. Current evidence regarding chimney graft occlusions in the endovascular treatment of pararenal aortic pathologies: a systematic review with pooled data analysis. *J Endovasc Ther.* 2015;22:396–400.
- Donas KP, Telve D, Torsello G, et al. Use of parallel grafts to save failed prior endovascular aortic aneurysm repair and type Ia endoleaks. *J Vasc Surg.* 2015;62:578–584.
- Minion D. Molded parallel endografts for branch vessel preservation during endovascular aneurysm repair in challenging anatomy. *Int J Angiol.* 2012;21:81–84.