

# A New System for Choosing the Form and Size of Complete Denture Anterior Teeth

Dario Melilli, Fabio Calandra<sup>1</sup>, Pietro Messina, Giuseppe A. Scardina

Department of Surgical, Oncological and Oral Sciences, University of Palermo, Palermo, <sup>1</sup>Dental Technician, Modena, Italy

## Abstract

**Introduction:** In the absence of pre-extraction records, the choice of the size and form of anterior complete denture teeth can be extremely subjective. Several clinical and statistical parameters are usually used for choosing the correct size and form of the complete denture anterior teeth. **Clinical Innovation:** The technique consists of a system that allows the dentist to choose and, if necessary, easily change the dental mold during maxillomandibular recording session. The unique feature of the system is that six teeth of each mold are represented by veneers, which are connected to each other on the lingual surface by a fiber that allows each veneer some degree of movement. **Discussion:** This technique allows the three-dimensional verification of the patient's esthetics and realistic phonetic test during the session of maxillomandibular records; if necessary, the dentist may easily replace the mold with a different one in form or size, without working the wax to move or replace a tooth.

**Key words:** Artificial teeth, clinical technique, complete dentures, dental aesthetics, oral rehabilitation

## INTRODUCTION

The correct choice and placement of artificial teeth play an important role in success when a patient is rehabilitated with a complete denture. Most of the issue concerning the esthetics of a complete denture depends on the correct vertical dimension, correct tooth position, and right choice of the artificial anterior teeth, which should be appropriate for the patient in color, size, and form.

The parameters to be considered in color selection of complete dentures, in addition to age and gender,<sup>[1-3]</sup> are extraoral characteristics, such as the color of the skin,<sup>[4]</sup> eyes, and hair.<sup>[3]</sup>

In the absence of pre-extraction records, the choice of the dental size and form can be extremely subjective and often is entrusted to the dental technician, who can refer only to the recorded lines on the wax rim.

Regarding the size of anterior teeth, several methods using clinical and statistical parameters have been proposed. In fact, clinical statistical methods can be useful in the absence of individual reference parameters for teeth dimensions. Some studies have demonstrated that, statistically, the size of some parts of the face have a proportional relationship to the dimensions of the upper central incisors or with the six anterior teeth. So, historically, the

width of the maxillary central incisor has been correlated with bizygomatic distance,<sup>[5-7]</sup> or with the interpupillary distance,<sup>[8]</sup> or with the intercanthal distance,<sup>[9-11]</sup> other authors have compared the distance between the maxillary canines with intercommissural distance,<sup>[12-15]</sup> or with the distance between the wings of the nose,<sup>[16,17]</sup> or with the intercanthal distance.<sup>[15]</sup>

The form of the anterior teeth can be chosen based on information obtained from photographs at a time when the patient had natural teeth or by statistical methods.

In general, teeth form varies depending on race<sup>[18]</sup> and gender;<sup>[19]</sup> triangular forms with curved edges and rounded corners are considered female characteristics, whereas pronounced angles are male characteristics.<sup>[19]</sup> However, Sellen *et al.* showed that there was little consistency in the selection of the shade, mold, and arrangement of anterior teeth appropriate for the age and gender of an individual, even by qualified dental staff.<sup>[20]</sup>

According to Williams, the incisors mimic the form of an upside down face, indicating three classes of teeth, namely,

**Address for correspondence:** Dr. Dario Melilli, Department of Surgical, Oncological and Oral Sciences, University of Palermo, Via del Vespro 129, 90127, Palermo, Italy  
E-mail: melilli@odonto.unipa.it

This is an open access article distributed under the terms of the Creative Commons Attribution-NonCommercial-ShareAlike 3.0 License, which allows others to remix, tweak, and build upon the work noncommercially, as long as the author is credited and the new creations are licensed under the identical terms.

**For reprints contact:** reprints@medknow.com

**How to cite this article:** Melilli D, Calandra F, Messina P, Scardina GA. A new system for choosing the form and size of complete denture anterior teeth. *Dent Hypotheses* 2016;7:147-51.

### Access this article online

#### Quick Response Code:



**Website:**  
[www.dentalthypotheses.com](http://www.dentalthypotheses.com)

**DOI:**  
10.4103/2155-8213.195974

class I (square), class II (triangular), and class III (oval).<sup>[21]</sup> This concept was not confirmed by Mavroskoufis and Ritchie as well as by Bell, who noted the lack of a correlation between facial and maxillary central incisor form.<sup>[22,23]</sup>

There is no standardized, repeatable scientific method for choosing dental size and form. Consequently, statistical parameters, clinical, and esthetic sense, with the patient's input, are helpful during the try-in phase of rehabilitation, although one study showed that the esthetic preferences of the patient and dentist differed in most cases.<sup>[24,25]</sup>

This article presents a new system for selecting complete denture anterior teeth, the Dental Veneers Selection Form (Dental VSF, European Patent EP 2759278);<sup>[26]</sup> it allows quick visualization of the final esthetic result in a realistic, three-dimensional manner during the maxillomandibular recording session. The described system is a prototype, an idea to be submitted to manufacturers of artificial teeth, to make it easier for the dentist to choose the set-up for the teeth of the anterior group. The manufacturer would produce a kit with the forms and the dimensions of its product line.

### Clinical Innovation

After the impressions sessions, the dental technician makes the denture bases with wax rim. At the end of the maxillomandibular recordings session, the dentist chooses the most suitable dental molds for the upper and lower denture, using the Dental VSF kit. This kit consists of 18 maxillary and 6 mandibular anterior molds [Figure 1]. The molds differ, similar to the traditional molds present in the market, in dimensions and form. The unique feature of the system is that six teeth of each mold are represented by veneers, which are connected to each other on the lingual surface

surface by a fiber that allows each veneer some degree of movement [Figures 2 and 3,]. During the esthetic and phonetic test, the most suitable dental mold in size and form is chosen; hence, the anterior wax rim is removed from the right to the left canine and the chosen dental mold is placed for the aesthetic try-in [Figures 4 and 5].

An "artificial gum" made from wax can be produced and made to adhere to the base of the denture in order to make the aesthetic appearance of the chosen mold more effective.

At this moment it is possible to provide the appropriate horizontal and vertical overlap, to change, if necessary, the

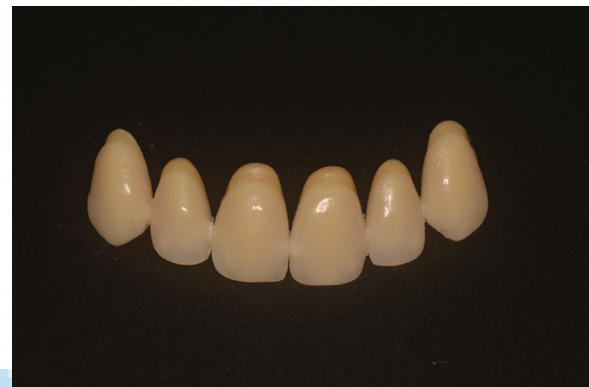

Figure 2: Dental mold of the Dental Veneers Selection Form

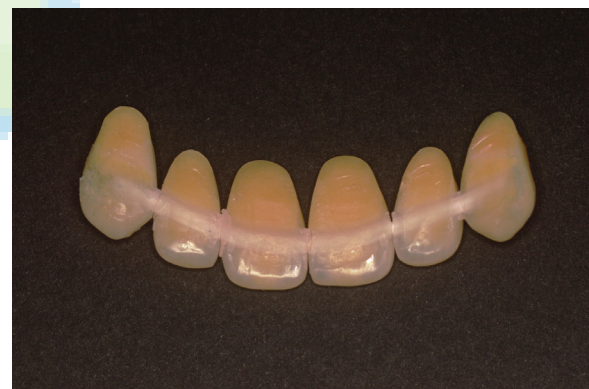

Figure 3: Teeth of the mold are represented by veneers connected to each other on the lingual surface by a fiber



Figure 1: Dental molds of the Dental VSF system. At the centre of the kit an example of radiopaque dental mold, useful for radiological template, is shown

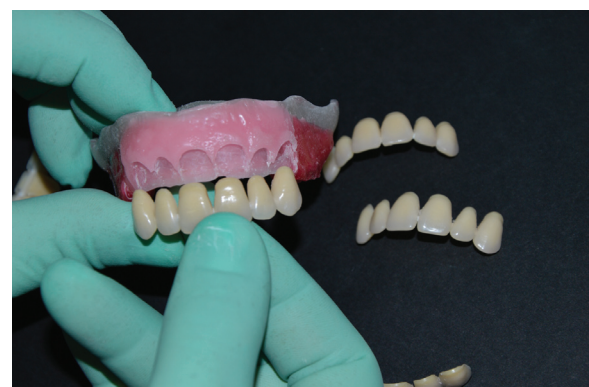
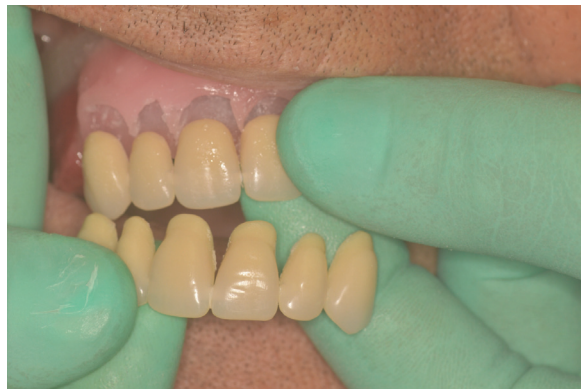
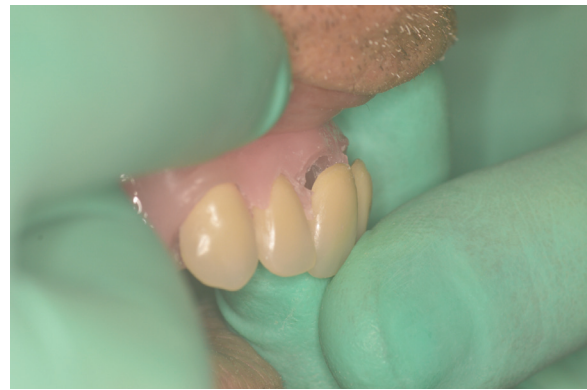Figure 4: A dental mold is chosen and placed for the esthetic try-in



**Figure 5:** The dental mold may be changed with another from the system



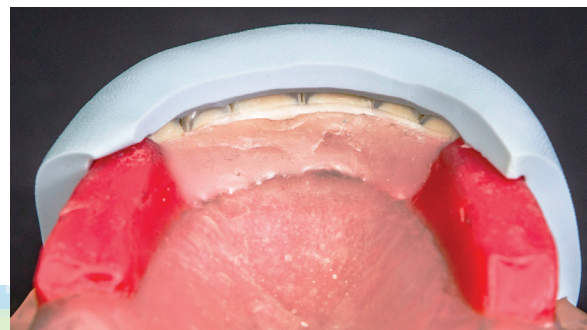
**Figure 6:** The tilt of a singular tooth may be changed to individualize the denture

tilt of a single tooth, to individualize the denture with some characterization [Figure 6], and to verify the patient's esthetics and phonetics. If not satisfied, the mold could be replaced with a different one without working the wax to move or replace each tooth, saving chair time.

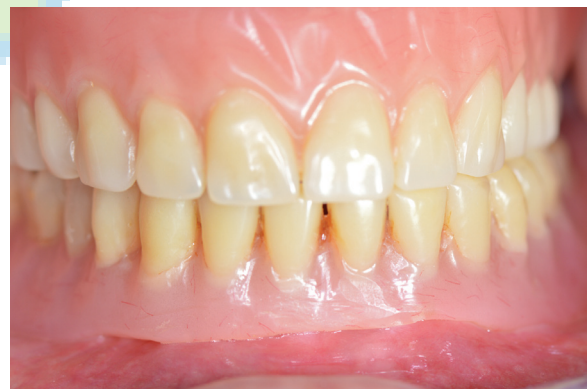After the esthetic and phonetic tests, the technician makes a silicone template to record all the information sent to him, to be able to place the dental mold corresponding to that chosen with the Dental VSF system in the indicated position [Figure 7]. In fact, the dental mold of Dental VSF will have to be substituted by that of ready-made teeth, and because of the silicone template, the following information will be recorded: the median line, chosen dental mold, position of each individual tooth, their inclination in the buccal-lingual and mesiodistal direction, overjet, overbite, and the position of the teeth in relation to the smile line. Figure 8 shows the patient's smile where the anterior teeth, belonging to the product line of the manufacturer, are corresponding to the chosen dental mold of the Dental VSF System.

## DISCUSSION

The assessment of dental appearance, one of the most important aspects of dental esthetics, often refers simply to the six maxillary anterior teeth because they are the most visible ones.<sup>[27-29]</sup> The described technique allows verification of the patient's esthetics and phonetics during the maxillomandibular recording session. After recording the occlusal vertical dimension and jaw relations in the horizontal and sagittal planes, the dentist removes the anterior wax rim from the right to the left canine and places a mold of Dental VSF system. At this point, both the dentist and the patient may evaluate the esthetics of the denture and, if necessary, the dentist can easily replace the mold with a different one in form or size, without working the wax to move or replace a tooth. The phonetics can also be evaluated and the teeth of the Dental VSF can be moved to try to find the best position for correct phonetics, according to Ritchie and Ariffin<sup>[30]</sup> who reported speech defects caused by different incisor positions in maxillary dentures; in addition, it was reported that immediate phonetic adaptation of prosthetic restoration can be achieved if the original position of the natural teeth is transferred to the



**Figure 7:** A silicone template is made to record all the information useful for placing the corresponding dental mold of the product line in the indicated position



**Figure 8:** The patient's dentures with the anterior teeth corresponding to that chosen of the Dental VSF System

denture.<sup>[31]</sup> A method that includes a kit with three transparent esthetic guides had been proposed for fabricating a denture with computer-assisted design and machining (CAD-CAM) technology; in that system, the chosen transparent guide was applied and bonded on the existing denture or wax rim.<sup>[32]</sup> That system had the advantage of helping the dentist to choose the form and size of teeth in the patient's mouth and not delegating this task to the dental technician, making the dentist's decision easier. However, it was a superficial system because it was based on unrealistic paper drawings, without a three-dimensional perspective, and without the possibility of moving a single tooth.

The use of the Dental VSF system may be extended:

- (1) To implant supported dentures; the dental molds of the Dental VSF system, when selected and placed in the correct position, can be used for manufacturing a radiological or surgical template.
- (2) To CAD-CAM technology; the assembly may be scanned and the scanned image may be used to design a screw-retained denture or a Toronto bridge.

The main advantages of this technique are that:

- (1) It is possible to try some forms of teeth and to check the esthetics and phonetics in a single appointment, making the decision of the dentist easier and less subject to mistakes of evaluation.
- (2) The patient actively participates in the choice of his smile. The system gives the dentist the chance to show to the patient different forms of teeth, easily and at the same appointment, and with the same ease to move the inclination of each veneer as well as to change vertical and horizontal overlap, previsualizing the final aesthetic result of the denture.
- (3) The dentist does not need to entrust the choice of the most suitable dental mold to the dental technician, but may choose it on the face of the patient, testing different forms without having to work the wax.

Disadvantages of the system are that:

- (1) It is impossible to move the body of a single veneer in the buccolingual or coronapical direction. The single veneer, which is connected to the others by a fiber bonded on the lingual surface, has some freedom of movement in the horizontal, sagittal, and frontal axes, and hence the dental long axis can be tilted in the buccolingual and mesiodistal directions.
- (2) The dental veneers of the kit are monochromatic. This is justified by the fact that the presence of many colors for each form and size of tooth mold would require a very large number of tooth molds in the kit, inducing more confusion rather than simplification.

## Acknowledgments

The authors thank Mr. Fabio Calandra, dental technician and inventor of the Dental VSF, who introduced to us the new system described here and placed it at our disposal.

## Financial support and sponsorship

None.


## Conflict of Interest

There are no conflicts of interest.

## REFERENCES

1. Esan TA, Olusile AO, Akeredolu PA. Factors influencing tooth shade selection for completely edentulous patients. *J Contemp Dent Pract* 2006;7:80-7.
2. Gozalo-Diaz D, Johnston WM, Wee AG. Estimating the color of maxillary central incisors based on age and gender. *J Prosthet Dent* 2008;100:93-8.
3. Hassel AJ, Nitschke I, Dreyhaupt J, Wegener I, Rammelsberg P, Hassel JC. Predicting tooth color from facial features and gender: Results from a white elderly cohort. *J Prosthet Dent* 2008;99:101-6.
4. Jahangiri L, Reinhardt SB, Mehra RV, Matheson PB. Relationship between tooth shade value and skin color: An observational study. *J Prosthet Dent* 2002;87:149-52.
5. Sears VH. The selection and arrangement of artificial teeth. *Dent Digest* 1960;66:514-7.
6. Berry FH. Study of prosthetic art. *Dentist Magazine* 1905;12:405-9.
7. House MM, Loop JL. Form and color in dental art (monograph). California: Whittier, MM House; 1939. p. 3-33.
8. Cesario VA Jr, Latta GH Jr. Relationship between the mesiodistal width of the maxillary central incisor and interpupillary distance. *J Prosthet Dent* 1984;52:641-3.
9. Levin EI. Dental esthetics and the golden proportion. *J Prosthet Dent* 1978;40:244-52.
10. Abdullah MA. Inner canthal distance and geometric progression as a predictor of maxillary central incisor width. *J Prosthet Dent* 2002;88:16-20.
11. Al Wazzan KA. The relationship between intercanthal dimension and the widths of maxillary anterior teeth. *J Prosthet Dent* 2001;86: 608-12.
12. Gomes VL, Gonçalves LC, do Prado CJ, Junior IL, de Lima Lucas B. Correlation between facial measurements and the mesiodistal width of the maxillary anterior teeth. *J Esthet Restor Dent* 2006;18:196-205.
13. Silverman SI. Physiologic factors in complete denture esthetics. *Dent Clin North Am* 1967; 115-22.
14. Varjão FM, Nogueira SS. Intercommisural width in 4 racial groups as a guide for the selection of maxillary anterior teeth in complete dentures. *Int J Prosthodont* 2005;18:513-5.
15. Kini AY, Angadi GS. Biometric ratio in estimating widths of maxillary anterior teeth derived after correlating anthropometric measurements with dental measurements. *Gerodontology* 2013;30: 105-11.
16. Puri M, Bhalla LR, Khanna VK. The relationship of intercanine distance with the distance between the alae of the nose. *J Indiana Dent Assoc* 1972;44:46-50.
17. Hoffman W Jr, Bomberg TJ, Hatch RA. Interlar width as guide in denture tooth selection. *J Prosthet Dent* 1986;55:219-21.
18. Lee SP, Lee SJ, Hayashi K, Park YS. A three-dimensional analysis of the perceived proportions of maxillary anterior teeth. *Acta Odontol Scand* 2012;70:432-40.
19. Horvath SD, Wegstein PG, Lüthi M, Blatz MB. The correlation between anterior tooth form and gender – A 3D analysis in humans. *Eur J Esthet Dent* 2012;7:334-43.
20. Sellen PN, Jagger DC, Harrison A. The selection of anterior teeth appropriate for the age and sex of the individual. How variable are dental staff in their choice? *J Oral Rehabil* 2002;29:853-7.
21. Williams JL. A new classification of tooth forms with special reference to a new system of artificial teeth. New York: The Dentists' Supply Co; 1914.
22. Mavroskoufis F, Ritchie GM. The face-form as a guide for the selection of maxillary central incisors. *J Prosthet Dent* 1980;43:501-5.
23. Bell RA. The geometric theory of selection of artificial teeth: Is it valid? *J Am Dent Assoc* 1978;97 637-40.
24. Brisman AS. Esthetics: A comparison of dentists' and patients' concepts. *J Am Dent Assoc* 1980;100:345-52.
25. Mehl CJ, Harder S, Kern M, Wolfart S. Patients' and dentists' perception of dental appearance. *Clin Oral Investig* 2011;15:193-9.
26. Calandra F. Device and methods for manufacturing dental prostheses. European Patent EP2759278 (2014). Available at <https://data.epo.org/publication-server/pdf-document?pn=2759278&ki=A2&cc=EP>
27. Albashaireh ZS, Alhusein AA, Marashdeh MM. Clinical assessments and patient evaluations of the esthetic quality of maxillary anterior restorations. *Int J Prosthodont* 2009;22:65-71.

28. Wolfart S, Quaas AC, Freitag S, Kropp P, Gerber WD, Kern M. Subjective and objective perception of upper incisors. *J Oral Rehabil* 2006;33:489-95.
29. Lajnert V, Pavić DK, Gržić R, Kovač Z, Pahor D, Kuis D, *et al.* Influences of age and maxillary anterior teeth status on patient's satisfaction with dental appearance and tooth colour. *Gerodontology* 2012;29:e674-9.
30. Ritchie GM, Ariffin YT. Sonographic analysis of speech sounds with varying positions of the upper anterior teeth. *J Dent* 1982;10:17-27.
31. Runte C, Lawerino M, Dirksen D, Bollmann F, Lamprecht-Dinnesen A, Seifert E. The influence of maxillary central incisor position in complete dentures on /s/ sound production. *J Prosthet Dent* 2001;85:485-95.
32. Infante L, Yilmaz B, McGlumphy E, Finger I. Fabricating complete dentures with CAD/CAM technology. *J Prosthet Dent* 2014;111:351-5.



### Author Help: Reference checking facility

The manuscript system ([www.journalonweb.com](http://www.journalonweb.com)) allows the authors to check and verify the accuracy and style of references. The tool checks the references with PubMed as per a predefined style. Authors are encouraged to use this facility, before submitting articles to the journal.

- The style as well as bibliographic elements should be 100% accurate, to help get the references verified from the system. Even a single spelling error or addition of issue number/month of publication will lead to an error when verifying the reference.
- Example of a correct style  
Sheahan P, O'leary G, Lee G, Fitzgibbon J. Cystic cervical metastases: Incidence and diagnosis using fine needle aspiration biopsy. *Otolaryngol Head Neck Surg* 2002;127:294-8.
- Only the references from journals indexed in PubMed will be checked.
- Enter each reference in new line, without a serial number.
- Add up to a maximum of 15 references at a time.
- If the reference is correct for its bibliographic elements and punctuations, it will be shown as CORRECT and a link to the correct article in PubMed will be given.
- If any of the bibliographic elements are missing, incorrect or extra (such as issue number), it will be shown as INCORRECT and link to possible articles in PubMed will be given.