



Mittal, T., Atack, N., Naish, H., Williams, J., Puryer, J., Sandy, J., & Ireland, A. (2018). The aberrant molar. *Orthodontic Update*, 11(2), 55-60.
<https://doi.org/10.12968/ortu.2018.11.2.55>

Peer reviewed version

Link to published version (if available):
[10.12968/ortu.2018.11.2.55](https://doi.org/10.12968/ortu.2018.11.2.55)

[Link to publication record in Explore Bristol Research](#)
PDF-document

This is the author accepted manuscript (AAM). The final published version (version of record) is available online via Mark Allen Group at <https://www.magonlinelibrary.com/doi/10.12968/ortu.2018.11.2.55> . Please refer to any applicable terms of use of the publisher.

University of Bristol - Explore Bristol Research

General rights

This document is made available in accordance with publisher policies. Please cite only the published version using the reference above. Full terms of use are available:
<http://www.bristol.ac.uk/pure/about/ebr-terms>

Generic Heading: Orthodontics

Title: The Aberrant Molar

Authors:

T Mittal

BDS, Specialty Registrar, Derriford Hospital, Plymouth

NE Atack

BDS, MSc, MOrth RCS, FDS RCS, Consultant Orthodontist, Musgrove Park Hospital, Taunton and School of Oral and Dental Sciences, University of Bristol

H Naish

BSc, BDS, MFDS RCS(Ed), MOrth RCS(Ed) Specialist Practitioner, Cathedral Orthodontics, Cardiff

JC Williams

BDS, MSc, DDS, MOrth RCS, FGDP, PGCert, FHEA, Academic Clinical Lecturer in Orthodontics, School of Oral and Dental Sciences, University of Bristol

J Puryer

BDS, DPDS, FDS RCS(Eng), MSc, FHEA, Clinical Lecturer in Restorative Dentistry, School of Oral and Dental Sciences, University of Bristol

JR Sandy

BDS, MSc, PhD, MOrth RCS, FDS RCS, FDS RCS(Ed), FFD RCS, Professor of Orthodontics and Dean of Health Sciences, University of Bristol

AJ Ireland

BDS, MSc, PhD, MOrth RCS, FDS RCS, FHEA Professor of Orthodontics, School of Oral and Dental Sciences, University of Bristol,

The Aberrant Molar

Abstract: The eruption of the molar teeth represents the start and end of the establishment of the permanent dentition. This process often occurs without event, but occasionally abnormalities of eruption occur and most frequently this affects the third molar. This article gives an overview of the possible aetiology, diagnosis and treatment of the aberrant molar.

Clinical Relevance: Awareness of the possible sequelae of unerupted or impacted molars is important in diagnosis and treatment planning.

Objectives statement: To inform the reader of possible aetiology, diagnosis and treatment of the aberrant molar.

1. Introduction

The molar teeth are unique in that they are accessional teeth, *i.e.* they do not have a primary precursor. The eruption of the first permanent molar marks the beginning of the mixed dentition phase of development. This is the first accessional tooth to erupt and is followed by the eruption of upper and lower incisors, premolars and canines (successional teeth). The eruption of the second molar marks the establishment of the permanent dentition, which maybe completed with the eruption of the third molar (if present). Abnormalities of eruption are common in the case of the third molar and less so in the case of the first and second molars.

2. Development of the molars

The first molar begins calcification at birth and erupts at roughly 6 years of age. As with most permanent teeth, the lower molar usually erupts just before the upper molar. The second molars begin to calcify at 3 years of age and erupt at about 12 to 14 years. The third molars may be visible radiographically between the ages of 8 to 14 years old and usually erupt between the ages of 17 to 25 years. They are the least predictable teeth in terms of their morphology and behaviour.

3. Third Molars

The third molars are the last teeth to develop, are the most likely to fail to develop¹ (Figure 1) and the most likely to become impacted². The incidence of developmentally absent third molars has been reported to be between 13% and 25%^{3,4}. They become impacted and so may not fully erupt in approximately 20 to 30% of cases and this impaction is most frequently mesioangular⁵ (Figure 2).

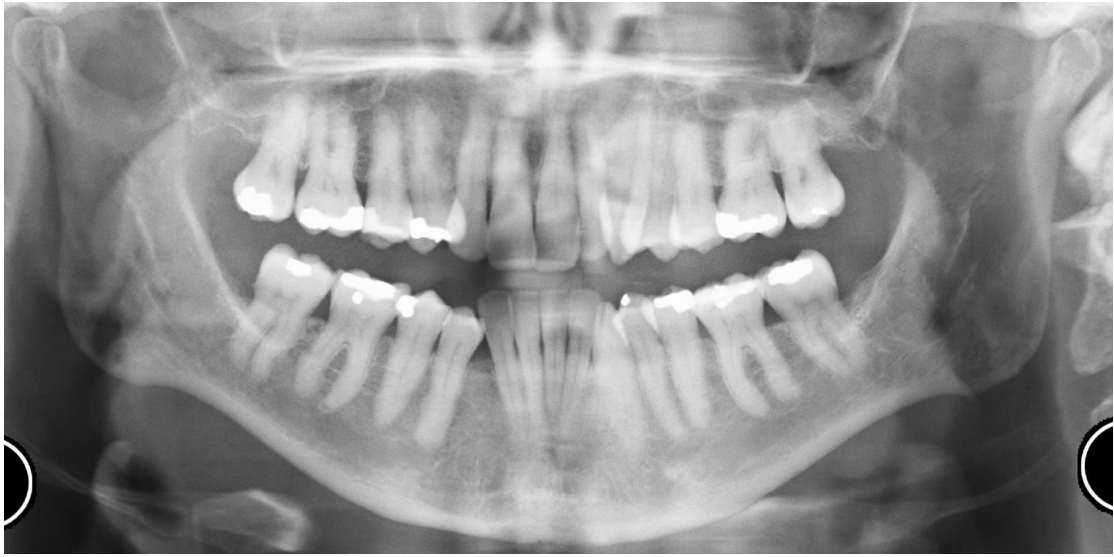

Figure 1 – DPT radiograph showing absent third permanent molars

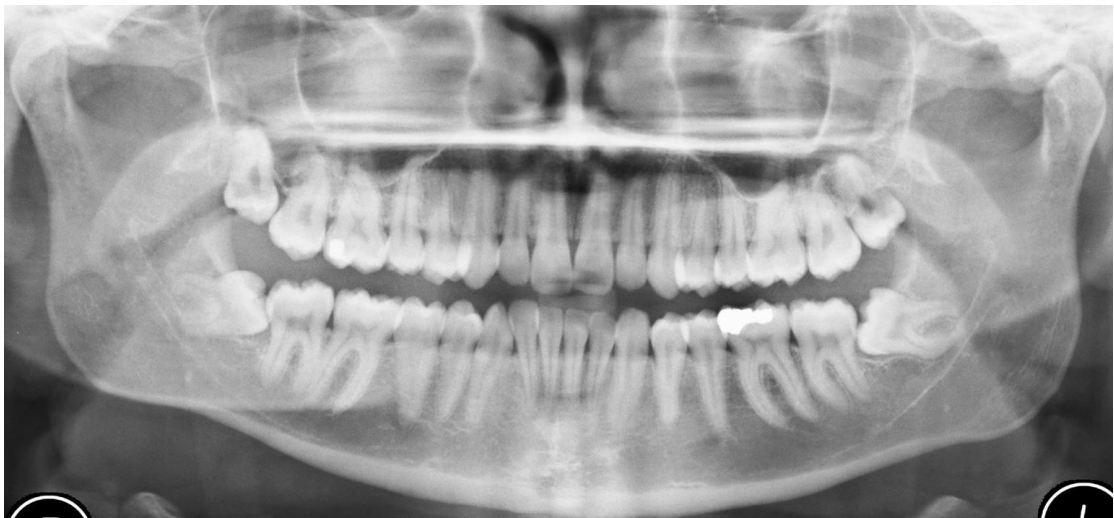

Figure 2 - DPT radiograph showing one upper and two lower mesioangularly impacted third permanent molars

There is no compelling evidence that the impaction of the third molar has any effect on late lower incisor crowding⁶⁻⁸. Consequently the National Institute for Clinical Excellence (NICE) advises that prophylactic removal of asymptomatic third molars, in order to prevent changes to incisor alignment, is not recommended.

4. Second molars

There is little literature relating specifically to eruptive disturbances of the second molar. The incidence of impaction of the second molar is reported as 1.5% and failure of eruption as 0.6%⁹. The second molar is rarely absent, but this has been reported to occur in 0.8% to 1.5% of cases^{9, 1}

4.1 Signs of posterior crowding

The terms 'stacked molars' refers to the radiographic appearance of the upper molar teeth being stacked almost vertically, one on top of the other, and is indicative of posterior crowding (Figure 3). In the lower arch, posterior crowding can also be seen on a dental panoramic tomogram (DPT) and in this case the lower second molar may appear distally angulated (Figure 4). This posterior crowding is an indication that mid arch extractions may be applicable, especially if third permanent molars are present. A distally angulated lower second molar can be problematic in the longer term, as it increases the risk of impaction of the third molar and the same angulation will make restorative work more challenging.

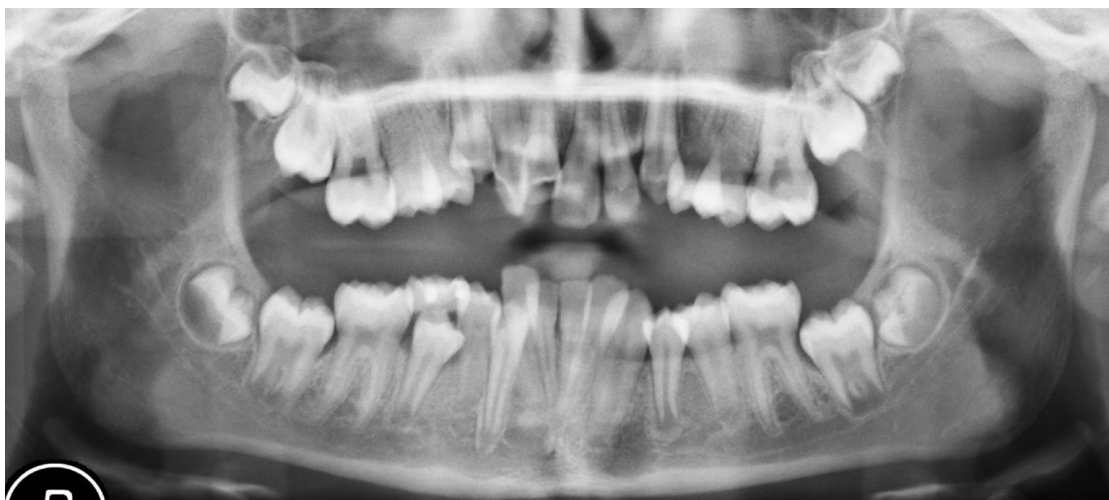

Figure 3 – DPT radiograph showing “Stacked upper molars”

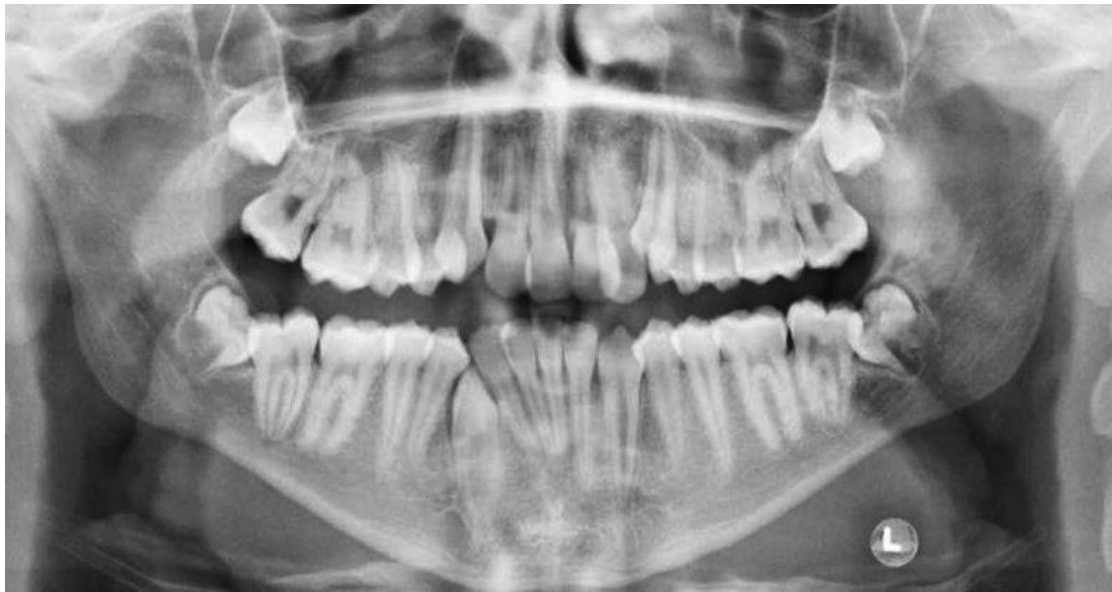

Figure 4 - DPT radiograph showing distoangularly impacted lower second molars

4.2 Mesially angulated second molar

Mesial impaction of the second molar is not always evident at the beginning of treatment and often occurs when the mesial marginal ridge of the second molar gets caught on the distal aspect of the first molar (Figures 5a-c), especially if there is an orthodontic band on the latter tooth. The second molar continues to erupt, but usually tips further mesially.

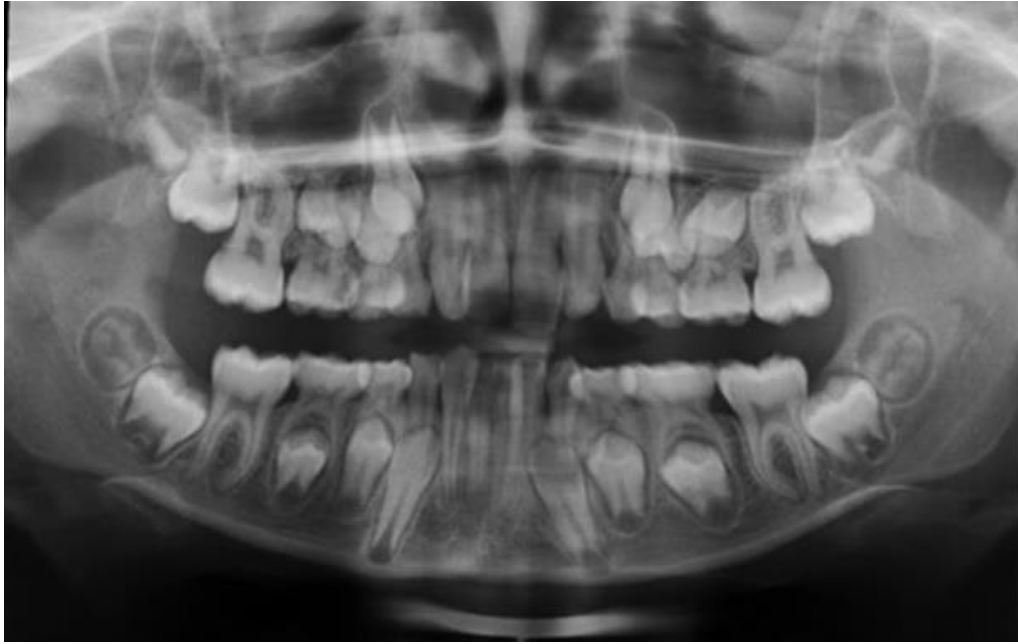

Figure 5a - DPT radiograph of a patient showing lower second molars that are slightly mesioangular, but in a reasonable position. There is a dental delay elsewhere.

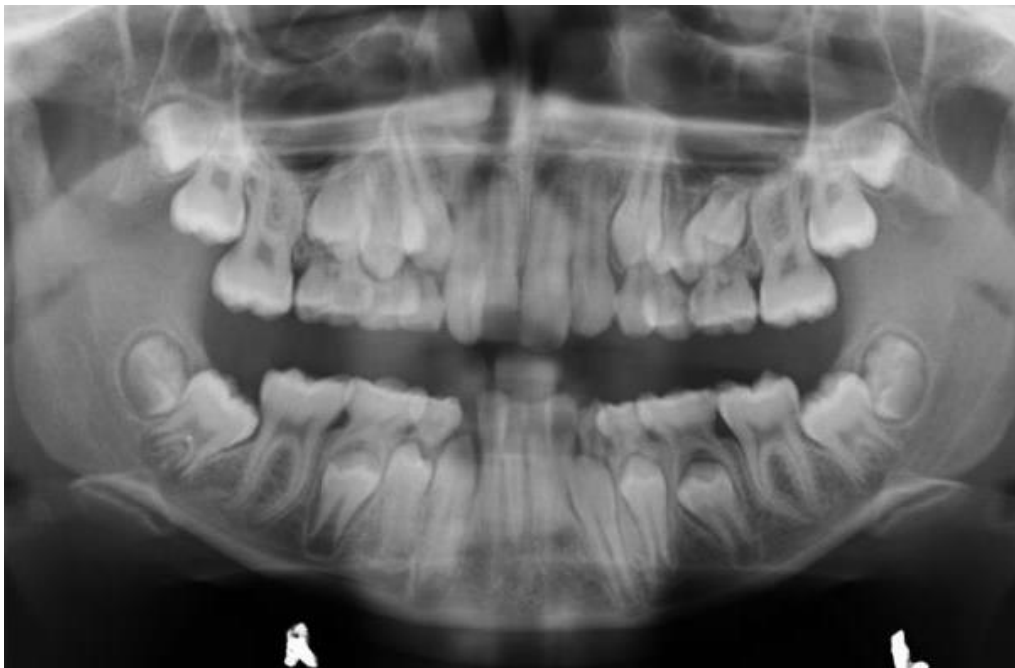

Figure 5b - The same patient as in Figure 5a. Upper and lower second molars appear short of space and mesioangularly angulated. There is a risk of impaction

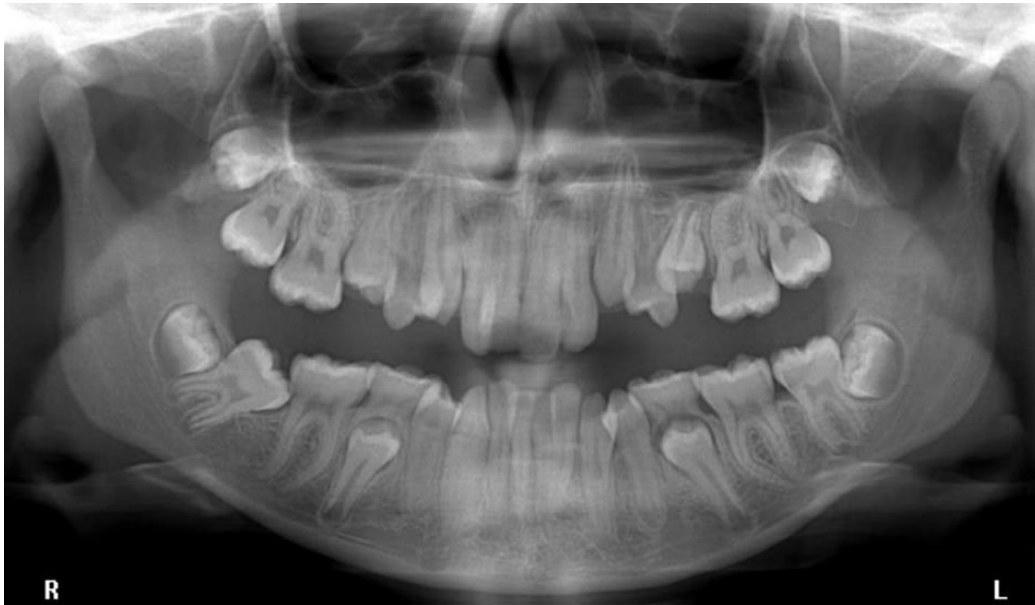

Figure 5c - The same patient as in 5a&b. As deciduous teeth are lost the second molars have self-corrected, with the exception of the LR7. The LR7 is mesioangularly impacted on the distal aspect of the LR6

4.3 Treatment in the case of the mesially impacted second molar

Uprighting of the second molar requires that the tooth is tipped distally. Should the marginal ridge be freed, for example with a separator, then it is possible it will self-correct. If this is not successful, or the impaction is severe, orthodontic uprighting may be required. Provided a tube can be bonded to the buccal surface of the second molar, either a continuous or a sectional archwire can be used to upright the second molar. A sectional arch^{10, 11} can be used in combination with an existing fixed appliance or it can be used on its own. For example a single buccal tube can be bonded onto the second molar and a sectional rectangular stainless steel wire bent such that it passes up the buccal surface of the adjacent first permanent molar and onto its occlusal surface (Figure 6). In this case it is important the second molar is opposed so that as it is tipped distally by the sectional wire, the occlusion with the opposing upper arch tooth encourages the roots of the lower second molar to move

mesially. Alternatively tubes can be bonded onto both the first and second molars and a sectional rectangular nickel titanium wire used to upright the first molar (Figure 7). A lockable attachment is used to prevent the wire from slipping either mesially or distally.

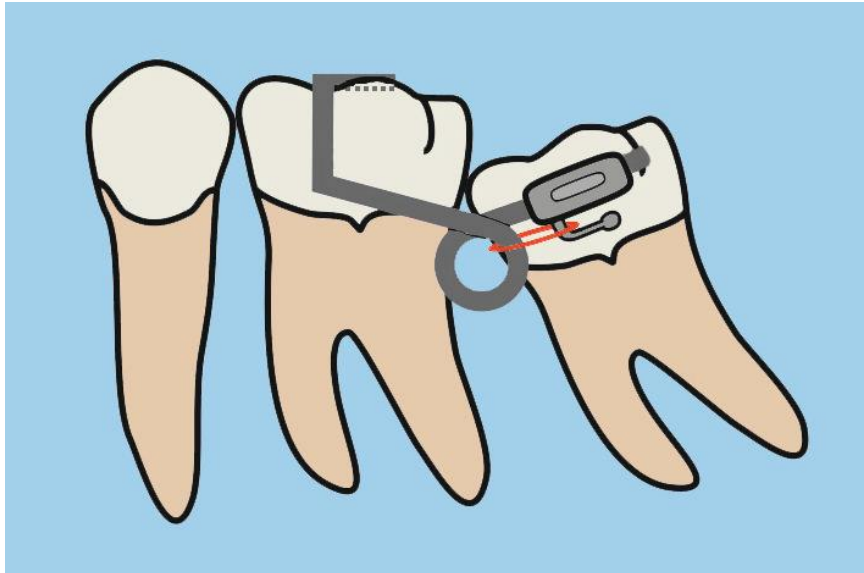


Figure 6 – Diagram illustrating the use of a stainless steel sectional attached to just the second molar to upright it

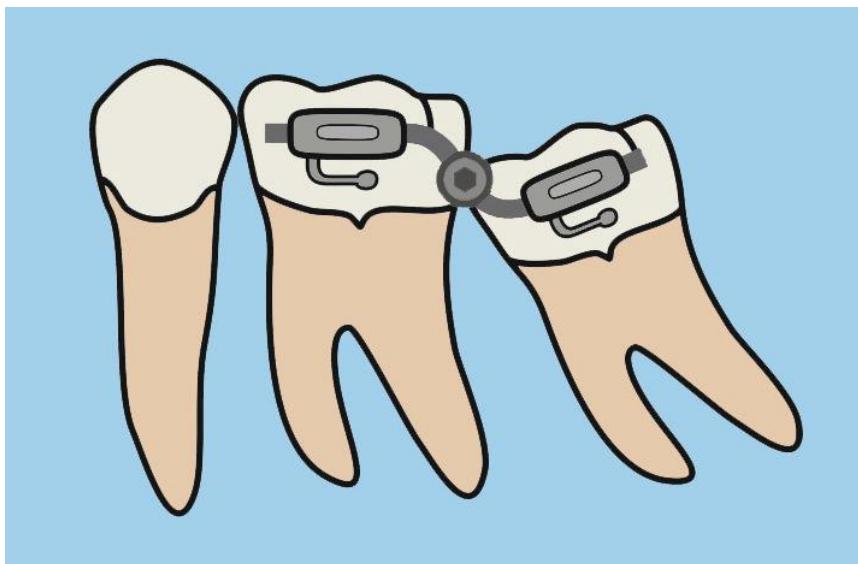


Figure 7 - A sectional fixed appliance with a rectangular nickel titanium alloy wire being used to upright an impacted lower second permanent molar

Bonding a button onto the occlusal surface of the second molar and using a fixed segmental spring, or a spring on a removable appliance, will also have the effect of tipping the second molar distally, thereby disimpacting it¹².

A deep impaction of the second molar may necessitate extraction of this tooth. If this is the case then the presence and position of the third molar should be assessed (Figure 8). If extraction of the second molar occurs at or near the time of formation of the bifurcation of the third molar, there is a high likelihood that the third molar will erupt into the position of the second molar¹³⁻¹⁶

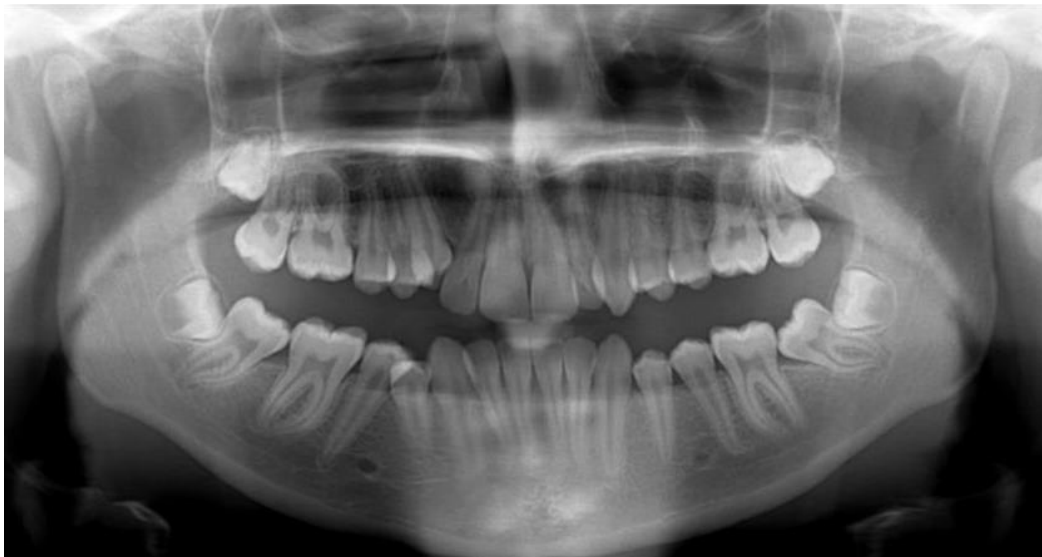

Figure 8 - The lower left second molar is mesioangularly impacted. The third molar bifurcation is forming. Uprighting the second molar would require considerable root movement and there is a high chance the third molar would become impacted in the long term. In this case the lower left second molar was extracted.

Uprighting of the second molar is likely to become easier following any mid arch extractions and space closure as the increase in available space may allow self-resolution of the impaction. If orthodontic correction is not possible and extraction is not considered a sensible option, surgical repositioning of the tooth may be

required. If the procedure is performed before the completion of root formation there is often good bony infill between the first and second molar^{17, 18}.

5. First Molars

The first molar is one of the first permanent teeth to erupt. There is almost always sufficient space for its eruption and other factors dictate anomalies of eruption.

Physical obstruction by the second primary molar is referred to as ectopic eruption and is more common in the maxilla. Occasionally lower first permanent molars fail to erupt due to ankylosis and they are usually in intimate relation to the inferior dental canal.

5.1 Ectopic eruption of the maxillary molar

Ectopic eruption of the upper first permanent molar is a localised disturbance of eruption where the first molar comes into contact with the distal aspect of the second deciduous molar. This occurs in roughly 4% of patients¹⁹ and is more common in siblings²⁰. There is often resorption of the distal aspect of the second deciduous molar, in which case only the distal portion of the first molar crown is visible intra-orally (Figure 9). If resorption of the second deciduous molar is extensive it can lead to a direct communication between the mouth and the dental pulp (Figure 10), resulting in symptoms including pain, which will inevitably necessitate extraction of the second deciduous molar.

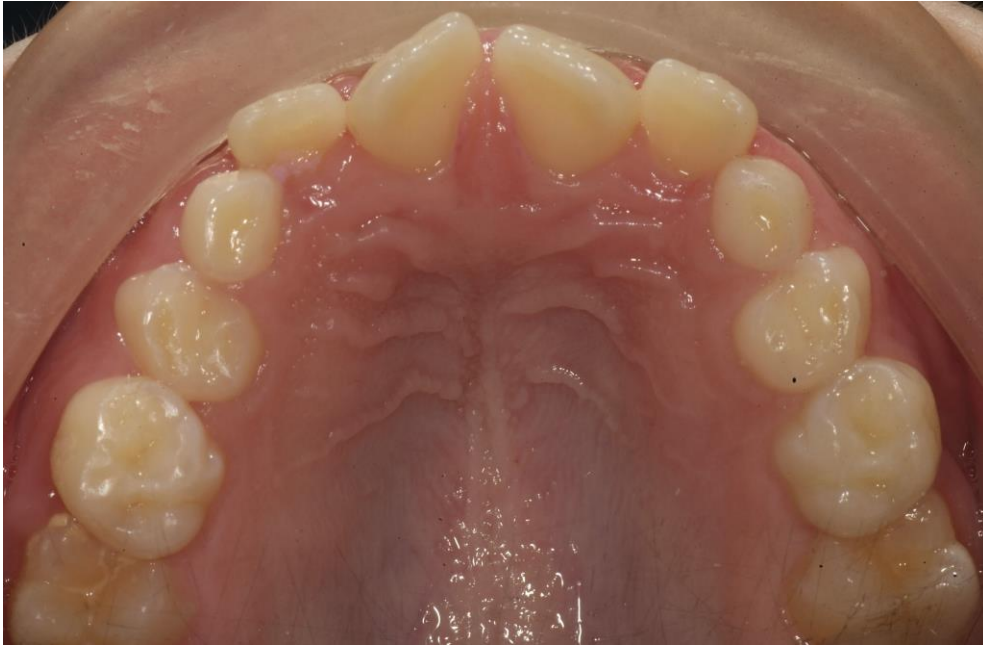


Figure 9 – Impacted upper first permanent molars. Notice how the mesial portions of the crowns of the first permanent molars are obscured beneath the distal aspects of the second deciduous molars.

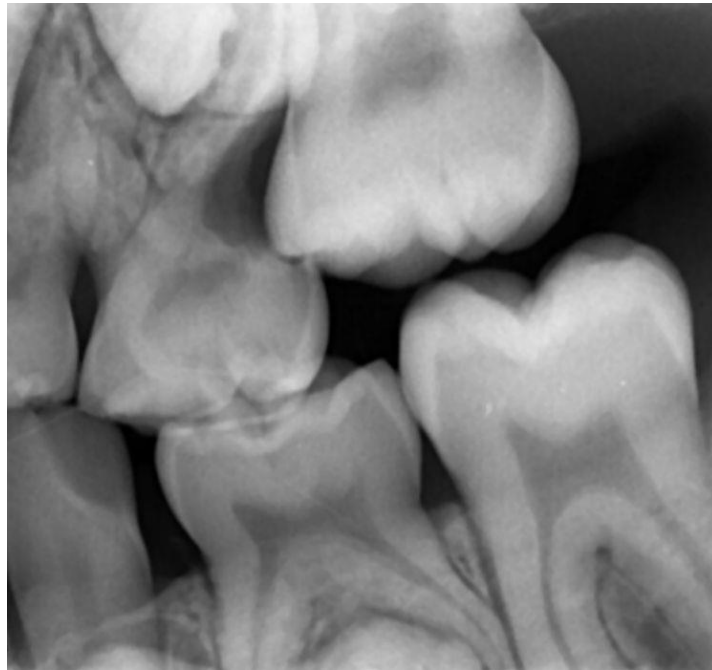


Figure 10 – A bitewing radiograph showing extensive resorption on the distal aspect of the second deciduous molar. Open communication between the mouth and dental pulp can lead to symptoms including pain.

Treatment in the case of the ectopic maxillary first molar

Two thirds of ectopic first molars impacted against the distal of the second deciduous molar will spontaneously self-correct^{21, 22}. Placement of a separator to free the mesial portion of the first molar will often encourage disimpaction of the tooth. However, access is notoriously difficult and separator placement can be uncomfortable. Removal of the deciduous tooth will allow the first molar to erupt, but the inevitable consequence is space loss and future crowding in the premolar regions as the molar moves further mesially (Figure 11).

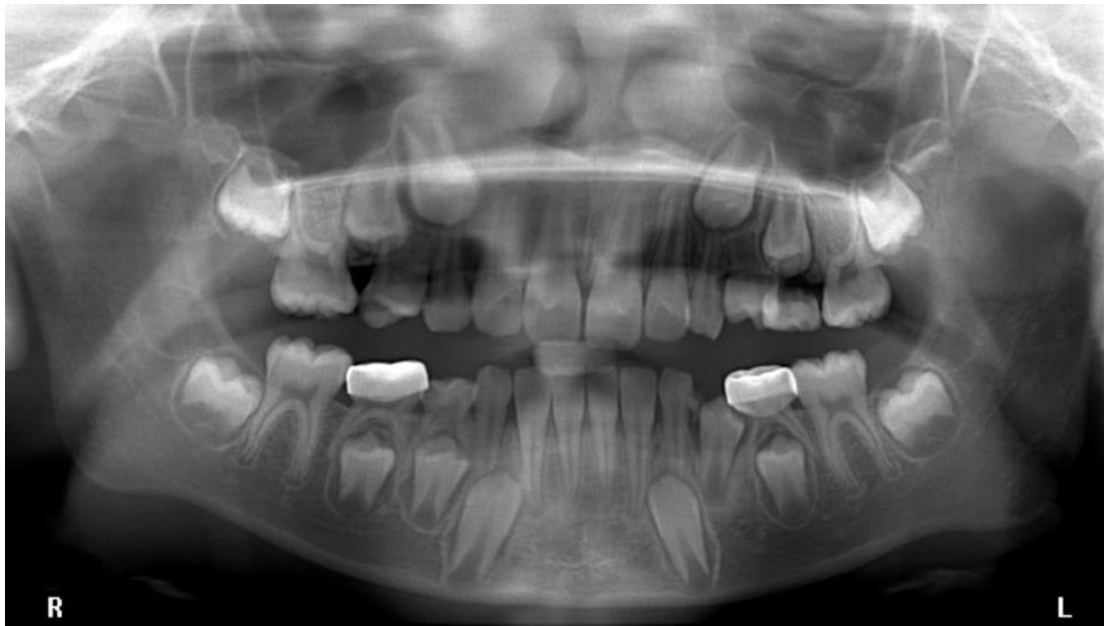

Figure 11 - There is significant resorption of the distal aspect of the upper left second deciduous molar and the upper right second deciduous molar has been lost. There is no history of extraction. It is likely that the upper first molars were previously ectopically erupted and self-corrected on the left. In the upper right quadrant, resorption was probably so extensive that the second deciduous molar exfoliated early. Note the lack of space for the upper right second premolar

5.2 Single ankylosed mandibular first molar

Very occasionally the lower first permanent molar becomes ankylosed and can be seen in a close relationship with the inferior alveolar nerve and canal. Fortunately it is a rare occurrence with an incidence of just 0.05%²³. The aetiology is unclear, but it may be a variation of primary failure of eruption, associated with cystic change within the follicle or the presence of odontomes²⁴. A local abnormality in bone resorption overlying the first molar on one quadrant is unusual, but possible²⁵. Should the second molar erupt before the first molar, space loss and tipping will result in physical obstruction of the first molar (Figure 12). If root formation has progressed and there is intimate relation with the lower border of the mandible then the roots may splay mesially or distally, appearing dilacerated.

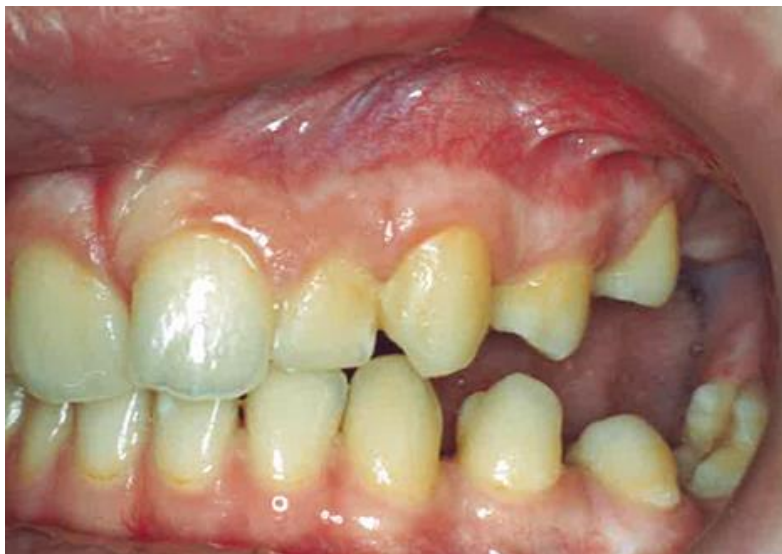

Figure 12 – An ankylosed and unerupted lower left first molar has led to mesial tipping of the lower left second molar. Notice how the upper left first permanent molar has also failed to erupt.

Treatment in the case of the ankylosed mandibular first molar

Although thankfully rare, ankylosis of the mandibular molar can represent a considerable treatment challenge. If there is any physical barrier to eruption,

removal of the obstruction should allow either autonomous or orthodontically assisted eruption. Surgical luxation of the tooth and orthodontic extrusion may be suitable if the root morphology is favourable²⁵. In other cases extraction or coronectomy is the treatment of choice, as attempted orthodontic extrusion may result in unwanted intrusion of the adjacent teeth, possibly creating a posterior open bite.

6. Primary failure of eruption

The term primary failure of eruption (PFE) is used to refer to cases where there is failure of eruption of all teeth distal to the most mesially affected tooth²⁶⁻²⁸. Figure 13 illustrates such a case where the teeth distal to the canines have failed to continue to erupt and make occlusal contact with their counterparts in the opposing arch. PFE may be an autosomal dominant inherited trait and there is evidence that mutation of the *PTH1R* gene is responsible²⁷⁻²⁹. Treatment of PFE is extremely difficult and even though teeth may appear responsive to orthodontic force shortly following surgical uncovering, they invariably become ankylosed. Dentoalveolar osteotomy is the only method of repositioning the tooth or teeth.

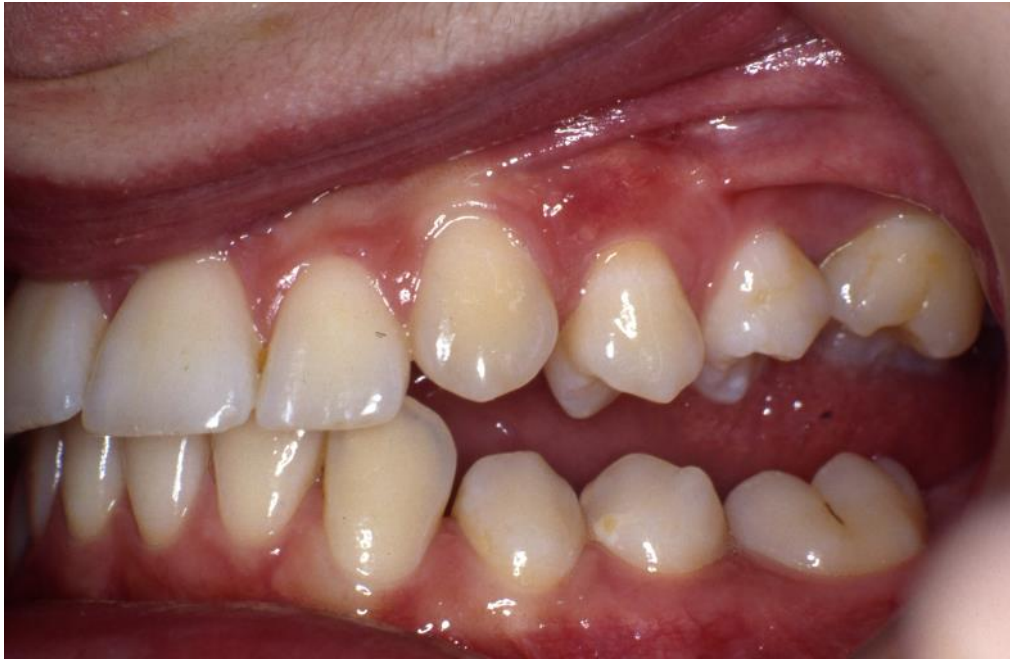

Figure 12 – A case of primary failure of eruption

7. Conclusion

This article has reviewed and summarised the aetiology and treatment options for eruption disturbances of permanent molar teeth. With the exception of the third molar, posterior teeth often erupt without incident, but there are instances where this is not the case, as outlined. Early identification of these eruption disturbances may simplify treatment.

Acknowledgements

The Authors would like to thank Mrs Karen Drage (Consultant Orthodontist, Derriford Hospital, Plymouth) for the use of some of her clinical cases

References

1. Khalaf K, Miskelly J, Voge E, Macfarlane TV. Prevalence of hypodontia and associated factors: a systematic review and meta-analysis. *J Orthod.* 2014;41(4):299-316.
2. Thilander H, Thilander B, Persson G. Treatment of impacted teeth by surgical exposure. A survey study. *Svensk tandlakare tidskrift Swedish dental journal.* 1973;66(6):519-25.
3. Banks HV. Incidence of third molar development. *The Angle Orthodontist.* 1934;4(3):223-33.
4. Shinn DL. Congenitally missing third molars in a British population. *Journal of Dentistry.* 1976;4(1):42-4.
5. Bishara SE, Andreasen G. Third molars: A review. *American Journal of Orthodontics.* 1983;83(2):131-7.
6. Lindqvist B, Thilander B. Extraction of third molars in cases of anticipated crowding in the lower jaw. *American Journal of Orthodontics.* 1982;81(2):130-9.
7. Richardson M, Orth D, Mills K. Late lower arch crowding: The effect of second molar extraction. *American Journal of Orthodontics and Dentofacial Orthopedics.* 1990;98(3):242-6.
8. Harradine NW, Pearson MH, Toth B. The effect of extraction of third molars on late lower incisor crowding: a randomized controlled trial. *British journal of orthodontics.* 1998;25(2):117-22.
9. Bondemark L, Tsiopa J. Prevalence of Ectopic Eruption, Impaction, Retention and Agenesis of the Permanent Second Molar. *The Angle Orthodontist.* 2007;77(5):773-8.
10. Shapira Y, Borell G, Nahlieli O, Kuftinec MM. Uprighting mesially impacted mandibular permanent second molars. *The Angle Orthodontist.* 1998;68(2):173-8.
11. Sawicka M, Racka-Pilszak B, Rosnowska-Mazurkiewicz A. Uprighting Partially Impacted Permanent Second Molars. *The Angle Orthodontist.* 2007;77(1):148-54.
12. Majourau A, Norton LA. Uprighting impacted second molars with segmented springs. *American Journal of Orthodontics and Dentofacial Orthopedics.* 1995;107(3):235-8.
13. Richardson ME, Richardson A. Lower third molar development subsequent to second molar extraction. *American Journal of Orthodontics and Dentofacial Orthopedics.* 1993;104(6):566-74.
14. Orton-Gibbs S, Crow V, Orton HS. Eruption of third permanent molars after the extraction of second permanent molars. Part 1: assessment of third molar position and size. *American Journal of Orthodontics and Dentofacial Orthopedics.* 2001;119(3):226-38.

15. Orton-Gibbs S, Orton S, Orton H. Eruption of third permanent molars after the extraction of second permanent molars. Part 2: Functional occlusion and periodontal status. *American Journal of Orthodontics and Dentofacial Orthopedics*. 2001;119(3):239-44.
16. De-la-Rosa-Gay C, Valmaseda-Castellón E, Gay-Escoda C. Spontaneous third-molar eruption after second-molar extraction in orthodontic patients. *American journal of orthodontics and dentofacial orthopedics*. 2006;129(3):337-44.
17. Johnson JV, Quirk GP. Surgical repositioning of impacted mandibular second molar teeth. *American Journal of Orthodontics and Dentofacial Orthopedics*. 1987;91(3):242-51.
18. Pogrel MA. The surgical uprighting of mandibular second molars. *American Journal of Orthodontics and Dentofacial Orthopedics*. 1995;108(2):180-3.
19. Bjerklin K, Kuroi J. Ectopic eruption of the maxillary first permanent molar: Etiologic factors. *American Journal of Orthodontics*. 1983;84(2):147-55.
20. Bjerklin K. Ectopic eruption of the maxillary first permanent molar. An epidemiological, familial, aetiological and longitudinal clinical study. *Swed Dent J Suppl*. 1994;100:1-66.
21. Kennedy DB, Turley PK. The clinical management of ectopically erupting first permanent molars. *American Journal of Orthodontics and Dentofacial Orthopedics*. 1987;92(4):336-45.
22. Barberia-Leache E, Suarez-Clúa MC, Saavedra-Ontiveros D. Ectopic Eruption of the Maxillary First Permanent Molar: Characteristics and Occurrence in Growing Children. *The Angle Orthodontist*. 2005;75(4):610-5.
23. Baccetti T. Tooth anomalies associated with failure of eruption of first and second permanent molars. *American Journal of Orthodontics and Dentofacial Orthopedics*. 2000;118(6):608-10.
24. Mellor TK. Six cases of non-eruption of the first adult lower molar tooth. *Journal of Dentistry*. 1981;9(1):84-8.
25. Raghoobar GM, Boering G, Vissink A, Stegenga B. Eruption disturbances of permanent molars: a review. *Journal of oral pathology & medicine : official publication of the International Association of Oral Pathologists and the American Academy of Oral Pathology*. 1991;20(4):159-66.
26. Ireland AJ. Familial posterior open bite: a primary failure of eruption. *British journal of orthodontics*. 1991;18(3):233-7.
27. Frazier-Bowers SA, Koehler KE, Ackerman JL, Proffit WR. Primary failure of eruption: further characterization of a rare eruption disorder. *American Journal of Orthodontics and Dentofacial Orthopedics*. 2007;131(5):578. e1-. e11.
28. Frazier-Bowers SA, Simmons D, Wright JT, Proffit WR, Ackerman JL. Primary failure of eruption and PTH1R: the importance of a genetic diagnosis for orthodontic treatment planning. *American journal of orthodontics and dentofacial orthopedics : official publication of the American Association of Orthodontists, its constituent societies, and the American Board of Orthodontics*. 2010;137(2):160.e1-7; discussion -1.

29. Stellzig-Eisenhauer A, Decker E, Meyer-Marcotty P, Rau C, Fiebig BS, Kress W, et al. Primary failure of eruption (PFE)—clinical and molecular genetics analysis. *Journal of Orofacial Orthopedics/Fortschritte der Kieferorthopädie*. 2010;71(1):6-16.