

LONDON
SCHOOL of
HYGIENE
& TROPICAL
MEDICINE



Stambolliu, E.; Ioakeim-Ioannidou, M.; Kontokostas, K.; Dakoutrou, M.; Kousoulis, A.A. (2017) [Accepted Manuscript] The Most Common Comorbidities in Dandy-Walker Syndrome Patients: A Systematic Review of Case Reports. *Journal of child neurology*. ISSN 0883-0738 DOI: <https://doi.org/10.1177/0883073817712589>

Downloaded from: <http://researchonline.lshtm.ac.uk/4258852/>

DOI: [10.1177/0883073817712589](https://doi.org/10.1177/0883073817712589)

Usage Guidelines

Please refer to usage guidelines at <http://researchonline.lshtm.ac.uk/policies.html> or alternatively contact researchonline@lshtm.ac.uk.

Available under license: <http://creativecommons.org/licenses/by-nc-nd/2.5/>

TITLE PAGE

The most common comorbidities in Dandy-Walker Syndrome patients: a systematic review of case reports

Running title: Comorbidities in Dandy-Walker Syndrome

Authors & Affiliations

Emelina Stambolliu, MD^{1,2*}; Myrsini Ioakeim-Ioannidou, MS^{1,3*}; Kimonas Kontokostas, MD, MSc⁴; Maria Dakoutrou, MD^{1,5}; Antonis A. Kousoulis, MD, MSc^{1,6}

¹ Society of Junior Doctors, Athens, Greece

² Department of Internal Medicine, General Hospital of Kalavryta, Kalavryta, Greece

³ Medical School, University of Athens, Athens, Greece

⁴ Department of Neurology, General Hospital "Pammakaristos", Athens, Greece

⁵ First Department of Paediatrics, "Aghia Sophia" Children's Hospital, University of Athens, Greece

⁶ Faculty of Epidemiology and Population Health, London School of Hygiene & Tropical Medicine, London, UK

** These authors contributed equally to the manuscript.*

Corresponding Author contact information:

Myrsini Ioakeim Ioannidou

Mailing address: Argyrokastrou 17 str, Athens, Greece

Telephone number: 00306947099734

Fax number: 00302112127485

E-mail address: mirsini.ioakeim@gmail.com

Word Count: 3266

Abstract

OBJECTIVE: Dandy-Walker Syndrome (DWS) is a rare neurological multi-entity malformation. This review aimed at reporting its main non-neurological comorbidities. **METHODS:** Following PRISMA guidelines, search in Medline was conducted (2000-2014, keyword dandy-walker). Age, sex, country, DWS type, consanguinity or siblings with DWS, and recorded coexistent conditions (by ICD10 category) were extracted for 187 patients (46.5% male, 43% from Asia) from 168 case reports. **RESULTS:** Diagnosis was most often set in <1y.o. (40.6%) or >12y.o. (27.8%). One-third of cases had a chromosomal abnormality or syndrome (N=8 PHACE), 27% had a cardiovascular condition (N=7 Patent Ductus Arteriosus), 24% had a disease of eye and ear (N=9 cataract); most common malignancy was neuroblastoma (N=8, all Asian). Almost one-fifth had a mental illness diagnosis; only 6.4% had mild or severe intellectual disability. **CONCLUSION:** The spread of comorbidities calls for early diagnosis and multidisciplinary research and practice, especially as many cases remain clinically asymptomatic for years.

Keywords: neuropathy, pediatric, neurodevelopment, developmental delay, cerebellum

MAIN TEXT

INTRODUCTION

Dandy-Walker Syndrome (DWS) is a rare congenital posterior fossa malformation, reported in only 1 in 25-30,000 live births, which occurs during the embryonic development of the cerebellum and 4th ventricle^{1,2}. There is an ongoing debate among researchers when it comes to categorizing the variant forms of DWS; the most acceptable classification has been Barkovich's which identifies two types to the DW complex, A and B, wherein A split into the classic DW malformation and the DW variant, and B comprises the DW "mega cisterna magna"^{1,3}. The aforementioned classification is now in dispute and some of these terms, like "variant" or "complex", are largely avoided. Most cases of DWS are sporadic. However, it seems that first-degree relatives (such as siblings and especially twins) of DWS patients have increased risk of developing the condition compared to the general population, with the pattern of inheritance remaining unclear^{4,5}.

Diagnosis of the classic Dandy-Walker malformation is based on a series of characteristic neuroimaging findings, which include complete or partial agenesis of the cerebellar vermis, cystic dilatation of the 4th ventricle, enlarged posterior fossa. Hydrocephalus is a common complication of the disease (in almost 80% of the cases)^{1,3}. Dandy-Walker malformation could be diagnosed before birth sonographically (by identifying certain sonographic features such as the size of ventricles or measurements of the brainstem- vermis angle)^{6,7} but the majority of cases seem to be diagnosed postnatally and, in fact, before the age of 1-year-old.

DWS has multiple neurodevelopmental complications since the cerebellum, which is the mainly affected structure, is the region of the brain that regulates movement coordination as well as, partially, cognition and behavior⁸. The symptoms usually become apparent in early infancy with the most common being macrocephaly, signs of increased intracranial pressure and spastic paraparesis, hypotonia, slow motor development and intellectual disability can also be observed in the early stages. Other less common signs include focal neurologic signs such as strabismus, nystagmus and palsies of cranial nerves, truncal ataxia and speech difficulties^{1,9,10}. Some patients with DWS may also suffer from seizures which are usually associated with supratentorial malformations¹¹.

DWS comorbid with non-neurological clinical entities can be a treatment challenge and is currently under research. Many cases of DWS have been associated with major psychopathology such as schizophrenia¹², bipolar disorder¹³, major depression and impulse control disorder¹⁴. Further, a seemingly high percentage of children with DWS have dysmorphic characteristics¹⁵, other malformations of the Central Nervous System (agenesis of the corpus callosum, rachischisis, ectopic brain or cerebellar tissue)^{1,16}, as well as disorders of the cardiovascular¹⁷, urogenital¹⁸, and gastrointestinal systems¹⁹. Multiple types of neoplasms and neurocutaneous disorders have also been observed in variable frequencies^{20,21}. In addition, other genetic syndromes²² and chromosomal anomalies, such as 3q Syndrome (the location of the DWS affected genes, known as ZIC1 and ZIC4)^{1,23} and trisomy 18²⁴ may coexist. However, despite many observations, the sporadic nature of the disease and the expectation that it is now relatively well understood in Europe and North America has impeded research in large case-series to explore clinically significant

comorbidities and most of the above observations are derived from low evidence case reports.

The aim of this paper has been to systematically review the literature, collect all disparate case reports of children with all types of DWS into a secondary case series and report on the frequency of non-neurological medical conditions coexisting with DWS.

METHODS

Working definitions

For the purposes of this review, comorbidity was defined as a systemic medical condition existing simultaneously with DWS in a single patient, regardless of the existence of a reported causal relationship²⁵. Any neuropathological and morphologic abnormalities were excluded. For the classification of comorbidities, the 10th revision of the International Statistical Classification of Diseases and Related Health Problems (ICD10 list) was used. As outlined above, DWS has been considered as an all-entity encompassing term.

Search strategy

This review has adopted the Preferred Reporting Items for Systematic Reviews and Meta-Analyses (PRISMA) guidelines²⁶. Using only variations of the main keyword “dandy-walker”, a systematic search was done in PubMed from 01/2000 to 05/2014 by two reviewers working independently. Inclusion criteria comprised the following: English-language publications, case reports or small case series and publications reporting comorbidities or coexisting conditions associated with Dandy-Walker. All other study designs, secondary research, and studies reporting on diagnosed fetuses who did not survive to birth were excluded. Two reviewers independently screened titles and abstracts of retrieved citations. The full texts of potentially relevant case reports were screened. A standard search diary was kept by each reviewer. Any disagreements were resolved through consensus following consultation with a third reviewer. A relevant flow chart was constructed to outline the number of papers retrieved and exclusions in each step.

Data extraction and synthesis

Three reviewers extracted the following information from each study on an Excel® spreadsheet: study title, first author’s surname, year of publication, study design, country of origin of patient, sex, age group (according to the Centers for Disease Control and Prevention Child Development classification), Dandy-Walker type (syndrome/malformation, variant and complex/mega cisterna magna, as defined in each article), parents or siblings diagnosed with DWS. To ensure that the review was inclusive of all relevant findings, studies

which reported patients with Dandy-Walker anomaly were included even when they were not confirming the diagnostic radiological evidence. In the event of missing data, additional information was requested via contacting the corresponding authors.

Most variables were expressed qualitatively. A purely descriptive approach was adopted (i.e. data expressed as non-weighted means whenever possible) for continuous variables. No further statistical analysis was undertaken. In the interest of not excluding clinically important case reports, no formal quality assessment of eligible articles was undertaken.

RESULTS

Literature search

The search yielded a total of 576 papers (Figure 1). Two-hundred forty-nine papers were excluded by screening of the title and abstract; 195 were irrelevant, 48 were non-English publications and 6 reported on fetuses or stillborn children. Following screening of the full text for 326 publications, 168 case reports were eventually included, which represented primary case reports or reports of cases in two siblings, corresponding to a total of 187 patients.

Study characteristics

Characteristics of the included case reports are summarized in Table 1. In most included cases the diagnosis of Dandy-Walker Syndrome was established by Magnetic Resonance Imaging (MRI) of the brain. Eighty seven (46.5%) individuals were male and 80 (42.8%) were female, while 20 (10.7%) studies did not report the gender of the case. At the point of diagnosis, 52 patients (27.8%) were 12 years old or older, 14 patients (7.5%) were between 5-12 years old, 29 (15.5%) were toddlers or of preschool age (1-5 years old) and 76 patients (40.6%) were infants or neonates (younger than 1 year old); age was not reported in 16 cases (8.6%).

As far as area of origin is concerned, most of the patients (43%, N=81) came from Asia, approximately a quarter (28%, N=52) from Europe, a further 16% (N=29) from North America, and the rest from South America (N=14), Africa (N=8), and Oceania (N=2). Most cases reported from a single country were from the United States (N=24), followed by Turkey (N=20), India (N=18), Japan (N=16), with Germany contributing a fifth of European cases (N=11).

Fifteen patients had a parent diagnosed with DWS (16%), whereas in half of the studies (49.7%, N=93 patients) this was not reported. Twenty cases had one or more siblings with Dandy-Walker malformations (21%). There was no evidence regarding siblings with DWS in 95 cases.

Most of the patients (64.7%, N=121) had been diagnosed with Dandy Walker malformation (or syndrome), 37 patients (19.8%) were reported as having the less severe form of Dandy

Walker variant, 23 (12.3%) patients had Dandy-Walker complex, 2 (1.1%) had mega cistern magna. Dandy Walker anomaly was recorded as part of the Dandy Walker Syndrome. The terms “variant” and “complex” were recorded for 62 cases to indicate disease type and severity, despite them being terms not widely used currently in Europe and North America.

Comorbidities

Comorbidities reported in all case reports combined, classified by ICD10 category, are summarized in Table 2. The most frequent ones are outlined below.

Neoplasms: One or more malignancies were reported in 22 patients (11.8%), most Asian (N=14, 77%). Nephroblastoma (Wilm’s tumor) was the most frequent, diagnosed in 8 patients (4.4%) from Asia. Four patients (2.1%) had tongue hamartoma.

Endocrine and metabolic diseases: Overall, 18 patients (9.6%) were reported to have diagnosed endocrine/metabolic disorder, with hirsutism being the most common (N=5, 2.7%).

Mental health and learning disability: Thirty-one patients (16.6%) were diagnosed with a mental or behavioral disorder, almost half of them being European (N=14, 45%) and a third (N=11, 35%) Asian, with an approximately equal number of women and men. About half (N=16, 51%) of these patients had Dandy Walker variant while a third (N=9, 29%) had Dandy Walker malformation and fewer (N=6, 19%) Dandy Walker complex. Twelve of them (38.7%) also had a diagnosed learning disability (severe or mild), 5 (16.1%) had bipolar disorder, 5 (16.1%) had symptoms of psychotic spectrum, while 4 patients (12.9%) were reported to have Attention Deficit/Hyperactivity Disorder (ADHD).

Diseases of the eye and ear: Twenty-four per-cent (N=45) of the patients had one or more ocular abnormalities and almost half of them (N=20, 44%) were Asian and a third (N=14, 31%) were European. Five (11%) had a diagnosed parent, while 10 (22%) had one or more siblings with DWS. Nine patients (20%) had a diagnosed cataract (almost half, N=4, 44.4%, of them had at least one sibling with Dandy Walker), 6 (13.3%) had microphthalmia, 5 patients (11.1%) had chorioretinal atrophy /dysplasia, 5 (11.1%) had optic nerve dysplasia/atrophy, 5 (11.1%) had microcornea/corneal opacity and 5 (11.1%) had reported myopia. Three patients (6.7%) were diagnosed with coloboma of the eye (iris/optic nerve/optic disk) and 7 patients (15.6%) had hearing impairment.

Diseases of the circulatory system: Overall, 27% (N=51) of the patients had a diagnosed heart or vascular disorder. Most of them were females (N=32, 62%), almost half of them were Asian (N=22, 43%) and a quarter (N=13, 25%) were European. The most common heart problem was patent ductus arteriosus (PDA) diagnosed in 7 patients (13.7%), 6 patients (11.8%) had coarctation of the aorta, 6 (11.8%) had ventricular septal defect and 5 (9.8%) had atrial septal defect (ASD). Heart failure was reported in five (9.8%) patients.

Diseases of the skin and subcutaneous tissue: Skin conditions were reported in 37 patients (19.8%). Neurocutaneous melanosis was the most common - observed in 11 (29.7%) of these patients - followed by hemangiomas (9 patients, 24.3% – including those who suffered from PHACE syndrome) and melanocytic nevi (N=6, 16.2%).

Diseases of the musculoskeletal system and connective tissue: Sixteen patients (9%) were reported to have musculoskeletal comorbidities; this was almost exclusively observed in patients with Dandy Walker malformation. Four of them (25%) had scoliosis/kyphoscoliosis while joint laxity was reported in three patients (18.8%).

Diseases of the genitourinary system: A total of 26 patients (14%) included in this review had mild or severe genitourinary problems. Ten patients (38.5%) had kidney malformations (polycystic kidneys/dysplastic kidney/agenesia/pelvic kidney), 7 (26.9%) had hypoplastic genitalia (poorly formed uterus/micropenis/concealed penis), and 4 (15.4%) had cryptorchidism/undescended testis.

Syndromes and chromosomal abnormalities: Approximately one third of the patients (N=62) were described to have a syndrome or chromosomal abnormality. A tenth of these patients had a parent diagnosed with DWS. The most common syndrome was PHACE Syndrome, which was reported in eight cases. Four patients (6.5%) had Edwards Syndrome (trisomy 18) and 4 (6.5%) had Joubert Syndrome.

DISCUSSION

Summary of findings

Dandy-Walker syndrome is a congenital malformation which is associated with a complex set of neurological as well as non-neurological medical conditions, as this review clearly demonstrated.

The review built up a case series of 187 patients, potentially allowing for some generalizations as well. The reported diagnosed patients were most often male, which contradicts older studies²⁷. Interestingly, almost half of the patients were diagnosed in the first year of life, which is consistent with published literature²⁸, however, the second peak for diagnosis (over a quarter of cases) was in young people older than 12 years old, where the syndrome is suspected usually due to mental health problems. As far as types are concerned, malformation was the most frequent, followed by variant, with the rest only being reported very rarely. A clear increased prevalence among Asian populations was extrapolated from this review; this may reflect poor access to prenatal diagnostic tests in certain settings and/or decrease in publication of cases from Europe (of note, most cases from a single country where from the US). Contrary to previous studies^{29 30}, no clear statistically important correlation between DWS in the offspring and clinical disease of the parents was found.

Comorbidities

The review resulted in interesting findings on non-neurological comorbidities. Of note, approximately a third of the patients with DWS, were reported to have a chromosomal abnormality or another genetic syndrome, the most frequent being PHACE Syndrome,

trisomy 18 and Joubert Syndrome, as has been described in the literature^{31,32}. Several malformation syndromes and cytogenetic abnormalities have been associated with Dandy Walker malformation and several genes have recently been implicated in its pathogenesis. These include ZIC1 and ZIC4 of chromosome 3q24 and it seems that the deletion of these genes in mice could account for associated defects similar to Dandy Walker malformation and differences in cerebellar size³²⁻³⁴. FOXC1, FGF17, LAMC1 and NID1 have also been associated with DWS². Several published reports have suggested that, there is a causal relationship between various types of chromosomal abnormalities and malformation syndromes³². In this review, it was indeed identified that trisomy 18 was the most frequent chromosomal abnormality and this is consistent with the literature as DWS has been reported to be a frequent complication of trisomy 18 and therefore, imaging tests should be conducted at an early stage³². It is more difficult to explain the potential association with PHACE Syndrome (Posterior fossa malformations–Hemangiomas–Arterial anomalies–Cardiac defects–Eye abnormalities–sternal cleft and supraumbilical raphe syndrome) which is a cutaneous condition linked to multiple congenital abnormalities. Although its pathogenesis, which implicates the neural crest, includes cerebellar involvement, the full mechanism has not been fully clarified yet³⁵.

The second most common group of comorbidities, occurring in a quarter of patients, was cardiovascular conditions, which is also consistent with the literature¹⁷. The basis for this association could well be in the suggested timing of the formation of DW malformation with a complex embryologic defect originating before the 6th week of gestational development. Given the significant number of patients with a heart defect, some of which may lead to heart failure, monitoring and awareness are important for the prognosis, especially in case of a shunting procedure¹. A recent published case report also highlighted the important association between DWS and vascular disease³⁶.

Other conditions reported in high numbers included diseases of the eye and ear and skin conditions, the most common being neurocutaneous melanosis. This is considered to follow from disorders in neurulation, the same that may cause the development of malformations like DWS. Meningeal cells are known to play a critical role in the neuromorphogenesis of the cerebellum and abnormal leptomeninges infiltrated by melanocytic cells may interfere with normal cerebellar development³⁷. The exact pathogenesis of DWS in this association, however, cannot be fully explained yet. In a different non-prevalent theory, melanocytic cells may cause atresia or obstruction in the outgoing foramen of the fourth ventricle leading to cystic dilatation³⁸.

The prevalence of mental health problems was an important finding of this review. Notably, most patients with mental/behavioral problems were from Europe, were diagnosed with variant and were older than 12 years, evidence that is not dissimilar to previous publications³⁹. This is not surprising as cognitive, affective and behavioural changes in psychiatric disorders have been linked to structural cerebellar abnormalities⁴⁰, including schizophrenia in which the cerebellum's role in cognition, particularly the role of the vermis, is very important⁴¹. Further, it is well known that patients diagnosed with ADHD disorder are unable to delay or inhibit a response, which is considered to be a central executive function, and cerebellum is one of the structures modulating this. Several studies have

already pointed toward cerebellar deficits in ADHD, and vermal volume was consistently found to be significantly smaller in children with this disorder^{35,39}. The key role of mental health problems in the prognosis of DWS patients is also clarified through three recent case reports which are mainly focused on bipolar disorder and mild cognitive impairment⁴²⁻⁴⁴.

Lastly, results on intellectual development are inconsistent. Some studies have reported that the majority of these children have a learning disability⁴⁵, with others suggesting that most of them have IQ in the normal range^{6,27}. Of note only 6.4% of DWS patients had mild or severe intellectual disability in our review

. Any extra-CNS diseases that coexist with DWS should be detected early, given that they play an important role in the development and health outcomes of these children^{45,46}. Postnatal outcomes vary from normal psychomotor development to severe disability or death, which highlights the importance of early diagnosis⁴⁷.

Strengths and Limitations

This review is presented as a proxy for reporting results on one of the largest cohorts of DWS patients ever pulled together in one study. It benefits from a strong standard methodology, and exhaustive reporting of all comorbidities in every of 187 patients reported. However, limitations to this review should be acknowledged. For reasons of access, only one database (Medline) was searched in one language (English). Second, only information referring to alive patients with Dandy-Walker Syndrome was included. Third, it should be noted that, given that there are no concrete classification criteria for the different types of DWS, outcomes reported may vary in different settings and studies, thus resulting in heterogeneity of reporting. This is further complicated by the rarity of the condition which suggests that most clinicians-authors would not be very familiar with its manifestations. Moreover, the fact that almost half of the case reports originate from Asian countries potentially leads to some degree of selection bias, though we were unable to extract from the literature if there has been a decrease in the interest of publishing such case reports in well-resourced settings like in North America. . Further, as mentioned previously and in an attempt to be inclusive, we included some cases which were recorded as “DW variant” or “complex” (terms not in wide use any more) as these terms have been used consistently by clinicians and researchers alike for several years. Finally, it should be noted that the comorbidities which were part of the syndromes described in this study were not reported separately and therefore, we could assume that certain medical conditions coexist more frequently with DWS.

Conclusion

Results from a secondary cohort of 187 patients with Dandy-Walker Syndrome highlight various genetic, cardiac and mental health abnormalities of importance as comorbidities to the syndrome, while clarifies the – previously thought higher – rates for intellectual disability

and cancer. Given the rarity of the condition internationally, future research should more realistically focus on exploring the pathophysiological mechanisms between some of these correlations to lead into targeted treatment and prevention. Comorbidities impact heavily on the prognosis and quality of life of patients, thus early diagnosis (over a quarter of DWS cases are still diagnosed after the age of 12 years) and multi-specialist approaches based on these epidemiological findings could help towards making a difference for this patient group, especially as many DWS cases lead a subclinical course for many years.

Acknowledgements: None

Author Contributions:

ES: literature search, data extraction, data analysis, text drafting, text editing, final manuscript approval

MII: literature search, data extraction, data analysis, text drafting, text editing, final manuscript approval

KK: data interpretation, critical revision of manuscript, text editing, final manuscript approval

MD: data extraction, data interpretation, text drafting, text editing, final manuscript approval

AAK: study concept, study design, critical revision of manuscript, text editing, final manuscript approval

Disclosure of conflict of interest: The Authors declare that there is no conflict of interest.

Study Funding: This research received no specific grant from any funding agency in the public, commercial, or not-for-profit sectors.

Ethical Approval: Not applicable

References

1. Spennato P, Mirone G, Nastro A, et al. Hydrocephalus in Dandy-Walker malformation. *Childs Nerv Syst.* Oct 2011;27(10):1665-1681.
2. Bosemani T, Orman G, Boltshauser E, Tekes A, Huisman TA, Poretti A. Congenital abnormalities of the posterior fossa. *Radiographics.* Jan-Feb 2015;35(1):200-220.
3. Waters DD, Ho JE, Boekholdt SM, et al. Cardiovascular event reduction versus new-onset diabetes during atorvastatin therapy: effect of baseline risk factors for diabetes. *J Am Coll Cardiol.* Jan 15 2013;61(2):148-152.
4. McClelland S, 3rd, Charnas LR, SantaCruz KS, Garner HP, Lam CH. Progressive brainstem compression in an infant with neurocutaneous melanosis and Dandy-Walker complex following ventriculoperitoneal shunt placement for hydrocephalus. Case report. *J Neurosurg.* Dec 2007;107(6 Suppl):500-503.
5. Bragg TW, St George EJ, Wynne-Jones GA, Hockley A, Morton JE. Familial Dandy-Walker syndrome: a case report supporting an autosomal inheritance. *Childs Nerv Syst.* May 2006;22(5):539-541.
6. Ecker JL, Shipp TD, Bromley B, Benacerraf B. The sonographic diagnosis of Dandy-Walker and Dandy-Walker variant: associated findings and outcomes. *Prenat Diagn.* Apr 2000;20(4):328-332.
7. Ichizuka K, Mishina M, Hasegawa J, Matsuoka R, Sekizawa A, Pooh RK. Diagnosis of a case of Dandy-Walker malformation aided by measurement of the brainstem-vermis angle at 14 weeks gestation. *J Obstet Gynaecol Res.* May 2015;41(5):790-793.
8. Noroozian M. The role of the cerebellum in cognition: beyond coordination in the central nervous system. *Neurol Clin.* Nov 2014;32(4):1081-1104.
9. Economou A, Katsetos CD. Patterns of cognitive and fine motor deficits in a case of Dandy-Walker continuum. *J Child Neurol.* Jul 2012;27(7):930-937.
10. Boddaert N, Klein O, Ferguson N, et al. Intellectual prognosis of the Dandy-Walker malformation in children: the importance of vermian lobulation. *Neuroradiology.* May 2003;45(5):320-324.
11. Bokhari I, Rehman L, Hassan S, Hashim MS. Dandy-Walker Malformation: A Clinical and Surgical Outcome Analysis. *J Coll Physicians Surg Pak.* Jun 2015;25(6):431-433.
12. Ryan M, Grenier E, Castro A, Nemeroff CB. New-onset psychosis associated with dandy-walker variant in an adolescent female patient. *J Neuropsychiatry Clin Neurosci.* Spring 2012;24(2):241-246.
13. Aimua F, Dunn NR, Swift RG. Dandy walker variant with treatment-resistant bipolar disorder. *J Neuropsychiatry Clin Neurosci.* Winter 2012;24(1):E50.
14. Kim JH, Kim TH, Choi YC, Chung SC, Moon SW. Impulsive behavior and recurrent major depression associated with dandy-walker variant. *Psychiatry Investig.* Sep 2013;10(3):303-305.
15. Teslaa JJ, Keller AN, Nyholm MK, Grinblat Y. Zebrafish Zic2a and Zic2b regulate neural crest and craniofacial development. *Dev Biol.* Aug 1 2013;380(1):73-86.
16. Owler BK, Halmagyi GM, Brennan J, Besser M. Syringomyelia with Chiari malformation; 3 unusual cases with implications for pathogenesis. *Acta Neurochir (Wien).* Oct 2004;146(10):1137-1143; discussion 1143.
17. Kurdi ME, Chamsi-Pasha MA, Baeesa SS, Jan MM. Dandy Walker malformation and hypertrophic cardiomyopathy. Unusual fatal association. *Neurosciences (Riyadh).* Oct 2009;14(4):368-370.
18. Hussain Z, Masroor I, Haider QU, Alam T. Goldston syndrome. *J Coll Physicians Surg Pak.* Apr 2011;21(4):242-244.

19. Russ PD, Pretorius DH, Johnson MJ. Dandy-Walker syndrome: a review of fifteen cases evaluated by prenatal sonography. *Am J Obstet Gynecol.* Aug 1989;161(2):401-406.
20. Infante JR, Garcia L, Rayo JI, Serrano J, Dominguez ML, Moreno M. PET/CT in a Patient Diagnosed With Dandy-Walker Syndrome. *Clin Nucl Med.* Jan 2016;41(1):e58-59.
21. Walbert T, Sloan AE, Cohen ML, Koubeissi MZ. Symptomatic neurocutaneous melanosis and Dandy-Walker malformation in an adult. *J Clin Oncol.* Jun 10 2009;27(17):2886-2887.
22. Ghosh A, Tibrewal SR, Thapa R. PHACES syndrome with congenital hypothyroidism. *Indian Pediatr.* Feb 2007;44(2):144-147.
23. Ramieri V, Tarani L, Costantino F, et al. Microdeletion 3q syndrome. *J Craniofac Surg.* Nov 2011;22(6):2124-2128.
24. Lim FF, Ng YY, Hu JM, Chen SJ, Su PH, Chen JY. Ocular findings in a case of trisomy 18 with variant of Dandy-Walker syndrome. *Pediatr Neonatol.* Oct 2010;51(5):292-295.
25. Valderas JM, Starfield B, Sibbald B, Salisbury C, Roland M. Defining comorbidity: implications for understanding health and health services. *Ann Fam Med.* Jul-Aug 2009;7(4):357-363.
26. Moher D, Shamseer L, Clarke M, et al. Preferred reporting items for systematic review and meta-analysis protocols (PRISMA-P) 2015 statement. *Systematic reviews.* 2015;4:1.
27. Kolble N, Wisser J, Kurmanavicius J, et al. Dandy-walker malformation: prenatal diagnosis and outcome. *Prenat Diagn.* Apr 2000;20(4):318-327.
28. Limperopoulos C, du Plessis AJ. Disorders of cerebellar growth and development. *Curr Opin Pediatr.* Dec 2006;18(6):621-627.
29. Titlic M, Alfirovic S, Kolic K, Soldo A, Tripalol AB. Morphological manifestations of the Dandy-Walker syndrom in female members of a family. *Coll Antropol.* Mar 2015;39(1):225-228.
30. Has R, Ermis H, Yuksel A, et al. Dandy-Walker malformation: a review of 78 cases diagnosed by prenatal sonography. *Fetal Diagn Ther.* Jul-Aug 2004;19(4):342-347.
31. Nyberg DA, Mahony BS, Hegge FN, Hickok D, Luthy DA, Kapur R. Enlarged cisterna magna and the Dandy-Walker malformation: factors associated with chromosome abnormalities. *Obstet Gynecol.* Mar 1991;77(3):436-442.
32. Imataka G, Yamanouchi H, Arisaka O. Dandy-Walker syndrome and chromosomal abnormalities. *Congenit Anom (Kyoto).* Dec 2007;47(4):113-118.
33. Grinberg I, Northrup H, Ardinger H, Prasad C, Dobyns WB, Millen KJ. Heterozygous deletion of the linked genes ZIC1 and ZIC4 is involved in Dandy-Walker malformation. *Nat Genet.* Oct 2004;36(10):1053-1055.
34. Blank MC, Grinberg I, Aryee E, et al. Multiple developmental programs are altered by loss of Zic1 and Zic4 to cause Dandy-Walker malformation cerebellar pathogenesis. *Development.* Mar 2011;138(6):1207-1216.
35. Bhattacharya A, Desarkar P, Haque S. A case of Dandy-Walker variant disorder associated with multiple neuropsychiatric comorbidities managed with behavioral therapy. *J Neuropsychiatry Clin Neurosci.* Summer 2013;25(3):E03-04.
36. Han Z, Du Y, Qi H, Yin W. Aplasia of the Internal Carotid Artery with Dandy-Walker Variant. *J Clin Neurol.* Jan 2016;12(1):119-120.
37. Marnet D, Vinchon M, Mostofi K, Catteau B, Kerdraon O, Dhellemmes P. Neurocutaneous melanosis and the Dandy-Walker complex: an uncommon but not so insignificant association. *Childs Nerv Syst.* Dec 2009;25(12):1533-1539.
38. Mena-Cedillos CA, Valencia-Herrera AM, Arroyo-Pineda AI, et al. Neurocutaneous melanosis in association with the Dandy-Walker complex, complicated by

- melanoma: report of a case and literature review. *Pediatr Dermatol*. May-Jun 2002;19(3):237-242.
39. Prakash R, Singh LK, Kour J, Mishra B, Lakra A. Psychiatric comorbidities in Dandy-Walker variant disorder. *J Neuropsychiatry Clin Neurosci*. Fall 2009;21(4):477-479.
 40. Timmann D, Daum I. Cerebellar contributions to cognitive functions: a progress report after two decades of research. *Cerebellum*. 2007;6(3):159-162.
 41. Kvitvik Aune I, Bugge E. Schizophrenia in a young man with Dandy-Walker variant. *Biol Psychiatry*. Mar 1 2014;75(5):e9-10.
 42. Gross PL, Kays JL, Shura RD. Neuropsychological Function in a Case of Dandy-Walker Variant in a 68-Year-Old Veteran. *Appl Neuropsychol Adult*. Jan-Feb 2016;23(1):70-74.
 43. Eslami Shahre Babaki M, Estilae F. Bipolar Disorder in a Young Girl with Dandy-Walker Syndrome. *Iran J Psychiatry*. Jun 2015;10(3):212-213.
 44. Baliyan S, Arya A, Kar SK. Treatment-resistant mania in Dandy-Walker malformation with seizure disorder: A case report. *J Pediatr Neurosci*. Oct-Dec 2015;10(4):413-414.
 45. Aletobi FA, Fung KF. Neurodevelopmental outcome after antenatal diagnosis of posterior fossa abnormalities. *J Ultrasound Med*. Oct 1999;18(10):683-689.
 46. Correa GG, Amaral LF, Vedolin LM. Neuroimaging of Dandy-Walker malformation: new concepts. *Top Magn Reson Imaging*. Dec 2011;22(6):303-312.
 47. Bolduc ME, Limperopoulos C. Neurodevelopmental outcomes in children with cerebellar malformations: a systematic review. *Dev Med Child Neurol*. Apr 2009;51(4):256-267.

Figure 1. Flow chart

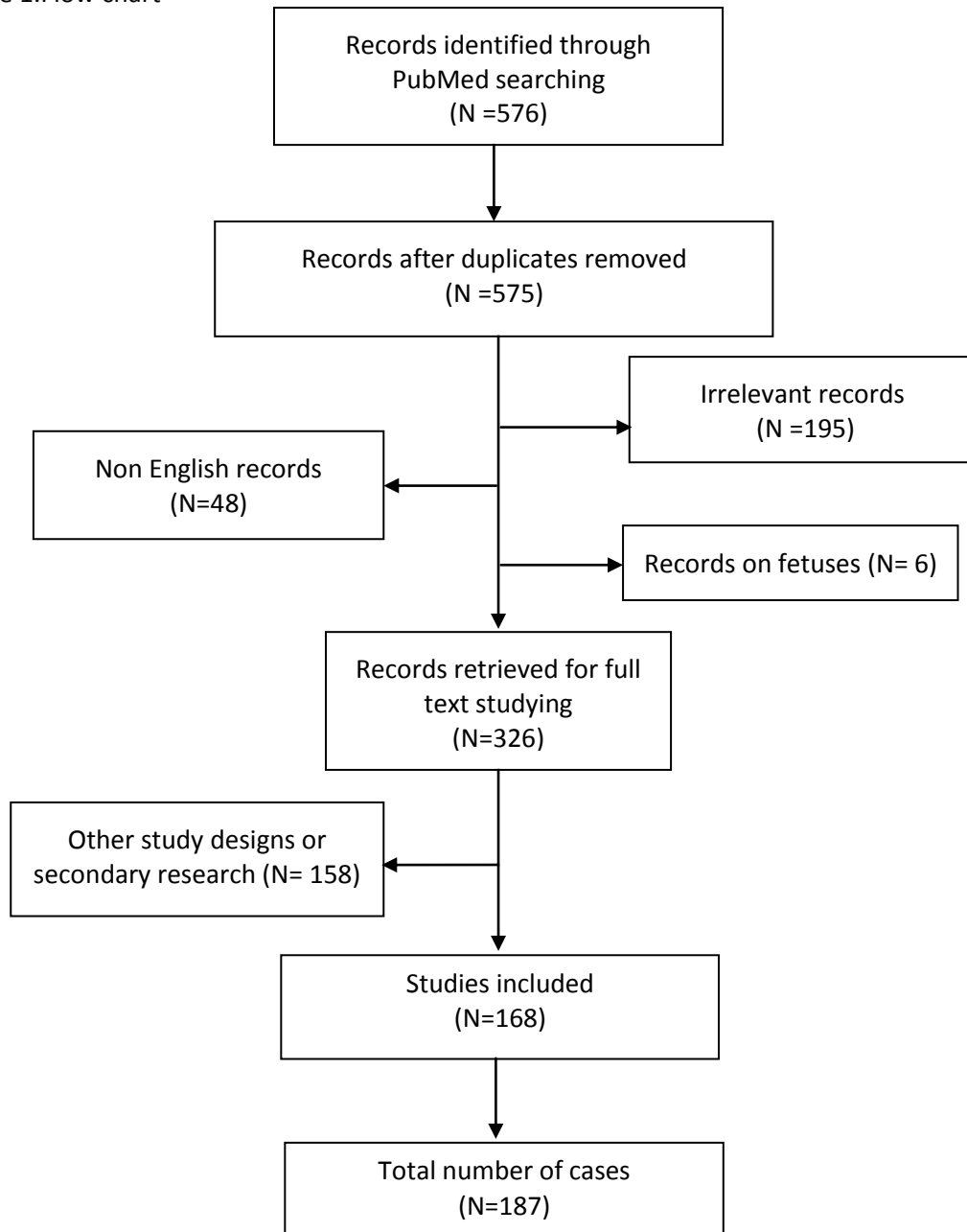


Table 1: Baseline characteristics of all included studies

Study Name	Continent	Sex	Age group	Type	Consanguinity	Siblings with DW
Walch et al, 2000 ¹	Europe	F	1-12m	Malformation	No	No
Koul et al, 2000 ²	Asia	M	13m-3y	Syndrome	N/A	Yes
Koul et al, 2000 ²	Asia	M	13m-3y	Syndrome	N/A	Yes
Pallotta et al, 2000 ³	Europe	F	5-12y	Variant	N/A	N/A
Matsuura et al, 2000 ⁴	Asia	M	1-12m	Malformation	N/A	N/A
Matsuura et al, 2000 ⁴	Asia	M	13m-3y	Malformation	N/A	N/A
Poetke et al, 2000 ⁵	Europe	N/A	13m-3y	Malformation	N/A	N/A
Poetke et al, 2000 ⁵	Europe	N/A	13m-3y	Malformation	N/A	N/A
Poetke et al, 2000 ⁵	Europe	N/A	13m-3y	Malformation	N/A	N/A
Haug et al, 2000 ⁶	Asia	F	1-12m	Malformation	No	Yes
Haug et al, 2000 ⁶	Asia	M	1-12m	Malformation	No	Yes
Ben Hamouda et al, 2001 ⁷	Africa	M	1-12m	Syndrome	N/A	N/A
Arslanoglu et al, 2001 ⁸	Asia	N/A	N/A	Complex	Yes	Yes
Gulcan et al, 2001 ⁹	Asia	M	N/A	Malformation	N/A	N/A
Fan et al, 2001 ¹⁰	North America	M	<1m	Malformation	No	No
Lapunzina et al, 2001 ¹¹	South America	F	<1m	Malformation	No	No
Gilbert- Barness et al, 2001 ¹²	North America	M	<1m	Malformation	No	No
Sudha et al, 2001 ¹³	North America	F	5-12y	Variant	No	No
McKee et al, 2001 ¹⁴	Asia	F	3-5y	Malformation	Yes	No
Imai et al, 2001 ¹⁵	Asia	M	1-12m	Variant	No	No
Kajii et al, 2001 ¹⁶	Asia	M	1-12m	Complex	No	No
Kajii et al, 2001 ¹⁶	Asia	F	3-5y	Complex	No	No
Kajii et al, 2001 ¹⁶	Asia	F	1-12m	Complex	No	No
Kajii et al, 2001 ¹⁶	Asia	F	13m-3y	Complex	No	No
Kajii et al, 2001 ¹⁶	Asia	M	13m-3y	Complex	No	Yes
Kajii et al, 2001 ¹⁶	Asia	M	1-12m	Complex	No	Yes
Gulati et al, 2002 ¹⁷	Asia	M	1-12m	Complex	No	No
Kisato et al, 2002 ¹⁸	Asia	M	1-12m	Malformation	N/A	N/A
Yoder et al, 2002 ¹⁹	North America	M	13m-3y	Malformation	N/A	N/A
Wieselthaler et al, 2002 ²⁰	Africa	M	5-12y	Variant	No	No
Mena-Cedillos et al, 2002 ²¹	North America	M	3-5y	Malformation	No	No
Hadzikaric et al, 2002 ²²	Asia	M	13m-3y	Syndrome	N/A	N/A

Hammond et al, 2002 ²³	Europe	M	>12y	Complex	N/A	N/A
Peters et al, 2002 ²⁴	Europe	M	13m-3y	Malformation	N/A	N/A
Freeman et al, 2002 ²⁵	Europe	M	>12y	Syndrome	N/A	N/A
Toriello et al, 2002 ²⁶	North America	F	1-12m	Malformation	N/A	N/A
Aslan et al, 2002 ²⁷	Asia	M	<1m	Malformation	Yes	No
Lin et al, 2003 ²⁸	Asia	F	1-12m	Malformation	N/A	N/A
Furukawa et al, 2003 ²⁹	Asia	N/A	N/A	Malformation	N/A	N/A
Dinakar et al, 2003 ³⁰	Europe	F	5-12y	Malformation	Yes	No
Panteliadis et al, 2003 ³¹	Europe	F	13m-3y	Malformation	N/A	N/A
Hedera et al, 2003 ³²	North America	M	<1m	Malformation	N/A	N/A
Litzman et al, 2003 ³³	Europe	F	>12y	Syndrome	No	No
Erdal et al, 2003 ³⁴	Asia	N/A	N/A	Complex	N/A	N/A
Cazorla Calleja et al, 2003 ³⁵	Europe	F	1-12m	Malformation	No	No
McCormack Jr et al, 2003 ³⁶	North America	N/A	N/A	Malformation	N/A	N/A
McCormack Jr et al, 2003 ³⁶	North America	N/A	N/A	Malformation	N/A	N/A
Muzumdar et al, 2004 ³⁷	Asia	F	1-12m	Malformation	No	No
Arai et al, 2004 ³⁸	Asia	N/A	N/A	Malformation	N/A	N/A
Mohammadi et al, 2004 ³⁹	Asia	F	1-12m	Malformation	N/A	N/A
Tubbs et al, 2004 ⁴⁰	North America	F	13m-3y	Variant	N/A	N/A
Ueno et al, 2004 ⁴¹	Asia	M	>12y	Malformation	N/A	N/A
Owler et al, 2004 ⁴²	Oceania	F	>12y	Malformation	N/A	N/A
Prieto Espuñes et al, 2004 ⁴³	Europe	F	<1m	Malformation	N/A	N/A
Weinzieri et al, 2005 ⁴⁴	Europe	N/A	<1m	Malformation	N/A	N/A
Ross et al, 2005 ⁴⁵	Oceania	F	1-12m	Malformation	No	No
Castro Conde et al, 2005 ⁴⁶	Europe	M	<1m	Variant	No	No
Sun et al, 2005 ⁴⁷	North America	F	<1m	Malformation	No	No
de Azevedo Moreira et al, 2005 ⁴⁸	South America	F	1-12m	Malformation	No	No
Teksam et al, 2005 ⁴⁹	Asia	F	1-12m	Malformation	Yes	No

Ounap et al, 2005 ⁵⁰	Europe	F	<1m	Malformation	No	No
Iyer et al, 2005 ⁵¹	N/A	F	N/A	Malformation	N/A	N/A
Klein et al, 2005 ⁵²	North America	M	5-12y	Malformation	No	No
Pascual-Castroviejo et al, 2005 ⁵³	Europe	N/A	N/A	Complex	No	No
Pascual-Castroviejo et al, 2005 ⁵³	Europe	N/A	N/A	Complex	No	No
Kolomietz et al, 2005 ⁵⁴	North America	F	1-12m	Malformation	No	No
Prasad et al, 2006 ⁵⁵	Asia	N/A	<1m	Malformation	N/A	N/A
Weimer et al, 2006 ⁵⁶	Europe	F	<1m	Variant	N/A	No
Menon et al, 2006 ⁵⁷	Asia	F	>12y	Malformation	N/A	N/A
Kim et al, 2006 ⁵⁸	Asia	M	>12y	Malformation	No	No
Chen et al, 2006 ⁵⁹	Asia	M	5-12y	Variant	N/A	N/A
Cappellacci et al, 2006 ⁶⁰	Europe	M	5-12y	Malformation	No	No
Kang et al, 2006 ⁶¹	Asia	M	N/A	Malformation	N/A	N/A
Richter et al, 2006 ⁶²	North America	F	<1m	Malformation	N/A	N/A
Kalayci et al, 2006 ⁶³	Asia	F	<1m	Malformation	No	No
Akgul et al, 2006 ⁶⁴	Asia	F	>12y	Variant	N/A	N/A
Cannady et al, 2006 ⁶⁵	North America	F	<1m	Malformation	N/A	N/A
Caceres et al, 2006 ⁶⁶	North America	F	1-12m	Complex	N/A	N/A
Abdel-Salam et al, 2006 ⁶⁷	Africa	M	3-5y	Malformation	Yes	Yes
Abdel-Salam et al, 2006 ⁶⁷	Africa	M	13m-3y	Malformation	Yes	Yes
McPherson et al, 2006 ⁶⁸	North America	M	<1m	Malformation	No	No
Su et al, 2007 ⁶⁹	Asia	F	<1m	Malformation	N/A	N/A
McClelland et al, 2007 ⁷⁰	North America	M	1-12m	Complex	N/A	N/A
De Brito Henriques et al, 2007 ⁷¹	South America	F	N/A	Syndrome	N/A	N/A
Sener, 2007 ⁷²	Asia	F	1-12m	Malformation	Yes	N/A
Aluclu et al, 2007 ⁷³	Asia	M	>12y	Malformation	N/A	N/A
Papazisis et al, 2007 ⁷⁴	Europe	M	>12y	Variant	N/A	N/A
Poot et al, 2007 ⁷⁵	Europe	M	5-12y	Complex	No	No
Cardoso et al, 2007 ⁷⁶	South America	F	>12y	Syndrome	No	No
Ghosh et al, 2007 ⁷⁷	Asia	F	<1m	Malformation	No	No
Humphries et al, 2007 ⁷⁸	North America	F	>12y	Variant	N/A	N/A
Vundinti et al,	Asia	M	3-5y	Malformation	No	N/A

2007 ⁷⁹						
Ferentinos et al, 2007 ⁸⁰	Europe	F	>12y	Mega Cisterna Magna	N/A	N/A
Zechi-Ceide et al, 2007 ⁸¹	South America	N/A	N/A	Variant	No	Yes
Zechi-Ceide et al, 2007 ⁸¹	South America	N/A	N/A	Variant	No	Yes
Zechi-Ceide et al, 2007 ⁸¹	South America	N/A	N/A	Variant	No	Yes
Hou et al, 2008 ⁸²	Asia	M	1-12m	Variant	No	No
van Steensel et al, 2008 ⁸³	Europe	M	>12y	Malformation	No	No
Herman et al, 2008 ⁸⁴	North America	M	1-12m	Malformation	N/A	N/A
Saatci et al, 2008 ⁸⁵	Asia	M	13m-3y	Variant	No	No
Cakmak et al, 2008 ⁸⁶	Asia	M	<1m	Malformation	N/A	N/A
Schreml et al, 2008 ⁸⁷	Europe	F	5-12y	Malformation	N/A	N/A
Warwick et al, 2008 ⁸⁸	North America	F	>12y	Malformation	N/A	N/A
Cushing et al, 2008 ⁸⁹	North America	F	1-12m	Malformation	N/A	N/A
Kasliwal et al, 2008 ⁹⁰	Asia	N/A	13m-3y	Malformation	N/A	N/A
Kurdi et al, 2009 ⁹¹	Asia	M	1-12m	Malformation	Yes	N/A
Nagdeve et al, 2009 ⁹²	Asia	F	1-12m	Malformation	N/A	N/A
Caglayan et al, 2009 ⁹³	Asia	F	1-12m	Malformation	No	No
Venturini et al, 2009 ⁹⁴	Europe	M	>12y	Malformation	N/A	N/A
Murugesan et al, 2009 ⁹⁵	Asia	M	>12y	Malformation	N/A	N/A
Marnet et al, 2009 ⁹⁶	Europe	M	>12y	Complex	N/A	N/A
Lingeswaran et al, 2009 ⁹⁷	Asia	M	5-12y	Variant	N/A	N/A
Cultrera et al, 2009 ⁹⁸	Europe	M	>12y	Variant	N/A	N/A
Linder et al, 2009 ⁹⁹	North America	M	1-12m	Complex	No	No
Gönül et al, 2009 ¹⁰⁰	Asia	F	>12y	Malformation	No	No
Ozdemir et al, 2009 ¹⁰¹	Asia	F	1-12m	Variant	Yes	No
Walbert et al, 2009 ¹⁰²	North America	F	>12y	Malformation	N/A	N/A
Masdeu et al, 2009 ¹⁰³	Europe	M	>12y	Malformation	N/A	N/A
Zhang et al, 2009 ¹⁰⁴	Asia	F	>12y	Malformation	No	No

Sato et al, 2009 ¹⁰⁵	North America	M	>12y	Malformation	N/A	N/A
Surányi et al, 2009 ¹⁰⁶	Europe	M	1-12m	Malformation	N/A	N/A
Al-Adnani et al, 2009 ¹⁰⁷	Europe	N/A	N/A	Malformation	Yes	N/A
Panas et al, 2005 ¹⁰⁸	Europe	M	>12y	Complex	No	Yes
Panas et al, 2005 ¹⁰⁸	Europe	M	>12y	Complex	No	Yes
Coban et al, 2010 ¹⁰⁹	Asia	M	<1m	Malformation	No	No
Lim et al, 2010 ¹¹⁰	Asia	F	1-12m	Variant	No	No
Sartori et al, 2010 ¹¹¹	Africa	M	1-12m	Malformation	No	No
Mademont-Soler et al, 2010 ¹¹²	Europe	F	>12y	Malformation	No	No
Stoodley et al, 2010 ¹¹³	North America	M	>12y	Malformation	N/A	N/A
Coulibaly et al, 2010 ¹¹⁴	Europe	M	1-12m	Malformation	Yes	No
Mytilinaios et al, 2010 ¹¹⁵	Europe	N/A	>12y	Variant	N/A	N/A
Unal et al, 2010 ¹¹⁶	Asia	M	1-12m	Malformation	No	No
Stevens et al, 2010 ¹¹⁷	South America	M	<1m	Malformation	No	Yes
Stevens et al, 2010 ¹¹⁷	South America	F	<1m	Malformation	No	Yes
Ramieri et al, 2011 ¹¹⁸	Europe	M	3-5y	Malformation	N/A	N/A
Marchal et al, 2011 ¹¹⁹	Europe	F	>12y	Malformation	N/A	N/A
Gverić-Ahmetasević et al, 2011 ¹²⁰	Europe	F	1-12m	Malformation	No	No
Yahyaoui et al, 2011 ¹²¹	Europe	F	<1m	Variant	N/A	N/A
Tohyama et al, 2011 ¹²²	Asia	F	1-12m	Malformation	No	No
Murphy-Ryan et al, 2011 ¹²³	North America	M	1-12m	Malformation	No	No
Hu et al, 2011 ¹²⁴	Asia	F	1-12m	Malformation	N/A	N/A
Turan et al, 2011 ¹²⁵	Asia	M	>12y	Mega Cisterna Magna	N/A	N/A
Love et al, 2011 ¹²⁶	Europe	M	3-5y	Malformation	No	No
Bunch et al, 2011 ¹²⁷	North America	F	>12y	Variant	No	No
Tanoue et al, 2011 ¹²⁸	Asia	F	13m-3y	Variant	N/A	N/A
Talamonti et al, 2011 ¹²⁹	Africa	M	5-12y	Malformation	N/A	N/A
Hussain et al, 2011 ¹³⁰	Asia	N/A	<1m	Malformation	N/A	N/A

Al-Achkar et al, 2011 ¹³¹	Asia	M	1-12m	Complex	No	No
Amin, 2012 ¹³²	Asia	F	5-12y	Variant	N/A	N/A
Mancini et al, 2012 ¹³³	South America	M	13m-3y	Variant	No	No
Manel et al, 2012 ¹³⁴	Africa	F	<1m	Malformation	Yes	No
Aimua et al, 2012 ¹³⁵	North America	F	>12y	Variant	N/A	N/A
Beby et al, 2012 ¹³⁶	Europe	M	3-5y	Malformation	N/A	N/A
Kim et al, 2012 ¹³⁷	Asia	F	1-12m	Variant	N/A	N/A
Cho et al, 2011 ¹³⁸	Asia	F	1-12m	Malformation	N/A	N/A
Economou et al, 2012 ¹³⁹	Europe	F	5-12y	Variant	No	No
Badakali et al, 2012 ¹⁴⁰	Asia	F	1-12m	Malformation	Yes	N/A
Domínguez et al, 2012 ¹⁴¹	South America	F	>12y	Malformation	N/A	N/A
Kara et al, 2012 ¹⁴²	Asia	M	>12y	Malformation	No	No
Kim et al, 2012 ¹⁴³	Asia	M	5-12y	Malformation	No	No
Ryan et al, 2012 ¹⁴⁴	Asia	F	>12y	Variant	N/A	N/A
Azukizawa et al, 2013 ¹⁴⁵	Asia	F	1-12m	Malformation	No	No
Searson et al, 2013 ¹⁴⁶	Europe	M	>12y	Variant	N/A	N/A
Kim et al, 2013 ¹⁴⁷	Asia	M	>12y	Variant	No	No
Mandiwanza et al, 2013 ¹⁴⁸	Europe	M	13m-3y	Malformation	N/A	N/A
Hackmann et al, 2013 ¹⁴⁹	Europe	F	>12y	Malformation	No	No
Dhupar et al, 2012 ¹⁵⁰	Asia	M	1-12m	Malformation	N/A	N/A
Pai et al, 2013 ¹⁵¹	Asia	F	>12y	Malformation	N/A	N/A
Zhang et al, 2013 ¹⁵²	Asia	M	>12y	Malformation	No	No
Jang et al, 2013 ¹⁵³	Asia	M	>12y	Malformation	N/A	N/A
Passalacqua et al, 2013 ¹⁵⁴	South America	F	1-12m	Malformation	No	No
Zhou et al, 2013 ¹⁵⁵	North America	F	>12y	Variant	N/A	N/A
John et al, 2013 ¹⁵⁶	Asia	M	13m-3y	Variant	Yes	No
De Crecchio et al, 2013 ¹⁵⁷	Europe	M	N/A	Complex	No	Yes
De Crecchio et al, 2013 ¹⁵⁷	Europe	F	N/A	Complex	No	Yes
Guilherme et al, 2013 ¹⁵⁸	South America	F	>12y	Variant	No	No
Bhattacharya et al, 2013 ¹⁵⁹	Asia	M	3-5y	Variant	No	No
Sidana et, 2013 ¹⁶⁰	Asia	M	>12y	Variant	N/A	N/A
Graf et al, 2013 ¹⁶¹	Europe	M	>12y	Variant	N/A	N/A

Mama et al, 2014 ¹⁶²	Africa	F	>12y	Malformation	N/A	N/A
De Cock et al, 2014 ¹⁶³	Europe	M	1-12m	Malformation	N/A	N/A
Rodríguez et al, 2014 ¹⁶⁴	Europe	F	1-12m	Malformation	No	No
Na et al, 2014 ¹⁶⁵	Asia	F	>12y	Malformation	N/A	N/A
Buonaquero et al, 2014 ¹⁶⁶	Europe	F	>12y	Complex	No	No
Gathwala et al, 2014 ¹⁶⁷	Asia	M	<1m	Variant	No	No
Pandurangi et al, 2014 ¹⁶⁸	Asia	M	>12y	Complex	No	No
Pandurangi et al, 2014 ¹⁶⁸	Asia	M	>12y	Complex	No	No
Abbreviations: DW: Dandy-Walker, F: Female, M: Male, N/A: Not Available, y: years old						

References:

1. Walch E, Schmidt M, Brenner RE, et al. Yunis-Varon syndrome: evidence for a lysosomal storage disease. *American journal of medical genetics*. Nov 13 2000;95(2):157-160.
2. Koul RL, Chacko A, Leven HO. Dandy-Walker syndrome in association with neurofibromatosis in monozygotic twins. *Saudi medical journal*. Apr 2000;21(4):390-392.
3. Pallotta R, Ehresmann T, Fusilli P. Occurrence of Dandy-Walker anomaly in a familial case of distal arthrogryposis type IIB. *American journal of medical genetics*. Dec 18 2000;95(5):477-481.
4. Matsuura S, Ito E, Tauchi H, Komatsu K, Ikeuchi T, Kajii T. Chromosomal instability syndrome of total premature chromatid separation with mosaic variegated aneuploidy is defective in mitotic-spindle checkpoint. *American journal of human genetics*. Aug 2000;67(2):483-486.
5. Poetke M, Bultmann O, Berlien HP. Association of large facial hemangiomas with Dandy-Walker syndrome. Case study concerning three infants. *European journal of pediatric surgery : official journal of Austrian Association of Pediatric Surgery ... [et al] = Zeitschrift fur Kinderchirurgie*. Apr 2000;10(2):125-129.
6. Haug K, Khan S, Fuchs S, Konig R. OFD II, OFD VI, and Joubert syndrome manifestations in 2 sibs. *American journal of medical genetics*. Mar 13 2000;91(2):135-137.
7. Ben Hamouda H, Sfar MN, Braham R, et al. Association of severe autosomal recessive osteopetrosis and Dandy-Walker syndrome with agenesis of the corpus callosum. *Acta orthopaedica Belgica*. Dec 2001;67(5):528-532.
8. Arslanoglu S, Yalaz M, Goksen D, et al. Molybdenum cofactor deficiency associated with Dandy-Walker complex. *Brain & development*. Dec 2001;23(8):815-818.
9. Gulcan YH, Duman N, Kumral A, et al. Goldston syndrome: report of a case. *Genetic counseling (Geneva, Switzerland)*. 2001;12(3):263-267.
10. Fan YS, Siu VM. Molecular cytogenetic characterization of a derivative chromosome 8 with an inverted duplication of 8p21.3-->p23.3 and a rearranged duplication of 8q24.13-->qter. *American journal of medical genetics*. Aug 15 2001;102(3):266-271.
11. Lapunzina P, Musante G, Pedraza A, Prudent L, Gadow E. Semilobar holoprosencephaly, coronal craniosynostosis, and multiple congenital anomalies: a severe expression of the Genoa syndrome or a newly recognized syndrome? *American journal of medical genetics*. Aug 15 2001;102(3):258-260.
12. Gilbert-Barnes E, Debich-Spicer D, Cohen MM, Jr., Opitz JM. Evidence for the "midline" hypothesis in associated defects of laterality formation and multiple midline anomalies. *American journal of medical genetics*. Jul 15 2001;101(4):382-387.
13. Sudha T, Dawson AJ, Prasad AN, Konkin D, de Groot GW, Prasad C. De novo interstitial long arm deletion of chromosome 3 with facial dysmorphism, Dandy-Walker variant malformation and hydrocephalus. *Clinical dysmorphology*. Jul 2001;10(3):193-196.
14. McKee SA, Barnicoat A, Fryer A, Flinter F, McCormick D, McKeown C. Joint and skin laxity with Dandy-Walker malformation and contractures: a distinct recessive syndrome? *Clinical dysmorphology*. Jul 2001;10(3):177-180.
15. Imai T, Hattori H, Miyazaki M, Higuchi Y, Adachi S, Nakahata T. Dandy-Walker variant in Coffin-Siris syndrome. *American journal of medical genetics*. Apr 22 2001;100(2):152-155.

16. Kajii T, Ikeuchi T, Yang ZQ, et al. Cancer-prone syndrome of mosaic variegated aneuploidy and total premature chromatid separation: report of five infants. *American journal of medical genetics*. Nov 15 2001;104(1):57-64.
17. Gulati S, Gera S, Menon PS, Kabra M, Kalra V. Hypothalamic hamartoma, gelastic epilepsy, precocious puberty--a diffuse cerebral dysgenesis. *Brain & development*. Dec 2002;24(8):784-786.
18. Kisato Y, Nishikubo T, Uchida Y, et al. Hepatoblastoma in a low-birthweight infant complicated with cleft palate, Dandy-Walker malformation and chronic lung disease. *Pediatrics international : official journal of the Japan Pediatric Society*. Dec 2002;44(6):698-701.
19. Yoder BJ, Prayson RA. Shah-Waardenburg syndrome and Dandy-Walker malformation: an autopsy report. *Clinical neuropathology*. Sep-Oct 2002;21(5):236-240.
20. Wieselthaler NA, van Toorn R, Wilmshurst JM. Giant congenital melanocytic nevi in a patient with brain structural malformations and multiple lipomatosis. *Journal of child neurology*. Apr 2002;17(4):289-291.
21. Mena-Cedillos CA, Valencia-Herrera AM, Arroyo-Pineda AI, et al. Neurocutaneous melanosis in association with the Dandy-Walker complex, complicated by melanoma: report of a case and literature review. *Pediatric dermatology*. May-Jun 2002;19(3):237-242.
22. Hadzikaric N, Nasser M, Mashani A, Ammar A. CSF hydrothorax--VP shunt complication without displacement of a peritoneal catheter. *Child's nervous system : ChNS : official journal of the International Society for Pediatric Neurosurgery*. Apr 2002;18(3-4):179-182.
23. Hammond CJ, Chitnavis B, Penny CC, Strong AJ. Dandy-Walker complex and syringomyelia in an adult: case report and discussion. *Neurosurgery*. Jan 2002;50(1):191-194.
24. Peters V, Penzien JM, Reiter G, et al. Congenital disorder of glycosylation IId (CDG-IId) -- a new entity: clinical presentation with Dandy-Walker malformation and myopathy. *Neuropediatrics*. Feb 2002;33(1):27-32.
25. Freeman SR, Jones PH. Old age presentation of the Dandy-Walker syndrome associated with unilateral sudden sensorineural deafness and vertigo. *The Journal of laryngology and otology*. Feb 2002;116(2):127-131.
26. Toriello HV, Lemire EG. Optic nerve coloboma, Dandy-Walker malformation, microglossia, tongue hamartomata, cleft palate and apneic spells: an existing oral-facial-digital syndrome or a new variant? *Clinical dysmorphology*. Jan 2002;11(1):19-23.
27. Aslan H, Ulker V, Gulcan EM, et al. Prenatal diagnosis of Joubert syndrome: a case report. *Prenatal diagnosis*. Jan 2002;22(1):13-16.
28. Lin MC, Chen CH, Chi CS. PHACE syndrome: report of one case. *Acta paediatrica Taiwanica = Taiwan er ke yi xue hui za zhi*. Nov-Dec 2003;44(6):379-382.
29. Furukawa T, Azakami S, Kurosawa H, Ono Y, Ueda Y, Konno Y. Cystic partially differentiated nephroblastoma, embryonal rhabdomyosarcoma, and multiple congenital anomalies associated with variegated mosaic aneuploidy and premature centromere division: a case report. *Journal of pediatric hematology/oncology*. Nov 2003;25(11):896-899.
30. Dinakar C, Lewin S, Kumar KR, Harshad SR. Partial albinism, immunodeficiency, hypergammaglobulinemia and Dandy-Walker cyst--a Griscelli syndrome variant. *Indian pediatrics*. Oct 2003;40(10):1005-1008.
31. Panteliadis CP, Karatza ED, Tzitiridou MK, Koliouskas DE, Spiroglou KS. Lissencephaly and mongolian spots in Hurler syndrome. *Pediatric neurology*. Jul 2003;29(1):59-62.

32. Hedera P, Innis JW. Juberg-Hayward syndrome: report of a new patient with severe phenotype and novel clinical features. *American journal of medical genetics. Part A.* Oct 15 2003;122A(3):257-260.
33. Litzman J, Buckova H, Ventruba J, Holcikova A, Mikyska P, Lokaj J. A concurrent occurrence of cutis laxa, Dandy-Walker syndrome and immunodeficiency in a girl. *Acta paediatrica (Oslo, Norway : 1992).* Jul 2003;92(7):861-864.
34. Erdal M, Plikcioglu AC, Bikmaz K, Cosar M. Dandy-Walker complex and syringomyelia in an adult: case report and discussion. *Neurosurgery.* Jun 2003;52(6):1504-1505; author reply 1505.
35. Cazorla Calleja MR, Verdu A, Felix V. Dandy-Walker malformation in an infant with tetrasomy 9p. *Brain & development.* Apr 2003;25(3):220-223.
36. McCormack WM, Jr., Shen JJ, Curry SM, et al. Partial deletions of the long arm of chromosome 13 associated with holoprosencephaly and the Dandy-Walker malformation. *American journal of medical genetics. Part A.* Apr 15 2003;118A(2):384-389.
37. Muzumdar DP, Goel A. Giant occipital meningocele as a presenting feature of Dandy-Walker syndrome. *Indian pediatrics.* Aug 2004;41(8):863-864.
38. Arai M, Nosaka K, Kashihara K, Kaizaki Y. Neurocutaneous melanosis associated with Dandy-Walker malformation and a meningoencephalocele. Case report. *Journal of neurosurgery.* May 2004;100(5 Suppl Pediatrics):501-505.
39. Mohammadi M, Mohebbi MR, Holden KR. Facial hemangioma, and associated malformations: a case report. *Neuropediatrics.* Jun 2004;35(3):194-197.
40. Tubbs RS, Smyth MD, Oakes WJ, Blount JP. Duplication of the massa intermedia in a child. *Pediatric neurosurgery.* Jan-Feb 2004;40(1):42-43.
41. Ueno H, Yamaguchi H, Katakami H, Matsukura S. A case of Kallmann syndrome associated with Dandy-Walker malformation. *Experimental and clinical endocrinology & diabetes : official journal, German Society of Endocrinology [and] German Diabetes Association.* Jan 2004;112(1):62-67.
42. Owler BK, Halmagyi GM, Brennan J, Besser M. Syringomyelia with Chiari malformation; 3 unusual cases with implications for pathogenesis. *Acta neurochirurgica.* Oct 2004;146(10):1137-1143; discussion 1143.
43. Prieto Espunes S, Santos-Juanes J, Medina Villanueva A, Concha Torre A, Rey Galan C, Sanchez Del Rio J. Death from cerebrovascular infarction in a patient with PHACES syndrome. *Journal of the American Academy of Dermatology.* Jul 2004;51(1):142-143.
44. Weinzierl MR, Coenen VA, Korinth MC, Gilsbach JM, Rohde V. Endoscopic transtentorial ventriculocystostomy and cystoventriculoperitoneal shunt in a neonate with Dandy-Walker malformation and associated aqueductal obstruction. *Pediatric neurosurgery.* Sep-Oct 2005;41(5):272-277.
45. Ross G, Bekhor P, Su J, Marks M. A case of PHACE syndrome. *The Australasian journal of dermatology.* Nov 2005;46(4):253-256.
46. Castro Conde JR, Martinez ED, Rodriguez RC, Rodriguez De Hoyos AL. CNS siderosis and dandy-walker variant after neonatal alloimmune thrombocytopenia. *Pediatric neurology.* May 2005;32(5):346-349.
47. Sun L, Eklund EA, Chung WK, Wang C, Cohen J, Freeze HH. Congenital disorder of glycosylation id presenting with hyperinsulinemic hypoglycemia and islet cell hyperplasia. *The Journal of clinical endocrinology and metabolism.* Jul 2005;90(7):4371-4375.
48. de Azevedo Moreira LM, Neri FB, de Quadros Uzeda S, et al. Multiple congenital malformations including severe eye anomalies and abnormal cerebellar

- development with Dandy-Walker malformation in a girl with partial trisomy 3q. *Ophthalmic genetics*. Mar 2005;26(1):37-43.
49. Teksam O, Yurdakok M, Coskun T. Molybdenum cofactor deficiency presenting with severe metabolic acidosis and intracranial hemorrhage. *Journal of child neurology*. Feb 2005;20(2):155-157.
 50. Ounap K, Ilus T, Bartsch O. A girl with inverted triplication of chromosome 3q25.3 --> q29 and multiple congenital anomalies consistent with 3q duplication syndrome. *American journal of medical genetics. Part A*. May 1 2005;134(4):434-438.
 51. Iyer P, Smith R. Severe feeding difficulties in 3C syndrome. *Clinical dysmorphology*. Apr 2005;14(2):101-103.
 52. Klein OD, Backstrand K, Cotter PD, Marco E, Sherr E, Slavotinek A. Case report: Y;6 translocation with deletion of 6p. *Clinical dysmorphology*. Apr 2005;14(2):93-96.
 53. Pascual-Castroviejo I, Pascual-Pascual SI, Velazquez-Fragua R, Lapunzina P. Oculocerebrocutaneous (Delleman) syndrome: report of two cases. *Neuropediatrics*. Feb 2005;36(1):50-54.
 54. Kolomietz E, Godbole K, Winsor EJ, Stockley T, Seaward G, Chitayat D. Functional disomy of Xp: prenatal findings and postnatal outcome. *American journal of medical genetics. Part A*. May 1 2005;134(4):393-398.
 55. Prasad M, Iype M, Nair PM. Callosal agenesis and Open lip Schizencephaly. *Indian journal of pediatrics*. Sep 2006;73(9):838-839.
 56. Weimer J, Cohen M, Wiedemann U, Heinrich U, Jonat W, Arnold N. Proof of partial imbalances 6q and 11q due to maternal complex balanced translocation analyzed by microdissection of multicolor labeled chromosomes (FISH-MD) in a patient with Dandy-Walker variant. *Cytogenetic and genome research*. 2006;114(3-4):235-239.
 57. Menon RK, Nadkarni TD, Desai KI, Goel A. Dandy-Walker malformation associated with polycystic kidneys: Goldston syndrome revisited. *Journal of clinical neuroscience : official journal of the Neurosurgical Society of Australasia*. Oct 2006;13(8):875-877.
 58. Kim YJ, Won YD, Kim KT, Chang ED, Huh PW. Parenchymal neurocutaneous melanosis in association with intraventricular dermoid and Dandy-Walker variant: a case report. *Korean journal of radiology*. Apr-Jun 2006;7(2):145-148.
 59. Chen CP, Lin SP, Lin CC, et al. Spectral karyotyping and fluorescence in situ hybridization analysis of de novo partial trisomy 7p (7p21.2-->pter) and partial monosomy 12q (12q24.33-->qter). *Genetic counseling (Geneva, Switzerland)*. 2006;17(1):57-63.
 60. Cappellacci S, Martinelli S, Rinaldi R, et al. De novo pure 12q22q24.33 duplication: first report of a case with mental retardation, ADHD, and Dandy-Walker malformation. *American journal of medical genetics. Part A*. Jun 1 2006;140(11):1203-1207.
 61. Kang SG, Yoo DS, Cho KS, et al. Coexisting intracranial meningeal melanocytoma, dermoid tumor, and Dandy-Walker cyst in a patient with neurocutaneous melanosis. Case report. *Journal of neurosurgery*. Mar 2006;104(3):444-447.
 62. Richter EO, Pincus DW. Development of syringohydromyelia associated with Dandy-Walker malformation: treatment with cystoperitoneal shunt placement. Case report. *Journal of neurosurgery*. Mar 2006;104(3 Suppl):206-209.
 63. Kalayci M, Cagavi F, Bayar U, et al. Neurocutaneous melanosis associated with Dandy-Walker malformation. *Acta neurochirurgica*. Oct 2006;148(10):1103-1106; discussion 1106.
 64. Akgul A, Babaroglu S, Bahar I, Bokesoy I, Birincioglu L, Cobanoglu A. An unusual combination: aortic arch coarctation associated with Dandy-Walker variant. *International journal of cardiology*. Nov 10 2006;113(2):258-260.

65. Cannady SB, Kahn TA, Traboulsi EI, Koltai PJ. PHACE syndrome: report of a case with a glioma of the anterior skull base and ocular malformations. *International journal of pediatric otorhinolaryngology*. Mar 2006;70(3):561-564.
66. Caceres A, Trejos H. Neurocutaneous melanosis with associated Dandy-Walker complex. *Child's nervous system : ChNS : official journal of the International Society for Pediatric Neurosurgery*. Jan 2006;22(1):67-72.
67. Abdel-Salam GM, Shehab M, Zaki MS. Isolated Dandy-Walker malformation associated with brain stem dysgenesis in male sibs. *Brain & development*. Sep 2006;28(8):529-533.
68. McPherson E, Zaleski C, Mascola M. Prenatal diagnosis of episodic tachypnea in an infant with OFD VI. *American journal of medical genetics. Part A*. Oct 1 2006;140(19):2146-2149.
69. Su PH, Chen JY, Hsu CH, Chen SJ, Chan SW, Lin LL. Trisomy 18 with multiple rare malformations: report of one case. *Acta paediatrica Taiwanica = Taiwan er ke yi xue hui za zhi*. Sep-Oct 2007;48(5):272-275.
70. McClelland S, 3rd, Charnas LR, SantaCruz KS, Garner HP, Lam CH. Progressive brainstem compression in an infant with neurocutaneous melanosis and Dandy-Walker complex following ventriculoperitoneal shunt placement for hydrocephalus. Case report. *Journal of neurosurgery*. Dec 2007;107(6 Suppl):500-503.
71. de Brito Henriques JG, Henriques KS, Filho GP, Fonseca LF, Cardoso F, Da Silva MC. Bobble-head doll syndrome associated with Dandy-Walker syndrome. Case report. *Journal of neurosurgery*. Sep 2007;107(3 Suppl):248-250.
72. Sener RN. Rhombencephalosynapsis associated with Dandy-Walker malformation. *Journal of neuroimaging : official journal of the American Society of Neuroimaging*. Oct 2007;17(4):355-357.
73. Aluclu MU, Bahceci S, Bahceci M. A rare embryological malformation of brain - Dandy-Walker syndrome - and its association with Kallmann's syndrome. *Neuro endocrinology letters*. Jun 2007;28(3):255-258.
74. Papazisis G, Mastrogianni A, Karastergiou A. Early-onset schizophrenia and obsessive-compulsive disorder in a young man with Dandy-Walker variant. *Schizophrenia research*. Jul 2007;93(1-3):403-405.
75. Poot M, Kroes HY, SE VDW, et al. Dandy-Walker complex in a boy with a 5 Mb deletion of region 1q44 due to a paternal t(1;20)(q44;q13.33). *American journal of medical genetics. Part A*. May 15 2007;143A(10):1038-1044.
76. Cardoso J, Lange MC, Lorenzoni PJ, Scola RH, Werneck LC. Dandy-Walker syndrome in adult mimicking myasthenia gravis. *Arquivos de neuro-psiquiatria*. Mar 2007;65(1):173-175.
77. Ghosh A, Tibrewal SR, Thapa R. PHACES syndrome with congenital hypothyroidism. *Indian pediatrics*. Feb 2007;44(2):144-147.
78. Humphries WE, Grossi PM, Lieth LG, George TM. Ventriculoperitoneal shunt failure causing myelopathy in a patient with bilateral jugular vein occlusion. Case report. *Journal of neurosurgery. Spine*. Jan 2007;6(1):60-63.
79. Vundinti BR, Kerketta L, Korgaonkar S, Ghosh K. Dandy-Walker malformations in a case of partial trisomy 9p (p12.1-->pter) due to maternal translocation t(9;12)(p12.1;p13.3). *Indian journal of human genetics*. Jan 2007;13(1):33-35.
80. Ferentinos PP, Kontaxakis VP, Havaki-Kontaxaki BJ, Paplos KG, Pappa DA, Soldatos CR. Refractory psychosis and prominent cognitive deficits in a patient with megacisterna magna. *Progress in neuro-psychopharmacology & biological psychiatry*. Mar 30 2007;31(2):561-563.
81. Zechi-Ceide RM, Guion-Almeida ML, Zanchetta S, Richieri-Costa A. Occipital atretic cephalocele, striking facial anomalies, and large feet in three siblings of a

- consanguineous union. *American journal of medical genetics. Part A.* Dec 15 2007;143A(24):3295-3301.
82. Hou YJ, Chen FL, Ng YY, et al. Trisomy 18 syndrome with incomplete Cantrell syndrome. *Pediatrics and neonatology.* Jun 2008;49(3):84-87.
 83. van Steensel MA, Vreeburg M, Engelen J, et al. Contiguous gene syndrome due to a maternally inherited 8.41 Mb distal deletion of chromosome band Xp22.3 in a boy with short stature, ichthyosis, epilepsy, mental retardation, cerebral cortical heterotopias and Dandy-Walker malformation. *American journal of medical genetics. Part A.* Nov 15 2008;146A(22):2944-2949.
 84. Herman TE, Siegel MJ. Ritscher-Schinzel cranio-cerebello-cardiac syndrome. *Journal of perinatology : official journal of the California Perinatal Association.* Oct 2008;28(10):715-718.
 85. Saatci AO, Arikan G, Saatci P, Saatci Y, Kavukcu S. Oculocerebrocutaneous syndrome. *Journal of pediatric ophthalmology and strabismus.* May-Jun 2008;45(3):181-183.
 86. Cakmak A, Zeyrek D, Cekin A, Karazeybek H. Dandy-Walker syndrome together with occipital encephalocele. *Minerva pediatrica.* Aug 2008;60(4):465-468.
 87. Schreml S, Gruendobler B, Schreml J, et al. Neurocutaneous melanosis in association with Dandy-Walker malformation: case report and literature review. *Clinical and experimental dermatology.* Aug 2008;33(5):611-614.
 88. Warwick CT, Reyes BJ, Ayoob MR, Subit M. Adult diagnosed Dandy Walker malformation presenting as an acute brainstem event--a case report and review of the literature. *The West Virginia medical journal.* Jan-Feb 2008;104(1):25-27.
 89. Cushing SL, MacDonald L, Propst EJ, et al. Successful cochlear implantation in a child with Keratosis, Ichthyosis and Deafness (KID) Syndrome and Dandy-Walker malformation. *International journal of pediatric otorhinolaryngology.* May 2008;72(5):693-698.
 90. Kasliwal MK, Suri A, Sharma BS. Dandy Walker malformation associated with syringomyelia. *Clinical neurology and neurosurgery.* Mar 2008;110(3):317-319.
 91. Kurdi ME, Chamsi-Pasha MA, Baeesa SS, Jan MM. Dandy Walker malformation and hypertrophic cardiomyopathy. Unusual fatal association. *Neurosciences (Riyadh, Saudi Arabia).* Oct 2009;14(4):368-370.
 92. Nagdeve NG, Mudkhedkar KP. Large destructive facial hemangioma in PHACE syndrome. *Journal of Indian Association of Pediatric Surgeons.* Jul 2009;14(3):113-114.
 93. Caglayan AO, Gumus H, Yikilmaz A, Gumus GO, Per H. A provisionally unique syndrome with features including "molar tooth" sign and "femoral hypoplasia". *Genetic counseling (Geneva, Switzerland).* 2009;20(4):359-365.
 94. Venturini E, Magni L, Pucci G, Mazzinghi F. A late presentation of Dandy-Walker malformation and aortic coarctation. *Journal of cardiovascular medicine (Hagerstown, Md.).* Dec 16 2009.
 95. Murugesan C, Kumar P, Muralidhar K. A new association of multiple congenital anomalies/mental retardation syndrome with bradycardia-tachycardia syndrome: a case report. *Journal of medical case reports.* 2009;3:9309.
 96. Marnet D, Vinchon M, Mostofi K, Catteau B, Kerdraon O, Dhellemmes P. Neurocutaneous melanosis and the Dandy-Walker complex: an uncommon but not so insignificant association. *Child's nervous system : ChNS : official journal of the International Society for Pediatric Neurosurgery.* Dec 2009;25(12):1533-1539.
 97. Lingeswaran A, Barathi D, Sharma G. Dandy-Walker variant associated with bipolar affective disorder. *Journal of pediatric neurosciences.* Jul 2009;4(2):131-132.

98. Cultrera F, D'Andrea M, Battaglia R, Chierigato A. Unilateral oculomotor nerve palsy: unusual sign of hydrocephalus. *Journal of neurosurgical sciences*. Jun 2009;53(2):67-70.
99. Linder CE, Lu X, Kim YM, Li S, Pineda J. "Understanding Adam" multiple reciprocal translocations: complex case presentation. *The Journal of perinatal & neonatal nursing*. Apr-Jun 2009;23(2):150-156; quiz 157-158.
100. Gonul M, Soyulu S, Gul U, Aslan E, Unal T, Ergul G. Giant congenital melanocytic naevus associated with Dandy-Walker malformation, lipomatosis and hemihypertrophy of the leg. *Clinical and experimental dermatology*. Jul 2009;34(5):e106-109.
101. Ozdemir O, Polat A, Cinbis M, Kurt F, Kucuktasci K, Kiroglu Y. Dandy-Walker's variant and tetralogy of Fallot with atrial septal defect and patent ductus arteriosus and primary hypothyroidy--a new association. *Indian journal of pediatrics*. Apr 2009;76(4):433-435.
102. Walbert T, Sloan AE, Cohen ML, Koubeissi MZ. Symptomatic neurocutaneous melanosis and Dandy-Walker malformation in an adult. *Journal of clinical oncology : official journal of the American Society of Clinical Oncology*. Jun 10 2009;27(17):2886-2887.
103. Masdeu JC, Pascual B, Bressi F, et al. Ventricular wall granulations and draining of cerebrospinal fluid in chronic giant hydrocephalus. *Archives of neurology*. Feb 2009;66(2):262-267.
104. Zhang XB, Wei SC, Li CX, et al. Mutation of GJB2 in a Chinese patient with keratitis-ichthyosis-deafness syndrome and brain malformation. *Clinical and experimental dermatology*. Apr 2009;34(3):309-313.
105. Sato TS, Moritani T, Hitchon P. Occipital intradiploic CSF pseudocyst: an unusual complication of a ventriculoperitoneal shunt malfunction. *AJNR. American journal of neuroradiology*. Mar 2009;30(3):635-636.
106. Suranyi A, Bito T, Vajda G, et al. Unusual clinical history of a male infant with Edwards syndrome. *Pathology oncology research : POR*. Mar 2009;15(1):147-152.
107. Al-Adnani M, Kiho L, Scheimberg I. Fowler syndrome presenting as a Dandy-Walker malformation: a second case report. *Pediatric and developmental pathology : the official journal of the Society for Pediatric Pathology and the Paediatric Pathology Society*. Jan-Feb 2009;12(1):68-72.
108. Panas M, Spengos K, Tsivgoulis G, et al. Spinal muscular atrophy, Dandy-Walker complex, and cataracts in two siblings: a new entity? *Journal of neurology, neurosurgery, and psychiatry*. Aug 2005;76(8):1183-1184.
109. Coban D, Akin MA, Kurtoglu S, Oktem S, Yikilmaz A. Dandy-Walker malformation: a rare association with hypoparathyroidism. *Pediatric neurology*. Dec 2010;43(6):439-441.
110. Lim FF, Ng YY, Hu JM, Chen SJ, Su PH, Chen JY. Ocular findings in a case of trisomy 18 with variant of Dandy-Walker syndrome. *Pediatrics and neonatology*. Oct 2010;51(5):292-295.
111. Sartori S, Ludwig K, Fortuna M, et al. Dandy-Walker malformation masking the molar tooth sign: an illustrative case with magnetic resonance imaging follow-up. *Journal of child neurology*. Nov 2010;25(11):1419-1422.
112. Mademont-Soler I, Morales C, Armengol L, Soler A, Sanchez A. Description of the smallest critical region for Dandy-Walker malformation in chromosome 13 in a girl with a cryptic deletion related to t(6;13)(q23;q32). *American journal of medical genetics. Part A*. Sep 2010;152A(9):2308-2312.

113. Stoodley P, Braxton EE, Jr., Nistico L, et al. Direct demonstration of *Staphylococcus* biofilm in an external ventricular drain in a patient with a history of recurrent ventriculoperitoneal shunt failure. *Pediatric neurosurgery*. Aug 2010;46(2):127-132.
114. Coulibaly B, Sigaudy S, Girard N, et al. Coffin-Siris syndrome with multiple congenital malformations and intrauterine death: towards a better delineation of the severe end of the spectrum. *European journal of medical genetics*. Sep-Oct 2010;53(5):318-321.
115. Mytilinaios DG, Tsamis KI, Njau SN, Polyzoides K, Baloyannis SJ. Neuropathological findings in Dandy Walker variant. *Developmental neurorehabilitation*. Feb 2010;13(1):64-67.
116. Unal O, Arslan H, Adali E, Bora A, Yildizhan R, Avcu S. MRI of omphalopagus conjoined twins with a Dandy-Walker malformation: prenatal true FISP and HASTE sequences. *Diagnostic and interventional radiology (Ankara, Turkey)*. Mar 2010;16(1):66-69.
117. Stevens CA, Lachman RS. New lethal skeletal dysplasia with Dandy-Walker malformation, congenital heart defects, abnormal thumbs, hypoplastic genitalia, and distinctive facies. *American journal of medical genetics. Part A*. Aug 2010;152A(8):1915-1918.
118. Ramieri V, Tarani L, Costantino F, et al. Microdeletion 3q syndrome. *The Journal of craniofacial surgery*. Nov 2011;22(6):2124-2128.
119. Marchal P, Lairez O, Marachet MA, Massabuau P, Galinier M, Roncalli J. Invalidating headaches as a symptom of pulmonary embolism in a Dandy-Walker syndrome with ventriculoatrial shunt. *European journal of neurology*. Aug 2011;18(8):e102-103.
120. Gveric-Ahmetasevic S, Colic A, Gveric T, Gasparovic VE, Pavlisa G, Ozretic D. Coexistence of cerebral sinovenous thrombosis and Dandy Walker malformation in newborn. *Collegium antropologicum*. Jan 2011;35 Suppl 1:303-307.
121. Yahyaoui R, Espinosa MG, Gomez C, et al. Neonatal carnitine palmitoyltransferase II deficiency associated with Dandy-Walker syndrome and sudden death. *Molecular genetics and metabolism*. Nov 2011;104(3):414-416.
122. Tohyama J, Kato M, Kawasaki S, et al. Dandy-Walker malformation associated with heterozygous ZIC1 and ZIC4 deletion: Report of a new patient. *American journal of medical genetics. Part A*. Jan 2011;155A(1):130-133.
123. Murphy-Ryan M, Babovic-Vuksanovic D, Lindor N. Bifid tongue, corneal clouding, and Dandy-Walker malformation in a male infant with otopalatodigital syndrome type 2. *American journal of medical genetics. Part A*. Apr 2011;155A(4):855-859.
124. Hu CF, Fan HC, Chang CF, Wang CC, Chen SJ. Successful treatment of Dandy-Walker syndrome by endoscopic third ventriculostomy in a 6-month-old girl with progressive hydrocephalus: a case report and literature review. *Pediatrics and neonatology*. Feb 2011;52(1):42-45.
125. Turan T, Besirli A, Asdemir A, Ozsoy S, Esel E. Manic episode associated with mega cisterna magna. *Psychiatry investigation*. Dec 2010;7(4):305-307.
126. Love K, Huddleston L, Olney P, Wrubel D, Visootsak J. Developmental outcomes of Down syndrome and Dandy-Walker malformation. *Journal of pediatric neurology : JPN*. Jan 1 2011;9(3):405-408.
127. Bunch M, Singh A. Peculiar neuroimaging and electrophysiological findings in a patient with biotinidase deficiency. *Seizure*. Jan 2011;20(1):83-86.
128. Tanoue K, Matsui K, Ohshiro A, et al. Acute encephalopathy in two cases with severe congenital hydrocephalus. *Brain & development*. Aug 2011;33(7):616-619.
129. Talamonti G, Picano M, Debernardi A, Bolzon M, Teruzzi M, D'Aliberti G. Giant occipital meningocele in an 8-year-old child with Dandy-Walker malformation.

- Child's nervous system : ChNS : official journal of the International Society for Pediatric Neurosurgery.* Jan 2011;27(1):167-174.
130. Hussain Z, Masroor I, Haider QU, Alam T. Goldston syndrome. *Journal of the College of Physicians and Surgeons--Pakistan : JCPSP.* Apr 2011;21(4):242-244.
 131. Al-Achkar W, Wafa A, Jarjour RA. A new case of de novo translocation (12;17;18)(q21.2;q22;q21.1) and cranio-cerebello-cardiac (3C) syndrome. *American journal of medical genetics. Part A.* Mar 2011;155A(3):648-651.
 132. Amin OS. Ataxia, hypoplastic vermis and keyhole connection sign: is it the variant form of Dandy-Walker complex? *BMJ case reports.* 2012;2012.
 133. Mancini TI, Oliveira MM, Dutra AR, et al. Interstitial 4q Deletion and Isodicentric Y-Chromosome in a Patient with Dysmorphic Features. *Molecular syndromology.* Jun 2012;3(1):39-43.
 134. Manel L, Houneida ZB, Habib A, Dejla B, Chekib K. A rare inborn error of metabolism associated with a Dandy-Walker malformation. *Acta neurologica Belgica.* Dec 2012;112(4):425-426.
 135. Aimua F, Dunn NR, Swift RG. Dandy walker variant with treatment-resistant bipolar disorder. *The Journal of neuropsychiatry and clinical neurosciences.* Winter 2012;24(1):E50.
 136. Beby F, Des Portes V, Till M, Mottolese C, Denis P. Chromosome 6p25 deletion syndrome: report of a case with optic disc coloboma and review of published ophthalmic findings. *Ophthalmic genetics.* Dec 2012;33(4):240-248.
 137. Kim DH, Choi JH, Lee JH, Kim HS. PHACE association with intracranial, oropharyngeal hemangiomas, and an atypical patent ductus arteriosus arising from the tortuous left subclavian artery in a premature infant. *Korean journal of pediatrics.* Jan 2012;55(1):29-33.
 138. Cho IY, Hwang SK, Kim SH. Dandy-walker malformation associated with neurocutaneous melanosis. *Journal of Korean Neurosurgical Society.* Nov 2011;50(5):475-477.
 139. Economou A, Katsetos CD. Patterns of cognitive and fine motor deficits in a case of Dandy-Walker continuum. *Journal of child neurology.* Jul 2012;27(7):930-937.
 140. Badakali M, Badakali A, Dombale V. Rare manifestations of Neu-Laxova syndrome. *Fetal and pediatric pathology.* Feb 2012;31(1):1-5.
 141. Dominguez RO, Gonzalez SE, Saenz Valiente A, Pinkala E. Agenesis of posterior inferior cerebellar arteries in an asymptomatic adult with Dandy-Walker malformation. *Neurologia (Barcelona, Spain).* Sep 2012;27(7):445-446.
 142. Kara M, Tiftik T, Sari F, Dolmus M, Ozcakar L. Ultrasonographic evaluation of the peripheral nerves in a patient with chronic neuropathy and dandy-walker syndrome. *American journal of physical medicine & rehabilitation / Association of Academic Physiatrists.* Sep 2012;91(9):821.
 143. Kim KH, Chung SB, Kong DS, Seol HJ, Shin HJ. Neurocutaneous melanosis associated with Dandy-Walker complex and an intracranial cavernous angioma. *Child's nervous system : ChNS : official journal of the International Society for Pediatric Neurosurgery.* Feb 2012;28(2):309-314.
 144. Ryan M, Grenier E, Castro A, Nemeroff CB. New-onset psychosis associated with dandy-walker variant in an adolescent female patient. *The Journal of neuropsychiatry and clinical neurosciences.* Spring 2012;24(2):241-246.
 145. Azukizawa T, Yamamoto M, Narumiya S, Takano T. Oral-facial-digital syndrome type 1 with hypothalamic hamartoma and Dandy-Walker malformation. *Pediatric neurology.* Apr 2013;48(4):329-332.

146. Searson R, Hare DJ, Sridharan S. Neuropsychological and behavioural phenotype of Dandy-Walker variant presenting in chromosome 22 trisomy: a case study. *Journal of intellectual disabilities : JOID*. Jun 2013;17(2):102-106.
147. Kim JH, Kim TH, Choi YC, Chung SC, Moon SW. Impulsive behavior and recurrent major depression associated with dandy-walker variant. *Psychiatry investigation*. Sep 2013;10(3):303-305.
148. Mandiwanza T, Kaliaperumal C, Caird J. Central brain herniation in shunted Dandy Walker cyst. *Child's nervous system : ChNS : official journal of the International Society for Pediatric Neurosurgery*. Jun 2013;29(6):1035-1038.
149. Hackmann K, Stadler A, Schallner J, et al. Severe intellectual disability, West syndrome, Dandy-Walker malformation, and syndactyly in a patient with partial tetrasomy 17q25.3. *American journal of medical genetics. Part A*. Dec 2013;161A(12):3144-3149.
150. Dhupar V, Kumar P, Akkara F, Kumar A. Dandy Walker Syndrome with Tessier 7 Cleft- a Rare Case Report and a Surgical Note on the Use of Vermilion Flap and Lazy W-Plasty. *Journal of maxillofacial and oral surgery*. Sep 2012;11(3):368-370.
151. Pai A, Shakir M. Mayer-Rokitansky-Kuster-Hauser syndrome type II: A rare case. *Indian journal of human genetics*. Jan 2013;19(1):113-115.
152. Zhang W, Chen M, Zhang W. Trigeminal neuralgia due to Dandy-Walker syndrome. *The Journal of craniofacial surgery*. Jul 2013;24(4):1457-1459.
153. Jang JS, Lee JJ, Park WJ, Kim EY, Lim SY. Anesthetic management of an adolescent with Dandy-Walker syndrome. *Korean journal of anesthesiology*. Feb 2013;64(2):180-181.
154. Passalacqua CA, Villegas VP, Aracena MI, Mellado CX. Dandy-Walker malformation with postaxial polydactyly: a new case of Pierquin syndrome. *Clinical dysmorphology*. Apr 2013;22(2):51-53.
155. Zhou L, Lui GK, Shenoy R, Taub CC. Coarctation of the aorta associated with Dandy-Walker variant. *Journal of cardiovascular disease research*. Sep 2013;4(3):182-186.
156. John JS, Vanitha R. Moebius syndrome with Dandy-Walker variant and agenesis of corpus callosum. *Journal of pediatric neurosciences*. Sep 2013;8(3):210-212.
157. de Crecchio G, Cennamo G, de Leeuw N, et al. Severe myopia with unusual retinal anomalies and Dandy-Walker sequence in two sibs. A distinct new neuro-ocular disorder. *Ophthalmic genetics*. Dec 2013;34(4):254-257.
158. Guilherme RS, Kim CA, Alonso LG, et al. Ring chromosome 10: report on two patients and review of the literature. *Journal of applied genetics*. Feb 2013;54(1):35-41.
159. Bhattacharya A, Desarkar P, Haque S. A case of Dandy-Walker variant disorder associated with multiple neuropsychiatric comorbidities managed with behavioral therapy. *The Journal of neuropsychiatry and clinical neurosciences*. Summer 2013;25(3):E03-04.
160. Sidana A, Sarkar S, Balasundaram S, Praharaj SK. Increased sensitivity to atypical antipsychotics in a patient with Dandy-Walker variant with schizophrenia. *The Journal of neuropsychiatry and clinical neurosciences*. Summer 2013;25(3):E31-32.
161. Graf H, Franke B, Abler B. Cerebellar cognitive affective syndrome in Dandy-Walker variant disorder. *The Journal of neuropsychiatry and clinical neurosciences*. Summer 2013;25(3):E45-46.
162. Mama N, H'Mida D, Lahmar I, Yacoubi MT, Tlili-Graïess K. PHACES syndrome associated with carcinoid endobronchial tumor. *Pediatric radiology*. May 2014;44(5):621-624.
163. De Cock J, Snauwaert J, Van Rompaey W, Morren MA, Demaerel P. A newborn with neurocutaneous melanocytosis and Dandy-Walker malformation. *Pediatric neurology*. Mar 2014;50(3):276-278.

164. Rodriguez L, Bhatt SS, Garcia-Castro M, et al. A unique case of a discontinuous duplication 3q26.1-3q28 resulting from a segregation error of a maternal complex chromosomal rearrangement involving an insertion and an inversion. *Gene*. Feb 10 2014;535(2):165-169.
165. Na M, Xie C, Wang H, Shen H, Lin Z. Calvarial defects and Dandy-Walker malformation in association with neurofibromatosis type 1. *Chinese medical journal*. 2014;127(6):1187-1188.
166. Buonaguro EF, Cimmarosa S, de Bartolomeis A. Dandy-Walker syndrome with psychotic symptoms: a case report. *Rivista di psichiatria*. Mar-Apr 2014;49(2):100-102.
167. Gathwala G, Silayach J, Bhakhari BK, Narwal V. Very severe spinal muscular atrophy: Type 0 with Dandy-Walker variant. *Journal of pediatric neurosciences*. Jan 2014;9(1):55-56.
168. Pandurangi S, Pandurangi A, Matkar A, Shetty N, Patil P. Psychiatric manifestations associated with mega cisterna magna. *The Journal of neuropsychiatry and clinical neurosciences*. Apr 1 2014;26(2):169-171.

Table 2. Reported comorbidities under ICD 10 categorization

ICD10 Disease Category	Comorbidities reported with Dandy Walker Syndrome (No of cases)
II Neoplasm	nephroblastoma(Wilms tumour) (8) tongue hamartoma(4) rhabdomyosarcoma(2) meningeal melanocytoma (1) primary meningeal melanoma(1) intraventricular dermoid tumour (1) nasal glioma (1) hepatoblastoma(1) endobronchial carcinoid tumour(1) intracranial cavernous angioma(1) multiple tumoral lesions(1)
III Diseases of the blood and blood-forming organs and certain disorders involving the immune mechanism	Anaemia/thrombocytopenia(1) immunodeficiency(1)
IV Endocrine, nutritional and metabolic diseases	hirsutism(5) Hypothyroidism(2) molybdenum cofactor deficiency(2) hypoparathyroidism(1) precocious puberty(1) horseshoe adrenal gland(1) single-lobe thyroid(1) Hurler disease (mucopolysaccharidosis type I) (1) congenital disease of glycosylation(1) hyperinsulinism(1) nonketotic hyperglycinemia(1) <i>Carnitine palmitoyltransferase II</i> deficiency (CPT-II) (1) biotinidase deficiency(1)
V Mental and behavioural disorders	severe intellectual disability(10) bipolar disorder(5) psychosis(5) attention deficit hyperactivity disorder(4) mild mental abnormality(3) neurobehavioral abnormalities (auto and heteroaggressive disorder) (3) speech impairment(1) OCD(obsessive-compulsive disorder) (1)
VII Diseases of the eye and adnexa	cataracts(9) microphthalmia(6) microcornea/corneal opacity(5) myopia(5) optic nerve atrophy/dysplasia(5) chorioretinal atrophy/dysplasia(5) nystagmus(3) iris/optic nerve/optic disk coloboma(3) strabismus(2)

	anophthalmia(1) posterior embryotoxon(1)
-VIII Diseases of the ear and mastoid process	Congenital deafness/hearing loss(7) vertigo(1) laryngomalacia(1)
IX Diseases of the circulatory system	Patent ductus arteriosus(7) coarctation of aorta(6) ventricular septal defect(VSD) (6) atrial septal defect(ASD) (5) heart failure(5) pulmonary stenosis/hypoplasia(4) intracranial and extracranial vascular malformations(3) aortic valve anomaly(2) tetralogy of Fallot(2) bilateral internal jugular vein occlusion(1) complex heart defect (ventricular and atrial septal defect, malrotation and interrupted aortic arch) (1) right sided aortic arch(1) total anomalous pulmonary venous return to the thoracic inferior vena cava, double outlet right ventricle and a type B interrupted aortic arch (1) engorgement of the main pulmonary artery(1)
XI Diseases of the digestive system	oesophageal atresia+ tracheoesophageal fistula/ bronchoesophageal fistula(1) Meckel's diverticulum(1) Hirschsprung disease(1) duodenal atresia(1) ectopic pancreas(1) multiple congenital liver masses(1) oesophageal diverticulum(1)
XII Diseases of the skin and subcutaneous tissue	Neurocutaneous melanosis/lipomatosis(11) hemangiomas(9) melanocytic nevi(6) skin and hair pigmentary problems(4) sparse hair/hair loss(3) cutis laxa(1) cutis aplasia(1) ichthyosis(1)
XIII Diseases of the musculoskeletal system and connective tissue	scoliosis/ kyphoscoliosis(4) joint laxity(4) Spinal Muscular Atrophy(SMA)(3) congenital arthrogyria (contractures) (3) general muscular dystrophy(1) Mimicking Myasthenia Gravis(1)
XIV Diseases of the genitourinary system	hypoplastic genitalia(7) polycystic kidneys(4) dysplastic kidneys-kidney/renal agenesis/pelvic kidney (4) undescended testis/ cryptorchidism (4) hydronephrosis/ hydroureters(3) hypospadias(1)
XVII Congenital	PHACE syndrome (8)

malformations, deformations and chromosomal abnormalities	Trisomy 18 (Edwards syndrome)(4) Joubert syndrome(4) Oorthuys syndrome(3) oro-facio-digital syndrome (3) partial trisomy 3q(2) Coffin-Siris syndrome(2) Goldston syndrome(2) Kallmann's syndrome(2) Keratosis, Icthiosis, and Deafness (KID) Syndrome(2) trisomy 9q(1) partial trisomy of 8q(1) trisomy 22(1) 4q Deletion (1) 6p25 deletion(1) trisomy 21(1) translocations(1) Ritscher-Schinzel cranio-cerebello-cardiac syndrome(1) heterozygous loss of ZIC1 and ZIC4(1) Mayer-Rokitansky-Kuster-Hauser (MRKH) syndrome(1) bradycardia-tachycardia syndrome(1) multiple congenital anomalies/mental retardation (MCA/MR) syndrome(1) otopalatodigital syndrome type 2 (OPD2)(1) Neu-Laxova syndrome(1) Brown syndrome(1) Fowler syndrome(1) Moebius syndrome(1) Yunis-Varon syndrome(1) Ehlers-Danlos syndrome(1) Shah-Waardenburg syndrome(1) femoral-facial syndrome (FH-UFS)(1) Juberg-Hayward syndrome(1) Griscelli syndrome(1) Bobble-head doll syndrome (BHDS) (1) heterozygous missense mutation (D50N) in the GJB2 gene(1) oculocerebrocutaneous syndrome (OCCS) or Delleman- 3C syndrome(1) microdeletion 3q syndrome(1)
---	---
