



City Research Online

City, University of London Institutional Repository

Citation: Vemala, R., Sivaprasad, S. & Barbur, J. L. (2017). Detection of Early Loss of Color Vision in Age-Related Macular Degeneration - With Emphasis on Drusen and Reticular Pseudodrusen. *Investigative Ophthalmology & Visual Science*, 58(6), BIO247-BIO254. doi: 10.1167/iovs.17-21771

This is the published version of the paper.

This version of the publication may differ from the final published version.

Permanent repository link: <http://openaccess.city.ac.uk/18099/>

Link to published version: <http://dx.doi.org/10.1167/iovs.17-21771>

Copyright and reuse: City Research Online aims to make research outputs of City, University of London available to a wider audience. Copyright and Moral Rights remain with the author(s) and/or copyright holders. URLs from City Research Online may be freely distributed and linked to.

City Research Online:

<http://openaccess.city.ac.uk/>

publications@city.ac.uk

Detection of Early Loss of Color Vision in Age-Related Macular Degeneration – With Emphasis on Drusen and Reticular Pseudodrusen

Roopa Vemala,^{1,2} Sobha Sivaprasad,^{1,3} and John L. Barbur²

¹King's College Hospital, Denmark Hill, London, United Kingdom

²Applied Vision Research Centre, School of Health Sciences, City, University of London, London, United Kingdom

³NIHR Moorfields Biomedical Research Centre, London, United Kingdom

Correspondence: John L. Barbur, Professor of Optics and Visual Science, City, University of London, London, UK; J.L.Barbur@city.ac.uk

Submitted: February 28, 2017
Accepted: July 28, 2017

Citation: Vemala R, Sivaprasad S, Barbur JL. Detection of early loss of color vision in age-related macular degeneration - with emphasis on drusen and reticular pseudodrusen. *Invest Ophthalmol Vis Sci*. 2017;58:BIO247-BIO254. DOI: 10.1167/iovs.17-21771

PURPOSE. To evaluate chromatic sensitivity in patients with age-related macular degeneration (AMD) characterized by drusen and reticular pseudodrusen. To investigate whether the severity of color vision loss can distinguish between various stages of AMD and hence be used as an index of progression toward advanced AMD.

METHODS. Chromatic sensitivity was measured by using the Color Assessment and Diagnosis (CAD) test in asymptomatic individuals with early and intermediate AMD and compared to normative data. All study participants had logMAR visual acuity of 0.3 or better. The CAD thresholds measured in eyes with and without reticular pseudodrusen were also compared and related to central macular thickness (CMT). Student's *t*-test *P* values < 0.05 were considered significant.

RESULTS. All early- and intermediate-AMD eyes (*n* = 90) had chromatic sensitivity loss in either RG (red/green) or YB (yellow/blue), or both (*P* < 0.0001) as compared to age-matched normal subjects. The eyes exhibited a range of CAD thresholds affecting both color mechanisms, but YB color thresholds were in general higher than RG thresholds (*P* < 0.001). Intermediate-AMD patients exhibited large intersubject variability. In general, eyes with reticular pseudodrusen and eyes with CMT < 200 μm had significantly higher CAD thresholds.

CONCLUSIONS. The anatomic integrity of cone photoreceptors remains relatively unaffected in early and intermediate stages of AMD. The processing of cone signals in the retina can, however, be heavily disrupted with subsequent loss of both YB and RG chromatic sensitivity. The greatest losses were observed in eyes with reticular pseudodrusen.

Keywords: reticular pseudodrusen, functional markers, soft drusen

Early signs of age-related macular degeneration (AMD), often characterized by drusen and pigmentary changes in the macula, are found in ~8% of people older than 50 years. The global prevalence of the sight-threatening, late AMD, which includes geographic atrophy (GA) and choroidal neovascularisation (CNV), is less than 0.4%.¹ Early AMD is characterized by the presence of medium-sized drusen (with typical dimension >63 and <125 μm) without pigmentary abnormalities. According to Beckman's classification,² eyes with large drusen or with pigmentary abnormalities associated with at least medium drusen are described as falling within the "intermediate" AMD group. The risk of progressing to late AMD over 5 years is 50% for patients of highest risk in the intermediate-AMD group.² Classification based on color photographs or biomicroscopy alone ignores changes relevant to the disorder such as retinal pigment epithelium (RPE) dysfunction, diminished photoreceptor function, or the development of reticular pseudodrusen (RPD). These subtle changes may, however, affect sensitivity for processing different stimulus attributes, even in the early stages of disease when visual acuity remains relatively normal. Psychophysical tests designed to measure stimulus-specific loss of visual sensitivity by determining the

relationship between controlled visual stimuli and a subject's response can be useful indicators of the functional status of the photoreceptors and other visual processing stages in the retina.³

Although accurate assessment of changes in chromatic sensitivity remains largely unexplored, other vision attributes such as hyperacuity,⁴ contrast sensitivity,⁵ dark adaptation,⁶ and microperimetry⁷ have been studied in AMD with some correlation between decreased retinal sensitivity and structural markers derived from spectral-domain optical coherence tomography (SD-OCT).^{8,9}

With improvements in infrared imaging, the interest in RPD has increased; these deposits are internal to the RPE and the presence of RPD is frequently associated with decrease in scotopic thresholds, suggesting rod dysfunction,⁶ but the link to loss of color vision remains unexplored.

Normal color vision (CV) is trichromatic and involves comparison of signals generated in short wavelength (S), middle wavelength (M), and long wavelength (L) sensitive cones. The RG (red/green) channel uses L and M cone signals whilst YB (yellow/blue) channel uses S-cone signals that are compared against the sum of L and M signals.¹⁰ S cones are less



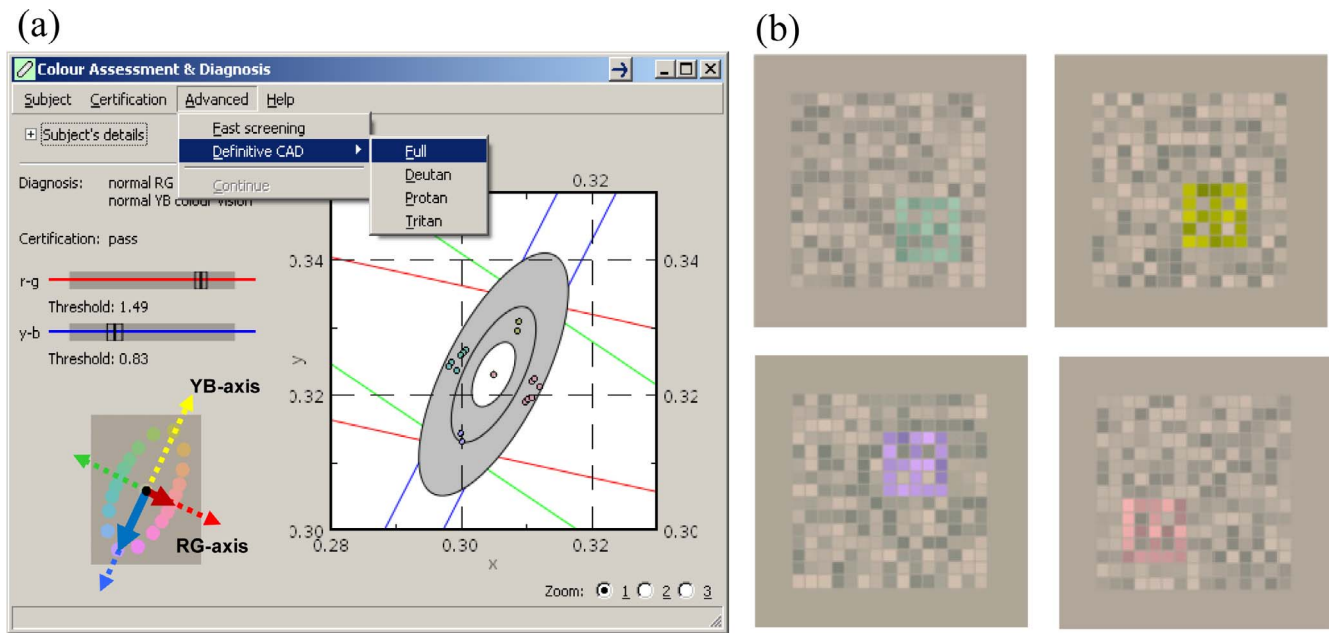


FIGURE 1. (a) Color report generated at the end of the test. RG/YB color threshold values are displayed and also plotted in the CIE 1931 (x, y) color chart. The thresholds are measured with respect to the chromaticity of the gray background field (0.305, 0.323), also known as MacAdam white, which is close to D65. The middle ellipse plots the age-matched mean thresholds expected in normal, healthy trichromats. The outer and inner ellipses show the corresponding $\pm 2.5\sigma$ upper and lower normal limits for the subject's age. The colored symbols show the subject's RG and YB thresholds which, in the case of congenital color deficiencies, extend along the corresponding color confusion bands for protanopes (red), deuteranopes (green), and tritanopes (blue). Screen dumps from the CAD test are shown in (b).

numerous in the very central region of the retina and make up only a small percentage of the cone population.¹¹ Under optimum conditions, young, normal trichromats require only 0.4% L- and 0.8% M-cone contrast changes to detect RG color differences (at threshold), but 7% S-cone contrast changes are needed to reach threshold in the case of YB color differences.^{12,13} The high sensitivity for detection of RG or YB color signals and the large number of stages involved in chromatic processing makes color assessment particularly suitable for detecting changes caused by retinal disease. A systematic review of 15 studies reveals loss of chromatic sensitivity in diseases of the retina with a tendency toward greater YB loss.¹⁴ Other studies¹⁵ have also reported a correlation between changes in chromatic sensitivity and disease progression in AMD.

The aim of this study was to evaluate whether changes in chromatic sensitivity measured with the Color Assessment and Diagnosis (CAD) test could be used as a functional biomarker in AMD to evaluate functional changes in early and intermediate AMD as well as in eyes with RPD.

METHODS

All patients/subjects were recruited from medical retina clinic at Kings College Hospital, London. The study received approval from the National Research Ethics Service (NRES) London-East and City, University of London. The research followed the tenets of the Declaration of Helsinki and informed consent was obtained from all subjects. The prospective study included people aged 50 years and older with early or intermediate AMD and logMAR visual acuity of 0.3 or better in the tested eye. Each eye of a subject was recruited separately, as earlier studies have revealed differences in color thresholds between the two eyes depending on the severity of AMD.¹⁵ Exclusion criteria included the presence of diabetes mellitus, glaucoma, and history of congenital color vision

deficiencies. Each eye was examined separately. LOCS II (Lens Opacities Classification System II) classification¹⁶ was used to grade lenticular opacity and eyes with nuclear sclerosis (N), cortical (C), and posterior subcapsular (P) cataract more than NI, CII, and PI were excluded from the study. This is simply because a significant reduction in retinal illuminance due to lens opacities can cause a reduction in chromatic sensitivity.¹⁷ All patients underwent routine ophthalmic examination, CAD assessment, fundus photography, and OCT scan of the macula in the test eye.

The CAD Test

The CAD test isolates the use of color signals, quantifies the severity of both RG and YB loss of chromatic sensitivity,¹⁵ and is particularly appropriate to use when acquired deficiencies are involved.¹⁸ When assessing YB chromatic sensitivity using the CAD test, the L- and M-cone signals remain unchanged with “yellow” and “blue” hues being signalled entirely by changes in S-cone signal.¹⁹ The test has been used in several studies designed to investigate variability in RG and YB chromatic sensitivity in both normal trichromats (as a function of age) and in subjects with congenital and/or acquired loss of chromatic sensitivity.^{15,20–22} The test uses dynamic luminance contrast noise to isolate the use of color signals.²²

The standard CAD test uses 16 interleaved directions specified in the CIE 1931 (x, y) color space (Fig. 1a). After each presentation, the subject's task is to press one of four buttons, to indicate the direction of motion of the color-defined stimulus (Fig. 1b). Mean thresholds measured in this way in 330 young, healthy normal subjects are used to define the Standard Normal CAD units for RG and YB color vision. All thresholds are expressed in CAD units.²³ For example, RG or YB thresholds of 3 CAD units indicate three times the mean color signal strength expected in young normal trichromats.

TABLE 1. Severity of CV Loss Classified According to the Subject's RG/YB Color Threshold

Subject's RG or YB Threshold, CAD Units	Classification Label to Indicate Severity of Loss
Upper normal limit < threshold \leq 6	Mild
6 < threshold \leq 12	Moderate
12 < threshold \leq 17	Severe
Threshold > 17	Very severe

The CAD test uses continuous age limits obtained by examining data from a large sample size of 720 eyes from individuals 4 to 90 years of age.¹² To interpret and analyze the data, the severity of CV loss was classified according to the subject's RG or YB color threshold as shown in Table 1. These limits are based largely on studies of minimum color vision requirements carried out within visually demanding occupations.¹³

The maximum possible YB CAD thresholds correspond to \sim 18 CAD units as opposed to maximum RG thresholds of 34 CAD units. The lower upper limit that can be achieved for YB thresholds is caused by the much larger YB color signals needed at threshold and the limits imposed by the visual display, which allows higher saturation for RG than YB.

When only S-cone signals are involved, the YB thresholds remain relatively independent of absorption of short-wavelength light by the lens and the macular pigment, provided sufficient ambient light is available to avoid large reductions in retinal illuminance for short-wavelength light.^{24,25} The presence of lens opacities can cause increased light scatter, changes in the spectral composition of the light, and reduced retinal illuminance. Small levels of scattered light, residual refractive errors, and higher-order aberrations do not, however, cause significant increases in either RG or YB color thresholds²⁶ because of the large stimulus size and the nature of the task involved in the CAD test.

The Severity of AMD

Fundus photographs of the central 35° of the retina were used to assess the severity of the disease, based on the Beckman classification of AMD² (Table 2), which classifies large drusen or pigmentary abnormalities associated with at least medium drusen to have intermediate AMD.

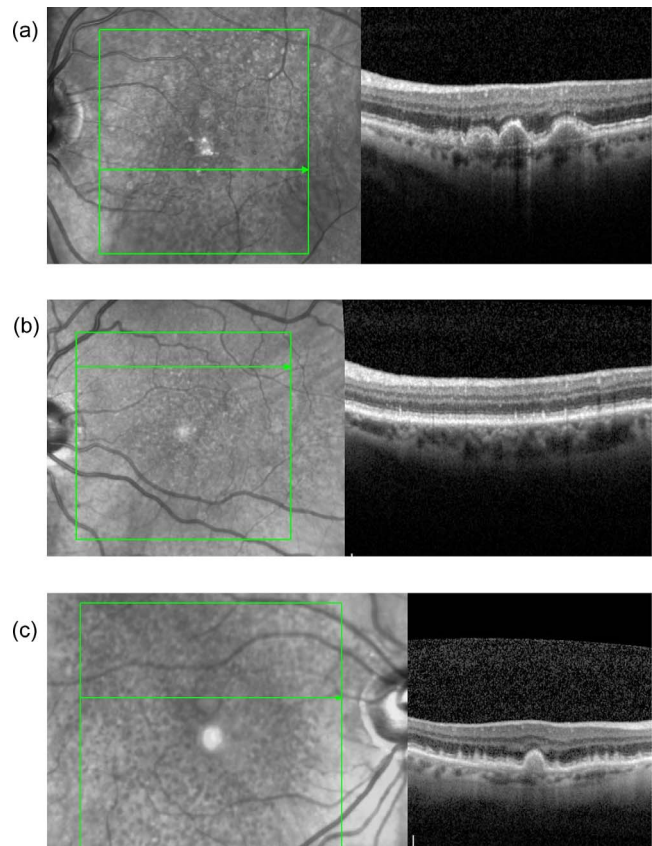
Optical Coherence Tomography

SD-OCT (Spectralis; Heidelberg Engineering, Heidelberg, Germany) volume scan consisting of a 20° × 20° cube with 49 raster lines, each containing 1064 pixels, separated by 125 μ m, was used to acquire the macular scan centred on the anatomic fovea.

Central macular thickness (CMT) was available as an automated calculation on the screen or on the printout of

TABLE 2. Clinical Categories for Severity of AMD Based on Beckman's Classification Criteria

AMD			
Grade	Severity Grade	Drusen Size, μ m	Pigment
0	No signs	Absent	Absent
1	Normal	\leq 63 μ m (droplets)	Absent
2	Early	>63 and \leq 125 (medium drusen)	Absent
3	Intermediate	>125 (large drusen)	Present
4	Late	Geographic atrophy/wet AMD	

**FIGURE 2.** Examples of SD-OCT macular scans showing (a) intermediate AMD with no reticular pseudodrusen, (b) eyes with reticular pseudodrusen, and (c) eyes with intermediate AMD and reticular pseudodrusen (which were included in the RPD group).

the measurement. CMT corresponds to approximately 500 μ m of the central region of the ETDRS grid. OCT imaging of incidental isolated cysts (suggestive of wet AMD) or early thinning (suggestive of GA) were noted and used to classify eyes accordingly. OCT observations were also compared against any fundus change noted on photographs. The scans were analyzed qualitatively to identify drusen and RPD along with the fundus photographs (Fig. 2). Infrared reflectance images of the fundus, acquired alongside the macular scans, were used to confirm the presence of RPD. Eyes with RPD and drusen were included in the reticular drusen group.

Drusen are the earliest clinical sign of AMD and are characterized by their texture (hard or soft), borders (distinct or indistinct), and size (small [$<$ 63 μ m], intermediate [$>$ 63 μ m and $<$ 125 μ m], or large [\geq 125 μ m]).^{27,28} Large, soft, confluent drusen are associated with a higher risk for development of advanced AMD.²⁹⁻³¹

Reticular drusen or subretinal drusenoid deposits represent a subphenotype of AMD that was first identified with blue light fundus photography.³² Sivaprasad et al.³³ have recommended that at least two modalities be used to detect and confirm the diagnosis of RPD. Currently, SD-OCT and infrared imaging are preferred for screening of RPD.³⁴⁻³⁶ RPD were initially associated with neovascular AMD,^{37,38} but recent studies^{39,40} show they represent a risk factor for progression to GA.

Statistical Analysis

All statistical tests were carried out by using SPSS V.17.0 (SPSS, Chicago, IL, USA). Measured RG and YB thresholds in patients

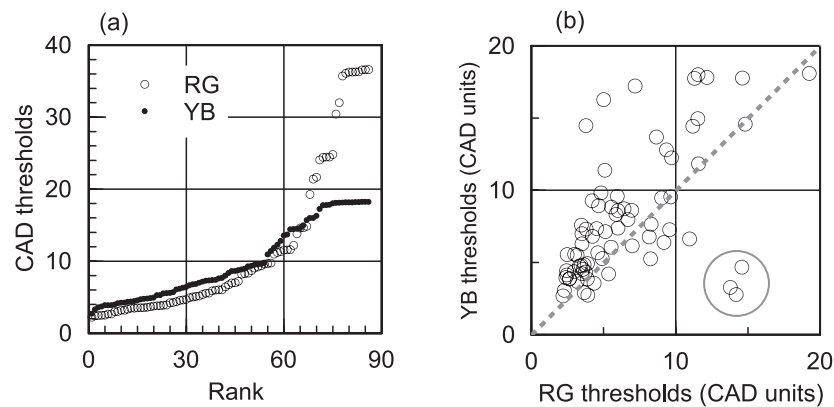


FIGURE 3. Distribution of RG and YB thresholds measured in the study. (a) CAD threshold (RG/YB) from each eye ranked in ascending order, independent of each other. The thresholds span the full range from just greater than the upper normal limits to the maximum chromatic saturations possible in the RG and YB directions. The maximum RG chromatic displacement is much larger than what can be achieved along the YB axis, as larger YB signals are needed at threshold and also owing to limitation of visual display. (b) Relationship between the RG and YB thresholds measured in the same eye. Most YB thresholds are above the dotted gray line of unity gradient. The results show the correlation between RG and YB thresholds when limited to values < 18.2 units, the upper limit of chromatic displacement for the YB direction (i.e., $YB = 1.95 + 1.03 \cdot RG$, $r^2 = 0.58$). The three patients (shown within the circle) with much larger RG thresholds are highly likely to have congenital RG deficiency in addition to acquired loss of color vision and have not been included in the study.

with AMD were compared against age-matched normative data.¹² The measured thresholds were related to the severity of AMD grading. Thresholds measured in eyes with RPD were also compared against those measured in eyes without RPD. The Student's *t*-test was used to determine if the two sets of data were significantly different from each other. A *P* value < 0.05 was considered significant.

RESULTS

Chromatic Sensitivity in AMD

The CAD test was performed in 90 eyes of 67 subjects: 26 men, and 41 women. The mean age of the subjects was 70 years, ranging from 55 to 88 years. The logMAR visual acuity of the participants selected for the study ranged from 0.0 to 0.3. Lenticular opacities in most eyes tested were classified either as N0, Ctr, P0 (33%) or N0, CI, P0 (33%). The remaining subjects were either pseudophakic or classified as NI, CI, PI (according to the LOCS II classification¹⁶).

Chromatic Sensitivity Results in Our Study Group

Every eye had either RG or YB thresholds, or both, above the upper normal limits for the corresponding age.¹² The distribution of thresholds spreads over the whole scale of severity from just above normal limits to the maximum chromatic saturation imposed by the limits of the visual display (i.e., ~ 2.5 – 36.6 CAD units RG and ~ 2.7 – 18.21 YB).

The independent ranking of RG and YB thresholds of AMD eyes, after eliminating those with thresholds above 18.2 CAD units (to account for the maximum possible YB limit), revealed higher YB thresholds when compared to RG ($P < 0.002$). This observation demonstrates clearly that on average loss of YB sensitivity precedes RG. The linear regression analysis limited to data below 18.2 CAD units yielded an r^2 value of 0.58 (Fig. 3b). The two thresholds are therefore correlated, but the YB loss was in general slightly greater than the RG loss. Three AMD patients with acquired loss on top of congenital RG deficiency (Fig. 3b) were not included in this analysis.

The Chromatic Loss in AMD Compared to Age-Matched Normals

The measured colored thresholds in AMD eyes were significantly higher for both RG and YB than for age-matched normal data ($P < 0.0001$). The loss of chromatic sensitivity in AMD can be clearly demonstrated by comparing directly the measured thresholds against the corresponding age-matched normal RG and YB thresholds¹² (Figs. 4a, 4b).

Correlation Between Clinical Classification Grades and Loss of Chromatic Sensitivity

Most eyes examined in this study were classified as intermediate AMD ($n = 70\% \sim 78\%$). Patients in this group had mean

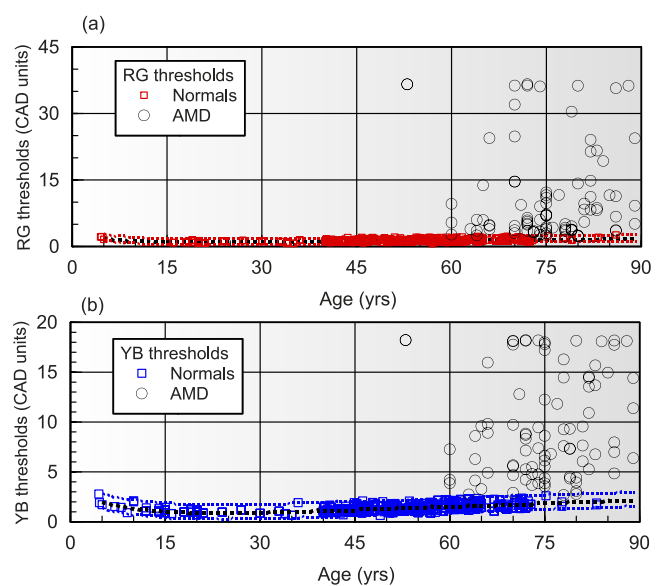


FIGURE 4. RG (a) and YB (b) CAD thresholds measured in AMD patients and plotted as a function of age, together with thresholds measured in healthy normal trichromats. The normative data are based on 720 eyes filtered for congenital and acquired color deficiencies.

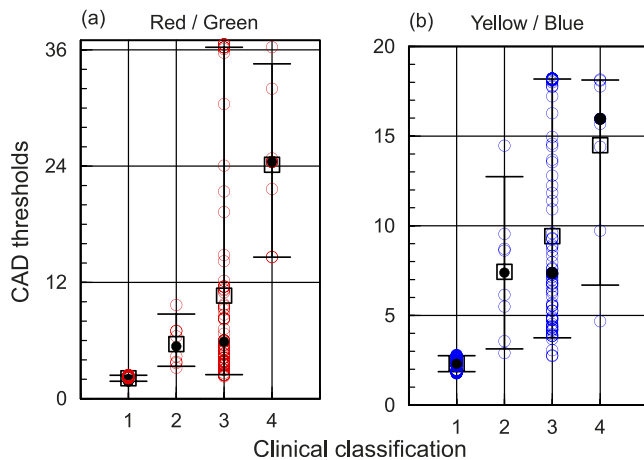


FIGURE 5. Spread in RG and YB thresholds within the four groups, based on the clinical classification criteria: 1 = normal, 2 = early, 3 = intermediate, 4 = late. Individuals' CAD thresholds of each eye are plotted for each of the four groups; the *whiskers* show the 5th and 95th percentile, while the mean values are plotted as an *outline square* and the median as a *solid black disk* for each group. Both indices increase significantly from the "normal" to the "late" group. Although routine statistical tests cannot be relied upon when skewed distributions are involved, the "late" AMD group in eyes with early GA had more severe loss of both RG and YB color vision as reflected in the much larger mean and median values. Significant skewness is only observed in the "intermediate" group, which suggests that the clinical classification criteria for this group may not be appropriate.

thresholds of 10.63 for RG and 9.42 for YB. There was wide intersubject variation with thresholds spreading across the whole spectrum of CAD threshold values.

There was no statistically significant difference between intermediate-AMD and early-AMD group, but the sample size for early AMD was small ($n = 8$; see Fig. 5).

CMT data were available in 90 eyes. CAD thresholds for eyes with CMT values $\leq 200 \mu\text{m}$ were significantly different from those measured in eyes with CMT values $> 200 \mu\text{m}$ ($P < 0.01$

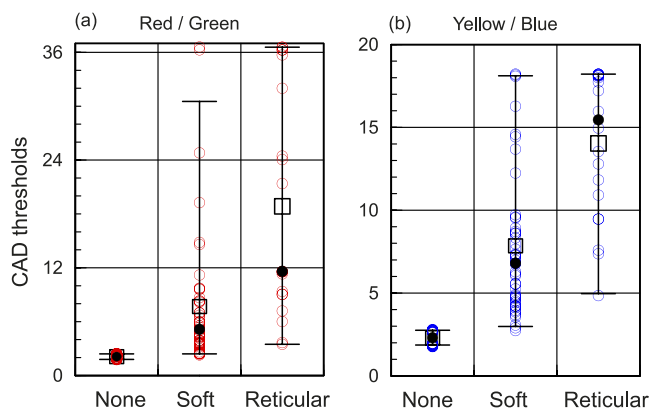


FIGURE 6. Spread in RG and YB thresholds in eyes classed as normal aging, soft drusen, and those with reticular drusen. The *whiskers* show the 5th and 95th percentile, while the mean values are plotted as an *outline square* and the median as a *solid black disk* for each group. The "none" group included three subjects classed as having changes attributed to normal aging as well as age-matched normal eyes from normative database. The RG thresholds in the "reticular" group are more skewed than the YB thresholds. In general, both the mean and median values increase significantly in the reticular group in spite of these asymmetries; there is little doubt that the loss of chromatic sensitivity is most evident in the "reticular" group.

for RG and < 0.002 for YB). Eyes noted to have incidental early GA with good vision showed very severe loss of RG/YB thresholds.

Chromatic Sensitivity Related to the Presence of RPD

Seventy-one eyes remained after excluding those with incidental late AMD and eyes with only pigmentary change, but no drusen. Of these eyes, 49 had only soft drusen, 20 eyes had reticular drusen (RPD), and 3 eyes had small drusen ($< 63 \mu\text{m}$) that was classified as normal aging.

Subjects with reticular drusen had the highest mean CAD thresholds (i.e., RG = 18.9 and YB = 14 CAD units). Subjects within the soft drusen group had mean RG thresholds of 7.7 and YB thresholds of 7.9 (Fig. 6). Typical examples are shown in Figures 7a and 7b.

Both the soft drusen and the RPD groups showed significantly larger thresholds than the normal group ($P < 0.0001$). The mean difference between the soft drusen and RPD groups was also statistically significant ($P < 0.0001$ for both RG and YB). The subjects within the reticular drusen group were significantly more affected than those in the soft drusen group.

DISCUSSION

Either YB or RG thresholds, or both, were found to be abnormal in every eye with AMD, when comparison was made with the upper normal limits for the corresponding age. Color vision depends on the normal functioning of cone photoreceptors and the normal processing of these signals in the retina. Early changes in the retina that are not detected and labeled as structural changes when using clinical fundus imaging techniques may cause loss of chromatic sensitivity, even when high-contrast visual acuity is spared. The latter is therefore a poor indicator of the earliest changes in the retina that must precede the loss of color vision. In addition, the foveal cone mosaic and the corresponding visual acuity can remain within normal limits even when the cone density decreases well below normal values at or near the fovea.⁴¹

Rod loss precedes cone loss in 75% of early- and intermediate-AMD eyes⁴² and deficits in rod-mediated functions occur in AMD and RPD.³³ In spite of these observations, changes in cone-mediated visual functions such as CV and rapid flicker sensitivity have been reported in early AMD. Cones may not therefore function normally or cone signals may not be processed efficiently in AMD despite unaltered foveal cone numbers, as evident in histopathologic studies.¹⁴

The findings from this study demonstrated that YB loss is on average greater than RG loss. There was also a greater number of patients with only YB thresholds above upper normal limits. This observation is consistent with reports by Verriest⁴³ and others who have found YB loss to be the most commonly acquired CV deficiency in macular pathology. It has been proposed that the damage to the smaller number of S cones and their pathways is more apparent in diseases of the retina.⁴⁴ Changes in the metabolic environment of the RPE-photoreceptor complex also appear to affect S more than L and M cones.⁴⁵ Eisner and her colleagues^{46,47} have demonstrated in more than one study that patients who exhibit lower S-cone sensitivities are associated with high risk of developing wet AMD.

Our findings also showed that AMD eyes with RPD exhibited the greatest loss of both RG and YB chromatic sensitivity. The presence of RPD is a recognized risk factor in progression to GA or CNV in AMD subjects.⁴⁸ Significant

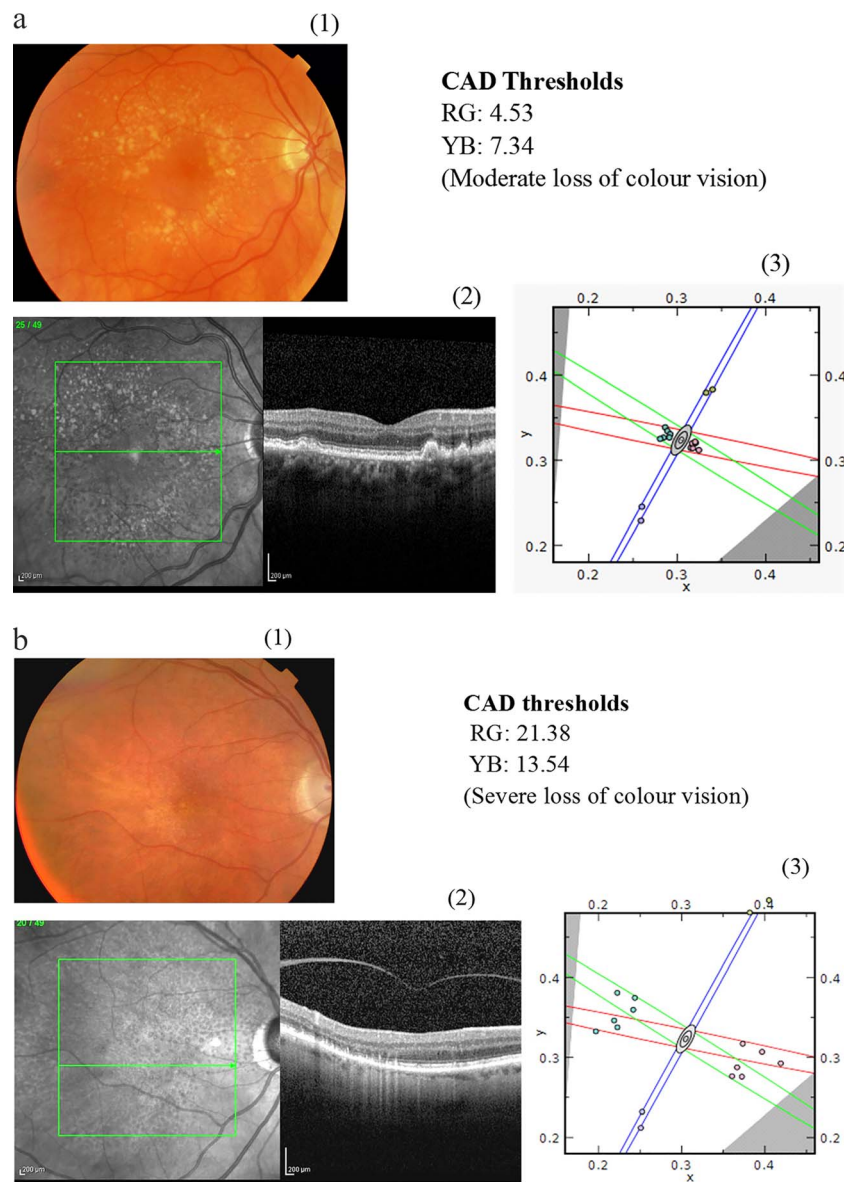


FIGURE 7. (a) Example of eye with soft drusen showing a moderate loss of chromatic sensitivity: (1) fundus photo, (2) OCT scan, and (3) CAD results. (b) Example of images from eye with reticular drusen showing severe loss of chromatic sensitivity: (1) fundus photo, (2) OCT scan, and (3) CAD results.

histologic changes in eyes with RPD have been reported, and Spaide⁴⁹ has found the photoreceptor length reduced to 74.4% and choroidal thickness reduced to 81.4% of its initial value. Subretinal drusenoid deposits, a histologic correlate of RPD, have been found to be localized preferentially around the perifovea affecting the rods, which are abundant at this eccentricity. Cones are also not spared completely either, and high-resolution imaging with large pupils and correction of higher-order aberrations using adaptive optics also show a dramatic reduction in cone density over the RPD lesions, possibly due to change in their orientation, alteration in their cellular architecture, or even absence of cones themselves.⁵⁰ These observations suggest that eyes with RPD undergo less apparent structural changes that precede the presence of CNV or GA.

One possible hypothesis to account for the specific loss of color vision is choroidal hypoxia,⁵¹ which in turn may be a cause or consequence of RPD. The photoreceptors are highly

active metabolically, and choroidal hypoxia will undoubtedly compromise the normal functioning of photoreceptors. This, in turn, can cause a uniform loss of chromatic sensitivity, particularly when rods consume more oxygen under mesopic, low-light-level conditions of ambient lighting.¹⁸ In addition to changes in the normal functioning of cone photoreceptors with little or no effect on visual acuity, it is highly likely that choroidal hypoxia also causes changes in the inner retina that may cause specific loss of chromatic sensitivity.

Most eyes in this study were graded as intermediate AMD, which include eyes with drusen size $>125 \mu\text{m} \pm$ pigmentary change. The CAD thresholds in this group spread across the severity scale with large intersubject variation. This large variability does suggest the involvement of other factors not visualized on clinical grading that occur in aging/AMD such as axonal loss of the distal segment of the optic nerve, decreased choroidal blood flow, increase in the oxidative stress, incomplete degradation of cells, and material accumulating

between the RPE and Bruch's membrane. Together, these processes are likely to slow the transfer of fluids and essential nutrients across Bruch's membrane. The microenvironment changes in the retinal and the choroidal space in AMD may not be detectable in conventional imaging. Although many aspects of functional vision remain relatively normal, the loss of both RG and YB color vision can be surprisingly severe in AMD. Although this conclusion is fully justified by our data, the correlation with the clinical classification criteria of normal, early, intermediate, and late is less well demonstrated. This is largely due to the intersubject variability and the relatively small number of patients per group. The study was limited in the number of eyes in early-AMD and late-AMD groups and, as a result, useful comparisons of the severity of CV loss between the AMD groups could not be made.

CONCLUSIONS

Patients with AMD can exhibit large loss of both RG and YB chromatic sensitivity. In some cases, such losses precede obvious clinical signs and may represent the earliest detectable functional changes. Patients with RPD exhibited the greatest loss of chromatic sensitivity. Such losses may turn out to be sensitive and important indicators of early macular atrophy. In addition to loss of rod function, which has been demonstrated in early phases of AMD, this study also revealed the significant loss of sensitivity to chromatic signals, which indirectly must implicate the normal functioning of cones and/or the subsequent processing of cone signals within the retina. These findings suggest that evaluation of chromatic sensitivity using the CAD test can be a potential biomarker in AMD, particularly in RPD.

Acknowledgments

Preliminary findings from this project have been presented at ARVO 2012, Euretina 2012, ICVS 2013, and ARVO 2016.

The authors thank City, University of London and Kings College Hospital for financial support with the doctoral studentship (to RV) and the equipment provided for this project.

Supported by the National Institute for Health Research (NIHR) Biomedical Research Centre based at Moorfields Eye Hospital NHS Foundation Trust and UCL Institute of Ophthalmology. The views expressed are those of the author(s) and not necessarily those of the NHS, the NIHR, or the Department of Health.

Disclosure: **R. Vemala**, None; **S. Sivaprasad**, Novartis (C), Allergan (C), Bayer (C); **J.L. Barbur**, City Occupational Ltd (S), P

References

1. Wong WL, Su X, Li X, et al. Global prevalence of age-related macular degeneration and disease burden projection for 2020 and 2040: a systematic review and meta-analysis. *Lancet Glob Health*. 2014;2:e106-e116.
2. Ferris FL III, Wilkinson CP, Bird A, et al. Clinical classification of age-related macular degeneration. *Ophthalmology*. 2013; 120:844-851.
3. Rauscher FG, Chisholm CM, Edgar DF, Barbur JL. Assessment of novel binocular colour, motion and contrast tests in glaucoma. *Cell Tissue Res*. 2013;353:297-310.
4. Chen JS, Adelman RA. Hyperacuity exam screens for choroidal neovascularization in age-related macular degeneration on a mobile device. *Ophthalmic Surg Lasers Imaging Retina*. 2016;47:708-715.
5. Maynard ML, Zele AJ, Feigl B. Mesopic Pelli-Robson contrast sensitivity and MP-1 microperimetry in healthy ageing and

age-related macular degeneration. *Acta Ophthalmol*. 2016;94:e772-e778.

6. Flamendorf J, Agron E, Wong WT, et al. Impairments in dark adaptation are associated with age-related macular degeneration severity and reticular pseudodrusen. *Ophthalmology*. 2015;122:2053-2062.
7. Miden E, Pilotto E. Microperimetry in age-related macular degeneration. *Eye (Lond)*. 2017;31:985-994.
8. Wu Z, Ayton LN, Luu CD, Guymer RH. Relationship between retinal microstructures on optical coherence tomography and microperimetry in age-related macular degeneration. *Ophthalmology*. 2014;121:1445-1452.
9. Vujosevic S, Pucci P, Casciano M, et al. Long-term longitudinal modifications in mesopic microperimetry in early and intermediate age-related macular degeneration. *Graefes Arch Clin Exp Ophthalmol*. 2016;255:301-309.
10. Hering E. *Outlines of a Theory of the Light Sense*. Hurvich LM, Jameson D, translators. Cambridge, MA: Harvard University Press; 1964.
11. Kolb H, Lipetz LE. The anatomical basis for colour vision in the vertebrate retina. In: *Vision and Visual Dysfunction*. London: Macmillan Press Ltd; 1991:128-145.
12. Barbur JL, Rodriguez-Carmona M. Color vision changes in normal aging. In: Elliott AJ, Fairchild MD, Franklin A, eds. *Handbook of Color Psychology*. United Kingdom: Cambridge University Press; 2015:180-196.
13. Barbur JL, Rodriguez-Carmona M. Colour vision requirements in visually demanding occupations. *Br Med Bull*. 2017;122:1-27.
14. Neelam K, Nolan J, Chakravarthy U, Beatty S. Psychophysical function in age-related maculopathy. *Surv Ophthalmol*. 2009; 54:167-210.
15. O'Neill-Biba M, Sivaprasad S, Rodriguez-Carmona M, Wolf JE, Barbur JL. Loss of chromatic sensitivity in AMD and diabetes: a comparative study. *Ophthalmic Physiol Opt*. 2010;30:705-716.
16. Chylack LT Jr, Leske MC, McCarthy D, Khu P, Kashiwagi T, Sperduto R. Lens opacities classification system II (LOCS II). *Arch Ophthalmol*. 1989;107:991-997.
17. Rodriguez-Carmona M, Barbur JL. Variability in normal and defective colour vision: consequences for occupational environments. In: Best J, ed. *Colour Design: Theories and Applications*. Woodhead Publishing, Duxford, United Kingdom: Elsevier; 2017:43-97.
18. Barbur JL, Connolly DM. Effects of hypoxia on color vision with emphasis on the mesopic range. *Expert Rev Ophthalmol* 2011;6:409-420.
19. Rodriguez-Carmona M, O'Neill-Biba M, Barbur JL. Assessing the severity of color vision loss with implications for aviation and other occupational environments. *Aviat Space Environ Med*. 2012;83:19-29.
20. Barbur JL. 'Double-blindsight' revealed through the processing of color and luminance contrast defined motion signals. *Prog Brain Res*. 2004;144:243-259.
21. Walkey HC, Barbur JL, Harlow A, Makous W. Measurements of chromatic sensitivity in the mesopic range. *Colour Res Appl*. 2001;26:36-42.
22. Barbur JL, Harlow AJ, Plant GT. Insights into the different exploits of colour in the visual cortex. *Proc R Soc Lond B*. 1994;258:327-334.
23. Barbur JL, Rodriguez-Carmona M, Harlow A. Establishing the statistical limits of "normal" chromatic sensitivity. In: *CIE Expert Symposium, CIE Proceedings; 75 Years of the Standard Colorimetric Observer*. Ottawa, Ontario, May 2006.
24. Barbur JL, Konstantakopoulou E. Changes in color vision with decreasing light level: separating the effects of normal aging

- from disease. *J Opt Soc Am A Opt Image Sci Vis.* 2012;29:A27-A35.
25. Rodriguez-Carmona M, Kvangsakul J, Harlow JA, Kopcke W, Schalch W, Barbur JL. The effects of supplementation with lutein and/or zeaxanthin on human macular pigment density and colour vision. *Ophthalmic Physiol Opt.* 2006;26:137-147.
 26. Barbur JL, Harlow JA, Williams C. Light scattered in the eye and its effect on the measurement of the colour constancy index. In: Cavonius CR, ed. *Colour Vision Deficiencies XIII*. Dordrecht, The Netherlands: Kluwer Academic Publishers; 1997:439-448.
 27. Klein R, Klein BE, Tomany SC, Meuer SM, Huang GH. Ten-year incidence and progression of age-related maculopathy: The Beaver Dam Eye Study. *Ophthalmology.* 2002;109:1767-1779.
 28. Seddon JM, Sharma S, Adelman RA. Evaluation of the clinical age-related maculopathy staging system. *Ophthalmology.* 2006;113:260-266.
 29. Klein R, Klein BE, Knudtson MD, Meuer SM, Swift M, Gangnon RE. Fifteen-year cumulative incidence of age-related macular degeneration: the Beaver Dam Eye Study. *Ophthalmology.* 2007;114:253-262.
 30. Pauleikhoff D, Barondes MJ, Minassian D, Chisholm IH, Bird AC. Drusen as risk factors in age-related macular disease. *Am J Ophthalmol.* 1990;109:38-43.
 31. Ferris FL, Davis MD, Clemons TE, et al. A simplified severity scale for age-related macular degeneration: AREDS Report No. 18. *Arch Ophthalmol.* 2005;123:1570-1574.
 32. Mimoun G, Soubrane G, Coscas G. Macular drusen [in French]. *J Fr Ophthalmol.* 1990;13:511-530.
 33. Sivaprasad S, Bird A, Nitiahpapand R, Nicholson L, Hykin P, Chatziralli I. Perspectives on reticular pseudodrusen in age-related macular degeneration. *Surv Ophthalmol.* 2016;61:521-537.
 34. Smith RT, Sohrab MA, Busuioc M, Barile G. Reticular macular disease. *Am J Ophthalmol.* 2009;148:733-743.e2.
 35. Sohrab MA, Smith RT, Salehi-Had H, Sadda SR, Fawzi AA. Image registration and multimodal imaging of reticular pseudodrusen. *Invest Ophthalmol Vis Sci.* 2011;52:5743-5748.
 36. Ueda-Arakawa N, Ooto S, Tsujikawa A, Yamashiro K, Oishi A, Yoshimura N. Sensitivity and specificity of detecting reticular pseudodrusen in multimodal imaging in Japanese patients. *Retina.* 2013;33:490-497.
 37. Arnold JJ, Sarks SH, Killingsworth MC, Sarks JP. Reticular pseudodrusen: a risk factor in age-related maculopathy. *Retina.* 1995;15:183-191.
 38. Cohen SY, Dubois L, Tadayoni R, Delahaye-Mazza C, Debibie C, Quentel G. Prevalence of reticular pseudodrusen in age-related macular degeneration with newly diagnosed choroidal neovascularisation. *Br J Ophthalmol.* 2007;91:354-359.
 39. Klein R, Meuer SM, Knudtson MD, Iyengar SK, Klein BE. The epidemiology of retinal reticular drusen. *Am J Ophthalmol.* 2008;145:317-326.
 40. Pumariega NM, Smith RT, Sohrab MA, Letien V, Souied EH. A prospective study of reticular macular disease. *Ophthalmology.* 2011;118:1619-1625.
 41. Ratnam K, Carroll J, Porco TC, Duncan JL, Roorda A. Relationship between foveal cone structure and clinical measures of visual function in patients with inherited retinal degenerations. *Invest Ophthalmol Vis Sci.* 2013;54:5836-5847.
 42. Curcio CA, Owsley C, Jackson GR. Spare the rods, save the cones in aging and age-related maculopathy. *Invest Ophthalmol Vis Sci.* 2000;41:2015-2018.
 43. Verriest G. Further studies on acquired deficiency of color discrimination. *J Opt Soc Am.* 1963;53:185-195.
 44. Boycott BB, Wassle H. Morphological classification of bipolar cells of the primate retina. *Eur J Neurosci.* 1991;3:1069-1088.
 45. Spraul CW, Lang GE, Grossniklaus HE, Lang GK. Histologic and morphometric analysis of the choroid, Bruch's membrane, and retinal pigment epithelium in postmortem eyes with age-related macular degeneration and histologic examination of surgically excised choroidal neovascular membranes. *Surv Ophthalmol.* 1999;44(suppl 1):S10-S32.
 46. Eisner A, Stoumbos VD, Klein ML, Fleming SA. Relations between fundus appearance and function: eyes whose fellow eye has exudative age-related macular degeneration. *Invest Ophthalmol Vis Sci.* 1991;32:8-20.
 47. Eisner A, Klein ML, Zilis JD, Watkins MD. Visual function and the subsequent development of exudative age-related macular degeneration. *Invest Ophthalmol Vis Sci.* 1992;33:3091-3102.
 48. Naysan J, Jung JJ, Dansingani KK, Balaratnasingam C, Freund KB. Type 2 (subretinal) neovascularization in age-related macular degeneration associated with pure reticular pseudodrusen phenotype. *Retina.* 2016;36:449-457.
 49. Spaide RF. Outer retinal atrophy after regression of subretinal drusenoid deposits as a newly recognized form of late age-related macular degeneration. *Retina.* 2013;33:1800-1808.
 50. Mrejen S, Sato T, Curcio CA, Spaide RF. Assessing the cone photoreceptor mosaic in eyes with pseudodrusen and soft drusen in vivo using adaptive optics imaging. *Ophthalmology.* 2014;121:545-551.
 51. Alten F, Eter N. Current knowledge on reticular pseudodrusen in age-related macular degeneration. *Br J Ophthalmol.* 2015;99:717-722.