



Contents lists available at ScienceDirect

Oral Oncology

journal homepage: www.elsevier.com/locate/oraloncology

Review

The infrahyoid flap: A comprehensive review of an often overlooked reconstructive method

Alberto Deganello ^{a,*}, C René Leemans ^{a,b}^a Academic Clinic of Otolaryngology – Head and Neck Surgery, Department of Translational Medicine and Surgery, University of Florence, Florence, Italy^b Department of Otolaryngology – Head and Neck Surgery, VU Medical Center, Amsterdam, The Netherlands

ARTICLE INFO

Article history:

Received 15 December 2013

Received in revised form 22 April 2014

Accepted 26 April 2014

Available online xxxx

Keywords:

Infrahyoid flap

Pedicled flap

Free flap

Alternative flap

Head and neck reconstruction

ABSTRACT

The infrahyoid flap is a myocutaneous pedicled flap mainly nourished by the superior thyroid vessels through the perforators of the infrahyoid muscles. This thin and pliable flap provides a skin island of about 7 by 4 cm from the central part of the anterior neck. The flap can be transferred on its pedicle of superior thyroid artery and vein to reconstruct medium sized head and neck defects created after cancer ablation. We have successfully used this flap in a series of 40 cases with no total flap loss and with 1 case of superficial skin necrosis. The aim of this review is to highlight the clinical usefulness of this pedicled flap even in the microvascular free flap era. A comprehensive review of the available literature reporting on the infrahyoid flap has been carried out using a web search. The history of the infrahyoid flap, the surgical technique with technical innovations, the clinical utility and limitations of this flap, are reported and discussed. Among the 7 larger series (cohort larger than 50 cases) a total of 956 flaps were performed, and the global success rate was 91.7%, with failures being mainly related to partial skin necrosis, as the rate of total (skin and muscle) flap necrosis was only 1%.

This flap is reliable, easy to harvest during neck dissection, oncologically safe, it does carry a negligible donor site morbidity. This paper highlights how the infrahyoid flap can represent an excellent reconstructive solution in selected patients and head and neck sites.

© 2014 Elsevier Ltd. All rights reserved.

Introduction

The introduction of microvascular reconstructions has provided the head and neck surgeon with the possibility of choosing among a broad variety of free flaps. This reconstructive method represents a major evolution in the management of head and neck cancer with a consequent reduction of pedicled flap reconstructions. The IHF is a thin and pliable pedicled flap that has been developed in a free flap era, hence it is important to assess its usefulness in this modern scenario.

History

The first report of using the infrahyoid system of muscles as a pedicled flap with reconstructive intents came from Clairmont and Conley in 1977 [1]. In their report they described the transposition of the infrahyoid muscles to repair anterior floor of mouth

defects arising from pull through composite resections with en block neck dissection. In the report it was clearly specified that only the infrahyoid muscles were transposed upwards, and the Authors recommended to make any effort to preserve the superior thyroid artery and the innervation by the ansa hypoglossi in order to ensure the viability of this newly designed flap.

In 1984 Eliachar et al. included the overlying skin to a transposition of the infrahyoid muscles for the reconstruction of laryngotracheal defects. In their technique this myocutaneous flap was used as a rotary-door flap with a double blood supply from the superior and inferior thyroid arteries [2,3]. Having thus substantial limitation on the arch of rotation (coming from the need of maintaining both cranial and caudal pedicles), this rotary-door flap was therefore recommended only for laryngotracheal defects.

In 1985 Rabson et al. pointed out how the inferior cervical skin approaching the midline receives blood supply from perforator vessels coming from the superior thyroid artery piercing the infrahyoid muscles [4].

The most important and decisive step was taken by Wang et al. when in 1986 they first reported in the English literature the surgical technique and the results of 112 head and neck reconstructions in 108 patients, describing the infrahyoid myocutaneous

* Corresponding author. Address: Clinic of Otolaryngology – Head and Neck Surgery, University of Florence Largo Brambilla 13 - 50134 Firenze. Tel.: +39 0557947054; fax: +39 055435649.

E-mail address: adeganello@hotmail.com (A. Deganello).

flap as we know it today [5]. The flap was mainly transposed to replace intraoral defects, the blood supply being clearly identified in the superior thyroid vessels. It is important to remark that since this first report Wang noticed how this easy and quick reconstructive method was particularly convenient and useful in weak elderly patients. This series starts from May 1979, so, even if undoubtedly Wang is the father of this flap, credit for the original idea (the grandfathers) must be given to Clairmont and Conley [1].

Methods

A comprehensive review of the available literature reporting on the IHF has been carried out using a web search in Pubmed/Medline, Google Scholar, Isi Web of Knowledge and Scopus. Nowadays, this method is reported in 61 published papers, including less than 1400 patients. Only 24 full text papers in the English language were published in 28 years since 1986, with only 10 papers appearing in US Journals [5–14], the remaining 37 papers were published in other languages (Chinese, French, German, Polish and Japanese).

This review is intended to highlight the many advantages that this flap can offer to the head and neck surgeon even in a free flap era.

Surgical technique

In its original description by Wang et al. the IHF is harvested as a myocutaneous flap [5] after ipsilateral modified radical or selective neck dissection is completed. Technically, the harvest of the IHF does not interfere with the extent of the neck dissection, since this flap lies in the central compartment of the neck, medial to the carotid artery at neck level VI. When a therapeutic modified radical neck dissection is indicated, this is performed according to the standard technique, with the only mandatory requirement being the preservation of the superior thyroid vein and the caudal stump of the internal jugular vein.

The infrahyoid muscles included in this flap are the sternohyoid muscle, the superior belly of the omohyoid muscle [6] and the sternothyroid muscle. Usually the flap is unilateral and the side is determined by the location of the defect, therefore the skin paddle and cervical incision for neck dissection are outlined in the same neck side of the tumor resection. The shape of the flap is rectangular or oval in a vertical position, and the skin paddle must be fitted and included in the incision for unilateral or bilateral neck dissection. In 2005 Dolivet et al. [15] introduced a modification for the neck incision proposing an S instead of the original T shaped incision, and this modification was acquired in further reports (Fig. 1) [8,11,16–20].

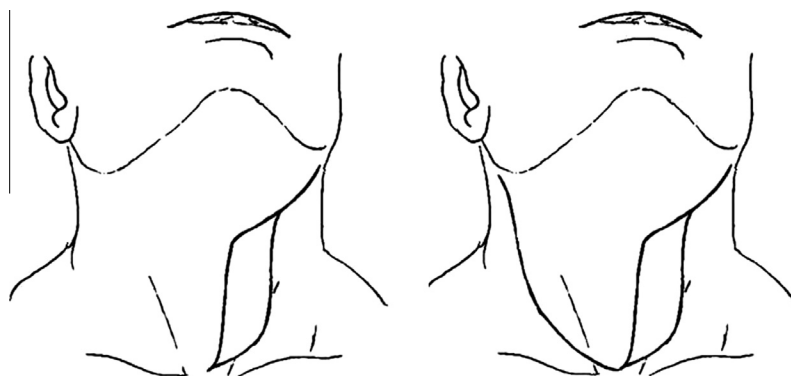


Fig. 1. Neck incision: vertically oriented infrahyoid flap at the left side: neck incision for unilateral and bilateral neck dissection.

The medial edge of the IHF lies at the midline, the upper edge at the level of the hyoid bone and the lower edge at the suprasternal notch, the lateral edge lies three to five cm from the midline. When a tracheotomy is required this is usually performed first and it is important to prevent tracheotomy site contamination to the wound bed. We recommend to place the caudal edge of the skin paddle at list 1 cm above the incision for the tracheotomy, and to open the trachea under the thyroid isthmus; the harvest of the flap will eventually create a communication with the tracheotomy at the side where the infrahyoid muscles are harvested, later on, to ensure a tight separation, the thyroid isthmus and the sternal edge of the sternocleidomastoid muscle are sutured to the subcutaneous tissue above the tracheotomy opening.

The skin and platysma all around the skin paddle are incised to allow prompt choke perforator vessels opening [8]; the skin flaps are elevated and, before starting with the intended modified radical or selective neck dissection, the superficial cervical fascia along the anterior border of the sternocleidomastoid muscle, from the sternal insertion to the level of the hyoid bone, is incised and the dissection of the fascia proceeds until the omohyoid muscle is identified at its intersection with the internal jugular vein. The intermediate tendon is divided and the fascia, together with the anterior belly of the omohyoid muscle is elevated towards the lateral edge of the skin paddle and sutured to it Fig. 2.

Neck dissection and primary tumor resection are now completed.

The elevation of the flap starts by dividing the anterior jugular vein and sectioning the sterno-hyoid and sterno-thyroid muscles distally at the level of the suprasternal notch. The skin paddle is stitched to the underlying muscles and then the IHF is raised over the avascular plane of the proper capsule of the thyroid gland, Fig. 3. When the dissection reaches the upper pole of the thyroid gland, the crico-thyroid artery (at the midline of the neck) and the posterior branch of the superior thyroid artery (at its entrance in the upper pole of the gland) are cut, ligated and kept with the flap. The sterno-thyroid muscle is detached from the thyroid cartilage, Fig. 4. Fascial connections between the superficial and median cervical fascia are maintained in proximity of the neurovascular pedicle; these fascial connections are important to directly provide microvascular venous return towards the median cervical fascia and to protect the superior thyroid vein from twisting or kinking [8,11].

Special care must be taken in preserving the external branch of the superior laryngeal nerve, and therefore the thyrohyoid muscle is usually spared and left in place. Finally, the hyoid insertions of the sternohyoid and omohyoid muscles are severed, the entire flap remains attached only by the neurovascular pedicle formed by the superior thyroid artery and vein, and nerves from the ansa cervicalis, and is then ready to be transferred to reconstruct the defect,

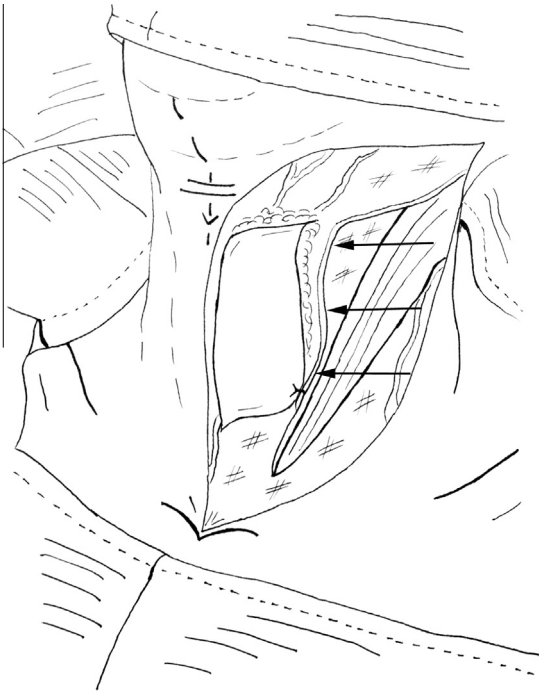


Fig. 2. Step 1 harvesting technique: the skin and platysma all around the skin paddle are incised, the fascia along the anterior border of the sternocleidomastoid muscle (arrows) is incised and sutured to the lateral edge of the skin paddle.

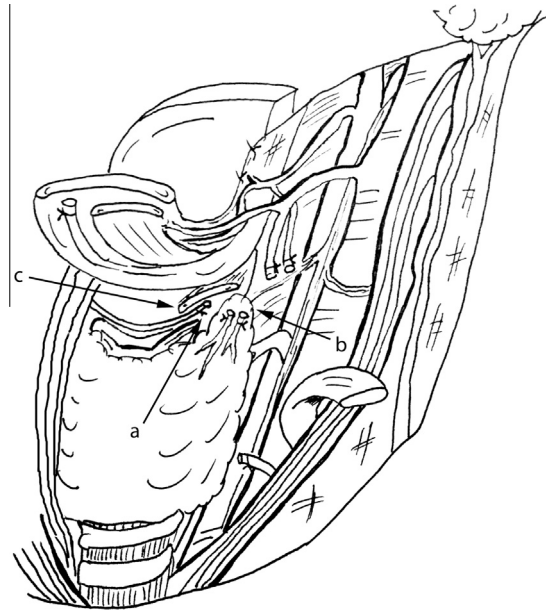


Fig. 4. Step 3 harvesting technique: the cricothyroid artery and vein (a), the posterior branch of the superior thyroid artery and vein (b), are cut, ligated and kept with the flap. The laryngeal insertion of the sternothyroid muscle is severed (c), the hyoid insertions of the sternohyoid and omohyoid muscles are severed.

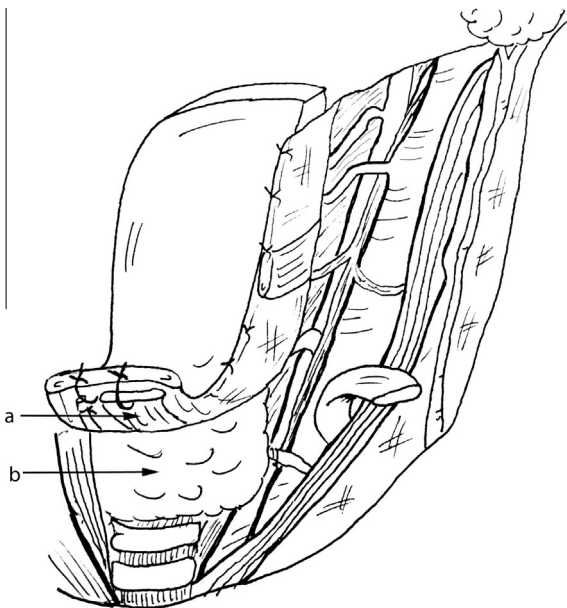


Fig. 3. Step 2 harvesting technique: the sternohyoid and sternothyroid muscles are transected at the suprasternal notch and sutured to the skin paddle (a) and the flap is elevated over the proper capsule of the thyroid lobe (b).

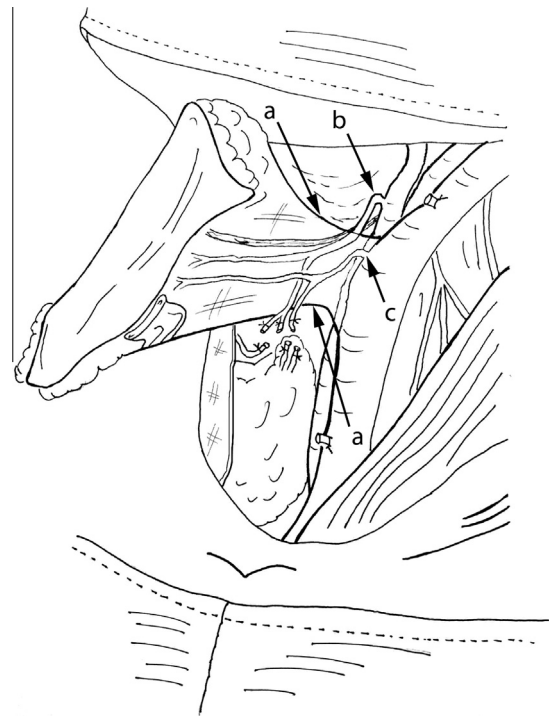


Fig. 5. Step 3 harvesting technique: fascial connections between superficial and median cervical fascia (a) are maintained to protect the pedicle: superior thyroid artery (b) and vein (c).

Fig. 5. The arc of rotation of the IHF depends on the location of the carotid bifurcation and of the superior thyroid vessels: the more cranial the more convenient to reach upper sites. The zygomatic arch sets the superior limit for the IHF, usually for soft palate or lateral pharyngeal wall reconstructions the lower edge of the skin paddle is rotated to the most cranial portion of the defect. For oral cavity reconstructions the lower edge of the skin paddle is usually placed anteriorly and the upper edge posteriorly. After the flap is

transposed to the donor site, the tacking sutures connecting the skin paddle with underlying fascia and muscles are removed, increasing the arc of rotation for the inset.

If the width of the skin paddle is not greater than 5 cm the donor site can be primary closed with excellent aesthetic results and no scar-related impairment in neck movements, otherwise the transposition of a deltopectoral flap is usually necessary.

Technical modifications

The venous drainage is anatomically ensured by both the external and internal jugular systems, and the preservation of one systems is crucial: the superior thyroid vein provides drainage to the internal jugular vein (Fig. 6); the cranial portion of the anterior jugular vein drains, with retrograde flow, into the external jugular vein (Fig. 7). Some put particular emphasis on the preservation of the cranial portion of the anterior jugular vein [12,13,21,22], which is perfectly feasible and reliable, nevertheless preservation of the external jugular system makes ipsilateral neck dissection technically more demanding.

We described a new technique for tongue base reconstruction [11]: the neurovascular IHF is transposed without detaching it from the hyoid bone that acts as rotational pivot. During deglutition, the hyoid bone elevates and pushes the flap backwards, thus helping with bolus propulsion. For defects limited to the tongue base, IHF is perfectly suited to the resected area having the desired thickness Fig. 8.

As originally suggested by Wang et al. [5], it is wise to preserve the motor innervations of the infrahyoid muscles (provided by the ansa cervicalis) in all cases of tongue reconstruction, to prevent subsequent atrophy. Conversely, for other sites, we recommended to resect all motor innervations since denervation atrophy of the underlying muscles will increase flap's pliability with better functional results Fig. 9 [11].

Majoufre-Lefebvre et al. [23] introduced the horizontal infrahyoid flap claiming less cosmetic sequelae at the donor site; this

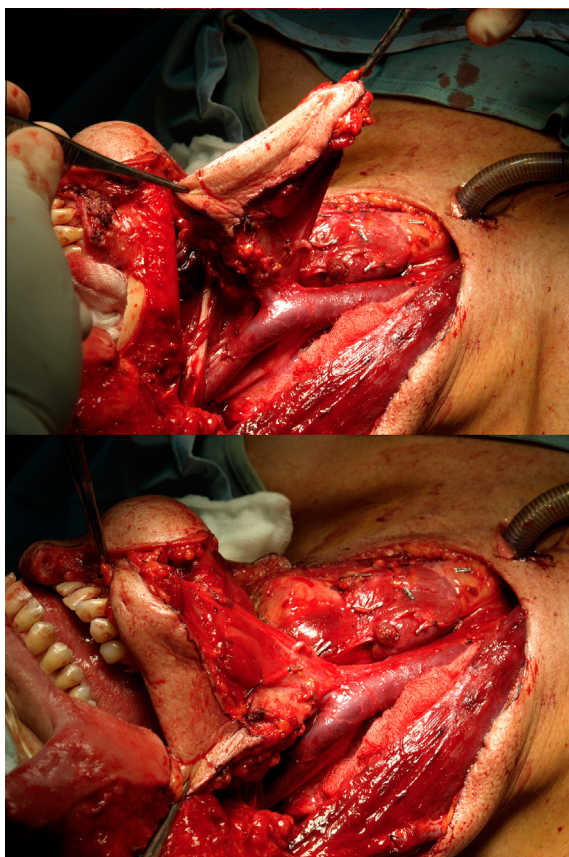


Fig. 6. Superior thyroid vein: infrahyoid flap with venous drainage ensured by the superior thyroid vein. The picture shows how the flap easily reaches the oral cavity; after the flap is transposed (medial to the mandible) to the donor site, the tacking sutures connecting the skin paddle with underlying fascia and muscles are removed to increase the arc of rotation.

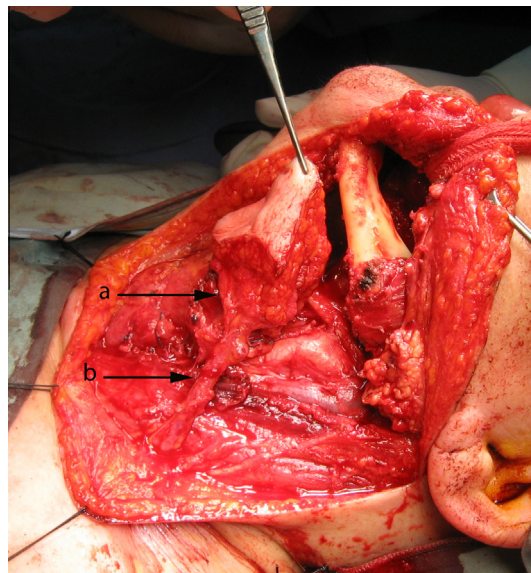


Fig. 7. Anterior jugular vein: infrahyoid flap with venous drainage ensured by the anterior jugular vein (a) and draining with retrograde flow to the external jugular vein (b). The flap is ready to reconstruct a lateral floor of mouth and alveolar ridge defect resulting from lateral pull through resection with marginal mandibulectomy and en block selective neck dissection I–III.

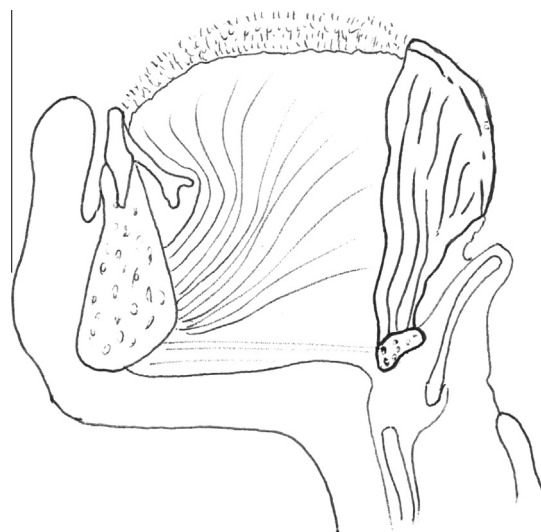

Fig. 8. Tongue base reconstruction: schematic representation of tongue base reconstruction maintaining the muscular insertions at the hyoid bone.

technique was then implemented in a large series of 276 cases from the same group [24], and the authors also stated that no additional scars in the neck were required. This is certainly true when a selective neck dissection I–III is planned (as it happened for the 275 squamous cell carcinoma patients in this series), nevertheless only the neck incision for a vertically oriented flap allows a comprehensive neck dissection without further incisions. Furthermore, a vertically oriented flap has a superior arc of rotation as compared to an horizontal flap, allowing for upper reconstructions that reach the soft palate [19].

Clinical series and results

The web search identified 7 series with a study cohort larger than 50 flaps (Table 1) [5,13,15,24–27], and 16 series with 10 to

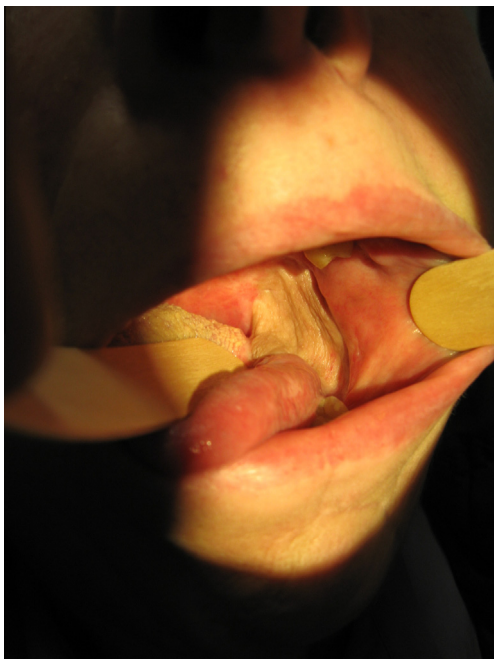


Fig. 9. Oral cavity reconstruction: Postoperative result after reconstruction of the whole retromolar trigone, the flap ensures good pliability (informed consent for publication was obtained).

50 cases [6–8,10–12,18–22,28–32]. Among the 7 larger series a total of 956 IHF were performed, and the global success rate was 91.7%, with failures being mainly related to partial skin necrosis, as the rate of total (skin and muscle) flap necrosis was only 1%.

In 1991 Wang reported his global experience with the IHF analyzing 260 cases [25]; this series came from the 112 flaps described in 1986 with further 148 flaps in the following 3 years. In the first report, Wang stated how the rate of failure was 38% (7 of 18 cases), versus 4% (4 of 94 cases) when the internal and external jugular veins were both removed or not both removed respectively. The success rate reported by Wang in the further 148 flaps was 97% [25]. Wang indicated several technical points to increase the success rate, but the attention to venous drainage is the crucial step. Another aspect to be highlighted is that no total flap necrosis was reported in this large series and the necrosis of the skin paddle never lead to further surgery.

In a series of 276 cases, the horizontal IHF was used for oral cavity reconstructions in 95.6% of the cases, insufficient venous return was recorded in 22 cases (8%), leading to partial skin paddle necrosis in 20 patients, and total skin paddle necrosis in the remaining 2 patients [24]. Also in this series no total flap loss was recorded and no further surgery was required for the management of the superficial skin paddle necrosis. All these patients received a selective neck dissection of levels I–III; data on clinical and pathological neck involvement were not reported.

Among the 16 series with 10–50 IHFs a total of 328 flaps were reported, and the overall success rate was 85.5%, with a large range from 54% [7] to 100% [8,28,31]; also in these series the rate of total (skin and muscle) flap necrosis was low (2.7%). Among the 80 flaps used as myofascial transposition [10,28,29,32], 2 partial muscular necrosis and 3 total were recorded (92.7% success rate).

Unfortunately, data regarding the oncologic appropriateness of harvesting the IHF in N+ necks are lacking.

Wang demonstrated how this flap was oncologically sound in N1 necks [25], but in the majority of other large series patients were submitted to selective neck dissections I–III, and this would indicate a preponderance of cN0 cases. Only other 7 series in literature report IHF in N+ necks [8,11,19–21,28,29]; among the 153 IHF harvested in these series, 88 flaps were harvested in N+ necks: 35 N1 out of 88 N+ (39.7%), 51 N2 (58%), 2N3 (2.27%).

Therapeutic neck dissection is not a contraindication for IHF as long as the oncologic radicality doesn't require the resection of the internal jugular vein, jeopardizing venous drainage.

Clinical utility

In head and neck reconstructions, especially for oral cavity and oropharyngeal defects, the pliability of the flap should allow for a good motility of the preserved structures all around the resected area. The majority of pedicled myocutaneous flaps for head and neck reconstruction (e.g., pectoralis major, trapezius, latissimus dorsi) are quite bulky, and this intrinsic characteristic carries a disadvantage in terms of functional results; conversely the IHF is thin and pliable competing with fascio-cutaneous free flaps in the management of medium sized defects of the floor of mouth, alveolar ridge, and base of tongue. In our experience, for these sites, the results are particularly high-quality, because the pliable skin paddle is placed and sutured all around the mucosal defect and the infrahyoid muscles fill the deep tissue loss coming from resections carried en block with neck dissection. In case of marginal mandibulectomy, the flap's muscles cover the denuded mandibular bony surface, moreover the oval/rectangular shape of the IHF perfectly matches the usual shape of the resections in these cases, Fig. 7 (informed consent for publication was obtained). Excellent functional results are also obtained for base of tongue reconstructions [10,28], especially if the flap is not detached from the hyoid bone [11].

In a series of 32 consecutive oral cavity and oropharyngeal reconstructions from our group, functional results of 18 patients in poor general conditions unfit for a microvascular procedure and therefore receiving IHF reconstruction, were as good as those of the 16 patients in good general conditions receiving microvascular free radial forearm flap transposition [11], furthermore, comparing the medical costs, IHF reconstruction produced a savings in this fragile cohort of patients [33]. We also used the IHF for intraoral reconstruction together with free fibula osseous mandibular reconstruction, whenever skin perforators for a fibular osteo-cutaneous harvest were not found or reliable [8].

Table 1
Overview of the 7 largest series.

Author	No. of flaps	Site	Previous neck RT	Skin necrosis	Flap necrosis	Patients requiring further surgery
Wang 1986	112	OC:101 Parotid:7	NR	11	0	0
Wang 1991	148	/	/	5		
Faucher 1997	62	OC:19 OP:32 PL:9 Skin:2	1	Partial: 2	2	NR
Zao 2001	53	OC:53	NR	Partial: 2 Total: 2	1	0
Verhulst 2004	153	OC:54 OP:99	1	Partial: 17	4	4
Dolivet 2005	152	OC:78 OP:47 PL:27	19	8	2	NR
Ricard 2009	276	OC: 264 OP:12	None	Partial: 22 Total: 2	0	None

OC: oral cavity, NR: not reported, OP: oropharynx, PL: pharyngo-larynx.

In literature this flap has been successfully used for defects of the oral cavity and oropharynx [5,8,11,19,25,27,30,31], the parotid region [5], the pharyngolaryngeal tract [8,15,26,27] and the cervical trachea [9]. As a myofascial transposition, it has been used to close iatrogenic pharyngeal [34] and esophageal [35] fistulas following anterior cervical spine surgery, or to prevent fistula formation after total laryngectomy [36].

Limitations

This flap does carry dimensional limitations, which make it unsuitable for large sized and complex defects. The maximal length of the flap is usually around an average of 10 cm, depending on the length of the patient's neck. If the width of the flap exceeds 5 cm, a further flap (usually a deltopectoral flap) is required to close the donor site, and this would decrease all the intrinsic convenience of the IHF; in most series the average dimensions of the flap is 7 × 4 cm. It could be consequently argued that small or medium sized defects within the oral cavity and oropharynx can also be primarily closed or reconstructed using local flaps and skin grafts, without requiring a pedicled flap or a free flap transposition. This can be true when the defect comes from a transoral resection, but if the resection put in communication the oral cavity/oropharynx with neck spaces, as a result of tumour resection with en block neck dissection, then primary closure usually leads to fixation of mobile structures; furthermore in this situation local flaps or skin grafts are less able to ensure a tight separation between different compartments to prevent the occurrence of a salivary fistula with all its negative impacts.

Whenever the defect is large or encompasses more subsites, then a reconstruction with an more pliable fascio-cutaneous free flap ensures better results as compared to IHF transposition, because microvascular flaps can better follow the contour of the original anatomy, and can also be double folded in complex reconstructions.

Previous (chemo)radiotherapy is not an absolute contraindication for IHF [5,11,15], but preoperative careful evaluation of the intended skin paddle is recommended: if lack of pliability, radiation induced fibrosis or teleangiectasias are encountered in the cervical skin, then a decrease in blood supply to the skin through the perforator vessels is probably occurring and the flap is contra-indicated. However if none of these features is present and the appearance of the skin is normal, then the flap can be considered [11,15].

Contraindications

Disadvantages of IHF mainly coincide with its contraindications: previous thyroid surgery or neck dissection, N3 neck metastasis, and positive lymphnodes at level III–IV. All these contraindications pose consistent limitations to the use of this reconstructive option. The IHF must always be planned in advance and cannot represent a back-up solution in case of other flap failure, since it cannot be used in a previously operated neck. In fact probable damages to the superior thyroid artery and/or vein and/or possible elevation of the skin overlying the strap muscles prevent the possibility to rely on this myocutaneous flap.

Conclusions

The infrahyoid flap is a quick, easy, and reliable reconstructive method, when specific contraindications are respected and when used with knowledge of its clinical utility and limitations, the functional results are excellent with great patient's satisfaction.

Conflict of interest statement

This work had no founding, furthermore there are no financial disclosures from the authors.

Acknowledgment

The Authors thank Sabino Russo, MD, for surgical illustrations.

References

- [1] Clairmont AA, Conley JJ. Surgical technique – the strap muscle flap. *J Otolaryngol* 1977;6:200–2.
- [2] Eliachar I, Marcovich A, Shai YH. Rotary-door flap in laryngotracheal reconstruction. *Arch Otolaryngol* 1984;110:585–90.
- [3] Eliachar I, Marcovich A, Har Shai Y, Lindenbaum E. Arterial blood supply to the infrahyoid muscles: an anatomical study. *Head Neck Surg* 1984;7:8–14.
- [4] Rabson JA, Hurwitz DJ, Futrell JW. The cutaneous blood supply of the neck: relevance to incision planning and surgical reconstruction. *Br J Plast Surg* 1985;38:208–19.
- [5] Wang HS, Shen JW, Ma DB, Wang JD, Tian AL. The infrahyoid myocutaneous flap for reconstruction after resection of head and neck cancer. *Cancer* 1986;57:663–8.
- [6] Rojananin S, Suphaphongs N, Ballantyne AJ. The infrahyoid musculocutaneous flap in head and neck reconstruction. *Am J Surg* 1991;162:400–3.
- [7] Magrin J, Kowalski LP, Santo GE, Waksman G, DiPaula RA. Infrahyoid myocutaneous flap in head and neck reconstruction. *Head Neck* 1993;15:522–5.
- [8] Deganello A, Marcio V, Dolivet G, Leemans CR, Spriano G. Infrahyoid fascio-myocutaneous flap as an alternative to free radial forearm flap in head and neck reconstruction. *Head Neck* 2007;29:285–91.
- [9] Masuda M, Kamizono K, Ejima M, Fujimura A, Uryu H, Kadota H. Tracheal reconstruction with a modified infrahyoid myocutaneous flap. *Laryngoscope* 2012;122:992–6.
- [10] Remmert SM, Sommer KD, Majocco AM, Weerda HG. The neurovascular infrahyoid muscle flap: a new method for tongue reconstruction. *Plast Reconstr Surg* 1997;99:613–8.
- [11] Deganello A, Gitti G, Parrinello G, et al. Infrahyoid flap reconstruction of oral cavity and oropharyngeal defects in elderly patients with severe general comorbidities. *Head Neck* 2012;34:1299–305.
- [12] Peng H, Wang SJ, Yang X, Guo H, Liu M. Infrahyoid myocutaneous flap for medium-sized head and neck defects: surgical outcome and technique modification. *Otolaryngol Head Neck Surg* 2013;148:47–53.
- [13] Zhao YF, Zhang WF, Zhao JH. Reconstruction of intraoral defects after cancer surgery using cervical pedicle flaps. *J Oral Maxillofac Surg* 2001;59:1142–6.
- [14] Perrenot C, Berengère P, Mastronicola R, Gangloff P, Dolivet G. Infrahyoid myocutaneous flap for reconstruction after robotic transoral surgery for oropharyngeal tumors. *Plast Reconstr Surg*. 2014 Feb;133:236e–7e.
- [15] Dolivet G, Gangloff P, Sarini J, et al. Modification of the infra hyoid musculocutaneous flap. *Eur J Surg Oncol* 2005;31:294–8.
- [16] Deganello A, De Bree R, Dolivet G, Leemans CR. Infrahyoid myocutaneous flap reconstruction after wide local excision of a Merkel cell carcinoma. *Acta Otorhinolaryngol Ital* 2005;25:50–3.
- [17] Deganello A, Struijs B, De Bree R. The infrahyoid myocutaneous flap in head and neck reconstruction [abstract]. *Clin Otolaryngol* 2005;30:298.
- [18] Ouyang D, Su X, Chen WC, Chen YF, Men QQ, Yang AK. Anatomical study and modified incision of the infrahyoid myocutaneous flap. *Eur Arch Otorhinolaryngol* 2013;270:675–80.
- [19] Gangloff P, Deganello A, Lacave ML, et al. Use of the infra hyoid musculocutaneous flap in soft palate reconstruction. *Eur J Surg Oncol* 2006;32:1165–9.
- [20] Mirghani H, Meyer G, Hans S, et al. The musculocutaneous infrahyoid flap: surgical key points. *Eur Arch Otorhinolaryngol* 2012;269:1213–7.
- [21] Lockhart R, Menard P, Chout P, Favre-Dauvergne E, Berard P, Bertrand JC. Infrahyoid myocutaneous flap in reconstructive maxillofacial cancer and trauma surgery. *Int J Oral Maxillofac Surg* 1998;27:40–4.
- [22] Tincani AJ, Del Negro A, Araújo PP, Akashi HK, Neves Fda S, Martins AS. Head and neck reconstruction using infrahyoid myocutaneous flaps. *Sao Paulo Med J* 2006;124:271–4.
- [23] Majoufre-Lefebvre C, Laurentjoye M, Faucher A, Zwetyenga N, Siberchicot F, Ricard AS. The horizontal infrahyoid myocutaneous flap: surgical technique. *Rev Stomatol Chir Maxillofac* 2008;109:106–9 [French].
- [24] Ricard AS, Laurentjoye M, Faucher A, Zwetyenga N, Siberchicot F, Majoufre-Lefebvre C. 276 cases of horizontal infrahyoid myocutaneous flap. *Rev Stomatol Chir Maxillofac* 2009;110:135–7 [French].
- [25] Wang HS. Further experiences with the infrahyoid myocutaneous flap in reconstruction after radical surgery of cheek and palate cancer. *Zhonghua Kou Qiang Ke Za Zhi* 1985;20(100-2):127–8 [Chinese].
- [26] Faucher A, Verhulst J, Majoufre C, de Bonfils C. Infrahyoid musculocutaneous flaps: anatomical bases and indications in cervicofacial oncologic surgery. *Rev Laryngol Otol Rhinol* 1997;118:43–6 [French].
- [27] Verhulst J, Souza Leão R. The infrahyoid musculocutaneous flap: experience of 153 cases in the reconstruction of the oropharynx and oral cavity after tumoral excision. *Rev Laryngol Otol Rhinol* 2004;125:49–53 [French].

- [28] Windfuhr JP, Remmert S. Infrahyoid myofascial flap for tongue reconstruction. *Eur Arch Otorhinolaryngol* 2006;263:1013–22.
- [29] Hell B, Heissler E, Gath H, Menneking H, Langford A. The infrahyoid flap. A technique for defect closure in the floor of the mouth, the tongue, the buccal mucosa, and the lateral pharyngeal wall. *Int J Oral Maxillofac Surg* 1997;26:35–41.
- [30] Li B, Li CH, Guo H, Chen J, Wang SX. Analysis of 27 cases of defect restoration using infrahyoid myocutaneous flap after intraoral cancer surgery. *Zhonghua Er Bi Yan Hou Tou Jing Wai Ke Za Zhi* 2008;43:826–9 [Chinese].
- [31] Minni A, Mascelli A, Suriano M. The infrahyoid myocutaneous flap in intra-oral reconstruction as an alternative to free flaps. *Acta Otolaryngol* 2010;130:733–8.
- [32] Zhuang MA. Clinical study of infrahyoid muscle flap for repairing oral oncology postoperative defect. *Hebei Medicine* 2011;5:595–8 [Chinese].
- [33] Deganello A, Gitti G, Parrinello G, Muratori E, Larotonda G, Gallo O. Costs analysis in oral cavity and oropharyngeal reconstructions with microvascular and pedicled flaps. *Acta Otorhinolaryngol Ital* 2013 [Epub ahead of print].
- [34] Seidl RO, Niedeggen A, Todt I, Westhofen M, Ernst A. Infrahyoid muscle flap for pharyngeal fistulae after cervical spine surgery: a novel approach – report of six cases. *Eur Spine J* 2007;16:501–5.
- [35] Wierzbicka M, Pabiszczak M, Smuszkiewicz P, Szyfter W. Wide esophageal wall rupture as iatrogenic complication of anterior cervical spine surgery. *Otolaryngol Pol* 2005;59:887–92 [Polish].
- [36] Kadota H, Fukushima J, Kamizono K, et al. A minimally invasive method to prevent postlaryngectomy major pharyngocutaneous fistula using infrahyoid myofascial flap. *J Plast Reconstr Aesthet Surg*. 2013 July;66(7):906–11.