

New surgical technique for endoscopic management of anterior glottic web

A. Deganello*, O. Gallo*, G. Gitti*, E. de'Campora* and H. Mahieu**

*Department of Otolaryngology and Head and Neck Surgery, University of Florence, Italy; **Department of Otolaryngology, Meander Medical Center in Amersfoort, The Netherlands

Key-words. Glottic web; laryngeal stenosis; laryngeal synechia; complication; CO₂ laser

Abstract. *New surgical technique for endoscopic management of anterior glottic web. Objectives:* In this study we report a new endoscopic technique for the management of anterior glottic web (AGW). Previously, various procedures with endoscopic or open surgical approaches have been described for the treatment of symptomatic AGW. We present an original, highly effective endoscopic technique that seems to have several advantages over traditional approaches.

Methods: We used this novel technique in a preliminary series of four patients. Using a CO₂ laser, a curvilinear mucosal flap based on the web is elevated from the superior surface of one vocal chord. The web is divided, and the flap is sutured at the inferior surface of the opposite vocal chord, ensuring that no raw surfaces will be left exposed on this side of the larynx. We accurately describe the technique, displaying diagrams of the surgical steps.

Results: In three cases, a restoration of the laryngeal airway, with complete resolution of the AGW, was achieved. A limited residual web persisted close to the anterior commissure in the fourth patient.

Conclusions: The new endoscopic technique utilized in our preliminary series of patients is a simple, repeatable, and effective surgical procedure for managing AGW.

Introduction

Anterior glottic web (AGW) is the formation of a bridge of scar tissue covered by epithelium between the free edges of true vocal cords, involving the anterior commissure. AGW can be congenital or acquired. The incidence of congenital AGW is approximately 5% of all laryngeal congenital malformations.¹ The congenital condition is due to incomplete recanalization of the laryngo-tracheal lumen during the third month of gestation, resulting in different degrees of laryngeal stenosis.¹ Acquired AGW is often iatrogenic secondary to laryngeal surgery,² radiation therapy, or prolonged intubation³; other described causes are laryngeal trauma and inflammatory diseases.

A surgical procedure involving both vocal cords creates a raw wound surface at the level of the

free edges. During the early post-operative course, fibrin deposition in both sides can meet at the midline, with subsequent formation of a midline scar that will be covered by a mucosal layer migrating from lateral to medial. Therefore, to prevent AGW formation, simultaneous bilateral de-epithelisation of the vocal cords should be avoided, especially if the anterior commissure is comprised. Clinical manifestations of AGW depend upon the extension of the web, beginning with slight dysphonia for very limited webs confined to the anterior commissure, progressing to different degrees of dysphonia associated with dyspnoea for webs reducing the laryngeal airway by more than 50%.

Various procedures with endoscopic or open surgical approaches have been described for the treatment of symptomatic AGW.³⁻⁷ These have been varied

and ingenious, ranging from the simple dilation and intubation of the 1800s, to the galvanocautery and endoscopic scar incision of the early twentieth century.⁴ By the 1930s and 1940s, the concept of laryngofissure with scar excision was the most common approach to laryngeal stenosis.⁴ In the 1950s, treatment of AGW involving placement of keel prostheses with laryngofissure was first described.⁴

The common goal of these AGW procedures is restoration of airway patency and improvement of voice quality, always considering the tendency of recurrence.

Here we present an original endoscopic technique that is highly effective, and seems to have several advantages over previously-described traditional approaches. We report a preliminary series of four cases, display surgical diagrams, and detail the surgical steps involved.

Materials and methods

Patients

We performed our technique on 4 patients in two institutions: the Department of Otolaryngology and Head and Neck Surgery of the University of Florence, Italy, and the Otolaryngology Department of the Meander Medical Center in Amersfoort, The Netherlands. Of the four patients, three patients were male, with mean patient age 58 years. One patient developed AGW as a result of elective radiation therapy for a T1b glottic laryngeal carcinoma, three patients developed the web as a result of several endoscopic decortications due to dysplasia, carcinoma *in situ*, or microinvasive squamous cell carcinoma. One of the patients suffered from severe diabetes mellitus, and possessed a medical history positive for heart attack. The same patient also underwent several unsuccessful endoscopic attempts to treat the AGW in other institutions. The posterior limit of the AGW was located halfway along the true vocal cords in two cases. In the remaining two cases, it extended to the posterior third, causing moderate dyspnoea. None of the patients had a tracheotomy. Videolaryngostroboscopy without anaesthesia or with minor topical anaesthesia, and direct laryngoscopy under general anaesthesia with telescopes at 0°-30°-70° and 120°, were performed in all cases to assess the extension of the web, and to rule out a subglottic involvement. In every case only one endoscopic procedure was performed.

Surgical technique

The surgical procedure is performed as follows. Under general

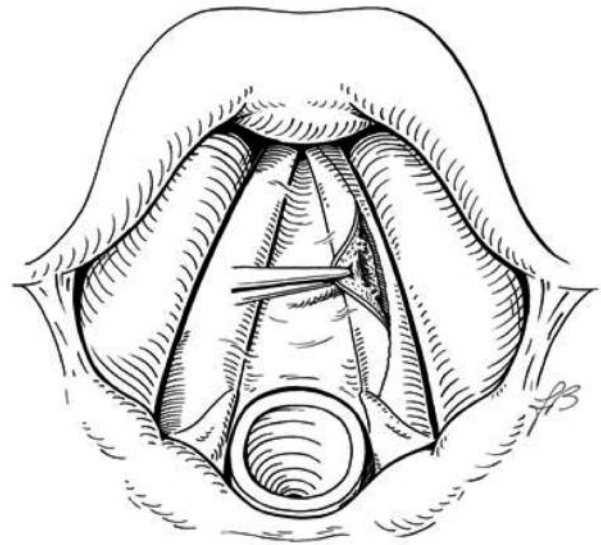


Figure 1

With a CO₂ laser, the upper surface of one true vocal cord is incised, respecting the underlying vocal ligament. The surface is elevated toward the midline.

anaesthesia, the glottic region is adequately exposed by means of a laryngoscope. A curvilinear incision at the superior surface of one true vocal cord is made with a carbon dioxide (CO₂) laser on a super-pulse repeat setting (0.1 sec on; 0.1 sec off) at 2 watts power (Figure 1). The incision cuts through the mucosal epithelium, respecting the underlying vocal ligament. The curvilinear shape starts from the anterior commissure and terminates at the end of the web, with lateral convexity. This cut thus results in a mucosal "apron" flap based on the web.

The mucosal flap is grabbed with grasping forceps and, using the CO₂ laser, the flap is elevated towards the midline (respecting the ligament as in a type I cordec-tomy) until the medial aspect of the AGW is reached and the full thickness is divided. At this point, one vocal cord is completely freed, while the opposite vocal

cord will have the web and the mucosal flap of the contralateral vocal cord still attached to its free edge. This mucosal flap has a raw surface facing downward and a smooth epithelialised surface facing upward. The flap is then sutured (rotated down) to the surface under the vocal cord, with the free edge attached to the inferior surface of the vocal cord. Thus no raw surfaces will be left exposed on this side of the larynx (Figure 2).

For right-handed surgeons it is convenient to incise and elevate the flap from the right vocal chord, placing the suture under the left vocal cord (as shown in Figures 1 and 2). Usually two or three surgical stitches are needed, the first stitch close to the anterior commissure, the second one corresponding to the midpoint of the AGW, and a third stitch fixing the posterior edge of the flap. We use absorbable PDS 7/0 wire, placed

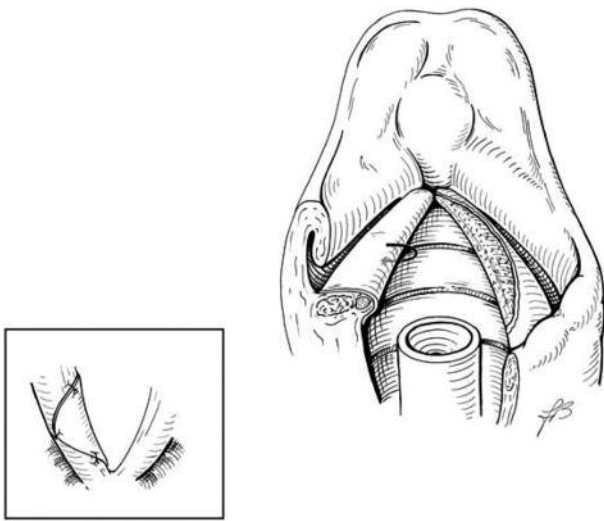


Figure 2

The mucosal flap is rotated downward, and its free edge is sutured to the inferior surface of the vocal cord, leaving no raw surfaces exposed. Usually two or three surgical stitches are required. Inset: a view from the trachea of the anterior commissure, with the flap sutured to the left vocal cord.

with a laryngoscopic needle holder (Storz®, Karl Storz Endoskope, Tuttlingen, Germany).

At the end of the procedure, the raw surface of the decorticated vocal cord will face an opposite true vocal cord covered by normal epithelium as a result of the rotated mucosal flap, preventing the development of further stenosis. Usually the mucosal flap sutured to the vocal cord undergoes complete atrophy within 6-8 weeks.

Results

In three of our four patients, a restoration of the laryngeal airway with complete AGW resolution was achieved. The fourth (diabetic) patient presented an AGW with posterior extension as a result of multiple decortications; a minimal residual AGW remained after surgery, but was limited to the most anterior part of the glottis

near the anterior commissure (Figure 3). This patient denied further surgery, as he experienced no further dyspnoea and his voice improvement was excellent.

Discussion

The development of endoscopic laryngeal surgery, together with the improvement in microlaryngeal instrumentation and the advent of the CO₂ laser, has per-

mitted many laryngeal stenoses, previously treated through open techniques, to be managed endoscopically. The CO₂ laser permits minimal deep tissue injury and can be successfully used for the ablation of AGW.^{3,5} Once the AGW is divided, action must be taken to prevent web recurrence; several pertinent techniques have been described.^{3,5-8} In recent years, mitomycin C has gained popularity as a topical treatment to prevent scar formation in the larynx following AGW division.⁸ However, mitomycin C is a potential carcinogen, and a case of laryngeal carcinoma which may have been induced by topical mitomycin C application to a glottic web has been reported in the literature.⁹ Endoscopic placement of silicon stents after AGW division aims to prevent web recurrence while the re-epithelisation of the vocal cords occurs. However, several problems may arise with this technique; the stent can dislocate, its external fixation requires larynx perforation with possible infections, its permanence can irritate the surrounding mucosa with subsequent formation of granulomas, and dysphonia is severe while the stent is in place.^{3,6,7}

To the best of our knowledge, the application of a contralateral

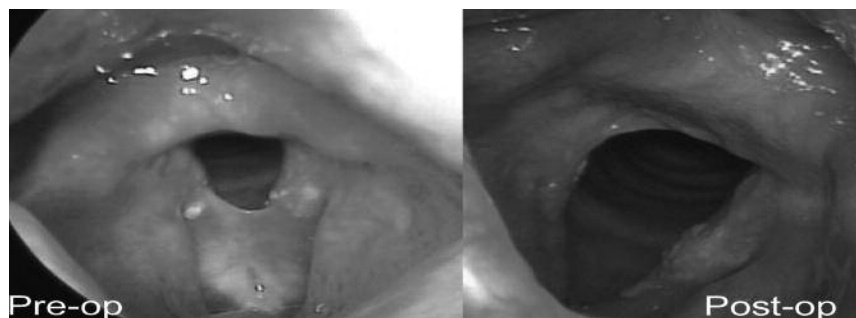


Figure 3

Pre-operative and post-operative view of the patient with partial web persistence in the most anterior part of the commissure.

mucosal flap for AGW management was never been published, although one case treated with a similar but more complicate technique has been reported.⁵ In another recent report, 8 patients (5 children and 3 adults) were successfully treated with midline AGW division and suture of the edges.⁶ In our technique, the flap only functions to leave no raw surfaces in juxtaposition. The complete atrophy of the flap, usually occurring within 6-8 weeks, guarantees the healing of the contralateral vocal cord and permits restoration of the normal anatomical structure. The crucial step is the anchorage of the flap; due to the narrow space, the most anterior stitch can be difficult to place. We produced a partial result in one case, related to early detachment of the anterior knot during the post-operative period that led to a limited persistence of the web at this level.

Conclusions

In the present study, we have reported a novel technique to

manage AGW. Advantages of this new technique are related to the ease of the procedure itself. Additional advantages include prompt airway restoration, no voice restrictions in the post-operative period, no perforation of the larynx, no need of endoscopic toilette in the post-operative period, repeatability in case of recurrence, and effectiveness in a single procedure. In order to minimise the difficulty of placing the anterior stitch, we are currently working on a slight modification of this technique.

References

- Holinger PH, Brown WT. Congenital webs, cysts, laryngoceles and other anomalies of the larynx. *Ann Otol Rhinol Laryngol.* 1967;76(4):744-752.
- Mesolella M, Motta G, Laguardia M, Galli V. Papillomatosis of the larynx: treatment with CO2 laser. *B-ENT.* 2006;2(2):51-54.
- Monnier P, George M, Monod ML, Lang F. The role of the CO2 laser in the management of laryngotracheal stenosis: a survey of 100 cases. *Eur Arch Otorhinolaryngol.* 2005;262(8):602-608.
- McIlwain JC. A historical overview of the aetiology and treatment of laryngeal stenosis. *Arch Otorhinolaryngol.* 1989;246(5):336-340.
- Schweinfurth J. Single-stage, stentless endoscopic repair of anterior glottic webs. *Laryngoscope.* 2002; 112(5):933-935.
- Xu W, Han D, Hu H, Chen X, Li H, Hou L, Zhang L. Endoscopic mucosal suturing of vocal fold with placement of stent for the treatment of glottic stenoses. *Head Neck.* 2009;31(6):732-737.
- Lichtenberger G, Toohill RJ. New keel fixing technique for endoscopic repair of anterior commissure webs. *Laryngoscope.* 1994;104(6):771-774.
- Roh JL, Yoon YH. Prevention of anterior glottic stenosis after bilateral vocal fold stripping with mitomycin C. *Arch Otolaryngol Head Neck Surg.* 2005;131(8):690-695.
- Agrawal N, Morrison GA. Laryngeal cancer after topical mitomycin C application. *J Laryngol Otol.* 2006; 120(12):1075-1076.

Alberto Deganello
Department of Otolaryngology and Head
and Neck Surgery
V.le Morgagni 85
AOU-Careggi
50139 Firenze, Italy
Tel.: +39 3203075573
E-mail: adeganello@hotmail.com