

CASE REPORT

Congenital Nasal Pyriform Aperture Stenosis as a Rare Manifestation of Trisome 8 Mosaicism: A Case Report

NORHAFIZAH S^{1,2}, SHIFA Z¹, SITTI FARHANA J¹, MARINA MB²

¹Department of Otorhinolaryngology, Hospital Sungai Buloh, Jalan Hospital, 47000 Sungai Buloh, Selangor Darul Ehsan.

²Department of Otorhinolaryngology-Head Neck Surgery, Faculty of Medicine, Universiti Kebangsaan Malaysia Medical Centre, Jalan Yaacob Latif, Bandar Tun Razak, 56000 Cheras, Kuala Lumpur,

ABSTRAK

Stenosis bukaan piriform nasal kongenital (CNPAS) adalah penyebab yang amat jarang ditemui untuk kesempitan saluran udara hidung. Secara klinikal, ia menyerupai atresia choanal pada bayi neonate. Ia perlu dibezakan kerana pengurusan kedua-dua penyakit ini adalah berbeza. Bukaan piriform hidung merupakan bahagian yang paling hadapan dan paling sempit di saluran udara hidung. Oleh itu, sekiranya berlaku sedikit kesempitan di kawasan rentas hidung, ia akan menyebabkan hidung tersumbat. CNPAS biasanya dikaitkan dengan kecacatan pembangunan garis tengah seperti kecacatan holoprosensefali atau pituitari. Kami membentangkan kes yang pertama dilaporkan dalam kesusasteraan saintifik bahasa Inggeris, CNPAS yang berkaitan dengan Trisomi 8 Mosaicism (T8M).

Kata kunci: choanal atresia, kromosom 8 mozek trisomy, holoprosensefali, mosaicism, halangan hidung

ABSTRACT

Congenital Nasal Pyriform Aperture Stenosis (CNPAS) is an extremely rare cause of nasal airway obstruction. Clinically, it mimics choanal atresia in neonate. It needs to be differentiated because management differs from each. Pyriform aperture is located at the most anterior part of the nose and is always the narrowest region of the nasal cavity. Therefore, nasal obstruction can easily occur if there is slight decrease in its cross sectional area. CNPAS rarely presents alone. Usually, it arises together with a midline developmental defect such as holoprosencephaly or pituitary defect. We present the first ever reported case of CNPAS, in association with Trisomy 8 Mosaicism (T8M).

Address for correspondence and reprint requests: Marina Mat Baki, Department of Otorhinolaryngology-Head Neck Surgery, Faculty of Medicine, Universiti Kebangsaan Malaysia Medical Centre, Jalan Yaacob Latif, Bandar Tun Razak, 56000 Cheras, Kuala Lumpur, Malaysia. Tel: +603-91456045 Fax: +603-91456675 E-mail: marinamatbaki@ppukm.ukm.edu.my

Keywords: choanal atresia, chromosome 8 mosaic trisomy, holoprosencephaly, mosaicism, nasal obstruction

INTRODUCTION

Neonatal nasal obstruction is a rare cause of Congenital Nasal Pyriform Aperture Stenosis (CNPAS) in newborn as compared to posterior nasal obstruction, seen in choanal stenosis or atresia. Due to the narrowing at the anterior bony portion of nasal cavity (Rozner 1964), an infant usually presents with respiratory distress, cyclic cyanosis, episodic apnoeas, and feeding difficulties.

Confirmation of the diagnosis can be made by using Computed Tomography (CT). In order to assess the level of obstruction, thin axial section scans through the midfacial region is required. CT must be taken from the level of palate to the orbital roof. In term baby, a pyriform aperture width of less than 8mm is considered diagnostic of CNPAS (Belden et al. 1999). CT is also useful to differentiate between CNPAS and choanal atresia as both may present with similar signs and symptoms.

The pathogenesis of CNPAS is unknown. Various theories existed regarding its relationship and degree of association with craniofacial anomalies. There are isolated CNPAS cases reported as well as cases with association to chromosomal abnormalities. Hypothalamo-Pituitary Axis abnormalities and Solitary Median Maxillary Central Incisor (SMMCI) are very common (40% and 55%, respectively), followed by cardiac, vertebral and other brain anomalies

(17.5, 12.5 and 30%) (Guilmin-Crepon et al. 2006).

Here, we report the first case of CNPAS in a baby with Trisomy 8 Mosaicism chromosomal abnormality.

CASE REPORT

A full term baby boy, with birth weight of 2.23 kg, length 49 cm and head circumference 29.5 cm was born through emergency caesarean section for failed induction of labour. He was the second child in the family. Antenatally, his mother had gestational diabetes mellitus on diet control. The neonate was cyanosed with poor breathing effort and the appearance, pulse, grimace, activity, respiration (APGAR) score of 6 at 1 min, followed by 8 at 5 mins. The child was dependent on oxygen and was put on headbox oxygen 5L/min after birth till day 10 of life and was tapered down to nasal prong oxygen 2L/min. He was referred to the Otorhinolaryngology Department at 10 hrs of life for nasal obstruction.

Clinically, the infant had dysmorphic features such as small chin, widened forehead, low set ears and left hand polysyndactily (Figure 1). There was no cleft lip or palate. The nasal vestibular openings were narrowed and there was marked decrease in mist formation on spatula test bilaterally suggesting obstruction. Nasogastric tube size 6F and 2.7 mm paediatric flexible nasopharyngolaryngoscopy were

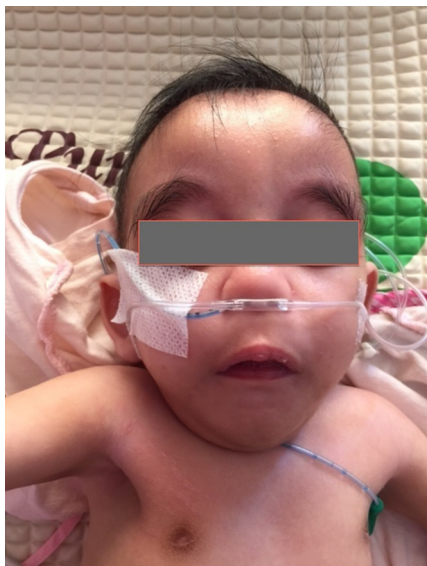

Figure 1: Figure shows clinical appearance of CNPAS such as small chin, widened forehead, low set ears

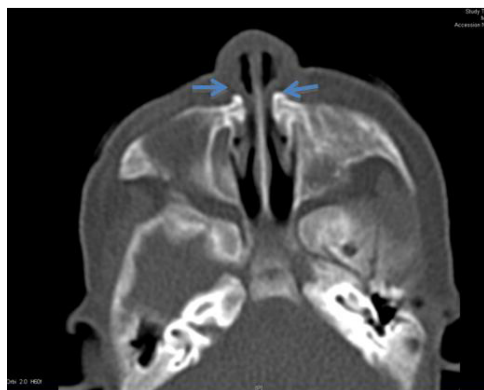


Figure 2: Figure shows an axial plane CT image at the level of the inferior meatus showing narrowing of the piriform aperture (width 5.4 mm) at the age of 1 months.

introduced bilaterally but both were unable to pass through the nasal cavity.

Other congenital abnormalities seen in this infant were coarctation of aorta with large patent ductus arteriosus, mild to moderate hypoplasia of ventricles, bilateral undescended testes and bilateral multicystic dysplastic kidneys.

Chromosomal studies confirmed Trisomy 8 Mosaicism. The analysis revealed 1 chromosome 8 showed an additional of unknown origin at 8p23.3. This abnormality imports monosomy for the region 8p23.3->8pter and trisomy for the additional chromosome material.

The CT paranasal sinuses showed inward bowing of bilateral maxillary spines and bony overgrowth of maxillary nasal process causing narrowing of the piriform aperture with soft tissue obscuring the piriform aperture. Piriform aperture measured 5.4 mm at the level of inferior meatus (Figure 2). Vomer was normal and the distance of lateral wall of nasal cavity to vomer was symmetrical at 0.5 cm bilaterally.

The infant was treated conservatively. Nasal patency was improved with the use of saline solutions. He improved symptomatically and was discharged at 2 months of life. Clinically child was well with no cyanosis or respiratory distress. A nasogastric tube size 6 was able to pass through bilateral nares upon review.

DISCUSSION

Trisomy 8 mosaicism (T8M) also known as Warkany syndrome is an extremely rare entity, which involves chromosomal abnormality where there is an extra copy of chromosome 8. The incidence was estimated to be about 1:25000 to 1:50000 births (Wisniewska et al. 2002). It can occur with or without mosaicism. T8M is a human chromosomal disorder caused by three copies (trisomy) of

chromosome 8. Complete trisomy 8 is usually associated with severe defect on the developing foetus and it causes 0.8% cases of miscarriages. However, individuals with T8M has variable phenotype ranges and would likely to survive into childhood and adulthood. The phenotype includes abnormal facies, eye anomalies, camptodactyly, reduced joint mobility, deep plantar, palmar creases, various vertebral and costal anomalies (Agrawal & Agrawal 2011).

To date, and to the best of our knowledge, CNPAS has not been described in Trisomy 8 Mosaicism. A midline developmental defect like holoprosencephaly which includes facial cleft is the most common cited association. However, in this case, the infant had no cleft lip or cleft palate. The least severe form of holoprosencephaly is single central maxillary incisor (SCMI). Arlis and Ward reported four out of six patients with CNPAS presented with SCMI (Arlis & Ward 1992). Neither holoprosencephaly nor single central maxillary incisor is a common feature of Trisomy 8 Mosaicism.

Neonatal nasal obstruction is a potentially life threatening condition as neonates are obligate nasal breathers. It may present with severe birth asphyxia. The differential diagnosis includes traumatic lesions, cysts, meningoencephalocele and encephalocele, tumours and choanal atresia. The latter can be a part of CHARGE syndrome (coloboma of the eye, heart defect, atresia of the nasal choanae, retardation of growth, genital abnormalities, ear abnormalities and deafness) (Al Abri et al. 2008).

CNPAS is a rare cause of nasal obstruction. The etiology and its pathogenesis remains unknown. Nasal pyriform aperture is made up of nasal and maxillary bones. Overgrowth of maxillary nasal process during maxillary ossification causes narrowing of the nasal aperture (Al Abri et al. 2008). Axial CT scan of the nose and paranasal sinus can assess the extent of the obstruction. Confirmation of diagnosis is made when the width of the whole pyriform aperture is less than 8mm and each pyriform aperture is less than 3mm (Arlis & Ward 1992). Treatment for nasal pyriform aperture in general is either medical or surgical, depending on the severity of the symptoms. Eighty percent of the children with this problem (n=12) were treated surgically in the first year of life (Losken et al. 2002). In this case, the infant was treated conservatively and upon review at two months of age, he had no respiratory distress and was tolerating orally well.

CONCLUSION

This was the case of CNPAS in a baby with Trisomy 8 Mosaicism chromosomal abnormality. The clinical features and treatment discussed in this case may be beneficial in future clinical practice.

REFERENCES

- Agrawal, A., Agrawal, R. 2011. Warkany syndrome: a rare case report. *Case Rep Pediatr* 2011: 437101.
- Al Abri, R., Javad, H., Kumar, S., Bharga, D., Koul, R., Al Futaisi, A., Sankla, D. 2008. Congenital nasal pyriform aperture stenosis: first Case report in oman. *Oman Med J* 23(3): 192-4.
- Arlis, H., Ward, R.F. 1992. Congenital nasal pyriform aperture stenosis: isolated abnormality vs

- developmental field defect. *Arch Otolaryngol Head Neck Surg* **118**(9): 989-991.
- Belden, C.J., Mancuso, A.A., Schmalfluss, I.M. 1999. CT features of congenital nasal pyriform aperture stenosis: initial experience *Radiology* **213**(2): 495-501.
- Guilmin-Crépon, S., Garel, C., Baumann, C., Brémond-Gignac, D., Bailleul-Forestier, I., Magnier, S., Castanet, M., Czernichow, P., Van Den Abbeele, T., Léger, J. 2006. High proportion of pituitary abnormalities and other congenital defects in children with congenital nasal pyriform aperture stenosis. *Pediatr Res* **60**(4): 478-84.
- Losken, A., Burstein, F.D., Williams, J.K., Turk, A.E. 2002. Congenital nasal pyriform aperture stenosis: diagnosis and treatment. *Plast Reconstr Surg* **109**(5): 1506-11.
- Rozner, L. 1964. Nasal obstruction due to restriction of the bony nasal inlet. *Br J Plast Surg* **17**: 287-96.
- Wi niewska, M., Mazurek, M. 2002. Trisomy 8 mosaicism syndrome. *J Appl Genet* **43**(1): 115-8.