

CASE REPORT

Prolong Placement of Tracheostomy Tube Causing Unusual Complication

MOHAMAD NORKAHFI R, MARINA MB, MAWADDAH A,
ABDULLAH SANI M

Department of Otorhinolaryngology-Head Neck Surgery, Faculty of Medicine, Universiti Kebangsaan Malaysia Medical Centre, Jalan Yaacob Latif, Bandar Tun Razak, 56000 Cheras, Kuala Lumpur, Malaysia.

ABSTRAK

Trakeostomi boleh dikaitkan dengan pelbagai komplikasi. Di sini, kami membentangkan kes berkaitan penjagaan tiub trakeostomi yang tidak sempurna di mana seorang pesakit telah menggunakan tiub trakeostomi melebihi jangkamasa tanpa menukarnya menyebabkan komplikasi tisu parut kulit yang besar pada trakeostoma dan tisu parut di dalam trakea yang menyebabkan kedudukan tiub trakeostomi teralih dari kedudukan asal seterusnya mengakibatkan halangan pada salur pernafasan. Kes ini menggambarkan bahawa kesedaran dan pengetahuan berkaitan penjagaan tiub trakeostomi yang betul di kalangan kakitangan perubatan adalah sangat penting bagi mengelakkan sebarang salah urus yang boleh mengakibatkan komplikasi yang mengancam nyawa kepada pesakit.

Kata kunci: salur pernafasan, tisu parut kulit, tisu parut trakea, trakeostomi

ABSTRACT

Tracheostomy can be associated with numerous complications. Here, we present a case of large hypertrophic skin of tracheostoma with tracheal granulation tissue causing malpositioning of tracheostomy tube and airway obstruction, secondary to prolong placement of a cuff tracheostomy tube due to improper tracheostomy care. This case illustrates that awareness and knowledge of proper tracheostomy tube care among medical personnel are very important to avoid any mismanagement that can cause life-threatening complications.

Keywords: airway obstruction, granulation tissue, hypertrophic, tracheostomy

Address for correspondence and reprint requests: Marina Mat Baki, Department of Otorhinolaryngology-Head Neck Surgery, Faculty of Medicine, Universiti Kebangsaan Malaysia Medical Centre, Jalan Yaacob Latif, Bandar Tun Razak, 56000 Cheras, Kuala Lumpur, Malaysia. Tel: +603-91456046 Fax: +603-91456675 E-mail: marinamatbaki@ppukm.ukm.edu.my

INTRODUCTION

Tracheostomy is associated with numerous complications, some of which continue to be relevant after placement. The most frequent late complication is the development of granulation tissue that may cause airway occlusion or result in airway stenosis (Epstein 2005). Lack of awareness and knowledge of tracheostomy care among medical staff may cause harm to the patient and lead to serious life threatening complications. Here, we present a case of large hypertrophic skin of tracheostoma with tracheal granulation tissue causing malpositioning of tracheostomy tube (TT) and airway obstruction, secondary to prolong placement of a cuff TT without change of more than four yrs due to improper tracheostomy care.

CASE REPORT

A 32-year-old male with poor socioeconomic status and family support sustained an open laryngeal injury following motor-vehicle accident in 2002 requiring tracheostomy. Since then, he was on non-cuff TT due to laryngeal stenosis and was under Otorhinolaryngology (ORL) team of hospital nearby follow-up. He was successfully decannulated about five yrs later.

In 2011, about four yrs after decannulation, he presented again to another hospital with dyspnoea and reduced effort tolerance. A revision of tracheostomy was performed and subsequently he was sent back home with a non-cuff TT and given follow-up under ORL team.

Unfortunately, in 2012, he was involved in another motor-vehicle accident where he sustained injury to the left hand requiring a surgical procedure under general anaesthesia. During the procedure, his TT was changed to a cuff type for the purpose of mechanical ventilation. A few days after the procedure, he was sent home with the cuff TT size 6 without prior consultation with ORL team.

Since then, he had been using the same cuff TT without ever change it for about four yrs until recently he developed dyspnoea with noisy breathing.

Physical examination revealed large hypertrophic skin over peristomal area on the anterior neck causing the TT protruded anteriorly (Figure 1a & 1b). Flexible nasopharyngolaryngoscopy showed distorted supraglottis and glottic stenosis with vocal cords at different vertical level (Figure 2). Flexible scope via tracheostomy tube at the stoma revealed presence of granulation tissue at the distal tip of TT obstructing 80% of the airway. The TT also adhered to the peristomal hypertrophic skin and was unable to be removed.

He was subsequently referred to our centre for further management. He underwent direct laryngoscopy and excision of peristomal hypertrophic scar. At the beginning of the procedure, TT was successfully mobilized, removed and changed to microlaryngeal tube for ventilation, following peristomal infiltration with marcaine adrenaline. The TT looked very dirty and mouldy (Figure 1c). The hypertrophic skin was excised by employing an elliptical

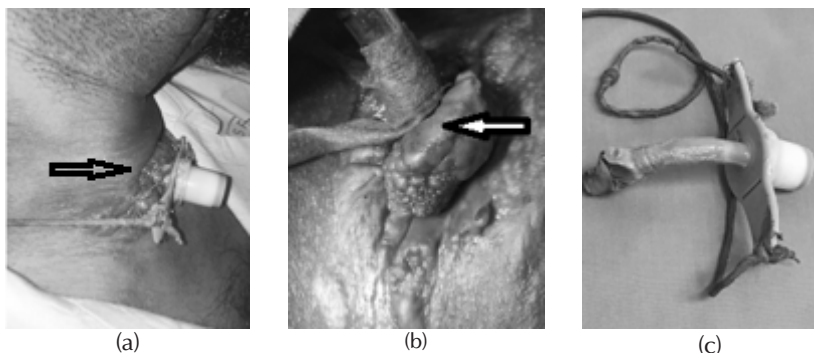


Figure 1: The figure shows a) the patient's tracheostomy tube protruded anteriorly from stoma due to presence of hypertrophic scar (arrow); b) close up view of the hypertrophic skin after the tracheostomy tube was changed to a microlaryngeal tube size 6 (white arrow); and c) patient's cuff tracheostomy tube that was dirty and mouldy

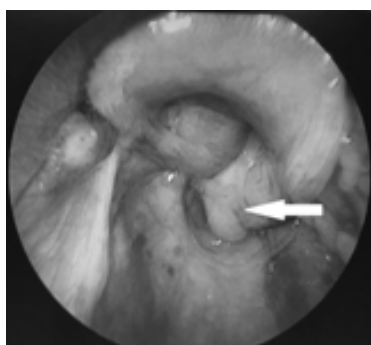

Figure 2: The figure shows a direct laryngoscopy view depicting distorted laryngeal structures with right arytenoid anteriorly displaced (white arrow)

incision around the lesion. Direct laryngoscopy revealed massive suprastomal granulation. At the end of the procedure, a new cuff TT tube was inserted that managed to bypass the distal granulation tissue.

He was then referred to the hospital social welfare team to assist him in term of financial support, hospital bill settlement and payment for new double lumen non-cuff TT. After few days of observation, TT was changed to new double lumen non-cuff type size 7. Subsequently, he was discharged

home well from ward with the new TT and a date of follow-up was set for him.

DISCUSSION

A number of mechanisms may cause late complications after tracheostomy (Stauffer et al. 1981). Granulation tissue is a common consequence of tracheostomy, occurring in 10-80% of cases, and it typically appears as pink and fleshy protuberant tissue produced by inflammation (Yaremchuk 2003). The common sites of occurrence are at suprastomal, infrastomal in the area of the cuff and the distal tip of TT.

Risk factors associated with granulation tissue formation include improper cannula size fitting, mechanical irritation of surrounding tissue caused by excessive tube movement, infection occurred at surrounding tracheostoma area, prolonged placement of TT, and anterior tracheal cartilage excision incommensurate with skin incision during the creation of the tracheostoma (Sue & Susanto 2003).

The site where the TT balloon cuff placed within the tracheal lumen is the common site of granulation tissue formation. When the cuff pressure exceeds the tracheal wall capillaries perfusion pressure, it may induce ischemic injury. Prolonged ischemia may subsequently cause mucosal ulceration, chondritis, and cartilaginous necrosis, leading to the formation of granulation tissue. The insults to the mucosa may be further aggravated by shearing forces from the tube or cuff of the TT (Epstein 2005). Other areas in which granulation tissue prone to occur is near the distal tip of the TT that commonly caused by malpositioning of the TT. The tube malposition may increase the contact point between the tip and surrounding tracheal wall mucosa, predisposing it to granulation tissue formation. In obese patients with thick soft tissue in the anterior neck, the posterior tracheal wall mucosa is commonly affected.

In the present case, the patient was not obese but the prolonged placement, formation of anterior neck hypertrophic skin and a single use of cuff TT without changing for more than four yrs in the patient, predisposed him to tracheal mucosal irritation and infection which lead to mucosal ulceration, inflammation and granulation tissue formation. In normal practice, the tube has to be changed to a non-cuff preferably a double lumen before allowing the patient home.

Prevention of stomal infection is important as it may promote granulation tissue (Sasaki et al. 1979). Fewer complications due to granulation tissue were reported when TTs were

changed twice weekly (Yaremchuk 2003). However, based on a Swedish study of long-term material wear of 3 different types of TTs made of silicone (Bivona), polyvinyl chloride (Shiley), and polyurethane (Tracoe), routine TT change every three months is recommended (Backman et al. 2009). They found biofilm formation on the TT, which can affect the structural integrity of the tube and cause damage. Substantial surface degradation was observed on TTs kept in place for three or six months, but no significant differences were established after three or six months of exposure between the various materials (Backman et al. 2009).

CONCLUSION

We learnt that suboptimal management for a patient on TT may lead to life threatening airway complications due to formation of peristomal hypertrophic skin causing malpositioning of TT and tracheal granulation tissue. Therefore, it is imperative to highlight this case to create awareness among medical personnel the importance of having basic knowledge on tracheostomy care. We recommend that the trained healthcare professionals in particular the ORL team must be engaged in managing patients with TT to ensure the long-term care.

REFERENCES

- Backman, S., Bjorling, G., Johansson U.B., Lysdahl, M., Markstrom, A., Schedin, U., Aune, R.E., Frostell, C., Karlsson, S. 2009. Material wear of polymeric tracheostomy tubes: a six-month study. *Laryngoscope* **119**(4): 657-64.
- Epstein, S. K. 2005. Late complications of tracheostomy. *Respir Care* **50**(4): 542-9.

- Sasaki, C.T., Horiuchi, M., Koss, N. 1979. Tracheostomy related subglottic stenosis: Bacteriologic pathogenesis. *Laryngoscope* **89**(6 Pt 1): 857-65.
- Sue, R.D., Susanto, I. 2003. Long term complications of artificial airways. *Clin Chest Med* **24**(3): 457-71.
- Stauffer, J.L., Olson, D.E., Petty, T.L. 1981. Complications and consequences of endotracheal intubation and tracheostomy. A prospective study of 150 critically ill adult patients. *Am J Med* **70**(1): 65-76.
- Yaremchuk, K. 2003. Regular tracheostomy tube changes to prevent formation of granulation tissue. *Laryngoscope* **113**(1): 1-10.