

## ORIGINAL ARTICLE

# Effects of *Eurycoma Longifolia* on Fracture Healing of Androgen-Deficient Osteoporosis Model: A Micro Computed Tomograph Analysis

AZRI J<sup>1,4</sup>, NAZRUN AS<sup>1</sup>, SABARUL AM<sup>2</sup>, MOHD FADLI K<sup>3</sup>,  
NORLIZA M<sup>1</sup>

<sup>1</sup>Department of Pharmacology, <sup>2</sup>Department of Orthopaedic and Traumatology, Faculty of Medicine, Universiti Kebangsaan Malaysia Medical Centre, Jalan Yaacob Latif, Bandar Tun Razak, 56000 Cheras, Kuala Lumpur, Malaysia.

<sup>3</sup>School of Dental Sciences, Health Campus, Universiti Sains Malaysia, 16150 Kubang Kerian, Kelantan, Malaysia.

<sup>4</sup>Department of Basic Medical Science, International Islamic University Malaysia, Bandar Indera Mahkota Campus, Jalan Sultan Ahmad Shah, 25200 Kuantan, Pahang, Malaysia.

## ABSTRAK

Tomografi berkomputer mikro (mikro-CT) adalah peralatan yang berguna untuk memantau pemulihan patah tulang pada model osteoporosis. Ia menyediakan imej 3D kalus fraktur yang boleh digunakan untuk mengira parameter tulang secara kuantitatif. Dalam kajian in, mikro-CT telah digunakan untuk menilai pemulihan patah tulang tikus yang diorkidektomi, iaitu model osteoporosis defisien-androgen. Kesan ke atas pemulihan patah tulang oleh *Eurycoma longifolia*, sejenis tumbuhan ubatan dengan aktiviti pro-androgenik, dinilai menggunakan mikro-CT. Tikus dibahagikan kepada empat kumpulan: kawalan orkidektomi (ORX), bedah sham (SHAM), orkidektomi dan disuntik dengan testosteron secara intramuskular seminggu sekali (TEN) dan orkidektomi dan menerima oral gavaj *Eurycoma longifolia* (EL) setiap hari. Jangkamasa rawatan ialah enam minggu. Patah tulang diaruh ke atas tibia kanan kesemua tikus. Mikro-CT telah digunakan untuk mengimbas kalus fraktur yang terdiri daripada 100 potongan aksial di atas dan di bawah aras fraktur. Analisa mikro-CT berjaya mengesan perbezaan signifikan pada pemulihan fraktur kumpulan ORX dan TEN. Bagaimanapun, tiada perubahan mikro-CT yang signifikan dilihat pada pemulihan fraktur kumpulan EL. Kesan EL ke atas pemulihan fraktur tidak dapat dilihat pada model tikus orkidektomi.

**Kata kunci:** androgen, *Eurycoma longifolia*, patah, orkidektomi, osteoporosis

**Address for correspondence and reprint requests:** Ahmad Nazrun Shuid. Department of Pharmacology, Faculty of Medicine, Universiti Kebangsaan Malaysia Medical Centre, Jalan Yaacob Latif, Bandar Tun Razak, 56000 Cheras, Kuala Lumpur, Malaysia. Tel :+603-91459545 Fax : +603-26938205 E-mail: anazrun@yahoo.com.

## ABSTRACT

Micro computed tomography (micro-CT) imaging is a useful tool to monitor fracture healing in osteoporosis model. It creates a 3-D image of the fracture callus which can be analysed to assess bone parameters quantitatively. In this study, micro-CT was used to assess the fracture healing of orchidectomised rats, an androgen-deficient osteoporosis model. The effects of *Eurycoma longifolia*, a medicinal plant with pro-androgenic effects, on fracture healing were assessed. The rats were grouped into orchidectomised-control (ORX), sham-operated (SHAM), orchidectomised and injected with testosterone intramuscularly once weekly (TEN) and orchidectomised and daily oral gavage of *Eurycoma longifolia* (EL). Treatment duration was six weeks following bone fracture. Fracture was induced in the right tibia of all the rats. A total of 100 axial slices above and below fracture line were scanned with a micro-CT. The micro-CT analysis was able to detect significant difference in the fracture healing rate of ORX and TEN groups. The bridging cortices and fraction of mineralized tissue of the bridging cortices of the callous of ORX group was significantly lower than TEN group. No significant micro-CT changes were seen in the fracture healing of the EL group. The effect of EL on fracture healing was not demonstrable in orchidectomised rat model.

Keywords: androgen, *Eurycoma longifolia*, fracture, orchidectomy, osteoporosis

---

## INTRODUCTION

Osteoporosis is defined as a systemic skeletal disease characterised by low bone mass and micro-architectural deterioration of bone tissue (CDC 1993). World Health Organization (WHO) defined osteoporosis based on the bone mineral density measurement by Dual energy X-ray Absorptiometry (DEXA) scan. Osteoporosis occurs when the bone mineral density falls more than 2.5 standard deviations below the standard reference for maximum bone mineral density of young adult female. Osteoporosis occurs more commonly in women, especially after menopause. Nevertheless, hip fractures due to osteoporosis has caused higher mortality rate in males than females (Amin & Felson 2001). Furthermore,

osteoporotic fracture in males was associated with significant morbidity and has huge impact emotionally and financially on their families and the society (Johnell et al. 2001).

There are three phases of fracture healing; the reactive phase, reparative phase and remodeling phase. In the reactive phase, platelets are activated to release products such as transforming growth factor- $\beta$  that triggers inflammation. At the same time, haematoma is formed to seal off the fracture area (Grundnes & Reikeras 1993; Marsh & Li 1999). In the reparative phase, granulation tissue is replaced by fibrocartilage and external callus is formed by intramembranous ossification at the periosteum. Finally, in the remodeling phase, the callus and

vasculature are remodelled to their normal size and shape (Gerstenfeld et al. 2003). Osteoporotic fracture requires special attention as the healing may be impaired or delayed by the osteoporotic condition. In human, fracture healing is assessed clinically based on the range of motion and pain sensation. The fracture callus formed during healing may also be assessed using plain film X-ray. Clinical assessments may not be accurate due to variations in medical judgement, while plain X-ray is only a representative two-dimensional assessment (2D) of the three-dimensional (3D) callus structure.

DEXA is the gold standard imaging in making a diagnosis of osteoporosis (Hamdy et al. 2002; Winzenberg & Jones 2011). DEXA scan works by passing a scanner which emits a dual energy beam of low dose X-rays over an area of skeleton and measuring it with a detector. Several studies had investigated the use of DEXA scan in assessing bone fracture healing. Eyres et al. (1993a) & (1993b) reported that DEXA scan could be used to analyze bone fracture healing from 1 to 2 weeks after distraction osteogenesis. Reiter et al. (1997) and Maffulli et al. (1997) recommended the use bone mineral density (BMD) and bone mineral content (BMC) values derived from DEXA scans to monitor bone fracture healing of femur or tibia. Markel et al. (1990) assessed fracture healing after tibial osteotomies in dogs and found that DEXA had good correlations with torsional properties and calcium content of the osteotomies.

Peripheral quantitative or quantitative computed tomography (pQCT or QCT) is another imaging technique which could be used to assess fracture healing. It provides 3D measurements of the structure and mineralization of the fracture callus, and may provide reliable and non-invasive assessments of fracture healing in humans. QCT was reported to have strong correlations with local material properties, such as indentation stiffness and calcium content during fracture healing in dogs (Markel et al. 1990).

Lately, micro-CT has emerged as the new paradigm technique for measuring bone structure and strength in 3D. In small animal model, micro-CT is more suitable compared to pQCT and QCT as it provides superior resolution for studying bone fracture healing (Duvall et al. 2007; Gabet et al. 2004; Gardner et al. 2006; Geiger et al. 2005; Midura et al. 2005; Schmidhammer et al. 2006; Shefelbine et al. 2005). It provides an accurate insight into the bone mineral density changes and biomechanical properties for the estimation of bone strength and fracture risk (Boyd et al. 2006). Micro-CT imaging is useful in monitoring murine fracture calluses at multiple post-fracture time points and under different experimental conditions that alter fracture healing. It measures parameters such as bone volume, bone volume fraction, and mineral density in the fracture callus to predict the strength of callus formed during fracture healing. Therefore, micro-CT can be used for non-invasive assessments of fracture healing and for identifying biological and biomechanical mechanisms that

lead to impaired or enhanced healing (Morgan et al. 2009).

In the present study, micro-CT was used to assess the osteoporotic fracture healing of orchidectomised rats which were administered synthetic testosterone and testosterone-like herb, known as *Eurycoma longifolia* Jack (EL). Testosterone is a steroid hormone that regulates bone remodelling and maintains bone mineral homeostasis. Testosterone deficiency or hypogonadism is the major cause of osteoporosis in men. Testosterone replacement is the main treatment for androgen-deficiency in men (Bhasin et al. 2010; Nieschlag 2006). It was reported that testosterone therapy improves bone mineral density in men (Nieschlag et al. 2004). However, long-term use of testosterone may increase the risk of prostate cancer (Ellem & Risbridger 2006). Therefore, a suitable alternative for testosterone is required for the treatment of androgen deficiency in men and to promote osteoporotic fracture healing.

EL is a medicinal plant that is found along the slopes of hilly territories in the Malaysian rainforest (Burkill & Hanif 1930). The water decoction of its root is used to enhance libido in men and as anti-aging supplements (Cyranski 2005; Talbott et al. 2013). The herbal product is advertised in the internet and available on-line worldwide. EL has been discovered to contain eurycomanone, eurycomanol, eurycomalactone, and alkaloids that may help to increase the free testosterone level in blood and inhibit sex hormone binding globulin. The pro-androgenic effect of EL was demonstrated in male rat model (Ang

& Cheang 2001). In human, EL was reported to elevate testosterone level and increase semen volume (Tambi & Imran 2010).

In the present study, the effect of testosterone replacement and EL on callous fracture in orchidectomised rat, the androgen-deficiency model was assessed using micro-CT.

## MATERIALS AND METHODS

Forty-eight male Wistar rats weighing between 350 to 450 gms were obtained from the Laboratory Animal Resources Unit, Faculty of Medicine, Universiti Kebangsaan Malaysia (UKM). The rats were randomly assigned into sham-operated group (n=12) and orchidectomised group (n=36). Two weeks following orchidectomy or sham operation, the right tibiae of all the rats were fractured under anesthesia according to Stuermer et al. (2010). Briefly, an incision was made from the medial femur condyle to the middle of the tibia and osteotomy was performed at the metaphysis region using pulsed ultrasound (Piezosurgery®, Mectron Medical Technology, Carasco, Italy). Following osteotomy, a T shaped titanium fixation plate XS (57-05140 Stryker Trauma, Selzach, Switzerland) was placed and fixed with 1.2 mm screws to stabilize the fracture.

The orchidectomised rats were further divided into three groups consisting of orchidectomised-control (ORX), orchidectomised and treated with EL extract (EL), and orchidectomised and treated with testosterone enanthate (TEN). The EL group was treated with daily oral gavages of 15 mg/kg of EL

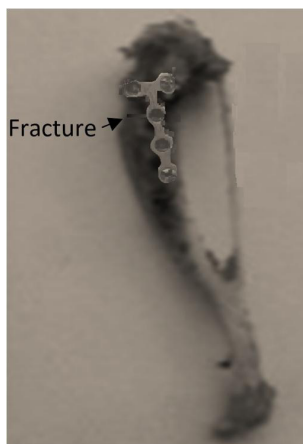


Figure 1: A sample of healed tibia extracted from the rat with T plate in place to fix the fracture.

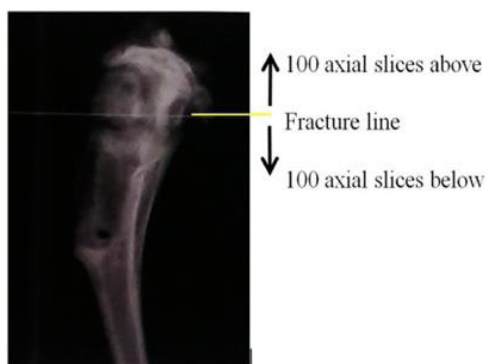


Figure 2: An area which consisted of 100 axial slices above and below fracture line were chosen as the region of interest (ROI) to be scanned for fracture healing assessments.

extract (Phytes Biotek. Sdn. Bhd., Shah Alam, Selangor). The TEN group received an intramuscular injection of testosterone enanthate (Jesalis Pharma, Germany) at the dose of 7 mg/rat once a week (Yarrow et al. 2008). The SHAM and ORX control groups received vehicles (oral gavages of normal saline and intramuscular injection of olive oil) only. Following six weeks of treatment, the rats were euthanized, the fixation

plate was removed and the tibiae were extracted and stored in 10% formalin at room temperature (Figure 1).

The protocol was approved by Universiti Kebangsaan Malaysia (UKM) Animal Ethics Committee (UKMAEC: PP/FAR/2011/NORLIZA/30 NOVEMBER/414-NOVEMBER-2011-JUNE-2012).

### MICRO-CT ASSESSMENT

The degree of fracture healing was measured using *in vitro* micro-CT ( $\mu$ CT 80 scanner, Scanco Medical, Switzerland). The system is equipped with a computer and evaluation software discretion for image analysis. For analysis procedure, the tibiae were placed in a sample holder in a vertical direction with the epiphyseal head facing upward. The source of energy was set to 70 kVp and 114  $\mu$ A and high definition resolution was selected to acquire better and accurate image (Ramli et al. 2012). The filter used was 0.5 mm Al. The voxel size was 10  $\mu$ m and the number of slices included was 201.

The fracture callus area which consisted of 100 axial slices above and below fracture line was chosen as the region of interest (ROI) to be scanned (Figure 2). A set of 2D images in form of vertical slices was produced from the scanning process. From these 2D images, a 3D evaluation could be performed by contouring all the 201 cross-sectional slices resulting from the 2D data set within the ROI. The bridging cortices were then extracted by applying a threshold of 400 mgHA/cm<sup>3</sup>, Gaussian noise filter of 0.8, and support of 2. This segmentation

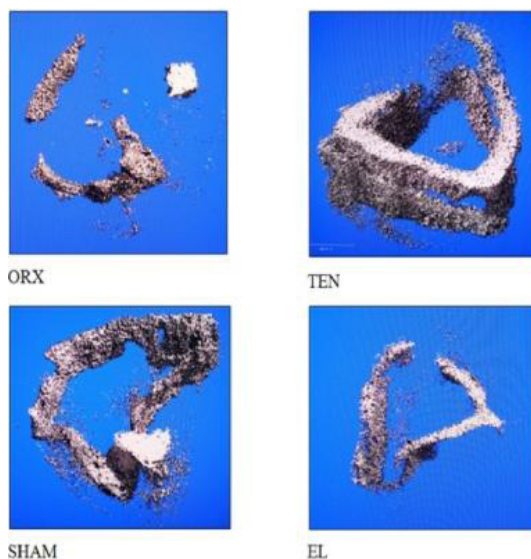


Figure 3: Three dimensions (3D) images of the bridging cortices generated by micro-CT. SHAM: sham-operated, ORX: orchidectomised-control, TEN: orchidectomy + testosterone enanthate treatment 7 mg/rat, EL: orchidectomy + *Eurycoma longifolia* 15 mg/kg.

threshold was utilized in all analyses. Using the Scanco evaluation software, the parameters measured were fraction of mineralized tissue in bridging cortices ( $BV_{bc}/TV_{bc}$ ), bone mineral density of the bridging cortices ( $mBMD_{bc}$ ) and soft callus volume ( $BV_{callus}$ ).

### STATISTICAL ANALYSIS

All the data were expressed as mean standard error mean (SEM). Statistical analysis was conducted using Statistical Package for Social Sciences version 18.0 (SPSS 18.0, Chicago, USA). Kolmogorov Smirnov test was used for normality testing. Normally-distributed data was analysed using parametric one-way ANOVA test followed by Tukey's HSD test while not normally-distributed data was analysed using Kruskal-Wallis, Mann-Whitney U and Wilcoxon Signed Rank tests. The level of significance was taken as  $p < 0.05$ .

### RESULTS

#### THREE DIMENSION (3D) IMAGES OF BRIDGING CORTICES OF THE CALLUS DURING FRACTURE HEALING

Bridging cortices referred to *callus* that *bridge* the fracture gap. When the 3D images of the bridging cortices of the calluses were compared, the ORX group showed the thinnest callus and poorly connected cortices compared to the other groups. The TEN group exhibited the thickest callus and marked connection between the cortices. The SHAM group displayed good connection of the cortices, but the callus thickness was lower than the TEN group. The EL group showed better cortices connection than the ORX group but more inferior compared to the TEN and SHAM groups (Figure 3).

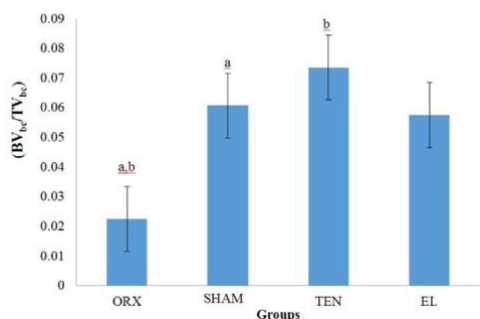


Figure 4: Fraction of mineralized tissue of the bridging cortices (BV<sub>bc</sub>/TV<sub>bc</sub>) after 6 weeks of study. Results were expressed as mean ± standard error mean (SEM). Similar alphabets showed significant difference. SHAM: Sham-operated, ORX: orchidectomised-control, TEN: orchidectomy + testosterone enanthate treatment 7 mg/rat, EL: orchidectomy + *Eurycoma longifolia* treatment 15 mg/kg.

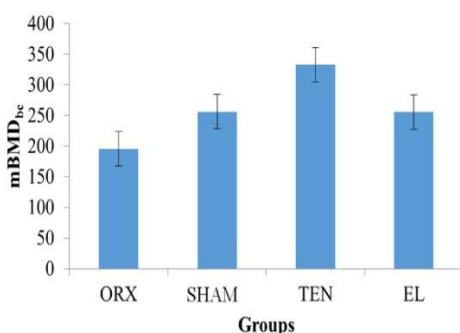


Figure 5: The mBMD<sub>bc</sub> between the groups after 6 weeks of study. Results were expressed as mean ± standard error mean (SEM). SHAM: Sham-operated, ORX: orchidectomised-control, TEN: orchidectomy + testosterone enanthate treatment 7mg/rat, EL: orchidectomy + *Eurycoma longifolia* treatment 15mg/kg.

### FRACTION OF MINERALIZED TISSUE OF THE BRIDGING CORTICES (BV<sub>BC</sub>/TV<sub>BC</sub>)

This parameter measured the ratio of mineralised callus that bridged the fracture gap to the total callus. The BV<sub>bc</sub>/TV<sub>bc</sub> of the ORX group was significantly lower than the SHAM and TEN groups.

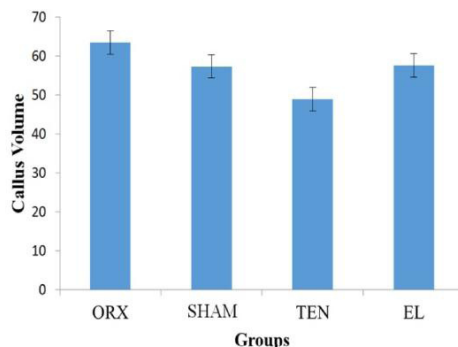


Figure 6: The soft callus volume values of the groups after 6 weeks of study. Results were expressed as mean ± standard error mean (SEM). SHAM: Sham-operated, ORX: orchidectomised-control, TEN: orchidectomy + testosterone enanthate treatment 7mg/rat, EL: orchidectomy + *Eurycoma longifolia* treatment 15mg/kg.

The EL group seemed to have higher BV<sub>bc</sub>/TV<sub>bc</sub> than the ORX group but the difference was not statistically significant (Figure 4).

### MINERALIZED BONE MINERAL DENSITY OF BRIDGING CORTICES (MBMD)<sub>BC</sub>

This parameter measured the bone mineral density of the callus that bridged the fracture gap. There were no significant differences in the mBMD<sub>bc</sub> among the groups (Figure 5).

### SOFT CALLUS VOLUME (BV<sub>CALLUS</sub>)

This parameter measured the volume of unmineralised callus. There was no significant difference in the soft callus volume parameter among the groups (Figure 6).

## DISCUSSION

Micro-CT has proven to be a useful tool for pre-clinical anatomic assessment

of small animal models including cardiovascular system (Jorgensen et al. 1998; Langheinrich et al. 2004; Schambach et al. 2010; Badea et al. 2005), gastrointestinal system (Graham et al. 2008; Martiniova et al. 2010) and skeletal system (Dom et al. 2012; Jiang et al. 2000). Micro-CT can differentiate between bone and soft tissues and provide high resolution images for both cortical and cancellous bones (Jayusman 2015). With these capabilities, micro-CT is becoming the standard tool for bone evaluation including the healing of bone fracture (Liu et al. 2008).

Previous studies on orchidectomised rat model had demonstrated mixed findings on the ability of EL to prevent osteoporosis. Biochemically, EL supplementation was shown to prevent bone calcium loss in orchidectomised rats (Shuid et al. 2011). However, a histomorphometric study found that EL supplementation failed to protect bone against osteoporosis in the same model (Tajul Ariff et al. 2012). A micro-CT study by Ramli et al. (2012) found that EL supplementation at the dose of 90 mg/kg was able to preserve bone volume of orchidectomised rats but not at lower doses.

To date, no study has been carried out to determine the effects of EL on fracture healing of osteoporotic bone. In this study, fracture was induced in tibiae of orchidectomised rats to represent osteoporotic fracture of androgen-deficient osteoporosis model. Fracture was created at the metaphyseal region of the tibia as osteoporotic fracture occurs more frequently at this area in human (Thompson et al. 1995). Tibia

was chosen to be fractured as there is only a thin subcutaneous tissue lining the anterior part of the bone with limited vessels. Therefore, trauma and haemorrhage, which could affect fracture healing, is minimal in the tibia fracture model. The osteoporotic fracture healing with testosterone replacement and EL was assessed using micro-CT.

Micro-CT imaging provides qualitative and quantitative analyses of bone such as bridging cortices fusion and volumetric BMD (Habermann et al. 2010; Nyman et al. 2009). As expected from the micro-CT analysis, the worst fracture healing was observed in the ORX group while the best healing was observed in the TEN group. Qualitatively, the EL group seemed to heal better than ORX group. However, the healing did not record any significant difference for the  $BV_{bc}/TV_{bc}$ ,  $mBMD_{bc}$  and  $BV_{callus}$  parameters measured. The best parameter to assess fracture healing is  $BV_{bc}/TV_{bc}$  as the number of cortices bridged by callus is the most objective measure (Whelan et al. 2002). The EL group has shown the best results in this important parameter compared to other two parameters which indicate some potential in promoting fracture healing.

Higher doses of EL may be required but based on a previous study; the dose used in this study should have been adequate (Shuid et al. 2011). Furthermore, the dose was nearly twice the dose of EL used to increase sperm counts in normal rats (Wahab et al. 2010).

The micro-CT parameters were sensitive enough to show reduced



fracture healing in the ORX group and better healing with the TEN group. The effect of EL was not significantly captured by micro-CT. Orchidectomised rats may not be a suitable model to determine the effects of EL. One of the mechanisms to increase testosterone by EL is by elevating the luteinizing hormone (LH) and follicle stimulating hormone (FSH), which would stimulate the Leydig cells to produce testosterone in testes (Low et al. 2005). Since the rat's testes were removed in this model, the EL's testosterone-raising effect through this mechanism was not available.

In this study, micro-CT was proven to be the best imaging tool for non-invasive assessment of fracture healing. However, there were several limitations with micro-CT scanning. Frequent scanning especially with *in-vivo* micro-CT may lead to bone structural deformities. Lower radiation dose should be used but this may lead to reduce image sharpness and resolution. Therefore, there should be a balance between image quality and radiation risks. It was demonstrated that repeated micro-CT imaging for six weeks with a two week time interval at the radiation dose of 776 mGy and pixel size of 9  $\mu\text{m}$  had negative effects on the trabecular bone structure (Laperre et al. 2011).

## CONCLUSION

Based on the orchidectomised model, EL has shown potential in promoting fracture healing but was not as effective as testosterone. A micro-CT study on EL should be repeated with a different castration model.

## ACKNOWLEDGEMENTS

The authors would like to thank UKM and the Ministry of Higher Education for the grant (ERGS/1/2012/SKK03/UKM/02/1) and Encik Fadhlullah Zuhair Japar Sidek and other staff members of Pharmacology Department for their technical support.

## REFERENCES

- Amin, S., Felson, D.T. 2001. Osteoporosis in men. *Rheum Dis Clin North Am* 27(1): 19-47.
- Ang, H.H., Cheang H.S. 2001. Effects of *Eurycoma longifolia* jack on laevator ani muscle in both uncastrated and testosterone-stimulated castrated intact male rats. *Arch Pharm Res* 24(5): 437-40.
- Badea, C.T., Fubara, B., Hedlund, L.W., Johnson, G.A. 2005. 4-D micro-CT of the mouse heart. *Mol Imaging* 4(2): 110-6.
- Bhasin, S., Cunningham, G.R., Hayes, F.J., Matsumoto, A.M., Snyder, P.J., Swerdloff, R.S., Montori, V.M. 2010. Testosterone therapy in men with androgen deficiency syndromes: an endocrine society clinical practice guideline. *J Clin Endocrinol Metab.* 95(6): 2536-59.
- Boyd, S.K., Davison, P., Müller, R., Gasser, J.A. 2006. Monitoring individual morphological changes over time in ovariectomized rats by *in vivo* micro-computed tomography. *Bone* 39(4): 854-62.
- Burkill, I.H., Hanif, M. 1930. Malay village medicine, prescriptions collected. *Gardens Bulletin Strait Settlements* 6: 176-7.
- Consensus Development Conference (CDC). 1993. Diagnosis, prophylaxis and treatment of osteoporosis. *Am J Med* 94(6): 646-50.
- Cyranoski, D. 2005. Malaysian researchers bet big on home-grown Viagra. *Nat Med* 11(9): 912.
- Dom, S.M., Salikin, M.S., Hassan, H.F., Yusoff, N.M. 2012. The effect of B-mode diagnostic ultrasound exposure on rabbit foetal bone mineral density (BMD). *Radiography* 18: 197-200
- Duvall, C.L., Taylor, W.R., Weiss, D., Wojtowicz, A.M., Guldborg, R.E. 2007. Impaired angiogenesis, early callus formation, and late stage remodeling in fracture healing of osteopontin-deficient mice. *J Bone Miner Res* 22(2): 286-97.
- Ellem, S.J., Risbridger, G.P. 2006. Aromatase and prostate cancer. *Minerva Endocrinol* 31(1): 1-12.

- Eyres, K.S., Bell, M.J., Kanis, J.A. 1993a. Methods of assessing new bone formation during limb lengthening. Ultrasonography, dual energy X-ray absorptiometry and radiography compared. *J Bone Joint Surg Br* 75(3): 358-64.
- Eyres, K.S., Bell, M.J., Kanis, J.A. 1993b. New bone formation during leg lengthening: evaluated by dual energy X-ray absorptiometry. *J Bone Joint Surg Br* 75(1): 96-106.
- Gabet, Y., Muller, R., Regev, E., Sela, J., Shteyer, A., Salisbury, K., Chorev, M., Bab, I. 2004. Osteogenic growth peptide modulates fracture callus structural and mechanical properties *Bone* 35(1): 65-73.
- Gardner, M.J., van der Meulen, M.C., Demetrakopoulos, D., Wright, T.M., Myers, E.R., Bostrom, M.P. 2006. In vivo cyclic axial compression affects bone healing in the mouse tibia. *J Orthop Res* 24(8): 1679-86.
- Geiger, F., Bertram, H., Berger, I., Lorenz, H., Wall, O., Eckhardt, C., Simank, H.G., Richter, W. 2005. Vascular endothelial growth factor gene-activated matrix (VEGF165-GAM) enhances osteogenesis and angiogenesis in large segmental bone defects. *J Bone Miner Res* 20(11): 2028-35.
- Gerstenfeld, L.C., Cullinane, D.M., Barnes, G.L., Graves, D.T., Einhorn, T.A. 2003. Fracture healing as a post-natal developmental process: molecular, spatial, and temporal aspects of its regulation. *J Cell Biochem* 88(5): 873-84.
- Graham, K.C., Ford, N.L., MacKenzie, L.T., Postenka, C.O., Groom, A.C., MacDonald, I.C., Holdsworth, D.W., Drangova, M., Chambers, A.F. 2008. Noninvasive quantification of tumor volume in preclinical liver metastasis models using contrast-enhanced x-ray computed tomography. *Invest Radiol* 43(2): 92-99.
- Grundnes, O., Reikeras, O. 1993. The importance of the hematoma for fracture healing in rats. *Acta Orthop Scand* 64(3): 340-2.
- Habermann, B., Kafchitsas, K., Olender, G., Augat, P., Kurth, A. 2010. Strontium ranelate enhances callus strength more than pth 1-34 in an osteoporotic rat model of fracture healing. *Calcif Tissue Int* 86(1): 82-9.
- Hamdy, R.C., Petak, S.M., Lenchik, L. 2002. Which central dual X-ray absorptiometry skeletal sites and regions of interest should be used to determine the diagnosis of osteoporosis? *J Clin Densitom* 5 Suppl: S11-S18.
- Jiang, Y., Zhao, J., White, D.L., Genant, H.K. 2000. Micro CT and Micro MR imaging of 3D architecture of animal skeleton. *J Musculoskelet Neuronal Interact* 1(1): 45-51.
- Johnell, O., Kanis, J., Gullberg, G. 2001. Mortality, morbidity, and assessment of fracture risk in male osteoporosis. *Calcif Tissue Int* 69(4): 182-4.
- Jorgensen, S.M., Demirkaya, O., Ritman, E.L. 1998. Three-dimensional imaging of vasculature and parenchyma in intact rodent organs with X-ray micro-CT. *Am J Physiol* 275(3 Pt 2): H1103-14.
- Langheinrich, A.C., Bohle, R.M., Breithecker, A., Lommel, D., Rau, W.S. 2004. [Micro-computed tomography of the vasculature in parenchymal organs and lung alveoli]. *Rofo* 176(9): 1219-25.
- Laperre, K., Depypere, M., van Gastel, N., Torrekens, S., Moermans, K., Bogaerts, R., Maes, F., Carmeliet, G. 2011. Development of micro-CT protocols for in vivo follow-up of mouse bone architecture without major radiation side effects. *Bone* 49(4): 613-22.
- Liu, X., Nadeem, F., Salmon, P.L., Sasov, A. 2008. 4D time-resolved micro-CT imaging for small animals. *International Society for Optics and Photonics* 7078: 707809.
- Low, B.S., Ng, B.H., Choy, W.P., Yuen, K.H., Chan, K.L. 2005. Bioavailability and pharmacokinetic studies of eurycomanone from *Eurycoma longifolia*. *Planta Medica* 71(9): 803-807.
- Maffulli, N., Cheng, J.C., Sher, A., Lam, T.P. 1997. Dual-energy X-ray absorptiometry predicts bone formation in lower limb callotaxis lengthening. *Ann R Coll Surg Engl* 79(4): 250-6.
- Markel, M.D., Wikenheiser, M.A., Morin, R.L., Lewallen, D.G., Chao, E.Y. 1990. Quantification of bone healing. Comparison of QCT, SPA, MRI, and DEXA in dog osteotomies. *Acta Orthop Scand* 61(6): 487-98.
- Marsh, D.R., Li, G. 1999. The biology of fracture healing: optimising outcome. *Br Med Bull* 55(4): 856-69.
- Martiniova, L., Schimel, D., Lai, E.W., Limpuangthip, A., Kvetnansky, R., Pacak, K. 2010. In vivo micro-CT imaging of liver lesions in small animal models. *Methods* 50(1): 20-5
- Midura, R.J., Ibiwoye, M.O., Powell, K.A., Sakai, Y., Doehring, T., Grabiner, M.D., Patterson, T.E., Zborowski, M., Wolfman, A. 2005. Pulsed electromagnetic field treatments enhance the healing of fibular osteotomies. *J Orthop Res* 23(5): 1035-46.
- Morgan, E.F., Mason, D.Z., Chien, K.B., Pfeiffer, A.J., Barnes, G.L., Einhorn, T.A., Gerstenfeld, L.C. 2009. Micro-computed tomography assessment of fracture healing: Relationships among callus structure, composition, and mechanical function. *Bone* 44(2): 335-44.
- Nieschlag, E. 2006. Testosterone treatment comes of age: new options for hypogonadal men. *Clin Endocrinol (Oxf)* 65(3): 275-81.
- Nieschlag, E., Behre, H.M., Bouchard, P., Corrales, J.J., Jones, T.H., Stalla, G.K., Webb, S.M., Wu, F.C. 2004. Testosterone replacement therapy: current trends and future directions. *Hum Reprod Update* 10(5): 409-19.

- Nyman, J.S., Munoz, S., Jadhav, S., Mansour, A., Yoshii, T., Mundy, G.R., Gutierrez, G.E. 2009. Quantitative measures of femoral fracture repair in rats derived by micro-computed tomography. *J Biomech* **42**(7): 891-7.
- Putri A.J. 2015. The Suitable Androgen-Deficient Models for Investigation of Pro-androgenic Agents. *Research Updates in Medical Sciences* **3**(1): 83-6.
- Reiter, A., Sabo, D., Pfeil, J., Cotta, H. 1997. Quantitative assessment of callus distraction using dual energy X-ray absorptiometry. *Int Orthop* **21**(1): 35-40.
- Ramli, R., Khamis, M.F., Shuid, A.N. 2012. Bone Micro-CT Assessments in an Orchidectomised Rat Model Supplemented with *Eurycoma longifolia*. *Evid Based Complement Alternat Med* **2012**: 501858.
- Schambach, S.J., Bag, S., Schilling, L., Groden, C., Brockmann, M.A. 2010. Application of micro-CT in small animal imaging. *Methods* **50**(1): 2-13.
- Schmidhammer, R., Zandieh, S., Mittermayr, R., Pelinka, L.E., Leixnering, M., Hopf, R., Kroepfl, A., Redl, H. 2006. Assessment of bone union/nonunion in an experimental model using microcomputed technology. *J Trauma* **61**(1): 199-205.
- Shelfelbine, S.J., Simon, U., Claes, L., Gold, A., Gabet, Y., Bab, I., Muller, R., Augat, P. 2005. Prediction of fracture callus mechanical properties using micro-CT images and voxel-based finite element analysis. *Bone* **36**(3): 480-8.
- Shuid, A.N., Abu Bakar, M.F., Abdul Shukor, T.A., Muhammad, N., Mohamed, N., Soelaiman, I.N. 2011. The anti-osteoporotic effect of *Eurycoma longifolia* in aged orchidectomised rat model. *Aging Male* **14**(3): 150-4.
- Stuermer, E.K., Sehmisch, S., Rack, T., Wenda, E., Seidlova-Wuttke, D., Tezval, M., Wuttke, W., Frosch, K.H., Stuermer, K.M. 2010. Estrogen and reloxifene improve metaphyseal fracture healing in the early phase of osteoporosis. A new fracture-healing model at the tibia in rat. *Langenbecks Arch Surg* **395**(2): 163-72.
- Tajul Ariff, A.S., Soelaiman, I.N., Pramanik, J., Shuid, A.N. 2012. Effects of *Eurycoma longifolia* on Testosterone Level and Bone Structure in an Aged Orchidectomised Rat Model. *Evid Based Complement Alternat Med* **2012**: 818072.
- Talbott, S.M., Talbott, J.A., George, A., Pugh, M. 2013. Effect of Tongkat Ali on stress hormones and psychological mood state in moderately stressed subjects. *J Int Soc Sports Nutr* **10**(1): 28.
- Tambi, M.I., Imran, M.K. 2010. *Eurycoma longifolia* Jack in managing idiopathic male infertility. *Asian J Androl* **12**(3): 376-80.
- Thompson, D.D., Simmons, H.A., Pirie, C.M., Ke, H.Z. 1995. FDA Guidelines and animal models for osteoporosis. *Bone* **17**(4 Suppl): 125S-133S.
- Wahab, N.A., Mokhtar, N.M., Halim, W.N., Das, S. 2010. The effect of *eurycoma longifolia* Jack on spermatogenesis in estrogen-treated rats. *Clinics (Sao Paulo)* **65**(1): 93-98.
- Whelan, D.B., Bhandari, M., McKee, M.D., Guyatt, G.H., Kreder, H.J., Stephen, D., Schemitsch, E.H. 2002. Interobserver and intraobserver variation in the assessment of the healing of tibial fractures after intramedullary fixation. *J Bone Joint Surg Br* **84**(1): 15-18.
- Winzenberg, T., Jones, G. 2011. Dual energy X-ray absorptiometry. *Aust Fam Physician* **40**(1-2): 43-4.
- Yarrow, J.F., Conover, C.F., Purandare, A.V., Bhakta, A.M., Zheng, N., Conrad, B., Altman, M.K., Franz, S.E., Wronski, T.J., Borst, S.E. 2008. Supraphysiological testosterone enanthate administration prevents bone loss and augments bone strength in gonadectomized male and female rats. *Am J Physiol Endocrinol Metab* **295**(5): E1213-E1222.