

ORIGINAL ARTICLE

Patterns of Polypoidal Choroidal Vasculopathy among a Multiracial Population in a Malaysian Hospital

NAZIMA SA, HANISAH AH, RONA AN, WONG HS, AMIN A,
BASTION MLC, MUSHAWIAHTI M, HAZLITA MI

Department of Ophthalmology, Faculty of Medicine, Universiti Kebangsaan Malaysia Medical Centre, Jalan Yaacob Latif, Bandar Tun Razak, 56000 Cheras, Kuala Lumpur, Malaysia.

ABSTRAK

Polypoidal choroidal vasculopathy (PCV) adalah penyakit retina yang dicirikan oleh aneurismal polip dalam salur darah koroid. Penyakit PCV kerap berlaku dikalangan populasi yang berpigmen terutama di kalangan orang Asia. Kebanyakan laporan mengenai corak penyakit PCV disekitar Asia hanya berdasarkan satu bangsa sahaja (e.g. kaum Cina, Jepun). Amat sedikit laporan mengenai corak penyakit ini dalam populasi pelbagai bangsa seperti di Malaysia. Oleh itu, kajian ini bertujuan menggambarkan ciri-ciri demografi, klinikal dan penyiasatan PCV dalam populasi pelbagai bangsa di Pusat Perubatan Universiti Kebangsaan Malaysia (PPUKM). Ini adalah kajian retrospektif pada 91 mata dari 86 pesakit PCV, terdiri daripada Cina (65.1%), Melayu (31.4%), India (2.3%) dan Eurasian (1.2%). Semua pesakit telah menjalani pemeriksaan oftalmik dan penyiasatan terperinci. Purata umur pesakit adalah 70.4 tahun, kebanyakannya lelaki (59.3%) dan majoriti mengalami masalah didalam satu mata sahaja (94.1%). Purata penglihatan adalah log MAR 0.78 ± 0.64 . Luka-luka vaskular polypoidal umumnya didapati dalam kawasan makular (86.8%) dan menunjukkan pendarahan terutamanya dibawah lapisan makular (59.3%). Menariknya, beberapa mata (43.9%) menunjukkan "drusen". Optikal kepaduan tomografi kebanyakannya menunjukkan perubahan eksudatif (75.9%) dan hampir semua pesakit (97.7%) mempunyai kehilangan membran pengehad external (ELM) dan IS/OS. Dengan ICG angiografi, kebanyakan mata didapati ada lebih dari satu polip (82.4%) dan konfigurasi polip yang paling kerap adalah dalam bentuk 'kelompok' (58.2%). Kesimpulannya, walaupun secara amnya corak PCV di PPUKM sama dengan corak PCV dipopulasi Asia yang lain, namun beberapa pesakit mempunyai "drusen". Oleh itu, PCV di Malaysia mungkin berlainan dengan populasi Asia lain dimana ia mungkin adalah varian degenerasi makular dan tidak idiopatik semata-mata.

Address for correspondence and reprint requests: Hazlita Mohd Isa, Department of Ophthalmology, Faculty of Medicine, Universiti Kebangsaan Malaysia Medical Centre, Jalan Yaacob Latif, Bandar Tun Razak, 56000 Cheras, Kuala Lumpur, Malaysia. Tel: +603-91455981/5984 Fax: +603-91453378 Email: drhdmia@yahoo.co.uk

Kata kunci: angiografi, koroid, indocynine hijau, makula, degenerasi makula, optikal kepaduan tomografi

ABSTRACT

Polypoidal choroidal vasculopathy (PCV) is a retinal disorder characterized by aneurismal polypoidal lesions in choroidal vasculature. PCV appears to preferentially affect pigmented individuals and is considerably high among Asians. Most reports on patterns of PCV around Asia are based on a homogenous race (e.g. Chinese, Japanese) and very few descriptions from a multiracial population like those seen in Malaysia. The present study aimed to describe the demographic features, clinical and investigative characteristics of PCV in a multiracial group at Universiti Kebangsaan Malaysia Medical Centre (UKMMC). Ninety one eyes of 86 PCV patients, comprising of Chinese (65.1%), Malays (31.4%), Indians (2.3%) and Eurasian (1.2%) were retrospectively reviewed. All underwent complete ophthalmic examination and investigations. Mean patient age was 70.4 years with a male preponderance (59.3%), and mostly unilateral presentation (94.1%). The logMAR mean presenting visual acuity was 0.78 ± 0.64 . Polypoidal vascular lesions were located generally within the macula area (86.8%), manifesting mainly as submacular hemorrhage (59.3%). Interestingly a number of eyes (43.9%) had associated drusen. Optical coherence tomography largely demonstrated exudative changes (75.9%) and almost all patients (97.7%) had loss of external limiting membrane (ELM) and IS/OS interface. On indocyanine green angiography, majority of eyes had multiple polyps (82.4%) with 'cluster' (58.2%) being the commonest configuration. In conclusion, although the patterns of PCV in UKMMC were mainly similar to other Asian patients, a number of our patients had associated drusen. This indicates that PCV in our population could be a variant of neovascular age related macular degeneration and not solely idiopathic in nature.

Keywords: angiography, choroid, indocyanine green, macular, macular degeneration, optical coherence tomography

INTRODUCTION

Polypoidal choroidal vasculopathy (PCV) is a retinal disorder characterized by the presence of out pouching or polyp like aneurismal dilatation of the choroidal vessels which is thought to be a clinical variant of neovascular age-related macular degeneration (AMD) (Yannuzzi et al. 1990; Ciardella et al. 2004; Gomi & Tano 2008). PCV seems

to preferentially affect pigmented individuals thus African-Americans and Asians are at higher risk. Various studies suggest that the incidence of PCV is considerably high in Asians, very high in blacks and low in whites. On the contrary, the incidence of AMD is high in whites; moderate in Asians and very low in blacks (Uyama et al. 2002; Sho et al. 2003). Most reports on

the patterns of PCV in Asia are mainly based on patients from a homogenous race (e.g. Chinese, Japanese, etc) (Gomi & Tano 2008; Uyama et al. 2002; Sho et al. 2003) and very few descriptions are from a mixed race population.

Malaysia, is a unique multiracial country, predominantly populated by the Malays (67.4%), followed by the Chinese (24.6%), and Indians (7.3%) where each race is unique in phenotypically and genetically (Department of Statistics Malaysia 2016). In the recent years, with increase awareness in macular diseases and in the current era of anti-VEGF treatment, Malaysia has seen a rise in the number of PCV patients.

The Universiti Kebangsaan Malaysia Medical Centre (UKMMC) is situated in the capital city Federal Territory of Kuala Lumpur; the most populous city in Malaysia. The centre is a tertiary referral centre, catering mainly for the population around the area, as well as receiving referral from various private and other local hospitals from all over Malaysia. Over the years it is noted that patients diagnosed with PCV in UKMMC appears to affect not only the Chinese population but other races too. This study therefore wanted to discover and describe the pattern of PCV in our mixed racial group particularly in terms of their features on fundus photographs, OCT, FFA and ICG. Then comparison made with other studies and see whether the findings differ or similar.

MATERIALS AND METHODS

Patients were identified from the Department of Ophthalmology,

UKMMC medical retina database. All patients with a confirmed diagnosis of PCV by two independent medical retina specialists from January 2013 to October 2015 were included in the study. Exclusion criteria were: exudative age related macular degeneration, high myopia, angioid streak, presumed ocular histoplasmosis syndrome, central serous chorioretinopathy, previous ocular surgery other than cataract and patient who were contraindicated for angiographic study. The medical records, fundus photographs, optical coherence tomography, fundus fluorescein angiography and indocyanine green angiography of all patients were then retrospectively reviewed. Medical illnesses such as diabetes, hypertension, dyslipidemia and cardiovascular disease as well the smoking status were identified from medical records.

On fundus photography, the PCV manifestations were grouped into either serous or hemorrhagic PCV. In the serous PCV group, the findings included serous retinal detachment, serous PED and intraretinal lipid deposition. Hemorrhagic PED, subretinal and vitreous hemorrhage were grouped under hemorrhagic PCV. Presence of orange-like nodule as well as drusens were also documented.

Features of PCV on OCT that were observed were based on the description by Coscas (2009) and Sato et al. (2007). These included the the double-hump sign and a 'double-layer' sign (Coscas 2009; Sato et al. 2007). Presence of exudative changes of the lesion and the loss of ELM and IS/OS interface were also looked at.

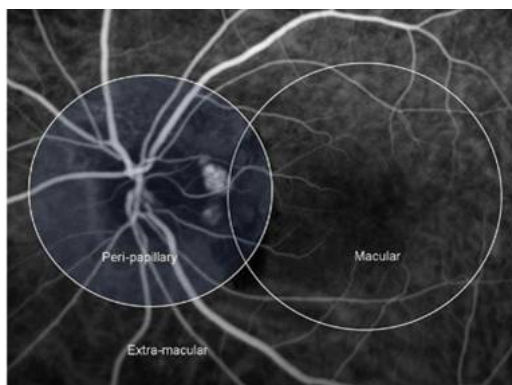


Figure 1: Location of polypoidal lesions on ICG¹⁴

On FFA, features of expanding fluorescent leakage or pseudoclassic CNV lesion and location of this pseudoclassic CNV lesion were documented and classified either located at the subfoveal, juxtafoveal or extrafoveal region, adjacent or separate to the polypoidal lesion.

On ICG angiography, PCV was characterized by a branching vascular network (BVN) that lies anterior to choroidal vessels that can be seen on stereoscopic examination (Spaide et al. 1995). The location of the polypoidal lesions on ICG were assigned to either peripapillary (polyp and BVN located within 1500 μm of the disc margin), macular (lesion is within 6000 μm diameter of the centre of FAZ) or extramacular (lesion lying outside the temporal vascular arcades) according to a previous study described by Lim et al. (2010) (Figure 1).

The polyp configurations were identified based on their angiographic features. The polyps were defined as solitary (one polyp) or multiple. If multiple, the polyps were classified as either cluster (or 'bunch of grapes'), in a ring (or 'whorl' pattern) or in a line (or

'string of pearls') (Lim et al. 2010; Cackett et al. 2009). In addition, we described two solitary polyps closely adjacent to each other as a diploid pattern (Figure 2). The study was approved by the UKM Research and Ethics Committee.

STATISTICAL ANALYSIS

Statistical analysis for descriptive statistics was performed using SPSS statistical software (SPSS, Inc, Chicago, IL, USA). Epidemiology and clinical and investigative features were described in percentages.

RESULTS

A total of 91 eyes from 86 patients were included in the study. Patients' age ranged from 54 to 86 yrs, (mean age of 70.4 yrs) for the whole study population. Almost two thirds of the patients were males ($n=51$, 59.3%) and 35 patients (40.7%) were females. Chinese race predominated (65.1%, $n=56$) followed by Malays (31.4%, $n=27$), Indians (2.3%, $n=2$) and Eurasian (1.2%, $n=1$). Thirty-five patients (40.7%) had diabetes mellitus as co-morbidities followed by 39 (45.3%) with hypertension,

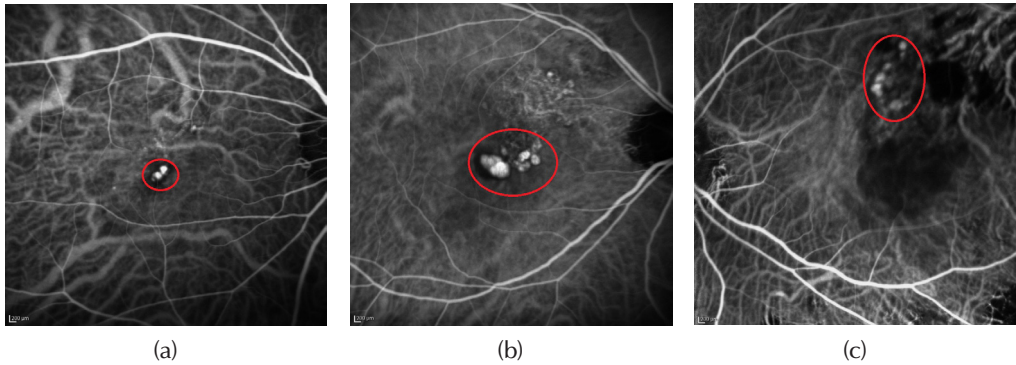


Figure 2: Polyp(s) configuration, (a) Diploid, (b) Clusters, and (c) 'String of pearls'

31 (36.0%) had dyslipidemia and 12 (13.9%) had cardiovascular disease. Only 16 (18.2%) patients were active smokers. The presenting mean best corrected visual acuity (BCVA) was 0.78 ± 0.64 logMAR units (Snellen 6/36) and the majority of patients had unilateral presentation (94.2%, n=81).

Most of the clinical findings on fundus photography at the first visit were confined to the area of the macula (86.8%). The commonest retinal manifestations at presentation were subretinal hemorrhage, seen in 54 eyes (59.3%), followed by serous macular detachment in 49 eyes (54.4%) and pigment epithelial detachment in 49 eyes (53.8%) (Table 1). Forty eyes (43.9%) were found to have drusens in the affected eye (Figure 3) and 48 eyes (52.7%) had orange-like nodule.

On SD-OCT, 75.9% of the eyes had exudative changes and double-hump sign (n = 66 eyes), while 64 eyes (73.6%) had double layer sign on SD-OCT (Figure 4). Nearly all patients (97.7%, n=85) had loss of ELM and IS/OS interface. Other SD-OCT findings were summarized in Table 2.

FFA features of the CNV lesions were summarised in Table 3. On

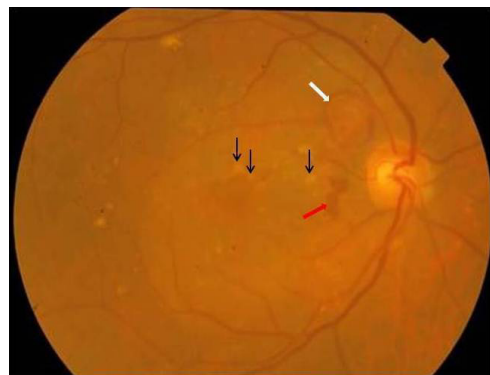


Figure 3: Fundus photograph of a PCV patient showing multiple drusens (black arrows), with hemorrhagic PED (white arrow) and subretinal hemorrhages (red arrows).

Table 1: Predominant findings in the macula in PCV at first visit *

Predominant Findings	No. (%) of eyes
Exudative pattern	
Serous retinal detachment	49 (54.4)
Serous PED	36 (39.6)
Intraretinal lipid deposits	48 (52.7)
Total	136
Hemorrhagic pattern	
Hemorrhagic PED	13 (14.3)
Subretinal hemorrhage	54 (59.3)
Vitreous hemorrhage	7 (7.7)
Total	72

* An eye can have more than 1 manifestation.

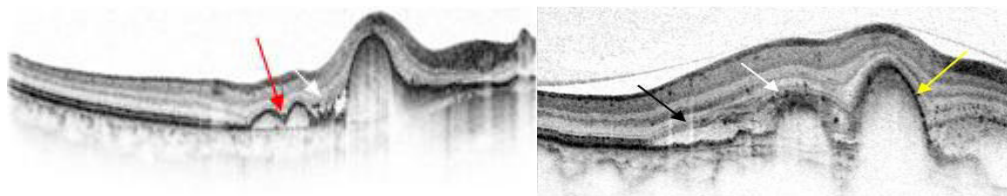


Figure 4: SD-OCT showing double-layer sign (black arrow), exudative changes (white arrows), double-hump sign (red arrow) and PEDs (yellow arrows).

ICG, pulsatile polyps were seen in 15 eyes (18.8%) and the predominant location for these polypoidal vascular abnormalities was in the macula area seen in 79 eyes (86.8%). A cluster of grape-like (Figure 2) polypoidal vascular dilations were the most common polyp pattern observed in 46 eyes (58.2%) (Table 4).

DISCUSSION

Apart from a previous report on visual outcome in vitrectomised PCV and AMD patients (Bastion et al. 2012), to the best of our knowledge this was the first study describing the pattern of PCV in a mixed race group of patients in a single tertiary centre in Malaysia. It was noted that the mean age in our study population was slightly older (70.4 years) compared to previous studies where mean age at presentations were within the age of 60. This was due to the fact that nearly a tenth (9.3%, n=8) of our PCV patients were 80 years old and above with the oldest being 86 years old. Although the majority of cases were among patients of Chinese-descendant (65%), one third of the cases in our study population were Malays (31%).

Our findings were consistent with several previous epidemiological studies where cases of PCV were reported

Table 2: OCT features of PCV

OCT features	No. of eyes (%)
Exudative changes	66 (75.9)
Double layer sign	64 (73.6)
Double-hump sign	66 (75.9)
Loss of external limiting membrane and IS/OS interface	85 (97.7)
PEDs	76 (87.4)
Multiple	42 eyes (48.3)
Single	34 eyes (39.1)
Absent	11 eyes (12.6)
Adjacent sub retinal fluid	71 eyes (81.6)

*N= 91 eyes. Some eyes had more than one finding.

Table 3: FFA features of PCV

FFA features of PCV	No. of eyes (%)
Location of CNV	
Juxtafovea	9 (10.5)
Subfovea	18 (20.9)
Extrafovea	59 (68.6)
Relation of CNV to polypoidal lesion	
Adjacent	75 (87.2)
Separate	11 (12.8)

to be more common in pigmented individuals such as blacks and Asians, (Yannuzzi et al. 1999; Ahuja et al. 2000; Yannuzzi et al, 1997; Lafaut et al. 2000; Kabasawa et al. 2011) and have a high incidence among the Japanese and Chinese populations (Table 5). In our multiracial study population, PCV

Table 4: ICG features of PCV

ICG features of PCV	No. of eyes (%)
Location of polyp (s)	
Macula	79 (86.8)
Peri papillary	6 (6.6)
Extramacular	6 (6.6)
Number of polyp (s)	
Single polyp	14 (15.4)
Multiple polyps	77 (84.6)
Cluster	46 (59.7)
'String of pearls'	23 (29.3)
'Ring-like'	7 (9.3)
Diploid	4 (5.3)

*One eye had both clusters and string of pearls polyps' configuration

occurrence had a preponderance for male gender (59.3%), unilateral involvement (94.1%) and macular location (86.8%) of the polyps and this was similar to other studies from Asia (Uyama et al. 2002; Yannuzzi et al. 1994). On the other hand, our findings differ greatly from the white population where PCV is reported to be more common among female patients with bilateral involvement and peripapillary location (Yannuzzi et al. 1990; Tsujikawa et al. 2007; Ojima et al. 2009; Lafaut et al. 2000). Important genetic substrate most probably explains the epidemiological similarities between our study population with other Asian populations and the difference observed with the white population. Further genetic studies however could be beneficial to explain and confirm this theory.

It is known that smoking is strongly associated with AMD and appears to be an important risk factor for PCV. In a study by Kabasawa et al. (2011), when compared to normal controls, smoking

was associated with an odds ratio of 4.87 for PCV. Similar finding was demonstrated by Cackett et al. (2009) with an odds ratio of 4.4 for smoker. However in our patients, only 16 of them (18.6%) were active smokers and 10 patients (11.6%) were ex-smokers.

It had been previously reported that hypertension might be associated in one third of PCV patients (Spaide et al. 1995). Ahuja et al. (2000) and Lip et al. (2000) found in their studies that 23.5% and 20% of their patients had history of hypertension. Almost half of our patients (45.3%) had hypertension which may suggest a probable close relationship between hypertension and PCV.

In PCV, the clinical manifestations are similar to those of neovascular AMD (Table 1). Sub-retinal hemorrhage at the macula was the most common feature (59.3%) in our study group, followed by serous macular detachment and PED, 54.4% and 53.8% respectively. According to Yannuzzi et al. (1990), due to low level of subretinal fibrovascular proliferation and hyperplasia of the RPE in PCV, there is little subretinal fibrosis and disciform scarring in PCV. It was previously reported that subretinal fibrovascular disciform scarring is rare in PCV however; one third of our patients had subretinal fibrovascular proliferations in the macula. This can be due to late presentation of our patients prior to diagnosis. Subretinal fibrous proliferation causes severe irreversible visual loss due to the disruption of sensory retina and retinal pigment epithelium (RPE). In a study by Tsujikawa et al. (2007), PED was observed in 51 eyes (55%), of which

Table 5: Comparison of findings with other PCV studies *

Source, y	Ethnicity, %	No. of Patients with PCV	Mean Age, y	Sex, % M	Bilaterality, %	Location of polyps, %	
						Macula	Peripapillary
Yannuzzi et al. 1997	Black, 50	20	60.1	15	80	25	75
	Asian, 30						
	White, 20						
Uyama et al. 1999	Japanese, 100	32	65.7	69	9	94	9
Lafaut et al. 2000	White, 100	36	N/A	47	61	49	36
Ahuja et al. 2000	White, 74	34	65.4	35	47	68	18
	Black, 20						
	Asians, 6						
Scassellati-Sforzolini et al. 2001	White, 100	19	73.4	47	21	53	37
Uyama et al. 2002	Japanese, 100	12	68.1	83	7	92	7
Kwok et al. 2002	Chinese, 100	19	65.1	68	16	64	32
Sho et al. 2003	Japanese, 100	100	68.4	63	10	85	7
Wen et al. 2004	Chinese, 100	23	50	73	13	N/A	N/A
Liu et al. 2007	Chinese, 100	38	50-86	68	24	N/A	N/A
Maruko et al. 2007	Japanese, 100	158	40	78	18	N/A	N/A
Byeon et al. 2008	Korean, 100	79	64.6	79	24	N/A	N/A
Chang et al. 2009	Taiwanese, 100	51	63.6	71	8	N/A	N/A
Mori et al. 2010	Japanese, 100	154	51-96	79	14	N/A	N/A
Li et al. 2014 Beijing Eye Study	Chinese, 100	3468	0.3 ± 0.1, 95% CI 0.1 ± 0.4	≥50	59	6	N/A
Coscas et al. 2015	Japanese, 51.3	48	N/A	N/A	N/A	N/A	N/A
	French, 48.7	9					
Cheung et al. 2014	Chinese, 88.2	102	68.9	58	5	N/A	N/A
	Indian, 1.1						
	Malay, 7.8						
	Others, 2.9						
UKMMC study, 2016	Malay, 31.4	86	70.4	59	6	87	7
	Chinese, 65.1						
	Indian, 2.3						
	Eurasian, 1.2						

Modified from Table 3 in Sho et al. and Table 1 in Wong et al. 2015

5 were hemorrhagic PED (9.8%) and 46 (90.2%) were serous. In our study, similar findings were observed where 49 eyes were found to have PED (53.8%), 13 eyes had hemorrhagic PED (26.5%) and 36 eyes (73.5%) had serous PED.

PCV is not usually associated with drusen, being reported only around 16.7% in a study by Yannuzzi et al. (1999) and around 26.7% in study by Scassellati-Sforzolini et al. (2001) among PCV patients. However, almost half (43.9%) of the PCV patients in our study population had drusen in the involved eye which is higher compared to other studies. In a recent study by Coscas et al. (2015), the authors postulated that there might be two distinct PCV groups which are: i) an idiopathic group (purely polypoidal) and ii) a subtype of neovascular (NV)-AMD group which is associated with drusen. They also found that the idiopathic group had a significantly better visual acuity between compared to the NV-AMD group. It is said that although these groups share some similarities; however the treatment approach and responses might differ based on the underlying pathogenesis (Coscas et al. 2015).

SD-OCT is an important investigative tool in the diagnosis of PCV as well in monitoring the disease progression and response to treatment. The specificity and sensitivity for the detection of PCV using SD-OCT is 92.9% and 94%, respectively (De Salvo et al. 2014). Actively evolving polyps are usually associated with exudative changes seen as sub-retinal or intra-retinal fluid collection. Bright hyper-reflective spots adjacent to the polyps can also be

detected in the outer or inner retinal layers. The protrusion of the polyps can alter the outer retinal layers, with subsequent displacement of the outer nuclear layer. The external limiting membrane (ELM) and inner segment-outer segment (IS/OS) interface can be lost leading to severe visual loss (Coscas 2009). These OCT findings show that PCV lesions do not arise directly from the choroid (Balaratnasingam et al. 2016). These polypoidal lesions are mostly present at the margin and inside the PED, which may cause a 'notch sign' between PED, also described as the 'double hump' sign seen with OCT (Tan et al. 2015).

On FFA, almost 87% of eyes had polypoidal lesion adjacent to the CNV, as opposed to only 9% in the study by Sho et al. (2003). This suggests that in our patients, the pathogenesis of polypoidal CNV in PCV might be similar to the CNV in AMD and not purely idiopathic in nature.

ICG angiography is very useful for diagnosing PCV as it often demonstrates polypoidal lesions with or without branching vascular network (BVNs) from the choroidal circulation. It also detects aneurismal and spheroidal vascular dilation of the choroidal vessel (Yannuzzi et al. 1990; Uyama et al. 2002; Yannuzzi et al. 1999). Majority of the polyps were located in the macula region in Asian patients (86.8% in the current study) as seen in our study, whereas it is equally distributed in the macular and peripapillary location in Europeans (Tsujikawa et al. 2007). In a study by Uyama et al. (2002), clustered grape-like polypoidal lesions were commonly observed in Asian

population and it carries poor visual prognosis which is consistent with our study where more than half of our patients had clustered grape-like polyps on ICG and it would certainly affect the overall visual outcome of the patients in the study.

The present study was performed in a single tertiary centre. Thus, it may do not reflect the Malaysian population as a whole. In addition, we did not look at visual and treatment outcomes of these patients. It would also be interesting to compare the pattern of PCV presentation and investigations among races which we are currently conducting. Despite this, this study does provide a glimpse of the pattern of PCV among Malaysian.

In conclusion, the pattern in our mixed race community shows a difference in the pattern of PCV presentation. PCV in our population showed a tendency to be a subtype of neovascular AMD. This suggests that race may have a role in the manifestation of PCV and may influence treatment and PCV outcome in these patients.

ACKNOWLEDGEMENT

The authors would like to acknowledge the technicians and photographers who performed the imaging of the fundus and took photos, angiograms and OCT. The authors also thank the nurses who helped out during the angiograms. The authors express their gratitude to Dr. Isa HM and Dr. Wong HS for their expertise in the image interpretations where needed.

REFERENCES

- Ahuja, R.M., Stanga, P.E., Vingerling, J.R., Reck, A.C., Bird, A.C. 2000. Polypoidal choroidal vasculopathy in exudative and hemorrhagic pigment epithelial detachments. *Br J Ophthalmol* **84**(5): 479-84.
- Balaratnasingam, C., Lee, W.K., Koizumi, H., Dansingani, K., Inoue, M., Freund, K.B. 2016. Polypoidal choroidal vasculopathy. A distinct disease or manifestation of many. *Retina* **36**(1): 1-8.
- Bastion, M.L.C., Ameloh, M.A.Q., Wong, H.S. 2012. Vitrectomy for breakthrough bleeding in age related macular degeneration and polypoidal choroidal vasculopathy in a Malaysian hospital. *Journal of Surgical Academia* **2**(2): 21-6.
- Byeon, S.H., Lee, S.C., Oh, H.S., Kim, S.S., Koh, H.J., Kwon, O.W. 2008. Incidence and clinical patterns of polypoidal choroidal vasculopathy in Korean patients. *Jpn J Ophthalmol* **52**(1): 57-62.
- Cackett, P., Wong, D., Yeo, I. 2009. A classification system for polypoidal choroidal vasculopathy. *Retina* **29**(2): 187-91.
- Chang, Y.C., Wu, W.C. 2009. Polypoidal choroidal vasculopathy in Taiwanese patients. *Ophthalmic Surg Lasers Imaging* **40**(6): 576-81.
- Cheung, C.M., Li, X., Mathur, R., Lee, S.Y., Chan, C.M., Yeo, I., Loh, B.K., Williams, R., Wong, E.Y., Wong, D., Wong, T.Y. 2014. A prospective study of treatment patterns and 1-year outcome of Asian age-related macular degeneration and polypoidal choroidal vasculopathy. *PLoS One* **9**(6): e101057.
- Ciardella, A.P., Donsoff, I.M., Huang, S.J., Costa, D.L., Yanuzzi, L.A. 2004. Polypoidal choroidal vasculopathy. *Surv Ophthalmol* **49**(1): 25-37.
- Coscas, G. 2009. Optical coherence tomography in Age-Related Macular Degeneration: OCT in AMD. 2nd edition. Heidelberg: Springer Medizin Verlag; 302-22.
- Coscas, G., Lupidi, M., Coscas, F., Benjellion, F., Zerbib, J., Dirani, A., Semoun, O., Souied, E.H. 2015. Toward a specific classification of polypoidal choroidal vasculopathy: Idiopathic disease or subtype of age-related macular degeneration. *Invest Ophthalmol Vis Sci* **56**(5): 3187-95.
- Department of Statistics, Malaysia. 2010. Population Distribution and Basic Demographic Characteristic Report. (Ethnic composition). https://en.wikipedia.org/wiki/Demographics_of_Malaysia [12 March 2016]
- De Salvo, G., Vaz-Pereira, S., Keane, P.A., Tufail, A., Lieu, G. 2014. Sensitivity and specificity of spectral-domain optical coherence tomography in detecting idiopathic polypoidal choroidal

- vasculopathy. *Am J Ophthalmol* **158**(6): 1228-38.
- Gomi, F., Tano, Y. 2008. Polypoidal choroidal vasculopathy and treatments. *Curr Opin Ophthalmol* **19**(13): 208-12.
- Kabasawa, S., Mori, K., Horie-Inoue, K., Gehlbach, P.L., Inoue, S., Awata, T., Katayama, S., Yoneya, S. 2011. Associations of cigarette smoking but not serum fatty acids with age-related macular degeneration in a Japanese population. *Ophthalmology* **118**(6): 1082-8.
- Kwok, A.K., Lai, T.Y., Chan, C.W., Neoh, E.L., Lam, D.S. 2002. Polypoidal choroidal vasculopathy in Chinese patients. *Br J Ophthalmol* **86**(8): 892-7.
- Lafaut, B.A., Leys, A.M., Snyers, B., Rasquin S., De Leay, J.J. 2000. Polypoidal choroidal vasculopathy in Caucasians. *Graefes Arch Clin Exp Ophthalmol* **238**(9): 752-9.
- Li, Y., You, Q.S., Wei, W.B., Xu, J., Chen, C.X., Wang, Y.X., Xu, L., Jonas, J.B. 2014. Polypoidal choroidal vasculopathy in adult Chinese: the Beijing Eye Study. *Ophthalmology* **121**(2): 2290-1.
- Lim, T.H., Laude, A., Tan, C.S. 2010. Polypoidal choroidal vasculopathy: an angiographic discussion. *Eye (Lond)* **24**(3): 483-90.
- Lip, P.L., Hope-Ross, M.W., Gibson, J.M. 2000. Idiopathic polypoidal choroidal vasculopathy: a disease with diverse clinical spectrum and systemic associations. *Eye (Lond)* **14** Pt 5: 695-700.
- Liu, Y., Wen, F., Huang, S., Luo, G., Yan, H., Sun, Z., Wu, D. 2007. Subtype lesions of neovascular age-related macular degeneration in Chinese patients. *Graefes Arch Clin Exp Ophthalmol* **245**(10): 1441-5.
- Maruko, I., Iida, T., Saito, M., Nagayama, D., Saito, K. 2007. Clinical characteristics of exudative age-related macular degeneration in Japanese patients. *Am J Ophthalmol* **144**(1): 15-22.
- Mori, K., Horie-Inoue, K., Gehlbach, P.L., Takita, H., Kabasawa, S., Kawasaki, I., Ohkubo, T., Kurihara, S., Iizuka, H., Miyashita, Y., Katayama, S., Awata, T., Yoneya, A., Inoue, S. 2010. Phenotype and genotype characteristics of age-related macular degeneration in a Japanese population. *Ophthalmology* **117**(5): 928-38.
- Ojima, Y., Hangai, M., Sakamoto, A., Tsujikawa, A., Otani, A., Tamura, H., Yoshimura, N. 2009. Improved visualisation of polypoidal choroidal vasculopathy lesions using spectral-domain optical coherence tomography. *Retina* **29**(1): 52-9.
- Sato, T., Kishi, S., Watanabe, G., Matsumoto, H., Mukai, R. 2007. Tomographic features of branching vascular networks in polypoidal choroidal vasculopathy. *Retina* **25**(5): 589-94.
- Scassellati-Sforzolini, B., Mariotti, C., Bryan, R., Yannuzzi, L.A., Giuliani, M., Giovannini, A. 2001. Polypoidal choroidal vasculopathy in Italy. *Retina* **21**(2): 121-5.
- Sho, K., Takahashi, K., Yamada, H., Wada, M., Nagai, Y., Otsuji, T., Nishikawa, M., Mitsuma, Y., Yamazaki, Y., Matsumura, M., Uyama, M. 2003. Polypoidal choroidal vasculopathy. incidence, demographic features, and clinical characteristics. *Arch Ophthalmol* **121**(10): 1392-6.
- Spaide, R.F., Yanuzzi, L.A., Slakter, J.S., Sorenson, J., Orlock, D.A. 1995. Indocyanine green videoangiography of idiopathic polypoidal choroidal vasculopathy. *Retina* **15**(2): 100-10.
- Tan, C.S., Ngo, W.K., Lim, L.W., Lim, T.H. 2014. Optical coherence tomography features of polypoidal choroidal vasculopathy and their impact on visual outcomes. *Invest Ophthalmol Vis Sci* **55**(13): 4044.
- Tsujikawa, A., Sasahara, M., Otani, A., Gotoh, N., Kameda, T., Iwama, D., Yodoi, Y., Tamura, H., Mandai, M., Yoshimura, N. 2007. Pigment epithelial detachment in polypoidal choroidal vasculopathy. *Am J Ophthalmol* **43**(1): 102-111.
- Uyama, M., Matsubara, T., Fukushima, I., Matsunaga, H., Iwashita, K., Nagai, Y., Takahashi, K. 1999. Idiopathic polypoidal choroidal vasculopathy in Japanese patients. *Arch Ophthalmol* **117**(8): 1035-42.
- Uyama, M., Wada, W., Nagai, Y., Matsubara, T., Matsunaga, H., Fukushima, I., Takahashi, K., Matsumura, M. 2002. Polypoidal choroidal vasculopathy: natural history. *Am J Ophthalmol* **133**(5): 639-48.
- Wen, F., Chen, C., Wu, D., Li, H. 2004. Polypoidal choroidal vasculopathy in elderly Chinese patients. *Graefes Arch Clin Exp Ophthalmol* **242**(8): 625-9.
- Wong, C.W., Wong, T.Y., Cheung C.M. 2015. Polypoidal Choroidal Vasculopathy in Asians. *J Clin Med* **4**(5): 782-821.
- Yannuzzi, L.A., Sorenson, J., Spaide, R.F., Lipson, B. 1990. Idiopathic polypoidal choroidal vasculopathy. *Retina* **10**(1): 1-8.
- Yannuzzi, L.A., Hope-Ross, M., Slakter, J.S., Guyer, D.R., Sorenson, J.A., Ho, A.C., Sperber, D.E., Freund, K.B., Orlock, D.A. 1994. Analysis of vascularized pigment epithelial detachments using indocyanine green video angiography. *Retina* **14**(2): 99-113.
- Yannuzzi, L.A., Ciardella, A., Spaide, R.F., Rabb, M., Freund, K.B., Orlock, D.A. 1997. The expanding clinical spectrum of idiopathic polypoidal choroidal vasculopathy. *Arch Ophthalmol* **115**(4): 478-85.
- Yannuzzi, L.A., Wong, D.W., Sforzolini, B.S., Goldbaum, M., Tang, K.C., Spaide, R.F., Freund,

K.B., Slakter, J.S., Guyer, D.R., Sorenson, J.A., Fisher, Y., Maberley, D., Orlock, D.A. 1999. Polypoidal choroidal vasculopathy and neovascularised age-related macular degeneration. *Arch Ophthalmol* **117**(11): 1503-10.