



University of  
Zurich<sup>UZH</sup>

Zurich Open Repository and  
Archive

University of Zurich  
Main Library  
Strickhofstrasse 39  
CH-8057 Zurich  
[www.zora.uzh.ch](http://www.zora.uzh.ch)

---

Year: 2017

---

## Combined intra- and extraperitoneal urinary bladder rupture - a rare seat-belt injury: a case report

Grünherz, Lisanne; Startseva, Xenia; Kozomara-Hocke, Marko; Barth, Borna K; Simmen, Hans-Peter; Mica, Ladislav; Rauer, Thomas

**Abstract:** **INTRODUCTION:** While isolated traumatic urinary bladder injuries are rare, combined intra- and extraperitoneal traumatic urinary bladder ruptures without an underlying fracture are an absolute rarity. **PRESENTATION OF CASE:** We report a case of combined intra- and extraperitoneal urinary bladder rupture without an underlying fracture resulting from blunt abdominal trauma during a high velocity car accident. A midline laparotomy was performed, and the intra- and extraperitoneal bladder ruptures were surgically treated. **DISCUSSION:** Based on the presented case the anatomical peculiarities of the urinary bladder and the different trauma mechanisms as well as the resulting lesions, the diagnostic modalities and the treatment options are discussed. **CONCLUSION:** Despite the rarity of traumatic urinary bladder injuries, and especially in the absence of an underlying fracture, physicians should maintain a high level of suspicion for urologic injuries in the presence of nonspecific lower abdominal pain, gross haematuria and the inability to urinate.

DOI: <https://doi.org/10.1016/j.ijscr.2017.07.029>

Posted at the Zurich Open Repository and Archive, University of Zurich

ZORA URL: <https://doi.org/10.5167/uzh-139855>

Published Version



Originally published at:

Grünherz, Lisanne; Startseva, Xenia; Kozomara-Hocke, Marko; Barth, Borna K; Simmen, Hans-Peter; Mica, Ladislav; Rauer, Thomas (2017). Combined intra- and extraperitoneal urinary bladder rupture - a rare seat-belt injury: a case report. *International Journal of Surgery Case Reports*, 38:119-121.

DOI: <https://doi.org/10.1016/j.ijscr.2017.07.029>



Contents lists available at ScienceDirect

## International Journal of Surgery Case Reports

journal homepage: [www.casereports.com](http://www.casereports.com)

## Combined intra- and extraperitoneal urinary bladder rupture – a rare seat-belt injury: A case report



Lisane Grünherz<sup>a,1</sup>, Xenia Startseva<sup>a,1</sup>, Marko Kozomara-Hocke<sup>b</sup>, Borna K. Barth<sup>c</sup>, Hans-Peter Simmen<sup>a</sup>, Ladislav Mica<sup>a</sup>, Thomas Rauer<sup>a,\*</sup>

<sup>a</sup> University Hospital Zurich, Division of Trauma Surgery, Rämistrasse 100, CH-8091 Zurich, Switzerland

<sup>b</sup> University Hospital Zurich, Department of Urology, Rämistrasse 100, CH-8091 Zurich, Switzerland

<sup>c</sup> University Hospital Zurich, Institute of Diagnostic and Interventional Radiology, Rämistrasse 100, CH-8091 Zurich, Switzerland

## ARTICLE INFO

## Article history:

Received 27 April 2017

Received in revised form 13 July 2017

Accepted 15 July 2017

Available online 22 July 2017

## Keywords:

Traumatic urinary bladder rupture

Blunt abdominal trauma

Abdominal seat-belt injuries

## ABSTRACT

**INTRODUCTION:** While isolated traumatic urinary bladder injuries are rare, combined intra- and extraperitoneal traumatic urinary bladder ruptures without an underlying fracture are an absolute rarity.

**PRESENTATION OF CASE:** We report a case of combined intra- and extraperitoneal urinary bladder rupture without an underlying fracture resulting from blunt abdominal trauma during a high velocity car accident. A midline laparotomy was performed, and the intra- and extraperitoneal bladder ruptures were surgically treated.

**DISCUSSION:** Based on the presented case the anatomical peculiarities of the urinary bladder and the different trauma mechanisms as well as the resulting lesions, the diagnostic modalities and the treatment options are discussed.

**CONCLUSION:** Despite the rarity of traumatic urinary bladder injuries, and especially in the absence of an underlying fracture, physicians should maintain a high level of suspicion for urologic injuries in the presence of nonspecific lower abdominal pain, gross haematuria and the inability to urinate.

© 2017 The Authors. Published by Elsevier Ltd on behalf of IJS Publishing Group Ltd. This is an open access article under the CC BY-NC-ND license (<http://creativecommons.org/licenses/by-nc-nd/4.0/>).

### 1. Introduction

The present work has been reported in line with the SCARE criteria [1].

The urinary bladder is a muscular hollow organ which is well protected against external trauma due to its location deep in the bony pelvis [2]. Hence, traumatic urinary bladder injuries (TBR) are rare, representing only 0.87–1.6% of all blunt abdominal trauma cases [3,4]. They usually result from blunt or penetrating trauma. Up to 90% of TBR are associated with pelvic fractures of which only 5–8% are combined intra- and extraperitoneal bladder ruptures (CBR) [2]. A CBR without an underlying fracture is an absolute rarity. Timely diagnosis and appropriate therapy of urinary bladder ruptures are associated with the postoperative morbidity [2,5].

In this paper, we present a rare case of an isolated CBR as a result of a seat-belt injury.

### 2. Case report

A haemodynamically stable 37-years old seat-belt fastened driver with an uneventful medical history was admitted to the resuscitation room of a Level-I trauma center with a delay of 40 min after a high velocity road traffic accident. While being fully conscious, reaching 15 points according to the Glasgow coma scale, the patient suffered from symptoms of an acute abdomen. The primary survey revealed a haemodynamically stable patient showing abdominal tenderness and bruises in the lower abdomen (“seat-belt sign”). On examination there was no clinically sign of pelvis instability. The laboratory parameters and vital signs are presented in Table 1.

A whole-body, multiphase, multiple detector computed tomography (MDCT) showed fluid within the peritoneal cavity (radiodensity 10–20 HU) and the space of Retzius (Fig. 1), a finding consistent with intra- and extraperitoneal urinary bladder ruptures. However, there was no evidence of fractures or further injuries to the parenchymatous or hollow organs. In the absence of any signs of urethral injury, a Foley catheter was placed revealing gross haematuria. Afterwards midline laparotomy was performed and revealed large amounts of mainly clear and slightly bloody fluid in the spatium rectovesicale. While no further injuries of the parenchymatous or hollow organs were detected, the urinary bladder showed a CBR with a 2 cm long intraperitoneal (Fig. 2) and

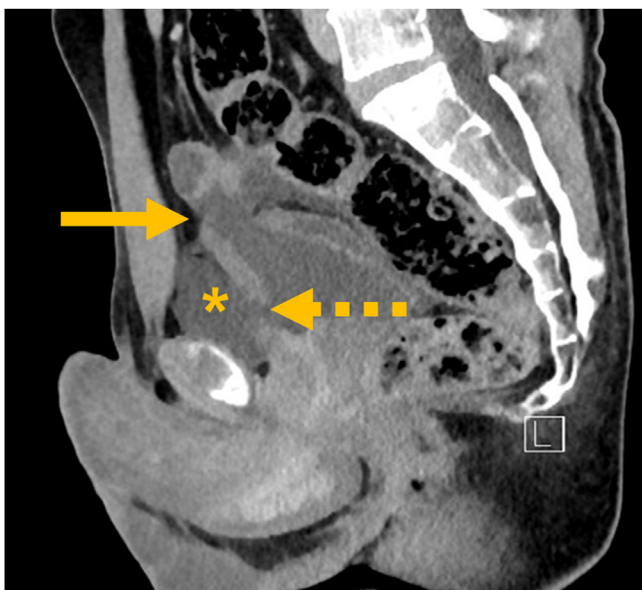
\* Corresponding author.

E-mail address: [thomas.rauer@usz.ch](mailto:thomas.rauer@usz.ch) (T. Rauer).

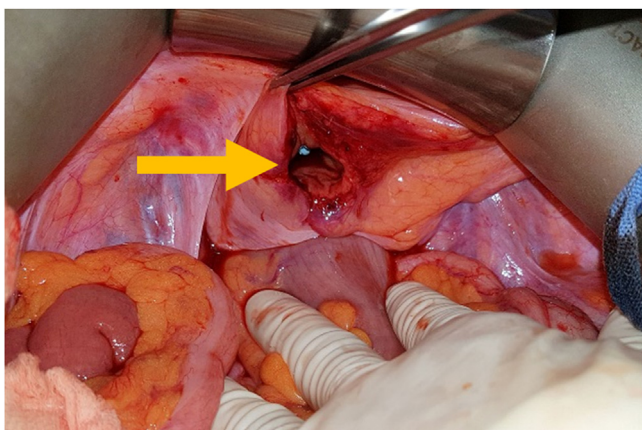
<sup>1</sup> First author.

**Table 1**  
Laboratory and vital parameters at admission in the resuscitation room in alphabetical order. INR: International Normalized Ratio.

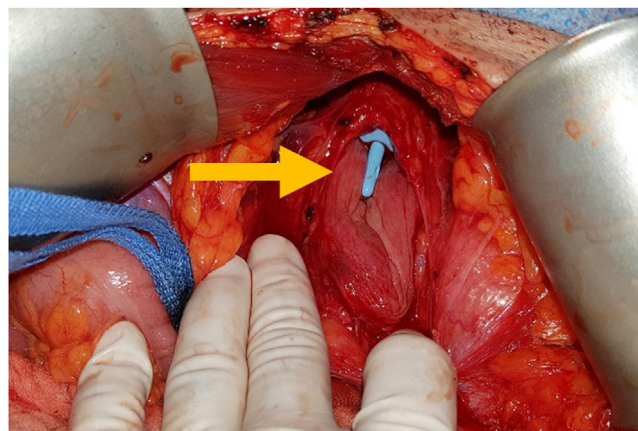
Parameter	Value at admission
Blood pressure	128/71 mm Hg
Hematocrite	0.422%
Hemoglobin	145 g/L
INR	1.1
Lactate	1.4 mmol/L
Lactate Dehydrogenase	313 U/L
Myoglobin	275 µg/L
Pancreatic amylase	40 U/L
Potassium	4.0 mmol/L
Pulse rate	83 bpm
Respiratory rate	15/min
Sodium	142 mmol/L



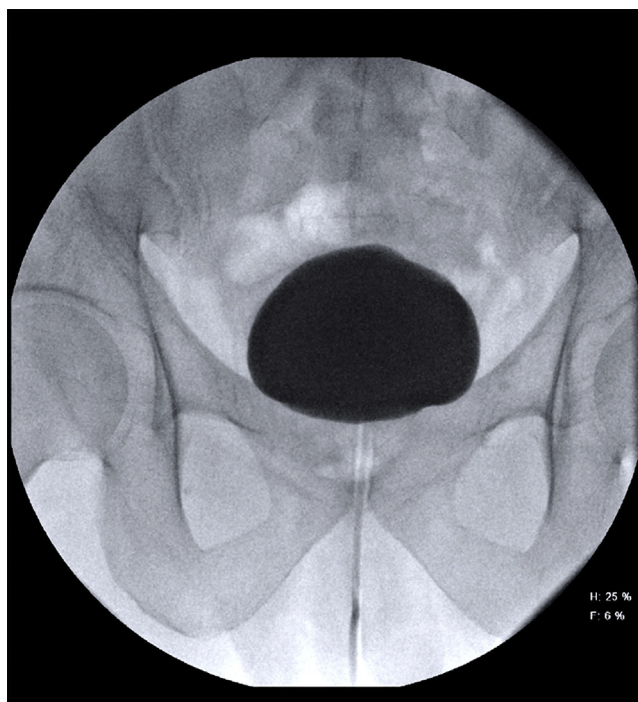
**Fig. 1.** Whole-body multiphase MDCT. The sagittal image reconstruction shows the location of the intraperitoneal bladder rupture (straight arrow), extraperitoneal bladder rupture (dotted arrow) and fluid in the space of Retzius (asterisk).



**Fig. 2.** Intraoperative view of the intraperitoneal bladder rupture (arrow).



**Fig. 3.** Intraoperative view of the extraperitoneal bladder rupture (arrow).



**Fig. 4.** Inconspicuous cystography three weeks postoperatively.

a 3 cm long extraperitoneal full thickness rupture (Fig. 3), which were repaired with a two-layer absorbable suture. Postoperatively, the initial cystography after 10 days showed a questionable dorsal leakage, so the Foley catheter remained in place for another two weeks and was removed after inconspicuous cystography (Fig. 4).

**3. Discussion**

The most common abdominal injuries following blunt abdominal trauma are liver and splenic injuries [6]. Due to its location deep in the bony pelvis the urinary bladder is well protected against external forces [2]. For this reason TBR are rare, representing only 0.87–1.6% of all blunt abdominal trauma cases [3,4]. The injury mechanisms of TBR are various: a) primary, due to a direct blow to a distended bladder, while there is a direct correlation between bladder distension and the extent of injury [7,8]; b) secondary, due to shearing forces during high-energy blunt abdominal trauma leading to pelvic fracture; c) due to penetrating injuries and d) due to various iatrogenic causes [2]. Traumatic urinary bladder injuries are classified in bladder contusions (i.e., damage to mucosa or muscularis without full-thickness lesion), intraperitoneal (IBR) or extraperitoneal ruptures (EBR) [2]. Up to 60% of all TBR are extraperitoneal and around 25% are intraperitoneal [9]. Approximately 10% of the pelvic fractures are associated with TBR [9], but 89% to 100% of the EBR are associated with pelvic fractures [10]. In



the presence of an underlying pelvic fracture only 5–8% of all TBR are CBR [2], while isolated CBR are even more seldom. The injury mechanism of IBR is a direct blow to the lower abdomen with a distended bladder, for example caused by a seat-belt injury, as seen in the presented case. In this constellation, the urinary bladder will rupture at its anatomically weakest point, the apex vesicae [5,8].

The clinical presentation of TBR is variable ranging from non-specific lower abdominal pain to symptoms of an acute abdomen. Characteristic symptoms are gross haematuria and the inability to urinate [5]. Patients may show signs of pelvic fractures or only bruising and friction burns (“seat-belt sign”), as a hint of a blunt abdominal trauma. The diagnostic modalities in patients with suspected TBR are bedside ultrasound [8], static or CT cystogram [2], whereby CT cystography is considered as the method of first choice in patients with suspected bladder injury with a sensitivity of 95% and specificity of 100% [11,12]. The whole-body CT is an excellent imaging tool for multiple injured patients, and its diagnostic superiority to other diagnostic methods has been described previously [13,14]. However, the standard contrast-enhanced CT alone is not sufficient to exclude a TBR [2]. In the presented case the whole-body standard contrast-enhanced CT detected a CBR, so a CT cystography was no longer necessary and surgical treatment was indicated. Surgical repair with absorbable suture is the standard of care in IBR, whereby there is no consent whether two-layer closure is superior to single layer closure in open urinary bladder repair [4]. Depending on the extent of the injury, isolated EBR is managed mainly nonsurgical with urinary catheter drainage for 10 days to 3 weeks [2]. However, the recent literature recommends cystorrhaphy for complicated EBR, and in cases of explorative laparotomy for non-urological indications as well as in cases of open repair of pelvic fractures [15,16].

As the coexistence of a seat-belt sign and abdominal pain is associated with an increased risk of intraabdominal injuries [17] and considering the high mortality rates of TBR, ranging from 11% to 22% [4,18], an immediate and adequate diagnostic approach followed by an appropriate therapy is indicated, while physicians should maintain a high level of suspicion for urologic injuries following blunt abdominal trauma.

#### 4. Conclusion

The presented case emphasizes the importance of the initial clinical assessment during resuscitation room management with a high level of suspicion for urologic injuries following blunt abdominal trauma, even in the absence of an underlying pelvic fracture.

#### Conflict of interest

No conflict of interest.

#### Funding

No source of funding.

#### Ethical approval

Not applicable.

#### Consent

Written informed consents was obtained from the patient for publication of this case report and any accompanying images.

We also ensure that we state in our introduction that the work has been reported in line with the SCARE criteria and we cite the following paper: Agha RA, Fowler AJ, Saetta A, Barai I, Rajmohan S, Orgill DP, for the SCARE Group. The SCARE Statement: Consensus-based surgical case report guidelines. International Journal of Surgery 2016.

#### Author contribution

Lisanne Grünherz: wrote the manuscript.

Xenia Startseva: wrote the manuscript.

Marko Kozomara-Hocke: co-operated the patient; reviewed the manuscript.

Borna K. Barth: radiologist, evaluated the CT images; reviewed the manuscript.

Hans-Peter Simmen: reviewed the manuscript.

Ladislav Mica: reviewed the manuscript.

Thomas Rauer: operated the patient; took the photographs; wrote the manuscript.

#### Guarantor

Dr. med. Thomas Rauer.

#### References

- [1] R.A. Agha, et al., The SCARE statement: consensus-based surgical case report guidelines, *Int. J. Surg.* 34 (2016) 180–186.
- [2] R. Gomez, et al., Consensus statement on bladder injuries, *BJU Int.* 94 (1) (2004) 27–32.
- [3] P.O. Udekwe, B. Gurkin, D.W. Oller, The use of computed tomography in blunt abdominal injuries, *Am. Surg.* 62 (1) (1996) 56–59.
- [4] R.J. Urry, et al., The incidence: spectrum and outcomes of traumatic bladder injuries within the Pietermaritzburg Metropolitan Trauma Service, *Injury* 47 (5) (2016) 1057–1063.
- [5] C. Protzel, O.W. Hakenberg, Diagnosis and treatment of lower urinary tract trauma, *Der Unfallchirurg* 113 (4) (2010) 313–324, quiz 325.
- [6] J. Stuhlfaut, et al., Blunt abdominal trauma: utility of 5-minute delayed CT with a reduced radiation dose, *Radiology* 238 (2) (2006) 473–479.
- [7] J.N. Corriere, C.M. Sandler, Bladder rupture from external trauma: diagnosis and management, *World J. Urol.* 17 (2) (1999) 84–89.
- [8] T. Wu, et al., Bedside ultrasound diagnosis of a traumatic bladder rupture, *J. Emerg. Med.* 41 (5) (2011) 520–523.
- [9] P.R. Carroll, J.W. McAninch, Major bladder trauma: mechanisms of injury and a unified method of diagnosis and repair, *J. Urol.* 132 (2) (1984) 254–257.
- [10] B. Cornelius, Traumatic bladder laceration in the absence of pelvic fracture, *J. Trauma Nurs.* 16 (1) (2009) 24–26.
- [11] A.J. Deck, et al., Current experience with computed tomographic cystography and blunt trauma, *World J. Surg.* 25 (12) (2001) 1592–1596.
- [12] C. Ishak, N. Kanth, Bladder trauma: multidetector computed tomography cystography, *Emerg. Radiol.* 18 (4) (2011) 321–327.
- [13] L. Geyer, et al., Incidence of delayed and missed diagnoses in whole-body multidetector CT in patients with multiple injuries after trauma, *Acta Radiol.* 54 (5) (2013) 592–598.
- [14] S. Huber-Wagner, et al., Effect of whole-body CT during trauma resuscitation on survival: a retrospective, multicentre study, *Lancet* 373 (9673) (2009) 1455–1461.
- [15] N. Johnsen, et al., Evaluating the role of operative repair of extraperitoneal bladder rupture following blunt pelvic trauma, *J. Urol.* 195 (3) (2016) 661–665.
- [16] A. Morey, et al., Urotrauma: AUA guideline, *J. Urol.* 192 (2) (2014) 327–335.
- [17] D. Borgianni, et al., Association between the seat belt sign and intra-abdominal injuries in children with blunt torso trauma in motor vehicle collisions, *Acad. Emerg. Med.* 21 (11) (2014) 1240–1248.
- [18] K. Matlock, et al., Blunt traumatic bladder rupture: a 10-year perspective, *Am. Surg.* 79 (6) (2013) 589–593.

#### Open Access

This article is published Open Access at [sciencedirect.com](https://www.sciencedirect.com). It is distributed under the [IJSCR Supplemental terms and conditions](#), which permits unrestricted non commercial use, distribution, and reproduction in any medium, provided the original authors and source are credited.