



<b>Title</b>	<b>Common urological problems in children: inguinoscrotal pathologies</b>
<b>Author(s)</b>	<b>Chan, HYI; Wong, KKY</b>
<b>Citation</b>	<b>Hong Kong Medical Journal, 2017, v. 23 n. 3, p. 272-281</b>
<b>Issued Date</b>	<b>2017</b>
<b>URL</b>	<b><a href="http://hdl.handle.net/10722/245315">http://hdl.handle.net/10722/245315</a></b>
<b>Rights</b>	<b>Hong Kong Medical Journal. Copyright © Hong Kong Academy of Medicine Press.; This work is licensed under a Creative Commons Attribution-NonCommercial-NoDerivatives 4.0 International License.</b>

# Common urological problems in children: inguinoscrotal pathologies

Ivy HY Chan, Kenneth KY Wong \*

## ABSTRACT

Urological problems in children are often encountered in general clinical practice. This review forms the second paper of our series on common urological problems in children about inguinoscrotal pathologies. We aimed to provide concise information for doctors who are unfamiliar with this topic.

Hong Kong Med J 2017;23:272–81

DOI: 10.12809/hkmj165061

IHY Chan, FRCSEd(Paed), FHKAM (Surgery)

KKY Wong \*, PhD, FHKAM (Surgery)

Division of Paediatric Surgery, Department of Surgery, The University of Hong Kong, Queen Mary Hospital, Pokfulam, Hong Kong

\* Corresponding author: kkywong@hku.hk

This article was published on 5 May 2017 at www.hkmj.org.

## Introduction

Our previous review paper described and discussed disorders of the prepuce.<sup>1</sup> In this paper, we focus on common inguinoscrotal pathologies in children. Inguinal hernia/hydrocoele, undescended testis, acute scrotum, and varicocele will be discussed. These have a broad disease spectrum, but may have similar clinical presentation and may be discovered by parents, during routine paediatric assessment or incidentally in the clinic. Despite advances in medical technology, proper history taking, physical examination, and understanding of these conditions remain crucial for management and specialist referral.

## Inguinal hernia/hydrocoele

These two conditions account for most of the pathologies in the inguinoscrotal region in children. For paediatric inguinal hernia, the cumulative incidence was reported to be 6.62% in boys up to 15 years old in a nationwide study in Taiwan: one in 15 boys would develop inguinal hernia before the age of 15 years.<sup>2</sup>

Both inguinal hernia and hydrocoele occur because of non-closure of the processus vaginalis (patent processus vaginalis). The processus vaginalis forms an extension of the peritoneum during the time of testicular descent into the scrotum in the fetus. It normally undergoes fusion or closure when testicular descent is complete. Failure to close may result in either inguinal hernia or hydrocoele, depending on the size of the defect. If it remains patent or unfused in girls, it becomes the canal of Nuck and may also result in inguinal hernia (Fig 1).

The incidence of inguinal hernia is highest in children under 1 year of age and thereafter decreases.<sup>2</sup> In premature babies, the incidence is even higher with babies born less than 32 weeks of gestation having a reported incidence of 9.34%.<sup>3</sup>

Right-sided hernias are more common (ratios of right, left, and bilateral hernia are approximately 59%, 29%, and 12%, respectively).<sup>4</sup> Boys are affected around 10 times more often than girls<sup>2</sup>; 99% of inguinal hernias in children are of the indirect type.<sup>4</sup>

Hydrocoele is an abnormal collection of fluid along the processus vaginalis, and can be communicating or non-communicating. In communicating hydrocoele, there is a patent processus vaginalis. Non-communicating hydrocoele includes scrotal hydrocoele and hydrocoele of cord, and here the processus vaginalis is obliterated with the collection of fluid in the tunica vaginalis. Hydrocoele can present in infants or older children and its management differs. For hydrocoele that presents before 1 year of age, there is a 62.7% to 89% chance of spontaneous complete resolution or significant improvement,<sup>5-7</sup> with the mean time of resolution being about 6 months. Thus, it is worth allowing a period of time to observe a hydrocoele provided other conditions like inguinal hernia or testicular pathology have been excluded.

## Clinical features

Parents usually notice the inguinoscrotal pathology in their child during bathing or changing nappies. A painless bulge over the inguinal region or even down to the scrotum may be seen in boys, or a bulge over the vulva in girls with inguinal hernia. The bulge will increase in size when the child cries and decrease when lying down. A proper clinical examination may not be easy in the clinic setting for children and the hernia may not be apparent. A well-taken clinical history is very important in making the correct diagnosis. An 'intermittent inguinal swelling' may indicate an inguinal hernia. A static painless scrotal swelling may indicate a scrotal/encysted hydrocoele.

For children who cooperate, the upper and lower extent of the inguinoscrotal mass should be

carefully examined. The upper extent of an inguinal hernia should start at the internal ring, that is, the midpoint between the pubic tubercle and anterior superior iliac spine. For scrotal/encysted hydrocoele, clinicians should be able to get above the lesions. A transillumination test is a very helpful in adults but is not reliable in infants/small children. Because of the thin bowel wall the transillumination test can also be positive in infants/small children with inguinal hernia.

Pain and inconsolable crying in a child with a tender irreducible inguinal bulge may indicate an incarcerated inguinal hernia. A younger child is more likely to be affected. The mean age of hernia incarceration was shown to be 1.5 years in a previous study.<sup>4</sup> The incidence of incarceration is 3 times higher in premature babies with inguinal hernia.

Very often, parents may not be able to describe the clinical features properly and no pathology can be demonstrated during a clinic visit. We suggest that parents take a clinical photo using mobile phones at home, which can be shown to the doctor during the subsequent clinic visit.

### Investigations

Diagnosis of an inguinal hernia depends largely on clinical history and physical examination. Different imaging techniques can sometimes be helpful in making the diagnosis. Contrast herniography is only of historical interest because of its invasiveness. Ultrasonography (USG) of the inguinal canal to detect occult inguinal hernia has been described and its use varies in different countries. Studies show that the preoperative USG can decrease the future risk of developing metachronous inguinal hernia.<sup>8</sup> A positive finding on USG strongly correlates with positive operative findings.<sup>9,10</sup> Nonetheless as the

## 常見的小兒泌尿系統問題：腹股溝陰囊病症

陳巧兒、黃格元

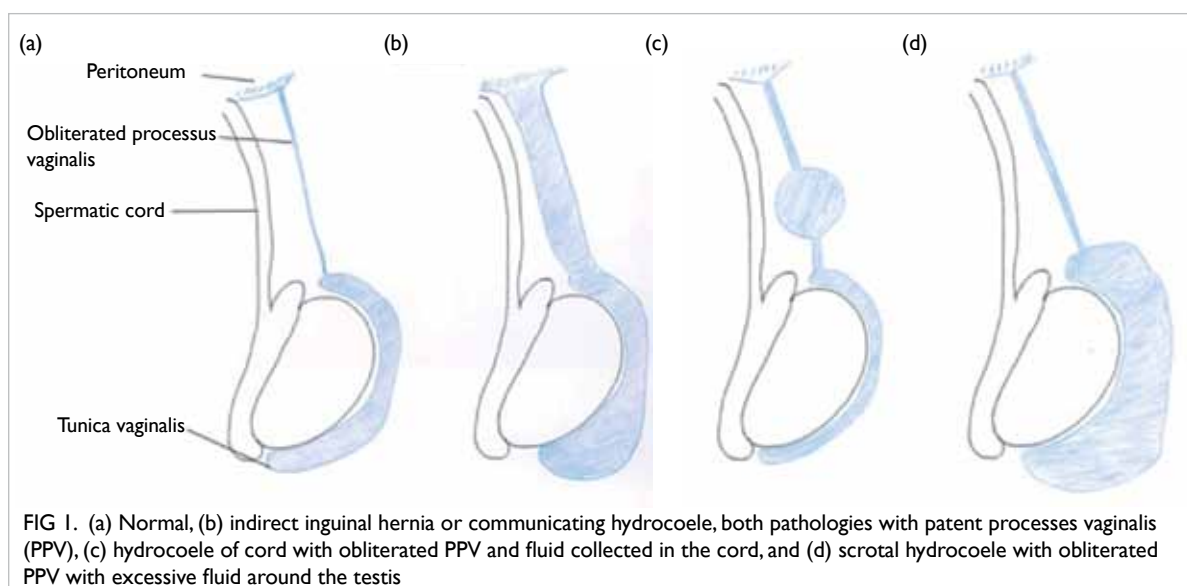
一般臨床病症中經常遇到小兒泌尿的問題。本文是常見小兒泌尿系統問題系列的第二篇文章，旨在為不熟悉腹股溝陰囊病症的醫生提供簡明的信息和指引。

accuracy of USG is largely operator-dependent, we feel that while a positive USG finding is strongly suggestive of a clinical hernia, a negative finding should be interpreted with care. Diagnosis of inguinal hernia will very much depend on clinical examination. Of note, USG of the inguinal canal is not a routine procedure when making a diagnosis of inguinal hernia. It may serve as an adjunct when there is doubt about incarcerated hernia versus hydrocoele of cord or concern about underlying testicular pathology for hydrocoele.

### Indications and timing of surgery

Once the diagnosis of inguinal hernia is made, operation is indicated regardless of age due to the risk of incarceration, with a reported rate of approximately 4.19% to 8.2%.<sup>2,11</sup> As young children and infants have a higher risk of incarceration, it may be wise to arrange earlier operation. Surgery, however, should still be arranged as early as possible in an otherwise healthy child.

For the management of premature babies with inguinal hernia, there are many factors that should be taken into consideration such as postoperative apnoea, respiratory distress, co-morbidities (eg chronic lung disease in premature babies), and risk of incarceration. There is always debate about the



optimal timing of hernia repair in premature babies, that is, surgery just before discharge from neonatal intensive care unit or when the child is older. Although a long waiting time is associated with higher risk of incarceration in infants and premature babies, and emergency repair in patients with incarceration is associated with a higher likelihood of testicular atrophy,<sup>12-14</sup> surgery is less technically demanding in older babies. Fewer perioperative morbidities are also observed when performing surgery later. Early inguinal hernia repair is associated with prolonged hospital stay and prolonged intubation.<sup>15</sup> A study from Hong Kong reported one (1.3%) incarceration in 79 premature patients with a mean body weight at operation of 4360 g.<sup>16</sup> This incarceration rate is relatively lower when compared with other studies—9% to 21% by Lautz et al<sup>13</sup> from the United States, and 5.2% to 10.1% by Zamakhshary et al<sup>12</sup> from Canada. It is likely to be due to the shorter travelling time between a patient's home and hospital in Hong Kong. Based on our experience, it is reasonable in Hong Kong to wait for surgery until premature babies have achieved a reasonable body weight. Parents should be taught how to observe the symptoms and signs of incarceration before discharge. If the patient lives unreasonably far from the hospital and parents are not able to observe the symptoms and signs of incarceration, earlier surgery should be offered. From our perspective, we would offer repair when the patient's body weight reaches 2.5 kg, provided there are no other indications for earlier or delayed repair.

As mentioned earlier, there is a high chance of spontaneous resolution of infantile hydrocoele during the first year of life. Patients should therefore be observed and monitored in the first 1 to 2 years of life.<sup>5,6</sup> Parents should also be taught about the symptoms and signs of inguinal hernia during this observation period as an inguinal hernia may present as a communicating hydrocoele on first sight. Patients with persistent hydrocoele, giant or symptomatic hydrocoele, hydrocoele associated with inguinal hernia or other conditions (eg presence of ventriculoperitoneal shunt), or who require peritoneal dialysis should be offered surgery.

### Open versus laparoscopic surgery

Open high ligation of patent processus vaginalis was the mainstay of treatment for both inguinal hernia and hydrocoele in children until the advent of laparoscopic surgery. Different laparoscopic techniques are largely categorised into intracorporeal or extracorporeal ligation of the patent processus vaginalis.<sup>17-19</sup> Benefits of laparoscopic surgery include the possible visualisation of the contralateral deep ring and better cosmetic outcome. Yet it may incur a higher set-up cost or longer operating time.

Two recent systematic reviews/meta-

analyses showed very similar results when comparing open and laparoscopic inguinal hernia repair in children.<sup>17,20</sup> Both studies showed no significant difference in recurrence rate. Esposito et al<sup>17</sup> reported a 1.4% recurrence rate following laparoscopic repair and 1.6% following open repair. For operating time, they noted a significantly shorter time for laparoscopic repair of bilateral hernia when compared with an open approach. There was no difference for unilateral hernia repair. Feng et al<sup>20</sup> reported that a laparoscopic extraperitoneal method had a much shorter operating time in both unilateral and bilateral hernia repair. Lower pain scores were also reported in two randomised controlled trials for laparoscopic repair.<sup>21,22</sup>

Feng et al<sup>20</sup> further showed more testicular complications in open repair. Another retrospective review showed similar results.<sup>23</sup> Of note, a higher recurrence rate of up to 3.4% for laparoscopic repair was observed in the early era of laparoscopic surgery.<sup>18</sup> There is no consensus, however, on whether a laparoscopic or open approach is superior.

In contrast to laparoscopic inguinal hernia repair, laparoscopic repair of hydrocoele has not received the same popularity, with open high ligation still being the mainstay of treatment. Indeed, only a handful of studies can be found in the literature. One reason may be the belief that the deep ring is already closed. A recent study noted that 97% of patients with a clinically non-communicating hydrocoele had a patent processus vaginalis during laparoscopy.<sup>24</sup> Among the small number of reports, Saka et al<sup>19</sup> showed no significant difference in terms of outcome between open and laparoscopic repair of hydrocoele.

### Contralateral exploration

Metachronous contralateral inguinal hernia (MCH)—presence of contralateral inguinal hernia—may present in some patients after successful repair of inguinal hernia. An initial presentation with left-sided hernia,<sup>25-27</sup> and prematurity are risk factors for MCH.

Before the era of laparoscopy, USG of the groin or routine contralateral exploration were suggested by some surgeons to reduce the risk of MCH and the need for second operation/anaesthesia. Miltenburg et al<sup>28</sup> reviewed the use of laparoscopic evaluation and concluded that it could successfully decrease the incidence of MCH.

Today, routine examination during laparoscopic hernia repair has shown the rate of contralateral patent processus vaginalis (CPPV) to be 30% to 39.7%.<sup>25,29</sup> Yet, a meta-analysis revealed that only 6% of all patients returned with MCH after unilateral inguinal hernia repair.<sup>26</sup> Thus, the presence of CPPV does not necessarily equate to subsequent clinical inguinal hernia. Kokorowski et

al<sup>29</sup> concluded that patent processus vaginalis might be over-treated. Repair of the patent processus vaginalis will definitely decrease the risk of MCH, the costs, and the risk of future hernia incarceration. On the other hand, it also carries an operative risk of vas injury, haematoma, and infection of the contralateral side. In view of the uncertainties about the overall balance of risks and benefits of routine prophylactic repair of CPPV, parents should be counselled on the benefits of avoiding potential future development of clinical hernia and the risks of the procedure.

## Undescended testis (cryptorchidism)

Cryptorchidism has an estimated incidence of 22.8 per 10000 live births.<sup>30</sup> It remains an important condition because of its potential sequelae of sub-fertility, testicular malignancy, and accompanying inguinal hernia.

### Embryology and pathophysiology

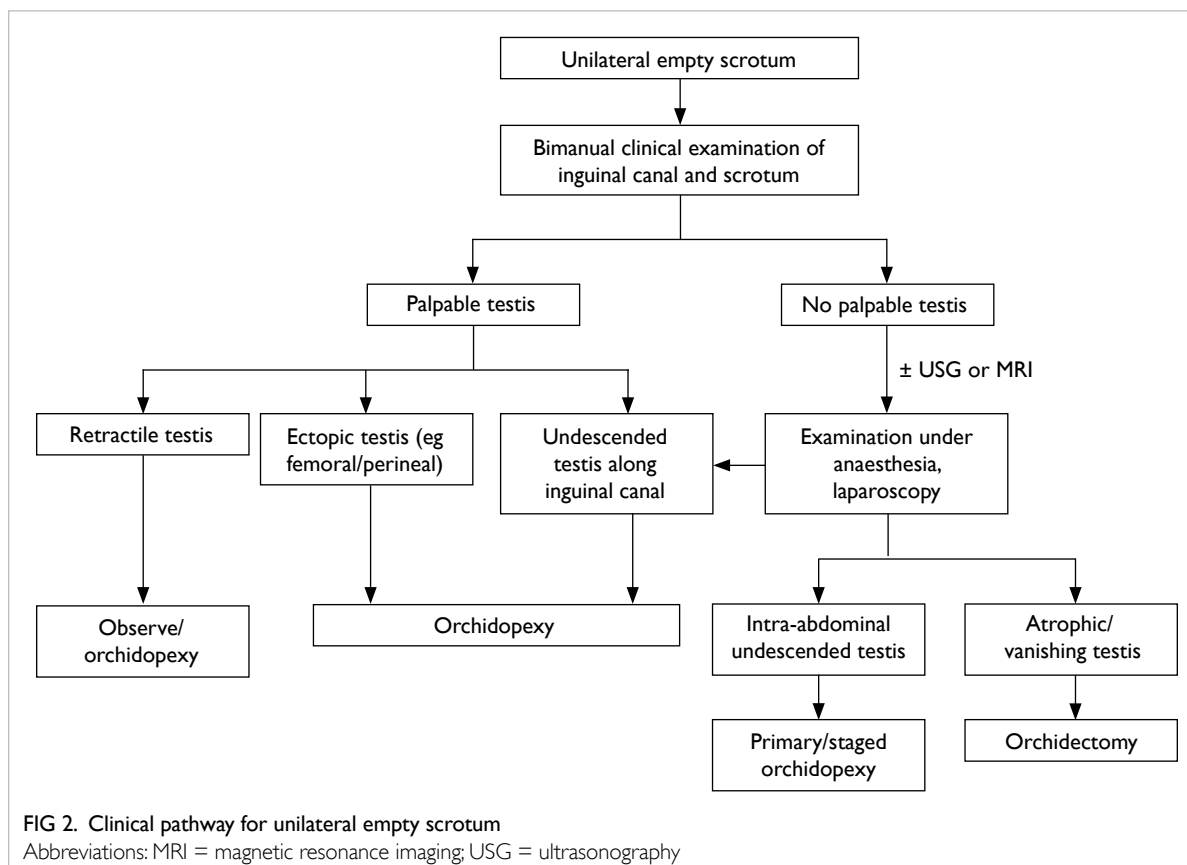
Testicular descent is a complex process. Male differentiation starts at around 7 to 8 weeks of gestation under the influence of the *SRY* gene. Testicular descent involves two phases, the transabdominal phase and the inguinoscrotal phase. The gonad descends from the area near the

urogenital ridge to the level of the deep ring in the transabdominal phase. This phase ends at around 15 weeks of gestation. The inguinoscrotal phase is a more complex process in which the peritoneal membrane bulges out and elongates to form the processus vaginalis through which the testes then descend. This phase usually starts at around 25 weeks and ends at 35 weeks of gestation. After descent, the testes will anchor to the connective tissue within the scrotum.

Both phases of testicular descent are controlled by hormones. Any derangement in the pathway can result in cryptorchidism. Conditions known to be associated with cryptorchidism include prematurity, Klinefelter syndrome, and abdominal wall defects like omphalocele. There is no single cause that can be identified to account for all the scenarios of cryptorchidism.

### Clinical evaluation

Cryptorchidism is mostly diagnosed by history and proper clinical examination (Fig 2). As most newborns will undergo a clinical examination before discharge from hospital, the position of the testes should be ascertained. During clinical examination, the infant should be placed supine with legs abducted in a relaxed and warm environment. A cold environment may induce a cremasteric reflex



that may move the testes up. Bimanual examination (two-handed technique) should be performed. The doctor's left hand should be placed at the deep ring and gently sweep along the inguinal canal down to the scrotum. The right hand should try to detect the testes at the scrotum or the lowest possible position. Size, mobility, and consistency of the testes should be assessed. If there are no palpable testes, a potential location of ectopic testes should be sought such as the femoral canal or perineum. The suprapubic region should be examined as well. Both sides should be examined carefully with the same technique. Other concurrent urological anomalies (eg hypospadias) or problems other than undescended testes (eg disorder of sexual differentiation) should be checked. These may warrant further in-depth investigations or indicate a need for urgent karyotyping in the newborn period.

A retractile testis should be distinguished from genuine undescended testis. The clinician should be able to bring the retractile testis down to the scrotum and the testis should stay in the scrotum for a while. It may retract with the cremasteric reflex. Patients with retractile testes should have normal testicular volume and fertility. If there is doubt about the diagnosis, regular assessment or scrotal orchidopexy can be offered.

Ascending testis is a condition in which the testis was previously within the scrotum but later ascends. Presence is usually associated with a history of retractile testis. The postulation is that the spermatic cord does not elongate with age. These patients usually present late. A history of previously noted testicular position should be sought. It has been shown that ascending testis shares a similar histopathology to congenital undescended testis.<sup>31</sup> Orchidopexy is also recommended.

### Investigations

Surgical approach for the undescended testis differs depending on the location of the testis. The most important factor is whether or not the testis is palpable. Clinicians, however, may not be able to locate the testis during a clinical examination if the child struggles. If the testis is impalpable, conditions such as intra-abdominal testis, atrophic testis, and ectopic testis should also be considered. Ultrasonography can be used to detect the location and size of the testis.<sup>32</sup> Nijs et al<sup>33</sup> noted a high sensitivity of USG scan for inguinal testis but very low sensitivity for intra-abdominal testis. They suggested laparoscopic exploration when the testis cannot be detected on physical examination and USG.<sup>33,34</sup>

Use of gadolinium-enhanced magnetic resonance angiogram was described in 1998 as another investigation for undescended testes with high sensitivity and specificity.<sup>35</sup> In another

study published in 2000 that compared magnetic resonance imaging (MRI) with laparoscopy in non-palpable testes, the false-positive rate of MRI was 32% and true-positive rate for laparoscopy was 100%.<sup>36</sup> As MRI is also limited by its costs, availability and potential need for general anaesthesia in a small child, many clinicians prefer laparoscopy as the method of choice for impalpable testis. Nonetheless there may still be a role for MRI in patients with suspected persistent Müllerian structures or a disorder of sexual differentiation.<sup>37</sup>

Nowadays, early operation on undescended testis is advocated to reduce the risk of malignancy and potentially preserve fertility. Early referral to a surgical specialist may be more important than investigations. The guideline from American Urological Association (AUA) published in 2014 advised that health care providers should not perform USG or other imaging modalities in the evaluation of boys with cryptorchidism prior to referral, as these studies rarely assist in decision making by the general practitioner.<sup>38</sup>

### Treatment

As testicular descent will continue after birth, watchful waiting should be the initial management of undescended testes. However, it is advised that all patients with undescended testis discovered at birth be re-examined at 6 months of age and referral made to a specialist if the condition persists.<sup>38</sup>

A study performed in 1974, which compared the histology of those with undescended testes before and after 2 years of age,<sup>39</sup> showed loss of spermatogonia in patients with undescended testis after 2 years of age. Another study also showed that the uncorrected position of undescended testes was associated with ongoing germ cell damage and later fertility problems and risk of malignancy.<sup>40</sup> Thus, orchidopexy is advised before 18 months of age.

The surgical plan for undescended testes will be dictated by the position and size of the testis. For palpable testis in the inguinal canal, inguinal orchidopexy should be performed. If no palpable testis can be identified during clinical examination, adjunct imaging studies in an attempt to locate the testis can be ordered before surgery. Laparoscopy, however, remains the gold standard in diagnosing clinically impalpable testis. In most cases the testis is located along the line of normal testicular descent, intra-abdominally or just at the deep ring of the inguinal canal. Rarely, the testis can also be atrophic, ectopic, or even absent. Three approaches have been described for intra-abdominal testes: primary orchidopexy, one-stage Fowler-Stephens orchidopexy, or two-stage Fowler-Stephens orchidopexy. Short testicular vessels are postulated to be the reason why the testis cannot be brought to the scrotum. The Fowler-Stephens



procedure involves the division of testicular vessels and repositioning of the testis to the scrotum, either immediately during the procedure (one-stage) or 6 months later (two-stage). The vascular supply will depend on the cremasteric vessels and collateral vessels to the vas after this procedure. Testicular atrophy and ascent (incidence of both approximately 8%) are potential complications of this procedure.<sup>41</sup>

On the subject of alternative therapy, the AUA guideline advises against using hormone therapy to induce testicular descent as evidence shows low response rates and a lack of evidence for long-term efficacy.<sup>38</sup>

### Prognosis/long-term outcome

Patients should be counselled about the increased risk of testicular malignancy and subfertility.<sup>40</sup> A histological study of the undescended testes in human fetuses, neonates, and infants showed that the absolute number of germ cells was decreased.<sup>42</sup> Mengel et al<sup>39</sup> noted a significant decrease in the content of spermatogonia and a lack of tubular growth at the beginning of the third year of life. Lee and Coughlin<sup>40</sup> compared paternity rates, the semen and hormone profiles of patients with previously unilateral undescended testes, bilateral undescended testes and normal control subjects; the paternity rates of these three groups of subjects were 89.7%, 65.3% and 93.2%, respectively. Historical studies have indicated improved fertility in patients who had orchidopexy at an earlier age.<sup>43</sup>

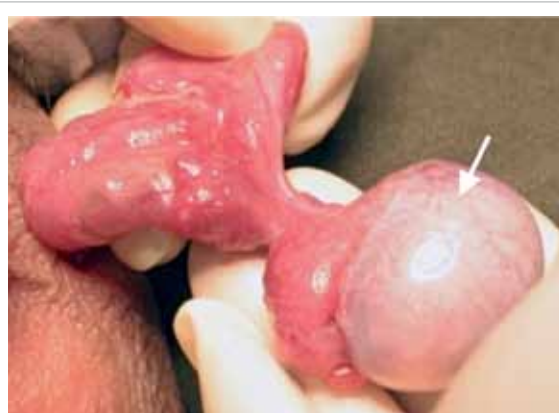Undescended testis is a known risk factor for testicular germ cell tumour. In a meta-analysis, Dieckmann and Pichlmeier<sup>44</sup> showed a relative risk of 4.8 compared with the normal population. The age at which orchidopexy is performed is also important. Pettersson et al<sup>45</sup> compared the risk of testicular malignancy between patients who received early or late orchidopexy and showed the relative risk of testicular cancer among those who underwent orchidopexy before reaching 13 years of age was 2.23 (95% confidence interval [CI], 1.58-3.06); for those treated at 13 years of age or older, the relative risk was 5.40 (95% CI, 3.20-8.53). It is postulated that the higher surrounding temperature in undescended testis could arrest germ cell maturation and become carcinoma in situ.<sup>46</sup>

### Acute scrotum

Although different disease conditions can present clinically with acute scrotum, testicular torsion should be the top differential diagnosis for all patients, as this condition needs precise clinical appreciation and urgent management. The time from presentation to operation is critical and will determine if the affected testis can be salvaged. A high index of suspicion with immediate referral is

crucial.

A nationwide epidemiological study in Korea showed the incidence of testicular torsion was 2.9 per 100 000 person-years of males younger than 25 years, and with a bimodal age distribution with peak incidence in infancy and adolescents.<sup>47</sup> The salvage rates differ, ranging from 75.7% to 29%.<sup>48,49</sup> The diagnosis of torsion depends mostly on clinical evaluation. Diffuse testicular tenderness, hydrocoele, high-lying testis with transverse lie, and absent cremasteric reflex are clinical signs of torsion. Scrotal exploration should be the management of choice in clinically suspect cases. As exploration may be negative, many clinicians have tried adjunctive methods such as the TWIST (Testicular Workup for Ischemia and Suspected Torsion) clinical scoring system,<sup>49</sup> Doppler USG, nuclear scintigraphy, MRI, or evaluation of testicular oxygen saturation with near-infrared spectroscopy.<sup>50</sup> For Doppler USG, accuracy depends on the skill of the radiologist. Normal intra-testicular perfusion does not exclude the possibility of torsion and there remains a false-negative rate in this modality.<sup>51,52</sup> As a missed diagnosis of testicular torsion is one of the most common medicolegal claims in adolescent patients in the United States,<sup>53</sup> we must stress again the prime importance of clinical evaluation and decision. Nuclear scintigraphy and MRI are not popular for the same reason. Near-infrared spectroscopy is a novel technology that measures testicular oxygen saturation but its accuracy has not been fully validated in a large population. Scrotal exploration involves open examination of the affected testes and a decision on whether to keep or remove the affected testes and also fix the contralateral side. A bell-clapper anomaly may be appreciated during examination of the testes (Fig 3).



**FIG 3. Bell-clapper anomaly**

A congenital anomaly in which the testicle lies horizontally within the tunica vaginalis in the scrotum and is likened to the clapper (gong) inside a bell (arrow). The testicle can move freely on its axis and thus predisposes to higher risk of torsion

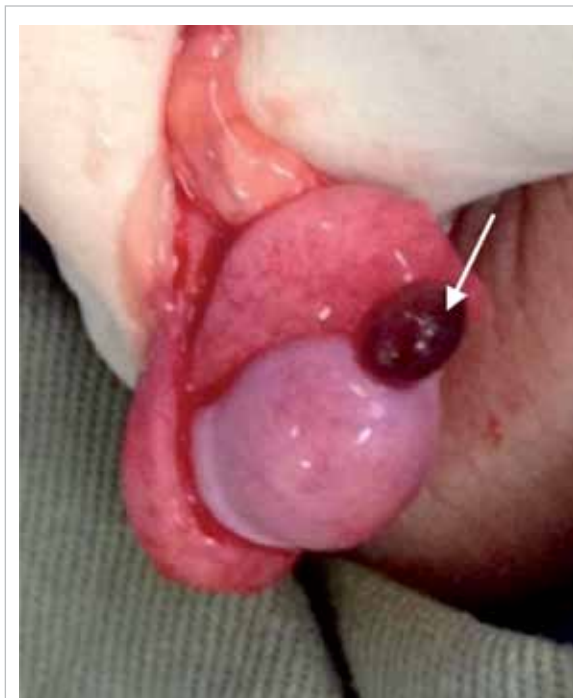Even after successful testicular salvage, testicular atrophy has been reported in almost 50% of patients. Those patients who presented with pain for more than 1 day were more likely to develop testicular atrophy. No testes survived in a patient who presented with pain for more than 3 days.<sup>54</sup>

Other causes of acute scrotum include torsion of the testicular appendage (hydatid of Morgagni), epididymo-orchitis, idiopathic scrotal oedema, incarcerated hernia, or Henoch-Schönlein purpura. Torsion of the testicular appendage presents in a very similar manner to torsion of the testes (Fig 4). The patient also complains of intense scrotal pain. A firm-to-hard pea-sized lesion may be palpable at the head of the epididymis. The classic 'blue dot sign' may also be appreciated. If testicular torsion can confidently be excluded, treatment can be by observation or simple excision of the testicular appendage. Epididymo-orchitis is a form of urinary tract infection. In small children or early adolescence, it may be a presentation of congenital anatomical urinary tract anomalies.<sup>55</sup>

Overall we advise general practitioners to seek urgent referral to a specialist without any delay if a patient presents with acute scrotum. Operative exploration should not be delayed by investigations whenever there is a suspicion of testicular torsion.

## Varicocele

Varicocele is an abnormal venous dilatation and/



**FIG 4. Torsion and testicular appendage**  
Torsion of a testicular appendix (hydatid of Morgagni) is shown (arrow)

or tortuosity of the pampiniform plexus in the cord. It may present as 'bags of worms' clinically and is identified in 15% of healthy men and up to 35% of men with primary infertility.<sup>56</sup> It appears in adolescent boys, with 7.8% in boys aged 11 to 14 years and 14.1% aged 15 to 19 years.<sup>57</sup>

## Potential clinical problems

Patients may not have any symptoms and can present late with subfertility. Increased temperature around the testis is believed to affect spermatogenesis and endocrine function of the testis.

The World Health Organization stated that varicocele was clearly associated with impaired testicular function and infertility.<sup>58</sup> They investigated 34 subfertility centres with 9034 men and identified varicocele in 25.4% of men with abnormal semen compared with 11.7% of men with normal semen.

Comparison of semen analysis in young men (17-19 years old) with and without varicocele revealed significant differences in total and progressive sperm motility and vitality, which were lower in boys with varicocele, and number of normal sperm forms.<sup>59</sup> It was concluded that spermatogenesis could be affected even at this young age.

## Clinical evaluation

Clinical (palpable) varicocele is detected and graded based on physical examination: a grade 1 varicocele is one that is only palpable during the Valsalva manoeuvre; a grade 2 varicocele is easily palpable with or without Valsalva but is not visible; grade 3 refers to a large varicocele that is easily palpable and detected on visual inspection of the scrotum. Size of both testes should be examined and measured with an orchidometer. Size discrepancy or testicular atrophy may indicate the need for further surgical management. Apart from examination of the genitalia, abdominal examination is also needed. Any abdominal mass/tumour that causes compression or obstruction of the renal veins or gonadal vessels can present with varicocele. Ultrasonography of the abdomen and scrotum may be needed if an abdominal mass is suspected. Semen analysis may not be practical or necessary in these child or adolescent patients.

## Indications for surgical management

Catch-up growth of the testis after varicocele operation has been demonstrated.<sup>60,61</sup> Nonetheless the same has also been demonstrated in varicocele patients managed conservatively.<sup>62</sup> Guidelines or recommendations have been suggested by different professional bodies including the AUA, American Society for Reproductive Medicine, European Association of Urology, and European Society of Paediatric Urology (ESPU). These guidelines are



mainly directed to adult patients and there is no consensus on the indications for surgery. A systematic review tried to collaborate the opinions from all the four professional bodies.<sup>63</sup> Some agreed indications include varicocele with reduced ipsilateral testicular volume, bilateral varicoceles, and varicocele with pathological semen quality. Symptomatic varicocele was suggested as an indication by ESPU but not the other three associations.

### Surgical options and complications

Different open surgical methods have been described: subinguinal, inguinal (Palomo), and microsurgical subinguinal approach. All involve ligation of testicular vessels, with or without the testicular artery. Laparoscopic high ligation of the vessels has become popular in this era. Lymphatic or artery-sparing techniques are preferred by some as they decrease the postoperative hydrocele rate.<sup>64,65</sup> Radiological embolisation of the testicular vein is another option.

Recurrence rates vary for different surgical procedures but are reported to be ranging from 0% to 35%. The rate of recurrence following various surgical methods have been quoted as: laparoscopic (1.2%), non-magnified inguinal (1.3%), open retroperitoneal (9.3%), microsurgical subinguinal (0.9%-2.5%), retrograde sclerotherapy (3.6%-8.6%), and antegrade sclerotherapy (9%).<sup>66</sup>

### Conclusion

Inguinoscrotal pathologies encompass a large disease spectrum in children. They may have very similar clinical presentations. Careful history taking and accurate clinical examination are crucial in achieving a correct diagnosis resulting in proper and timely management. There are some points to note:

- A properly performed clinical examination is important in establishing the diagnosis of hydrocele, inguinal hernia, and undescended testes.
- Clinically evident paediatric inguinal hernia should be offered surgical repair when the patient's general condition permits general anaesthesia, no matter the age.
- Infantile hydrocele should be managed with an expectant approach. Parents should be taught to observe for associated inguinal hernia.
- Undescended testis is associated with clinical problems of subfertility, increased risk of testicular torsion, and increased risk of testicular malignancy. Early orchidopexy (<18 months of age) should be advised.
- Testicular torsion is a surgical emergency. Urgent referral to a specialist should be made. Insistent investigations (USG) may confuse the clinical diagnosis and delay surgical management.

- Varicocele is associated with testicular atrophy and subfertility. Intra-abdominal mass should be excluded. Catch-up growth of the affected testis has been noted in some studies after operation.

### References

1. Chan IH, Wong KK. Common urological problems in children: prepuce, phimosis, and buried penis. *Hong Kong Med J* 2016;22:263-9.
2. Chang SJ, Chen JY, Hsu CK, Chuang FC, Yang SS. The incidence of inguinal hernia and associated risk factors of incarceration in pediatric inguinal hernia: a nation-wide longitudinal population-based study. *Hernia* 2016;20:559-63.
3. Kumar VH, Clive J, Rosenkrantz TS, Bourque MD, Hussain N. Inguinal hernia in preterm infants (≤32-week gestation). *Pediatr Surg Int* 2002;18:147-52.
4. Ein SH, Njere I, Ein A. Six thousand three hundred sixty-one pediatric inguinal hernias: a 35-year review. *J Pediatr Surg* 2006;41:980-6.
5. Naji H, Ingolfsson I, Isacson D, Svensson JE. Decision making in the management of hydroceles in infants and children. *Eur J Pediatr* 2012;171:807-10.
6. Koski ME, Makari JH, Adams MC, et al. Infant communicating hydroceles—do they need immediate repair or might some clinically resolve? *J Pediatr Surg* 2010;45:590-3.
7. Christensen T, Cartwright PC, Devries C, Snow BW. New onset of hydroceles in boys over 1 year of age. *Int J Urol* 2006;13:1425-7.
8. Toki A, Watanabe Y, Sasaki K, et al. Ultrasonographic diagnosis for potential contralateral inguinal hernia in children. *J Pediatr Surg* 2003;38:224-6.
9. Chen KC, Chu CC, Chou TY, Wu CJ. Ultrasonography for inguinal hernias in boys. *J Pediatr Surg* 1998;33:1784-7.
10. Kaneda H, Furuya T, Sugito K, et al. Preoperative ultrasonographic evaluation of the contralateral patent processus vaginalis at the level of the internal inguinal ring is useful for predicting contralateral inguinal hernias in children: a prospective analysis. *Hernia* 2015;19:595-8.
11. Gholoum S, Baird R, Laberge JM, Puligandla PS. Incarceration rates in pediatric inguinal hernia: do not trust the coding. *J Pediatr Surg* 2010;45:1007-11.
12. Zamakhshary M, To T, Guan J, Langer JC. Risk of incarceration of inguinal hernia among infants and young children awaiting elective surgery. *CMAJ* 2008;179:1001-5.
13. Lautz TB, Raval MV, Reynolds M. Does timing matter? A national perspective on the risk of incarceration in premature neonates with inguinal hernia. *J Pediatr* 2011;158:573-7.
14. Pini Prato A, Rossi V, Mosconi M, et al. Inguinal hernia in neonates and ex-preterm: complications, timing and need for routine contralateral exploration. *Pediatr Surg Int* 2015;31:131-6.
15. Lee SL, Gleason JM, Sydorak RM. A critical review of premature infants with inguinal hernias: optimal timing of repair, incarceration risk, and postoperative apnea. *J Pediatr Surg* 2011;46:217-20.
16. Chan IH, Lau CT, Chung PH, et al. Laparoscopic inguinal hernia repair in premature neonates: is it safe? *Pediatr Surg Int* 2013;29:327-30.
17. Esposito C, St Peter SD, Escolino M, et al. Laparoscopic versus open inguinal hernia repair in pediatric patients:

- a systematic review. *J Laparoendosc Adv Surg Tech A* 2014;24:811-8.
18. Schier F, Montupet P, Esposito C. Laparoscopic inguinal herniorrhaphy in children: a three-center experience with 933 repairs. *J Pediatr Surg* 2002;37:395-7.
  19. Saka R, Okuyama H, Sasaki T, Nose S, Yoneyama C, Tsukada R. Laparoscopic treatment of pediatric hydrocele and the evaluation of the internal inguinal ring. *J Laparoendosc Adv Surg Tech A* 2014;24:664-8.
  20. Feng S, Zhao L, Liao Z, Chen X. Open versus laparoscopic inguinal herniotomy in children: a systematic review and meta-analysis focusing on postoperative complications. *Surg Laparosc Endosc Percutan Tech* 2015;25:275-80.
  21. Chan KL, Hui WC, Tam PK. Prospective randomized single-center, single-blind comparison of laparoscopic vs open repair of pediatric inguinal hernia. *Surg Endosc* 2005;19:927-32.
  22. Celebi S, Uysal AI, Inal FY, Yildiz A. A single-blinded, randomized comparison of laparoscopic versus open bilateral hernia repair in boys. *J Laparoendosc Adv Surg Tech A* 2014;24:117-21.
  23. Steven M, Carson P, Bell S, Ward R, McHoney M. Simple purse string laparoscopic versus open hernia repair. *J Laparoendosc Adv Surg Tech A* 2016;26:144-7.
  24. Wang Z, Xu L, Chen Z, Yao C, Su Z. Modified single-port minilaparoscopic extraperitoneal repair for pediatric hydrocele: a single-center experience with 279 surgeries. *World J Urol* 2014;32:1613-8.
  25. Toufique Ehsan M, Ng AT, Chung PH, Chan KL, Wong KK, Tam PK. Laparoscopic hernioplasties in children: the implication on contralateral groin exploration for unilateral inguinal hernias. *Pediatr Surg Int* 2009;25:759-62.
  26. Wenk K, Sick B, Sasse T, Moehrlen U, Meuli M, Vuille-dit-Bille RN. Incidence of metachronous contralateral inguinal hernias in children following unilateral repair—A meta-analysis of prospective studies. *J Pediatr Surg* 2015;50:2147-54.
  27. Hoshino M, Sugito K, Kawashima H, et al. Prediction of contralateral inguinal hernias in children: a prospective study of 357 unilateral inguinal hernias. *Hernia* 2014;18:333-7.
  28. Miltenburg DM, Nuchtern JG, Jaksic T, Kozinetz C, Brandt ML. Laparoscopic evaluation of the pediatric inguinal hernia—a meta-analysis. *J Pediatr Surg* 1998;33:874-9.
  29. Kokorowski PJ, Wang HH, Routh JC, Hubert KC, Nelson CP. Evaluation of the contralateral inguinal ring in clinically unilateral inguinal hernia: a systematic review and meta-analysis. *Hernia* 2014;18:311-24.
  30. Agopian AJ, Langlois PH, Ramakrishnan A, Canfield MA. Epidemiologic features of male genital malformations and subtypes in Texas. *Am J Med Genet A* 2014;164A:943-9.
  31. Rusnack SL, Wu HY, Huff DS, et al. The ascending testis and the testis undescended since birth share the same histopathology. *J Urol* 2002;168:2590-1.
  32. Kullendorff CM, Hederström E, Forsberg L. Preoperative ultrasonography of the undescended testis. *Scand J Urol Nephrol* 1985;19:13-5.
  33. Nijs SM, Eijssbouts SW, Madern GC, Leyman PM, Lequin MH, Hazebroek FW. Nonpalpable testes: is there a relationship between ultrasonographic and operative findings? *Pediatr Radiol* 2007;37:374-9.
  34. Shoukry M, Pojak K, Choudhry MS. Cryptorchidism and the value of ultrasonography. *Ann R Coll Surg Engl* 2015;97:56-8.
  35. Lam WW, Tam PK, Ai VH, et al. Gadolinium-infusion magnetic resonance angiogram: a new, noninvasive, and accurate method of preoperative localization of impalpable undescended testes. *J Pediatr Surg* 1998;33:123-6.
  36. Siemer S, Humke U, Uder M, Hildebrandt U, Karadiakos N, Ziegler M. Diagnosis of nonpalpable testes in childhood: comparison of magnetic resonance imaging and laparoscopy in a prospective study. *Eur J Pediatr Surg* 2000;10:114-8.
  37. Tasian GE, Copp HL, Baskin LS. Diagnostic imaging in cryptorchidism: utility, indications, and effectiveness. *J Pediatr Surg* 2011;46:2406-13.
  38. Kolon TF, Herndon CD, Baker LA, et al. Evaluation and treatment of cryptorchidism: AUA guideline. *J Urol* 2014;192:337-45.
  39. Mengel W, Hienz HA, Sippe WG 2nd, Hecker WC. Studies on cryptorchidism: a comparison of histological findings in the germinative epithelium before and after the second year of life. *J Pediatr Surg* 1974;9:445-50.
  40. Lee PA, Coughlin MT. Fertility after bilateral cryptorchidism. Evaluation by paternity, hormone, and semen data. *Horm Res* 2001;55:28-32.
  41. Alagaratnam S, Nathaniel C, Cuckow P, et al. Testicular outcome following laparoscopic second stage Fowler-Stephens orchidopexy. *J Pediatr Urol* 2014;10:186-92.
  42. Cortes D, Thorup JM, Beck BL. Quantitative histology of germ cells in the undescended testes of human fetuses, neonates and infants. *J Urol* 1995;154:1188-92.
  43. Hanerhoff BL, Welliver C. Does early orchidopexy improve fertility? *Transl Androl Urol* 2014;3:370-6.
  44. Dieckmann KP, Pichlmeier U. Clinical epidemiology of testicular germ cell tumors. *World J Urol* 2004;22:2-14.
  45. Pettersson A, Richiardi L, Nordenskjöld A, Kaijser M, Akre O. Age at surgery for undescended testis and risk of testicular cancer. *N Engl J Med* 2007;356:1835-41.
  46. Hutson JM, Li R, Southwell BR, Petersen BL, Thorup J, Cortes D. Germ cell development in the postnatal testis: the key to prevent malignancy in cryptorchidism? *Front Endocrinol (Lausanne)* 2013;3:176.
  47. Lee SM, Huh JS, Baek M, et al. A nationwide epidemiological study of testicular torsion in Korea. *J Korean Med Sci* 2014;29:1684-7.
  48. Yu Y, Zhang F, An Q, Wang L, Li C, Xu Z. Scrotal exploration for testicular torsion and testicular appendage torsion: emergency and reality. *Iran J Pediatr* 2015;25:e248.
  49. Sheth KR, Keays M, Grimsby GM, et al. Diagnosing testicular torsion before urological consultation and imaging: validation of the TWIST score. *J Urol* 2016;195:1870-6.
  50. Burgu B, Aydogdu O, Huang R, Soygur T, Yaman O, Baker L. Pilot feasibility study of transscrotal near infrared spectroscopy in the evaluation of adult acute scrotum. *J Urol* 2013;190:124-9.
  51. Kalfa N, Veyrac C, Lopez M, et al. Multicenter assessment of ultrasound of the spermatic cord in children with acute scrotum. *J Urol* 2007;177:297-301.
  52. Lam WW, Yap TL, Jacobsen AS, Teo HJ. Colour Doppler ultrasonography replacing surgical exploration for acute scrotum: myth or reality? *Pediatr Radiol* 2005;35:597-600.
  53. Selbst SM, Friedman MJ, Singh SB. Epidemiology and etiology of malpractice lawsuits involving children in US emergency departments and urgent care centers. *Pediatr*

- Emerg Care 2005;21:165-9.
54. Lian BS, Ong CC, Chiang LW, Rai R, Nah SA. Factors predicting testicular atrophy after testicular salvage following torsion. *Eur J Pediatr Surg* 2016;26:17-21.
  55. Redshaw JD, Tran TL, Wallis MC, deVries CR. Epididymitis: a 21-year retrospective review of presentations to an outpatient urology clinic. *J Urol* 2014;192:1203-7.
  56. Alsaikhan B, Alrabeeah K, Delouya G, Zini A. Epidemiology of varicocele. *Asian J Androl* 2016;18:179-81.
  57. Akbay E, Cayan S, Doruk E, Duce MN, Bozlu M. The prevalence of varicocele and varicocele-related testicular atrophy in Turkish children and adolescents. *BJU Int* 2000;86:490-3.
  58. World Health Organization. The influence of varicocele on parameters of fertility in a large group of men presenting to infertility clinics. *Fertil Steril* 1992;57:1289-93.
  59. Paduch DA, Niedzielski J. Semen analysis in young men with varicocele: preliminary study. *J Urol* 1996;156(2 Pt 2):788-90.
  60. Paduch DA, Niedzielski J. Repair versus observation in adolescent varicocele: a prospective study. *J Urol* 1997;158(3 Pt 2):1128-32.
  61. Kass EJ, Belman AB. Reversal of testicular growth failure by varicocele ligation. *J Urol* 1987;137:475-6.
  62. Preston MA, Carnat T, Flood T, Gaboury I, Leonard MP. Conservative management of adolescent varicoceles: a retrospective review. *Urology* 2008;72:77-80.
  63. Roque M, Esteves SC. A systematic review of clinical practice guidelines and best practice statements for the diagnosis and management of varicocele in children and adolescents. *Asian J Androl* 2016;18:262-8.
  64. Esposito C, Valla JS, Najmaldin A, et al. Incidence and management of hydrocele following varicocele surgery in children. *J Urol* 2004;171:1271-3.
  65. Chiarenza SF, Giurin I, Costa L, et al. Blue patent lymphography prevents hydrocele after laparoscopic varicocelectomy: 10 years of experience. *J Laparoendosc Adv Surg Tech A* 2012;22:930-3.
  66. Rotker K, Sigman M. Recurrent varicocele. *Asian J Androl* 2016;18:229-33.