





| | |
|--------------------|--|
| Title | Control of brain metastases with alectinib in anaplastic lymphoma kinase-rearranged lung cancer |
| Author(s) | Kwok, WC; Tam, CCT; Lui, MSM; Lam, CLD; Ho, JCM |
| Citation | Respirology Case Reports, 2017, v. 5 n. 3, p. e00224 |
| Issued Date | 2017 |
| URL | http://hdl.handle.net/10722/245129 |
| Rights | This work is licensed under a Creative Commons Attribution-NonCommercial-NoDerivatives 4.0 International License. |

Control of brain metastases with alectinib in anaplastic lymphoma kinase-rearranged lung cancer

Wang Chun Kwok , Terence Chi Chun Tam, Macy Mei Sze Lui, David Chi Leung Lam & James Chung Man Ho 

Department of Medicine, Queen Mary Hospital, Hong Kong, China.

Keywords

Alectinib, anaplastic lymphoma kinase, brain metastasis, lung cancer, tyrosine kinase inhibitor.

Correspondence

Wang Chun Kwok, Department of Medicine, Queen Mary Hospital, 102 Pokfulam Road, Pokfulam, Hong Kong Special Administrative Region, China.
E-mail: herbert728@gmail.com

Received: 26 December 2016; Revised: 26 January 2017; Accepted: 7 February 2017; Associate Editor: Stephen Lam.

Respirology Case Reports, 5 (3), 2017, e00224

doi: 10.1002/rccr.2.224

Introduction

We report the case of a young man who had ALK-driven adenocarcinoma of the lung with progressive brain metastases despite targeted therapy and chemotherapy. Salvage treatment with alectinib resulted in a durable response in both systemic and intracranial diseases. The rationale of therapeutic selection among various ALK tyrosine kinase inhibitors (TKI) is illustrated with this case in the era of personalized lung cancer treatment.

Case Report

A 36-year-old Chinese man was first diagnosed to have stage IIIB adenocarcinoma of the lung in 2008. He was treated with paclitaxel, carboplatin, and bevacizumab for six cycles, but the disease progressed with new intrapulmonary metastases and two right parietal cystic brain metastases. He received whole brain irradiation (WBRT) followed by pemetrexed for five cycles. The disease progressed again. At that time, the ALK gene rearrangement test was not readily available. He had an epidermal growth factor receptor wild-type tumour; nonetheless, erlotinib was started as third-line chemotherapy despite having only

Abstract

Brain metastasis from non-small cell lung cancer remains a challenge to physicians. It occurs in 30% of patients with advanced stage adenocarcinoma of lung and is often regarded as the ominous sign of disease progression and death. Alectinib is likely to be a promising agent, even after the failure of crizotinib and ceritinib, for patients with anaplastic lymphoma kinase (ALK)-driven non-small cell lung cancer with brain metastasis, resulting in a durable response for both intracranial and extra-cranial diseases.

modest benefit. Disease progressed after 4 months. At that time, crizotinib was undergoing clinical trials in the setting of second-line treatment and beyond. His archived tumour sample tested positive for ALK by fluorescent in situ hybridization assay. Crizotinib (250 mg twice daily) was started under trial protocol. There was good partial response for 16 months until a new right high parietal metastasis developed. In view of the tiny, asymptomatic brain metastasis and still responding extra-cranial disease, crizotinib was continued for another 6 months until frank extra-cranial progression was recorded. He was recruited to another clinical trial with ceritinib (750 mg daily). He had gastrointestinal side effects and drug-induced hepatitis, which required temporary suspension of ceritinib for 3 weeks at the fifth month. The disease remained stable until 7 months later, when there was progression in the primary tumour and a new brain metastasis in the lower part of medulla oblongata. Ceritinib was continued despite progression, while CyberKnife was administered to the brainstem lesion. The disease remained stable for another 22 months. He could tolerate ceritinib with mild gastrointestinal problems. Subsequently, there was symptomatic progressive disease in the brain. Ceritinib was switched to alectinib 600 mg twice daily after 31 months. There was

partial response in the medullary metastasis, with stable disease at extra-cranial sites (Fig. 1). These responses have been maintained for at least 8 months of alectinib treatment at the time of writing. During the treatment course, alectinib was temporarily withheld due to myositis, with creatine kinase rising to 2673 U/L (normal: 65–355 U/L). Upon resumption of alectinib, there was no recurrence of myositis. Overall, he has satisfactory tolerance to alectinib, while there is sustained disease response in both intracranial and extra-cranial sites at around 8 years after diagnosis.

Discussion

Brain metastases remain a major challenge in thoracic oncology. Stereotactic radiosurgery is reserved for a limited number of small brain metastases. WBRT is still the treatment of choice for multiple brain metastases despite causing significant morbidities. The benefit from systemic therapy largely depends on its ability to cross the blood–brain barrier. Chemotherapy is considered less effective than radiotherapy for treating brain metastasis.

Central nervous system (CNS) penetration is also a problem for earlier TKI. Crizotinib only has modest activity against brain metastases. The reported cerebrospinal

fluid-to-plasma ratio of crizotinib was only 0.0026. In a study involving 343 patients with ALK-positive lung cancer, in which 79 patients received treatment for brain metastases, crizotinib had an intracranial disease control rate of 85% at 12 weeks, which decreased to 56% at 24 weeks [1]. The durability of intracranial disease control is a concern as CNS relapses may result in rapid neurological deterioration. The second generation ALK inhibitor, ceritinib, also has activity in brain metastasis, with an overall response rate of 54% [2]. Unfortunately, its use is limited by its toxicities. Diarrhoea, nausea, and vomiting occurred in 86, 80, and 60% of patients, respectively. Drug-induced hepatitis is common, occurring in up to 80% patients with 27% having grade 3–4 hepatitis. The adverse effects remain a hurdle to successful and tolerable treatment.

Alectinib has been shown to have important clinical activity in brain metastases, including CNS relapse with other ALK inhibitors. In a phase II trial with 84 patients, the CNS disease control rate of alectinib was 83% with a median duration of CNS response at 10 months [3]. Its activity against brain metastases was similar regardless of previous radiation therapy or not. Alectinib also demonstrated improved progression-free survival relative to crizotinib among patients with brain metastases in the J-ALEX study [4]. In a case series, alectinib demonstrated

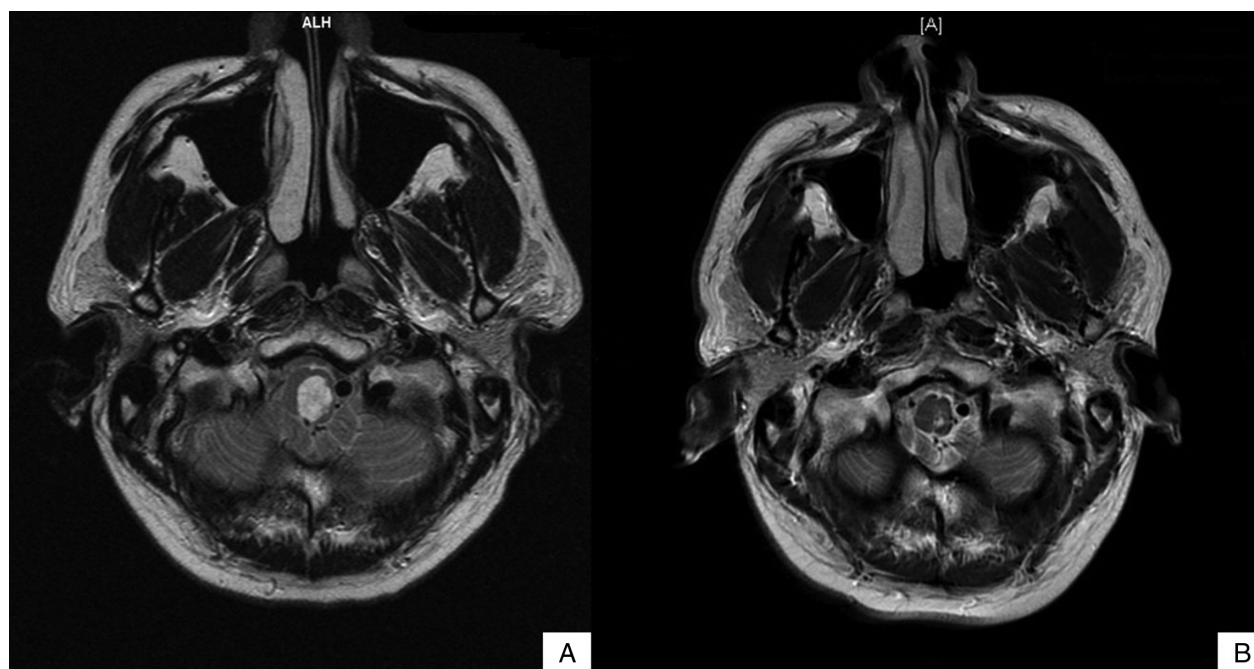

Figure 1. T2-weighted magnetic resonance imaging of the brainstem showing partial response in the medulla oblongata metastasis with alectinib treatment. (a) Medulla oblongata metastasis while on ceritinib for 30 months and after CyberKnife treatment, measuring 10 × 13 × 18 mm. (b) Medulla oblongata metastasis after 6 months of alectinib treatment, which showed interval reduction in size and enhancement, measuring 3 × 5 mm.

significant anti-tumour activity in ALK-positive patients with leptomeningeal and brain metastases who had prior treatment with crizotinib and ceritinib [5]

Our case also reflects some of these findings from previous reports. Crizotinib has some activity against brain metastases but has limited durability. Ceritinib has significant CNS activity, but its toxicities often warrant dose reduction or transient withholding, resulting in CNS relapse. In our case, the CNS disease was under control for 16 and 7 months while on crizotinib and ceritinib, respectively. Crizotinib achieved partial response in the brain metastases, while ceritinib led to disease stabilization. On the other hand, salvage treatment with alectinib resulted in significant partial response both intracranially and extracranially for at least 8 months at the time of writing. This could result from both better tolerability and potentially more potent ALK inhibition of alectinib compared with crizotinib and ceritinib. Our anecdotal experience suggests that alectinib is a reasonable choice of treatment for patients with ALK-driven non-small cell lung carcinoma with brain metastasis even after the failure of existing ALK inhibitors.

Disclosure Statements

No conflict of interest declared.

Appropriate written informed consent was obtained for publication of this case report and accompanying images.

References

1. Solomon BJ, Cappuzzo F, Felip E, et al. 2016. Intracranial efficacy of crizotinib versus chemotherapy in patients with advanced ALK-positive non-small-cell lung cancer: results from PROFILE 1014. *J. Clin. Oncol.* 34(24):2858–2865.
2. Shaw A, Mehra R, Tan DS, et al. 2014. BM-32Ceritinib (LDK378) for treatment of patients with ALK-rearranged (ALK+) non-small cell lung cancer (NSCLC) and brain metastases (BM) in the ASCEND-1 trial. *Neuro Oncol.* 16-(suppl 5):v39.
3. Ou SH, Ahn JS, De Petris L, et al. 2016. Alectinib in crizotinib-refractory ALK-rearranged non-small-cell lung cancer: a phase II global study. *J. Clin. Oncol.* 34(7):661–668.
4. Nokihara H, Hida T, Kondo M, et al. 2016. Alectinib (ALC) versus crizotinib (CRZ) in ALK-inhibitor naive ALK-positive non-small cell lung cancer (ALK+ NSCLC): primary results from the J-ALEX study. *J. Clin. Oncol.* 8:1005–1013.
5. Gainor JF, Sherman CA, Willoughby K, et al. 2015. Alectinib salvages CNS relapses in ALK-positive lung cancer patients previously treated with crizotinib and ceritinib. *J. Thorac. Oncol.* 10(2):232–236.