

## IMAGES IN INTERVENTION

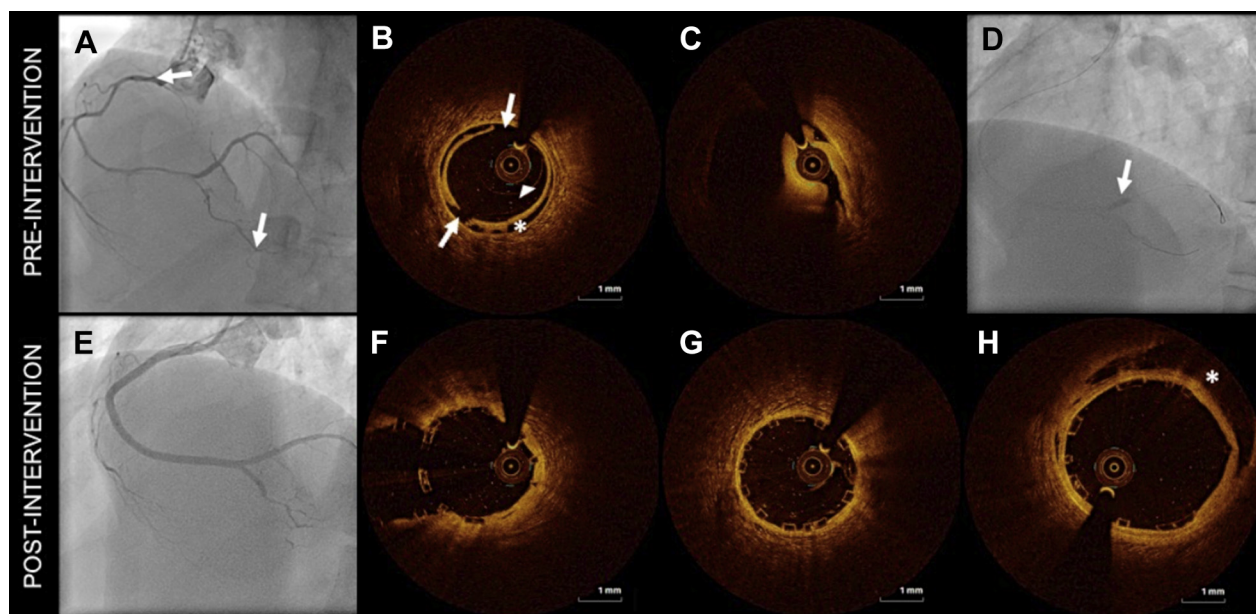
# Optical Coherence Tomography–Guided Full Plastic Jacket in Spontaneous Coronary Artery Dissection

Ana Rita Ramalho, MD, João Silva Marques, MD, Manuel Oliveira Santos, MD, Vitor Matos, MD

A healthy 38-year-old woman was hospitalized for an acute coronary syndrome. Coronary angiography revealed a smooth, diffusely narrowed right coronary artery (Figure 1A). With an

adequate level of suspicion, optical coherence tomography (OCT) was performed and identified spontaneous coronary artery dissection (SCAD) (Figures 1B and 1C). Contrast injection during optical coherence

**FIGURE 1** Spontaneous Coronary Artery Dissection: Angiographic Appearance and Optical Coherence Tomographic Insights, Before and After Percutaneous Coronary Intervention



(A) Right coronary artery (RCA) dissection (between arrows). (B) Optical coherence tomographic image showing the false lumen (asterisk), guidewire within the true lumen (arrowhead), and intimal rupture (arrows). (C) Severe narrowing of the true lumen because of extrinsic compression with poor assessment of reference size because of attenuation. (D) Contrast retention in RCA bifurcation (arrow) after diagnostic optical coherence tomography. (E) Final angiographic result of percutaneous coronary intervention. (F) Bifurcation bioresorbable vascular scaffold T stenting. (G) Good stent expansion and apposition. (H) Residual intramural hematoma at the ostium (asterisk).

From the Cardiology A Department, Coimbra Hospital and University Centre, Coimbra, Portugal. The authors have reported that they have no relationships relevant to the contents of this paper to disclose.

Manuscript received October 12, 2016; accepted October 20, 2016.

tomographic pullback induced distal progression of the dissection with no-flow, angina, and ST-segment elevation (**Figure 1D**). Percutaneous coronary intervention was undertaken with implantation of 7 sequential bioresorbable vascular scaffolds that were chosen for the theoretical benefit of avoiding late stent malapposition following resorption of intramural hematoma. Final angiography and OCT demonstrated the success of percutaneous coronary intervention, with residual proximal dissection covered by stent struts (**Figures 1E to 1H**).

OCT is often the preferred modality, as it provides better resolution (1). However, there are several limitations of OCT in SCAD management that are

emphasized by this case. Namely, hydraulic extension of coronary dissection precluded a conservative approach. Also, poor tissue penetration prevented accurate measurement of proximal reference diameter to guide angioplasty. IVUS may be a safer alternative diagnostic tool in SCAD. This case also illustrates that “full plastic jacket” stenting offers good acute results in SCAD when intervention is needed.

---

**ADDRESS FOR CORRESPONDENCE:** Dr. Ana Rita Ramalho, Serviço de Cardiologia A do Centro Hospitalar e Universitário de Coimbra, Praceta Professor Mota Pinto, 3000-075 Coimbra, Portugal. E-mail: [anarita\\_ramalho@hotmail.com](mailto:anarita_ramalho@hotmail.com).

---

## REFERENCE

1. Alfonso F, Paulo M, Gonzalo N, et al. Diagnosis of spontaneous coronary artery dissection by optical coherence tomography. *J Am Coll Cardiol* 2012;59:1073-9.

---

**KEY WORDS** full plastic jacket, optical coherence tomography, spontaneous coronary artery dissection