

Figura 4 - Produto de concepção: feto, placenta e mola hidatiforme (fotografia cortesia de Artur Costa e Silva)

gemelar em que há uma mola hidatiforme completa e um feto viável, o casal tem de optar entre interromper a gravidez de um feto vivo, sem patologia, ou deixar prosseguir a gestação, enfrentando os riscos de morte fetal e de complicações maternas graves. Se o casal optar por pro-

## REFERÊNCIAS

- Altieri A, Franceschi S, Ferlay J, Smith J, La Vecchia C. Epidemiology and aetiology of gestational trophoblastic diseases. *Lancet Oncol*. 2003;4:670-8.
- Sebire NJ, Foskett M, Paradinas FJ, Fisher RA, Francis RJ, Short D, et al. Outcome of twin pregnancies with complete hydatiform mole and healthy co-twin. *Lancet*. 2002;359:2165-6.
- Matsui H, Sekiya S, Hando T, Wake N, Tomoda Y. Hydatiform mole co-existent with a twin live fetus: a national collaborative study in Japan. *Hum Reprod*. 2000;15:608-11.
- Taylor JH. Twin pregnancy: Well-formed hydatiform mole associated with normal viable child. *BMJ*. 1957;1:1103.
- Piura B, Rabinovich A, Hershkovitz R, Maor E, Mazor M. Twin pregnancy with a complete hydatiform mole and a surviving co-existent fetus. *Arch Gynecol Obstet*. 2008;278:377-82.
- Marcorelles P, Audrezet MP, Le Bris MJ, Laurent Y, Chabaud JJ, Ferec C, et al. Diagnosis and outcome of complete hydatiform mole coexisting with a live twin fetus. *Eur J Obstet Gynecol Reprod Biol* 2005;118:21-7.
- Malhotra N, Deka D, Takkar D, Kochar S, Goel S, Sharma MC. Hydatiform mole with a coexisting live fetus in dichorionic twin gestation. *Eur J Obstet Gynecol Reprod Biol*. 2001;94:301-3.
- Choi-Hong SR, Genest DR, Crum CP, Berkowitz E, Goldstein DP, Schofield DH. Twin pregnancies with complete hydatiform mole and coexisting fetus: Use of fluorescent in situ hybridization to evaluate placental X- and Y- chromosomal content. *Hum Pathol*. 1995;26:1175-80.
- Wee L, Jauniaux E. Prenatal diagnosis and management of twin pregnancies complicated by a co-existing molar pregnancy. *Prenat Diagn*. 2005;25:772-6.

# Arachnoid Cyst Spontaneous Rupture

## Rotura Espontânea de Quisto Aracnóide

Inês Brás MARQUES<sup>1</sup>, J. VIEIRA BARBOSA<sup>1</sup>  
Acta Med Port 2014 Jan-Feb;27(1):137-141

### ABSTRACT

Arachnoid cysts are benign congenital cerebrospinal fluid collections, usually asymptomatic and diagnosed incidentally in children or adolescents. They may become symptomatic after enlargement or complications, frequently presenting with symptoms of intracranial hypertension. We report an unusual case of progressive refractory headache in an adult patient due to an arachnoid cyst spontaneous rupture. Although clinical improvement occurred with conservative treatment, the subdural hygroma progressively enlarged and surgical treatment was ultimately needed. Spontaneous rupture is a very rare complication of arachnoid cysts. Accumulation of cerebrospinal fluid accumulation in the subdural space causes sustained intracranial hypertension that may be life-threatening and frequently requires surgical treatment. Patients with arachnoid cysts must be informed on their small vulnerability to cyst rupture and be aware that a sudden and severe headache, especially if starting after minor trauma or a Valsalva manoeuvre, always requires medical evaluation.

**Keywords:** Arachnoid Cysts/complications; Rupture, Spontaneous.

1. Serviço de Neurologia. Centro Hospitalar e Universitário de Coimbra. Coimbra. Portugal.

Recebido: 14 de Fevereiro de 2013 - Aceite: 15 de Junho de 2013 | Copyright © Ordem dos Médicos 2014



## RESUMO

Os quistos aracnóides são coleções de líquido céfalo-raquidiano congénitas e benignas, geralmente assintomáticas e diagnosticadas incidentalmente em crianças ou adolescentes. Podem tornar-se sintomáticos após crescimento ou complicações, apresentando-se frequentemente com sintomas de hipertensão intracraniana. Reportamos um caso invulgar de cefaleia progressiva e refratária num doente adulto devido a rotura espontânea de quisto aracnóide. Apesar de melhoria clínica com tratamento conservador, verificou-se aumento progressivo de higroma subdural com necessidade de tratamento cirúrgico. A rotura espontânea é uma complicação muito rara dos quistos aracnóides. A coleção de líquido céfalo-raquidiano no espaço subdural causa hipertensão intracraniana mantida potencialmente ameaçadora da vida, necessitando frequentemente tratamento cirúrgico. Doentes com quistos aracnóides devem ser informados da sua pequena vulnerabilidade para rotura do quisto e ter conhecimento que uma cefaleia súbita e violenta, especialmente se surgir após pequeno trauma ou manobra de Valsalva, necessita sempre avaliação médica.

**Palavras-chave:** Quisto Aracnóide/complicações; Ruptura Espontânea.

## INTRODUCTION

Arachnoid cysts (ACs) are benign congenital collections of cerebrospinal fluid (CSF) surrounded by histologically normal layers of the arachnoid membrane. They are believed to result from a dysgenesis in embryological development with anomalous splitting of the normally fused inner and outer layers of the arachnoid membrane followed by secretion of fluid by the arachnoid cells into the resulting cleft.<sup>1-3</sup>

ACs represent about 1% of all intracranial space-occupying lesions, being a common incidental neuroimaging finding.<sup>1,4,5</sup> They are usually diagnosed during childhood and adolescence, with male gender predominance. Their most common location is the middle cranial fossa, with predilection for the left side.<sup>1,2,5-8</sup>

In most cases, ACs remain small and asymptomatic.<sup>2,9</sup> Occasionally, they become manifest, especially when large and located in the middle cranial fossa.<sup>6</sup> Signs and symptoms usually follow cyst enlargement with compression or irritation of adjacent structures, intracranial mass effect and/or CSF circulation disturbance.<sup>1</sup>

Clinical manifestations depend on various factors, including age and cyst location and size. Headache is the most common presentation, but they may also present with seizures, intracranial hypertension or focal motor deficits. In children they may cause macrocephaly and delayed psychomotor development.<sup>1,7,9</sup>

Although infrequent, more serious and potentially life-threatening complications may occur, making ACs not so benign as frequently believed.<sup>2,6,7</sup> Head trauma can origin rupture of blood vessels around the cyst wall or of the unsupported bridging veins in cyst cavity, producing intracystic and/or subdural hemorrhage.<sup>1-3,5,7</sup> Traumatic or spontane-

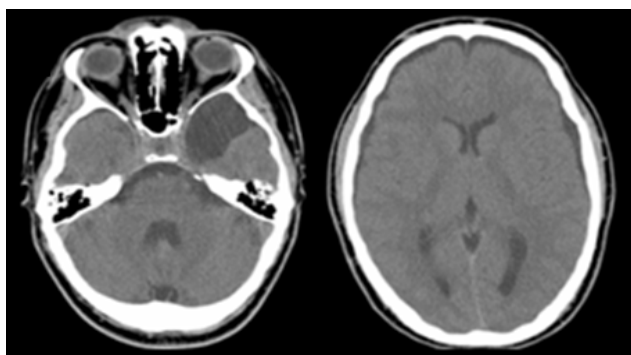
ous cyst rupture has been reported rarely, mainly in children.<sup>1-11</sup> In this article we report an unusual case of arachnoid cyst spontaneous rupture in an adult patient.

## CASE REPORT

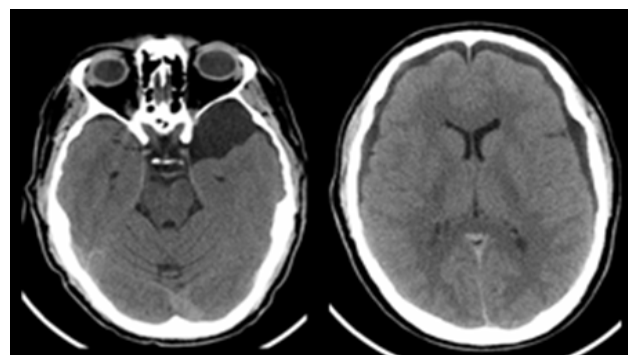
A 29-year-old caucasian male patient, with unremarkable past medical history, presented to the emergency room with severe headache and vomiting with sudden start three days before after lifting heavy objects. Brain CT scan and MRI revealed a left middle cranial fossa arachnoid cyst and bilateral frontotemporal subdural hygroma (Fig. 1). Neurosurgery team found no indication for surgical treatment and symptomatic treatment with tramadol, metamizol and metoclopramide was prescribed.

As the headache continued worsening despite symptomatic treatment, the patient returned four days later. The headache was holocranial, pressure-like, constant, with severe and progressively increasing intensity, exacerbated by supine position and accompanied by progressive photophobia and visual blurring. Neurological examination revealed bilateral papilledema with normal visual acuity, visual fields and pupillary responses. There were no other cranial nerve functions abnormalities, focal neurological findings or meningeal signs and the patient was apiretic. Lumbar puncture with manometry revealed an increased opening pressure (45 cmH<sub>2</sub>O). CSF cytochemical examination was normal.

Treatment with oral acetazolamide, 250 mg three times a day, induced progressive clinical improvement with total symptom resolution after eight days. However, brain CT scan revealed slight enlargement of the subdural hygroma (Fig. 2). Two weeks later, brain image revealed right subdural collection disappearance, but simultaneous left



**Figure 1** - Initial brain CT revealing left middle cranial fossa arachnoid cyst and bilateral frontotemporal subdural hygroma



**Figure 2** - Brain CT after symptoms resolution revealing slight hygroma enlargement

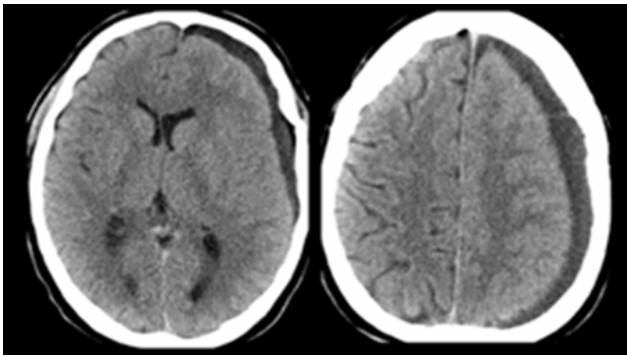


Figure 3 - Brain CT after three weeks of acetazolamide treatment revealing enlargement of the left subdural hygroma

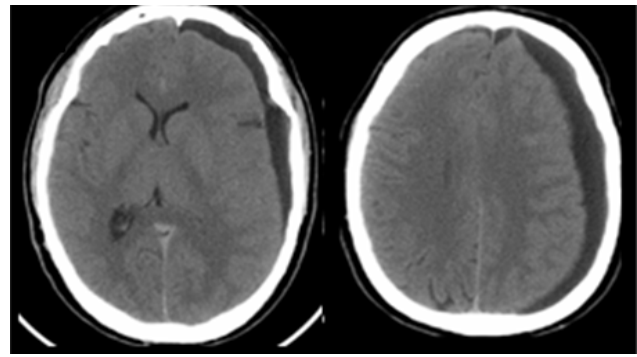


Figure 4 - Brain CT after two months, revealing left subdural hygroma enlargement with mass effect and midline shift

subdural hygroma enlargement with minor midline shift (Fig. 3). Neurosurgery team decided to maintain a conservative approach with watchful waiting, as the patient was asymptomatic and clinically stable.

A control CT scan scheduled for two months later identified enlargement of the left subdural hygroma with mass effect and larger contralateral displacement of midline structures (Fig. 4). Despite the absence of symptoms, urgent craniotomy with evacuation of subdural hygroma and cyst fenestration was performed with satisfactory imagiologic outcome (Fig. 5) and without clinical complications.

## DISCUSSION

Rupture is a very uncommon complication of arachnoid cysts, with less than fifty cases of either traumatic or spontaneous rupture reported in the literature, the vast majority in children and adolescents.<sup>2-17</sup> The rarity of this entity, especially in adulthood, probably explains the frequent lack of clinical suspicion in adults with progressive refractory headache.

We present a summary of the patients with spontaneous ACs rupture reported in literature in Table 1.<sup>6,7,9-16</sup> All cases occurred in children or adolescents (age range: 5-16 years), with our patient being the first adult reported with spontaneous AC rupture. In the totality of the cases with spontaneous rupture, cysts were located in the middle cranial fossa and intracranial hypertension manifestations were present with headache being a constant symptom. The most common finding in examination was bilateral papilledema and a focal neurological deficit (right hemiparesis) was present in one patient. Subdural hygroma was ipsilateral to the cyst in all but one of the cases, a patient with bilateral subdural collections in similarity to our patient. Surgical treatment was performed in all cases, except in one patient who responded to conservative treatment. Good clinical and radiological outcome was reported in the totality of cases.

Two mechanisms have been proposed to explain ACs rupture.<sup>10</sup> The first one would be a minor head injury able to create a tear in the subarachnoid cyst wall and a communication with subarachnoid space. A flap-valve mechanism, only allowing CSF entering into the cyst, progressively increases cyst internal pressure with later disruption into the subdural space. In the second mechanism, spontane-

ous rupture of the cyst into the subdural space follows a sudden transient intracranial pressure increase during a Valsalva manoeuvre. CSF accumulation in the subdural space results in subdural hygroma and subsequent intracranial hypertension.<sup>1-17</sup>

In clinically stable patients, a good response to conservative treatment with acetazolamide has been reported with resolution of hygroma and intracranial hypertension manifestations, albeit not affecting the cyst dimension.<sup>9,17</sup> Although our patient symptoms resolved with acetazolamide, the hygroma progressively enlarged and surgical treatment was ultimately necessary.

The best treatment approach for ACs remains controversial.<sup>4,5,8</sup> An expectant attitude is advised for small and asymptomatic cysts, while surgical treatment is indicated for symptomatic cysts, enlarging cysts, cysts with mass effect and after cyst complications.<sup>1,5,9</sup>

The main objective of surgical treatment is cyst decompression. The currently preferred surgical approach is cyst fenestration which establishes an adequate communication between the cyst cavity and the normal CSF flow pathway.<sup>1,2,4</sup> This procedure can be performed by craniotomy or endoscopically, both being safe and effective.<sup>1,2,4,6</sup> The surgical procedure choice depends mainly on surgeon experience and preference, as surgical complications are essentially related to cyst location and size rather than the method used.<sup>1</sup> Cystoperitoneal shunt is an alternative that reduces potential complications from sudden decompression of the surrounding brain, but has inconveniences as dependence on a valvular system and risk of obstruction or infection.<sup>1,5</sup>

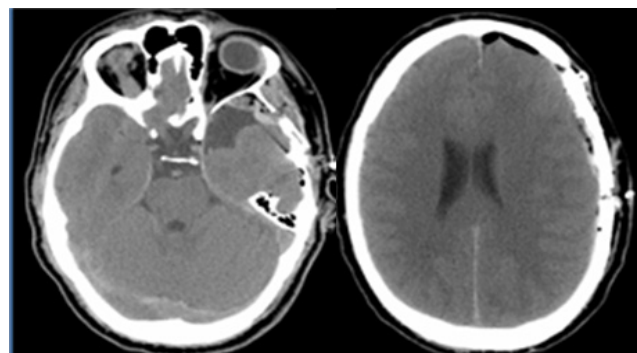


Figure 5 - Post-operative brain CT scan with subdural hygroma resolution and reduction of arachnoid cyst volume

Table 1 – Summary of patients with spontaneous arachnoid cyst rupture

Reference	Gender	Age (years)	Cyst Location	Clinical Presentation	Neurological Examination	Subdural Collections	Treatment	Outcome
Cullis P, Gilroy J, 1983 <sup>10</sup>	M	11	Left MCF	Headache and vomiting	Fundoscopy with "capillary blush and blurred disk margins"	Ipsilateral SD hygroma	Craniotomy and cyst fenestration	NR
Albuquerque FC, Giannotta SL 1997 <sup>7</sup>	NR	10	Left MCF	Headache, nausea and vomiting	NR	Ipsilateral SD hygroma	Subdural-peritoneal shunt	Symptoms and hygroma resolution; Cyst reduction
Ergun et al 1997 <sup>11</sup>	M	14	Left MCF	Headache, nausea, vomiting and right hemiparesis	Bilateral papilledema, mild right hemiparesis	Ipsilateral SD hygroma	Craniotomy and cyst fenestration	Symptoms resolution; Hygroma and cyst reduction
Sener 1997 <sup>12</sup>	M	12	Left MCF	"signs and symptoms of increased IP"	"signs and symptoms of increased IP"	Ipsilateral SD hygroma	NR	NR
Sener 1997 <sup>12</sup>	M	16	Left MCF	"signs and symptoms of increased IP"	"signs and symptoms of increased IP"	Ipsilateral SD haematoma	NR	NR
Choong et al 1998 <sup>9</sup>	F	9	Left MCF	Headache and vomiting	Bilateral papilledema	Bilateral SD hygroma	Conservative (Acetazolamide)	Symptoms and hygroma resolution
Cayli et al 2000 <sup>13</sup>	F	12	Left MCF	Headache, nausea and vomiting	Bilateral papilledema	Ipsilateral SD hygroma	Craniotomy and cyst fenestration	Symptoms resolution; Hygroma and cyst reduction
Cakir et al 2003 <sup>14</sup>	M	9	Right MCF	Headache, nausea and vomiting	Normal	Ipsilateral SD hygroma	Subdural-peritoneal shunt	Symptoms resolution; Hygroma and cyst reduction
Poirrier et al 2004 <sup>15</sup>	M	15	Right MCF	Headache, blurred vision, nausea, vomiting, anorexia, epigastric pain and diaphoresis	Normal	Ipsilateral SD hygroma	Subdural-peritoneal shunt	Symptoms and hygroma resolution
Slaviero et al 2008 <sup>6</sup>	M	5	Left MCF	Headache and drowsiness	Normal	Ipsilateral SD hygroma	Hygroma evacuation and endoscopic cyst fenestration	Symptoms and hygroma resolution; Cyst reduction
Gil-Gouveia et al 2010 <sup>16</sup>	F	16	Left MCF	Headache, nausea photophobia and diplopia	Normal	Ipsilateral SD hygroma	Subdural-peritoneal shunt	Symptoms and hygroma resolution

M – male; F – female; MCF –Middle cranial fossa; NR – not reported; SD – subdural; IP – intracranial pressure



A recent study about ACs complicated with subdural collections described good clinical results after subdural effusions evacuation, without cyst intervention.<sup>5</sup>

In our patient, additionally to subdural collection evacuation, surgical cyst fenestration was performed as a preventive measure of further cyst complications.

Arachnoid cyst rupture is a very rare complication of ACs and an extremely uncommon cause of headache. Patients must be informed on their small vulnerability to cyst rupture or hemorrhage and the relationship of those rare events with activities with increased risk for cranial trauma or with extreme increase in intracranial pressure. It is also important to explain these patients that a sudden and violent headache, especially after trauma or manoeuvres

increasing intracranial pressure, always requires medical evaluation.

### CONFLICTS OF INTEREST

None stated. This clinical case was previously delivered at the following scientific meetings: Autumn Meeting of the Sociedade Portuguesa de Cefaleias, November 18 and 19, 2011, Coimbra, Portugal (Oral Communication); 16th Congress of the European Federation Neurological Societies (EFNS), September 8 to 11, 2012; Stockholm, Sweden (Poster).

### FUNDING SOURCES

None stated.

### REFERENCES

- Vega-Sosa A, de Obieta-Cruz E, Hernández-Rojas MA. Intracranial arachnoid cyst. *Cir Cir.* 2010;78:551-6.
- Hamada H, Hayashi N, Umemura K, Kurosaki K, Endo S. Middle cranial fossa cyst presenting with subdural effusion and endoscopic detection of tear of the cyst – case report. *Neurol Med Chir.* 2010;50:512-4.
- Offiah C, St Clair Forbes W, Thorne J. Non-haemorrhagic subdural collection complicating rupture of a middle cranial fossa arachnoid cyst. *Br J Radiol.* 2006;79:79-82.
- Gelabert-González M, Fernández-Villa J, Cutrín-Prieto J, García Allut A, Martínez-Rumbo R. Arachnoid cyst rupture with subdural hygroma: report of three cases and literature review. *Childs Nerv Syst.* 2002;18:609-13.
- Sprung C, Armbruster B, Koeppen D, Cabraja M. Arachnoid cysts of the middle cranial fossa accompanied by subdural effusions—experience with 60 consecutive cases. *Acta Neurochir.* 2011;153:75-84.
- Slaviero F, Frighetto L, Azambuja Júnior ND, Martins LS, Annes RD, Vanzin JR. Middle cranial fossa arachnoid cysts complicated with subdural collections. *Arq Neuropsiquiatr.* 2008;66:913-5.
- Albuquerque FC, Giannotta SL. Arachnoid cyst rupture producing subdural hygroma and intracranial hypertension: case reports. *Neurosurgery.* 1997;41:951-6.
- Gupta R, Vaishya S, Mehta VS. Arachnoid cyst presenting as subdural hygroma. *J Clin Neurosci.* 2004; 11:317-8.
- Choong CT, Lee SH. Subdural hygroma in association with middle fossa arachnoid cyst: acetazolamide therapy. *Brain Dev.* 1998;20:319-22.
- Cullis P, Gilroy J. Arachnoid cyst with rupture into the subdural space. *J Neurol Neurosurg Psychiatry.* 1983;46:454-6.
- Ergun R, Ökten AI, Beşkonaklı E, Anasiz H, Ergüngör F, Taşkin Y. Unusual complication of arachnoid cyst: Spontaneous rupture into the subdural space. *Acta Neurochir.* 1997;139:692-4.
- Sener RN. Arachnoid cysts associated with post-traumatic and spontaneous rupture into the subdural space. *Comput Med Imaging Graph.* 1997;21:341-4.
- Cayli SR. Arachnoid cyst with spontaneous rupture into the subdural space. *Br J Neurosurg.* 2000;14:568-70.
- Cakir E, Kayhankuzeyli; Sayin OC, Peksoylu B, Karaarslan G. Arachnoid cyst rupture with subdural hygroma: case report and literature review. *Neurocirurgia.* 2003;14:72-5.
- Poirrier AL, Ngosso-Tetanye I, Mouchamps M, Misson JP. Spontaneous arachnoid cyst rupture in a previously asymptomatic child: a case report. *Eur J Paediatr Neurol.* 2004;8:247-51
- Gil-Gouveia R, Miguens J, Coiteiro D. Rupture of middle fossa arachnoid cyst simulating new-onset migraine with aura. *Headache.* 2010;50:314-9.
- Longatti P, Marton E, Billeci D. Acetazolamide and corticosteroid therapy in complicated arachnoid cyst. *Childs Nerv Syst.* 2005;21:1061-4.

# Protocolo de Actuação Hospitalar na Abordagem de Mordedura de Ofídio

## Hospital Protocol for Snakebite Victims Management



Pedro MARQUES DA COSTA<sup>1,2</sup>, Rodrigo SOUSA<sup>1</sup>, Maria LOBO ANTUNES<sup>1</sup>, Sara AZEVEDO<sup>1,2</sup>, Gabriela ARAÚJO E SÁ<sup>1,2</sup>, Maria do Céu MACHADO<sup>1,2</sup>  
 Acta Med Port 2014 Jan-Feb;27(1):141-145

### RESUMO

A mordedura de ofídio venenoso é uma situação rara em Portugal. Quando ocorre em idade pediátrica apresenta maior gravidade e risco de complicações fatais. A actuação protocolada constitui o *gold standard of care* nos centros internacionais. Neste artigo apresentamos dois casos clínicos de mordedura de ofídio venenoso em idade pediátrica. Baseados na literatura actual, discutimos a actuação clínica tomada e expomos uma proposta de protocolo de actuação hospitalar que visa uma intervenção multidisciplinar e actualizada das equipas médicas envolvidas.

**Palavras-chave:** Antivenenos; Mordeduras de Serpentes; Portugal.

1. Departamento de Pediatria. Hospital de Santa Maria. Centro Hospitalar Lisboa Norte. Lisboa. Portugal.

2. Faculdade de Medicina. Universidade de Lisboa. Lisboa. Portugal.

Recebido: 18 de Fevereiro de 2013 - Aceite: 08 de Setembro de 2013 | Copyright © Ordem dos Médicos 2014



Inês Brás MARQUES, J. VIEIRA BARBOSA

# Arachnoid Cyst Spontaneous Rupture

Acta Med Port 2014;27:137-141

Publicado pela **Acta Médica Portuguesa**, a Revista Científica da Ordem dos Médicos

Av. Almirante Gago Coutinho, 151  
1749-084 Lisboa, Portugal.

Tel: +351 218 428 215

E-mail: [submissao@actamedicaportuguesa.com](mailto:submissao@actamedicaportuguesa.com)

[www.actamedicaportuguesa.com](http://www.actamedicaportuguesa.com)

ISSN:0870-399X | e-ISSN: 1646-0758



ACTA MÉDICA  
PORTUGUESA

