

Hypertension, hemorrhagic stroke and smoking cessation

María Reverte^{1,2}, Sergio Aparicio-Eroz³, Raquel López de la Fuente⁴

¹ Instituto de Neurociencias de Castilla y León, Universidad de Salamanca, Spain

² Departamento Fisiología y Farmacología, Facultad de Medicina, Universidad de Salamanca, Spain

³ Hospital Clínico Universitario de Salamanca, Universidad de Salamanca, Spain

⁴ Departamento de Medicina, Facultad de Medicina, Universidad de Salamanca, Spain

key words: stroke • smoking cessation • hypertension • cardiovascular risks • bupropion

SUMMARY

Background: Smoking cessation is considered as a good solution for stroke prevention. Unfortunately, first-line therapies to reduce cigarette smoking are not always useful. Some clinical effects of these drugs are able to produce cardiovascular adverse events.

Case report: We present the case of a woman with hypertension, well treated with bisoprolol, who has a nonfatal hemorrhagic stroke event due to an exacerbation of baseline hypertension. The addition of an atypical antidepressant for smoking cessation to her antihypertensive treatment would be the cause of this cerebrovascular accident.

Conclusions: Drug therapy is a logical approach. A rational therapeutic decision includes selecting patients and specific drugs. Perhaps, bupropion, an atypical antidepressant, may not be useful for smoking cessation if patients are hypertensives and well treated with specific drugs. This drug is unable to reduce cardiovascular risks in those patients.

BACKGROUND

Control of risk factors and enhancement of protective factors are the keystones to avoid hemorrhagic stroke [1]. Smoking cessation is important for the prevention of this illness [2]. The use of pharmacological agents to control tobacco addiction is irrefutable [3,4]. Unfortunately, first-line therapies are not always safe [4,5]. Some of these drugs are able to induce cardiovascular adverse events. Here, we present a case of a hypertensive patient with a hemorrhagic stroke due to drug-drug interaction, by the addition of an atypical antidepressant for smoking cessation to her well control antihypertensive treatment.

CASE REPORT

A 44-year-old woman was referred to the hospital because of left frontal headache, nausea and vomiting. On admission, the patient was conscious and had a blood pressure of 200/100 mm Hg. The neurological examination revealed a mild motor aphasia, a left hemiparesis and a slight neck retraction. The patient was diagnosed 10 years ago of essential hypertension and treated with bisoprolol (10 mg per day). She had

also been a smoker for 25 cigarettes per day, but she had discount smoking approximately 2 months ago. 10 days before she stopped smoking she began to be treated with bupropion (150 mg per day). The laboratory studies were all normal, except for a high plasma glucose levels (200 mg/dl). Computerized tomography, an established tool for the diagnosis of stroke [6], demonstrated different signs of acute haemorrhagic stroke (Figure 1).

DISCUSSION

Per se smoking and hypertension are established risk factors for hemorrhagic stroke in men [2,7]. In both cases pharmacological agents could be used to favour smoking cessation [4] and reduce blood pressure levels [8]. However, the combination therapy using an antihypertensive drugs and antidepressants for to treat both diseases at the same time may not

Author's address: María Reverte, MD PhD, Departamento de Fisiología y Farmacología, Edificio Departamental (S12), Universidad de Salamanca, Campus Miguel de Unamuno, 37007 Salamanca, Spain, email: socorro@usal.es

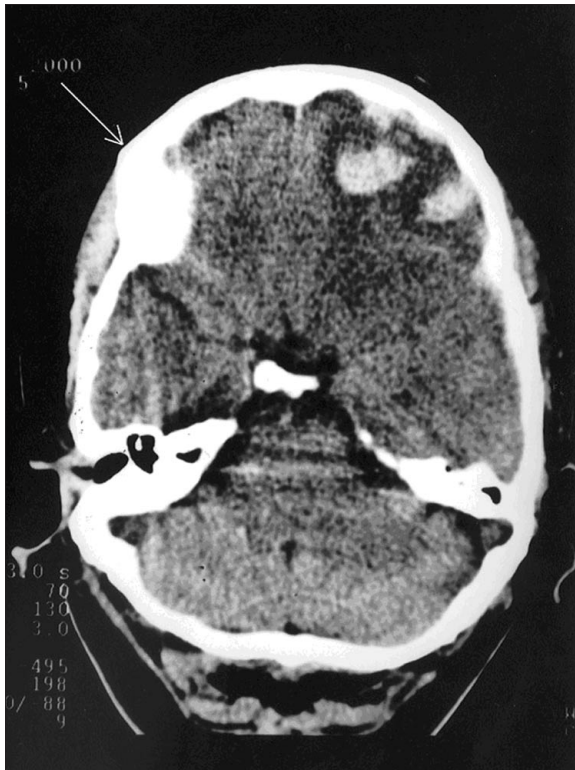


Figure 1. A brain imaging (computerized tomography) of a 44-years-old woman with hemorrhagic stroke due to a drug-drug interaction. The arrow shows the right part of the imaging.

be safer, as we shown in this case report, and not necessary could be related to a drug-drug interaction on CYP2D6 metabolism [9,10].

It is certainly that the rise in blood pressure was the potential mediator that caused the rupture of brain arteries and produced the hemorrhagic stroke in this young woman. In our case report the neurovisualization confirmed the brain damage. Nevertheless, the woman was previously well treated with bisoprolol, a selective β_1 -adrenoceptor antagonist devoid of partial agonist activity that is often used for the treatment of hypertension [11]. Perhaps, the secondary addition of bupropion chronically to the beta-blocker could induce the hypertensive emergency.

Bupropion is an atypical antidepressant using for smoking cessation [5,12,13]. Experimental data have evidenced that this drug is a relatively weak inhibitor of norepinephrine and dopamine reuptake mechanisms. This drug has also an indirect role on serotonin (5-HT) neuronal elements [14]. Bupropion is able to increase plasma norepinephrine levels in rats [15], an important mechanism to develop hypertension and favour stroke [8]. Recently data in healthy male subjects demonstrate that the main mechanism of action

of bupropion is to enhance synaptic availability of norepinephrine by increasing its release [16].

For several authors, hypertension is considered as a confounder factor between the possible connexion of the use of antidepressants and stroke [17]. In general, pharmaceutical products containing bupropion are not related to an increase risk for stroke, although several reports evidence an exacerbation in baseline hypertension [18,19]. We must to observe that in hypertension there is an increase in the density of sympathetic innervation in human and a faulty norepinephrine reuptake [20]. If we give bupropion chronically in combination with a selective β_1 -adrenoceptor antagonist, like bisoprolol, we did not inhibit all the vascular effects of norepinephrine, a neurotransmitter of the sympathetic nervous system that stimuli different subtypes of α - and β -adrenoceptors. In the vast majority of vascular tissues (arteries and veins), α_1 -adrenoceptors-mediated vasoconstriction and α_2 -adrenoceptors-mediated the neural complex system regulating cardiovascular function [21]. A chronic increase in norepinephrine levels could evoke more increase in vascular tone and an overactivation of somatodendritic α_2 -adrenoceptors. Desensitization of α_2 -adrenoceptors, secondary to an increased exposure to the endogenous agonist ligand norepinephrine or prolonged occupation of the norepinephrine transporter [22,23], could produce more hypertension. It is not yet known whether all α -adrenoceptor subtypes are predominantly implicated. Perhaps, in this case report the association between bupropion and bisoprolol, a drug-drug interaction would be the cause of the exacerbation of the hypertension and the production of the hemorrhagic stroke that could never be mention.

CONCLUSIONS

Drug therapy is a logical approached. A rational therapeutic decision includes selecting patients and specific drugs. Perhaps, bupropion, an atypical antidepressant, may not be useful for smoking cessation if patients are hypertensives. This drug is unable to reduce cardiovascular risks in those treated-patients.

REFERENCES:

1. Tamayo A, Hachinski V: Cerebrovascular diseases. In: Melmon and Morrell's Clinical Pharmacology ed. Carruthers SG, Hoffman BB, Melmon KL, Nierenberg DW New York: McGraw-Hill, 2000; 423-436
2. Kurth T, Kase CS, Berger K, et al: Smoking and the risk of hemorrhagic stroke in men. *Stroke*, 2003; 34: 1151-1155
3. Fiore MC, Hatsukami DK, Baker TB: Effective tobacco dependence treatment. *JAMA*, 2002; 288: 1768-1771

4. Watts SA, Noble SL, Smith PO, et al: First-line pharmacotherapy for tobacco use and dependence. *J Am Board Fam Pract*, 2002; 15: 489-497
5. Hughes JR, Stead LF, Lancaster T: Antidepressants for smoking cessation (Cochrane Review). *Cochrane Database Syst Review*, 2003 1: CD000031
6. Lees KR: Management of acute stroke. *Lancet Neurol*, 2002; 41-50
7. Broderick JP, Viscoli CM, Brott T, et al: Major risk factors for aneurismal subarachnoid hemorrhage in the young are modifiable. *Stroke*, 2003; 34: 1375-1381
8. Chalmers J: Trials on blood pressure-lowering and secondary stroke prevention. *Am J Cardiol* 91: 3G-8G
9. Guzey C, Norstrom A, Spigset O: Change from the CYP2D6 extensive metabolizer to the poor metabolizer phenotype during treatment with bupropion. *Ther Drug Monit*, 2002; 24: 436-437
10. Horikiri Y, Suzuld T, Mizobe M: Pharmacokinetics and metabolism of bisoprolol enantiomers in humans. *J Pharm Sci*, 87: 289-94
11. Brodde OE: Bisoprolol, a highly selective β_1 -adrenoceptor antagonist: in vitro and in vivo studies. *J Cardiovasc Pharmacol*, 1986; 8(suppl 11): S36-S40
12. Hausteil KO: Bupropion: pharmacological and clinical profile in smoking cessation. *Int J Clin Pharmacol Ther*, 2003; 41: 56-66
13. Hays JT, Ebbert JO: Bupropion for the treatment of tobacco dependence: guidelines for balancing risks and benefits. *CNS Drugs*, 2003; 17: 71-83
14. Dong J, Blier P: Modification of norepinephrine and serotonin, but not dopamine, neuron firing by sustained bupropion treatment. *Psychopharmacology*, 2001; 155: 52-57
15. Piacentini MF, Clinckers R, Meeuser R, Sarre S, Ebinger G, Michotte Y: Effect of bupropion on hippocampal dopamine, serotonin and noradrenaline and on peripheral hormonal concentrations in the rat: an in vivo study. *J Appl Physiol*, 2003; 95: 652-656
16. Gobbi G, Slater S, Boucher N, Debonnel G, Blier P: Neurochemical and psychotropic effects of bupropion in healthy male subjects. *J Clin Psychopharmacol*, 2003; 23: 233-239
17. Bak S, Tsiropoulos I, Kjaersgaard JO, et al: Selective serotonin reuptake inhibitors and the risk of stroke. *Stroke*, 2002; 33: 1465-1473
18. Roose SP, Dalack GW, Glassman AR, Woodring S, Walsh BT, Giardina EG: Cardiovascular effects of bupropion in depressed patients with heart disease. *Am J Psychiatry*, 1991; 148: 512-516
19. Isbister GK, Balit CR: Bupropion overdose: QTc prolongation and its clinical significance. *Ann Pharmacother*, 2003; 37: 999-1002
20. Esler M, Rumanitir M, Kaye D, Lambert G: The sympathetic neurobiology of essential hypertension: disparate influences of obesity, stress, and noradrenaline transporter dysfunction? *Am J Hypertens*, 2001: 139S-146S
21. Guimarães S, Moura D: Vascular adrenoceptors: An Update. *Pharmacol Rev* 53: 319-356
22. Bawa T, Altememi GF, Eikenburg DC, Standifer KM: Desensitization of $\alpha(2A)$ -adrenoceptor signalling by modest levels of adrenaline is facilitated by $\beta(2)$ -adrenoceptor-dependent GRK3 up-regulation. *Br J Pharmacol*, 2003; 138: 921-931
23. Baldessarì RJ: Drugs and the treatment of psychiatric disorders. In: Goodman & Gilman's *The pharmacological Bases of therapeutic ed.* Hardman JG, Limbird LE, Goodman Gilman A. New York: McGraw-Hill, 2001; 447-483