

Published in final edited form as:

Am J Ophthalmol. 2010 September ; 150(3): 325–329.e1. doi:10.1016/j.ajo.2010.04.018.

Choroidal Thickness in Normal Eyes Measured Using Cirrus-HD Optical Coherence Tomography

Varsha Manjunath¹, Mohammad Taha¹, James G. Fujimoto², and Jay S. Duker¹

¹ New England Eye Center, Tufts Medical Center, Boston, Massachusetts.

² Dept of Electrical Engineering and Computer Science, Research Laboratory of Electronics, Massachusetts Institute of Technology, Cambridge, MA

Abstract

PURPOSE—To examine choroidal thickness and area in healthy eyes using spectral domain optical coherence tomography (SD-OCT).

DESIGN—Retrospective, observational case series

METHODS—Thirty-four eyes (34 subjects), with no retinal or choroidal disease, underwent high definition raster scanning using SD-OCT with frame enhancement software. Choroidal thickness was measured from the posterior edge of the retinal pigment epithelium to the choroid/sclera junction at 500 μm intervals up to 2500 μm temporal and nasal to the fovea. The central 1 mm area of the choroid was also measured, along with foveal thickness of the retina. All measurements were performed by two independent observers. Statistical analysis was used to correlate inter-observer findings, choroidal thickness and area measurements with age, and choroidal thickness with retinal foveal thickness.

RESULTS—The 34 subjects had a mean age of 51.1 years. Reliable measurements of choroidal thickness were obtainable in 74% of eyes examined. Choroidal thickness and area measurements had strong inter-observer correlation ($r=0.92$, $P < 0.0001$) and ($r=0.93$, $P < 0.0001$) respectively. Area had a moderate negative correlation with age ($r=-0.62$, $P < 0.0001$) that was comparable to the correlation between mean subfoveal choroidal thickness and age ($r=-0.61$, $P < 0.0001$). Retinal and choroidal thickness were found to be poorly correlated ($r=-0.23$, $P = 0.18$). Mean choroidal thickness showed a pattern of thinnest choroid nasally, thickening in the subfoveal region, and then thinning again temporally. Mean subfoveal choroidal thickness was found to be 272 μm (SD, +/- 81 μm).

CONCLUSIONS—Choroidal thickness can be measured using SD-OCT high definition raster scans in the majority of eyes. Choroidal thickness across the macula demonstrates a thin choroid nasally, thickest choroid sub-foveally, and again thinner temporally, and a trend toward decreasing choroidal thickness with age.

© 2010 Elsevier Inc. All rights reserved.

Corresponding Author/Reprint Requests: Jay S. Duker, MD New England Eye Center Tufts Medical Center 800 Washington Street, Boston, MA 02111 Phone: 617-636-4677 Fax: 617-636-4866 Jduker@tuftsmedicalcenter.org.

Publisher's Disclaimer: This is a PDF file of an unedited manuscript that has been accepted for publication. As a service to our customers we are providing this early version of the manuscript. The manuscript will undergo copyediting, typesetting, and review of the resulting proof before it is published in its final citable form. Please note that during the production process errors may be discovered which could affect the content, and all legal disclaimers that apply to the journal pertain.

Introduction

The introduction of optical coherence tomography¹ (OCT) into clinical practice has changed ophthalmology, and with progression of new technology, the ability to obtain a true, non-invasive “optical biopsy” of the posterior segment is almost achievable. With advancements in OCT image processing software, more refined details of the posterior segment can be appreciated and characterized *in vivo*. The choroid plays a vital role in the pathophysiology of many diseases affecting the retina but adequate visualization of the choroid using OCT has not been possible until recently. Spaide et al recently reported the successful examination and measurement of choroidal thickness in normal and pathological states using the Heidelberg Spectralis (Heidelberg Engineering, Heidelberg, Germany) OCT instrument.²⁻⁷ The Spectralis offers eye tracking technology and the capability to capture up to 100 B-scans in the same position for OCT signal averaging^{8, 9} and enhancement. Furthermore, Spaide demonstrated the ability of the spectral domain (SD) OCT systems to show an inverted OCT image by moving the device close to the patients’ eye. Since spectral domain detection has highest sensitivity near zero-delay and sensitivity decreases for larger delays, by doing this, the choroid is closer to the zero-delay line, providing enhanced sensitivity and increased imaging depth. OCT imaging with longer wavelengths at 1060 nm (compared to 800 nm used in commercial OCT systems) has also been shown to increase signal penetration into the choroid and optic nerve head.¹⁰⁻¹⁵ Ikuno et al have recently characterized normal choroidal thickness in Japanese subjects using a 1060 nm based light source.¹⁶ The aim of this study was to evaluate another commercially available spectral domain device, Cirrus-HD OCT (Carl Zeiss Meditec, Inc., Dublin, CA) to see if its new software, which permits acquisition of 20 B-scans simultaneously in a single raster line scan, would allow accurate measurement of choroidal thickness and area in normal eyes using previously proposed measurement techniques.³

The SD Cirrus HD-OCT light source is centered on 800 nm wavelength, achieving 5 μ m axial resolution in tissue. Previously, the full thickness of the choroid could not be seen in most eyes due to scattering and insufficient light penetration beyond the retinal pigment epithelium (RPE), as well as, signal strength roll-off distal to the zero-delay line. Selective pixel profiling™ available in the newest version 4.5 software generates high definition 1 line raster image from 20 B-scans taken at a single location. This processing software is comparable to frame averaging, but unique in that images are generated by evaluating all of the pixel data to reduce noise and construct the best possible image. Decreased signal strength posterior to the RPE is compensated by this image enhancement software which enables visualization of the border where choroidal tissue meets sclera and allows choroidal thickness measurements to be performed.

Methods

A retrospective analysis was performed on 34 eyes of 34 normal patients, who underwent high definition 1 line raster scanning at the New England Eye Center, Tufts Medical Center, Boston, MA between November and December 2009. Medical chart review was done to identify patients with no retinal or choroidal pathology. Patients with a myopic refractive error of greater than minus 6.0 diopters were excluded from this study. Cirrus HD-OCT scans were obtained from patients as part of a comprehensive dilated ophthalmological exam, as well as from undilated healthy volunteers with no visual complaints or history of ocular pathology.

The 1 line raster is a 6 mm line consisting of 4096 A-scans. The images were taken in the usual manner and were not inverted to bring the choroid in closer proximity to the zero delay line, as image inversion using the Cirrus software results in a low resolution, pixilated

image. To be included in this study, images had to be at least 6 out of 10 in intensity and taken as close to the fovea as possible, by choosing to image the thinnest point of the macula, with the understanding that slight differences in positioning could affect the measured thicknesses. One eye per patient was selected for measurements. If images from both eyes met inclusion criteria, then the eye in which the choroid/sclera border could be most clearly visualized was selected. Of the 34 eyes, 13 right eyes and 21 left eyes were measured in this study. Using the Cirrus linear measurement tool, two independent observers measured choroidal thickness perpendicularly from the outer edge of the hyper-reflective RPE to the inner sclera at 500 μm intervals temporal and nasal from the fovea, up to 2500 μm (Figure 1). Furthermore, the central foveal thickness was also measured at this time in order to determine the correlation between retinal thickness and choroidal thickness.

Additionally, the area of the choroid in the central 1mm region, 500 μm temporal and nasal to the fovea was also measured on all images (Figure 1). The 1 line raster images were exported to publicly available research analysis software, ImageJ (<http://rsbweb.nih.gov/ij/>). In order to generate measurements equivalent to Cirrus software, the scale was set by drawing a line over a line of a known distance, adjusting the pixel aspect ratio to 0.5, and setting global measurements in microns. The area of interest was then outlined and calculated in μm^2 . Two independent observers measured the same area on all normal scans in order to correlate findings.

A Pearson correlation was applied to choroidal thickness and area with respect to age and central foveal thickness compared to choroidal thickness. A *P* value of < 0.01 was considered statistically significant. All statistics were calculated using SPSS software (Version 17.0 for Windows, SPSS Inc, Chicago, IL, USA).

Results

Of the 34 subjects, the group consisted of 17 males and 17 females, with an average age of 51.1 years (range, 22 to 78 years). 9 out of 34 were undilated volunteers. All eyes had normal foveal contour with no retinal pathology and no abnormalities of the choroid. The delineation between choroid and sclera could be visualized easily to permit reliable thickness measurements to be performed in 34 out of 46 (74%) of the images evaluated in this study. Examination of the undilated group separately showed that 9 out of 11 (82%) of eyes could be measured. Considering the remaining 10 dilated eyes that measurements could not be obtained in, 6 eyes had 1-2+ nuclear sclerotic cataract (NSC) and 2 had posterior chamber intraocular lens (PCIOL).

In these 34 eyes, choroidal thickness measurements had strong inter-observer correlation overall ($r = 0.92$, $P < 0.0001$) and at each of the 11 measurement locations (Table 1). Average thickness of the choroid beneath the fovea was 272 μm (SD, $\pm 81 \mu\text{m}$).

Mean choroidal thickness at each location was plotted, and the choroid was noted to be thinnest nasally, thicker in the subfoveal region and then thinner again temporally, however not as thin as the choroid proximal to the disc (Figure 2). This pattern was in agreement with previous studies of choroidal thickness in normal eyes.^{2, 3, 16} The correlation of central foveal thickness of the retina with choroidal thickness in the area directly beneath the fovea was also examined. A weak correlation between the two measurements ($r = -0.23$, $P = 0.18$) was found, suggesting that retinal thickness may not be directly related to choroidal thickness in normal eyes.

The average cross-sectional area of the choroid in the central 1mm region in the 34 eyes was 0.27 mm^2 . There was strong inter-observer correlation for the area measurements ($r = 0.93$, $P < 0.0001$). There was a moderate negative correlation between age and area ($r = -0.62$, $P <$

0.0001). In this study, the correlation between age and central 1 mm area to be comparable to the correlation between age and average choroidal thickness beneath the fovea ($r = -0.61$, $P < 0.0001$).

Discussion

The choroid is a highly vascular tissue, necessitating *in vivo* imaging to accurately determine its true structure and thickness. Until recently, information regarding choroidal thickness in normal eyes was based primarily on histological results, which do not necessarily reflect the true measurements of this dynamic tissue. OCT has been well established as an accurate imaging study of known retinal pathology through good correlation between histology of animals and humans *in vivo*¹⁷; however exact correlation between OCT and histology is limited since histological fixation produces artifacts due to processing, tissue deformation, and shrinkage.¹⁸ Recent studies by Spaide et al demonstrated the potential to image choroidal structure and thickness using new OCT imaging techniques with one commercially available spectral domain OCT instrument, the Heidelberg Spectralis. Already, this OCT imaging technique has revealed novel findings of choroidal thickness in known diseases such as central serous chorioretinopathy⁵ and myopic degeneration⁴, and helped define new entities such as age-related choroidal atrophy.⁶

Since 2006, a variety of spectral domain OCT instruments have become commercially available, therefore determining if choroidal thickness measurements were possible using another one of the commonly used spectral domain OCT devices is of interest. This report confirms that another simple, reproducible method for choroidal measurement using the Zeiss Cirrus HD-OCT device is possible in the majority of eyes. Reliable measurements of choroidal thickness were obtainable in nearly three quarters of examined eyes (74%). The results of this study were very similar to those reported previously using the Heidelberg OCT device. The mean subfoveal choroidal thickness was found to be 272 μm (SD, ± 81 μm), compared to 287 μm (SD, ± 76 μm) found in the study of normal eyes by Spaide et al.³ As reported previously³, similar variability of choroidal thickness across the macula in normal eyes was observed, with the choroid thinnest proximal to the disc. Additionally, a negative correlation between both area and age and thickness and age was noted, suggesting that progressive choroidal thinning occurs over time in normal eyes, which is a similar finding to previous reports. In addition, this study suggests that area measurements might be another value useful to track changes in choroidal thickness.

The most apparent limitation to this technique is the inability to measure choroidal thickness in all eyes due to an unclear posterior boundary of the choroid (choroid/sclera junction) in approximately 1/4 of eyes (Figure 3). Reasons for this may be a suboptimal number of averaged OCT B scans, the lack of eye tracking software, and the potential for eye movement during imaging with subsequent degradation of the image. Moreover, densely pigmented RPE and even mild cataracts, which were noted in 60% of dilated eyes that could not be measured, can attenuate light penetration, particularly at 800 nm wavelength, which further contributes to obscuration of the choroid/sclera boundary. The frequency at which normal choroidal thickness can be measured in this study and the previously mentioned study of normal choroidal thickness³ cannot be compared as data regarding the percentage of eyes meeting inclusion criteria which could not be successfully measured was not reported.

In the future, segmentation software that could define choroidal thickness and volume might prove to be a valuable measure in tracking choroidal changes. Currently, both Cirrus and Heidelberg OCT devices are limited by the number of lines that can be scanned at one time due to the large numbers of scans that need to be processed or averaged. Therefore, two

dimensional mapping of the choroid thickness across the fundus becomes difficult due to the large number of scans that are required, as well, as lengthy measurement times. Potential new software may also improve image inversion, image averaging, and signal-to-noise ratio, thus further improving visualization of choroidal structures. Studies have demonstrated that imaging at 1050 nm wavelength provides superior choroidal penetration¹³⁻¹⁵; however, the present software enhanced the capabilities of an 800 nm based system to provide good visualization of the choroid.

In summary, choroidal thickness can be measured using Cirrus HD-OCT high definition raster scans in the majority of eyes. Our findings were similar to those previously described using the Heidelberg Spectralis device, including a thinner choroid nasally, thickest choroid sub-foveally, and again thinner temporally, and a trend toward decreasing choroidal thickness with age. Improved in vivo visualization of the choroid and measurement of choroidal thickness using OCT is likely to improve our understanding of a variety of ophthalmic diseases in the future.

Acknowledgments

A. Funding/support: This work was supported in part by a Research to Prevent Blindness Challenge grant to the New England Eye Center/Department of Ophthalmology -Tufts University School of Medicine, NIH contracts R01-EY11289-23, R01-EY13178-10, R01-EY013516-07, Air Force Office of Scientific Research FA9550-07-1-0101 FA9550-07-1-0014, and Massachusetts Lions Eye Research Fund.

B. Disclosures: Dr. Jay S. Duker receives research support from Carl Zeiss Meditec, Inc., Optovue Corporation, and Topcon Medical Systems, Inc. Dr. James G. Fujimoto receives royalties from intellectual property owned by MIT and licensed to Carl Zeiss Meditec, Inc. and LightLabs Imaging. J. Fujimoto is also a scientific advisor and has stock options in Optovue. The authors did not receive any financial support for their work on this study.

C. Contributions of Authors: Design and conduct of the study (VM, MT, JSD); Collection, management, and interpretation of the data (VM, MT, JSD); Preparation and review of the manuscript (VM, JGF, JSD).

D. Conformity: The study was approved by the Institutional Review Board of the Tufts Medical Center and compliant with the Health Insurance Portability and Accountability Act.

E. Other acknowledgements: None

Biography



Varsha Manjunath graduated with high honors with a Bachelor of Science degree from McGill University and is presently between her third and fourth year of medical student at Drexel University College of Medicine. She was awarded the of the Research to Prevent Blindness Medical Student Eye Research Fellowship in 2009 and is currently involved in a one year research fellowship at the New England Eye Center investigating retinal diseases using prototype and commercial optical coherence tomography devices.

References

1. Huang D, Swanson EA, Lin CP, et al. Optical coherence tomography. *Science* 1991;254(5035):1178–81. [PubMed: 1957169]
2. Spaide RF, Koizumi H, Pozzoni MC. Enhanced depth imaging spectral-domain optical coherence tomography. *Am J Ophthalmol* 2008;146(4):496–500. [PubMed: 18639219]
3. Margolis R, Spaide RF. A pilot study of enhanced depth imaging optical coherence tomography of the choroid in normal eyes. *Am J Ophthalmol* 2009;147(5):811–5. [PubMed: 19232559]
4. Fujiwara T, Imamura Y, Margolis R, Slakter JS, Spaide RF. Enhanced depth imaging optical coherence tomography of the choroid in highly myopic eyes. *Am J Ophthalmol* 2009;148(3):445–50. [PubMed: 19541286]
5. Imamura Y, Fujiwara T, Margolis R, Spaide RF. Enhanced depth imaging optical coherence tomography of the choroid in central serous chorioretinopathy. *Retina* 2009;29(10):1469–73. [PubMed: 19898183]
6. Spaide RF. Age-related choroidal atrophy. *Am J Ophthalmol* 2009;147(5):801–10. [PubMed: 19232561]
7. Spaide RF. Enhanced depth imaging optical coherence tomography of retinal pigment epithelial detachment in age-related macular degeneration. *Am J Ophthalmol* 2009;147(4):644–52. [PubMed: 19152869]
8. Ferguson RD, Hammer DX, Paunescu LA, Beaton S, Schuman JS. Tracking optical coherence tomography. *Opt Lett* 2004;29(18):2139–41. [PubMed: 15460882]
9. Sander B, Larsen M, Thrane L, Hougaard JL, Jorgensen TM. Enhanced optical coherence tomography imaging by multiple scan averaging. *Br J Ophthalmol* 2005;89(2):207–12. [PubMed: 15665354]
10. Povazay B, Bizheva K, Hermann B, et al. Enhanced visualization of choroidal vessels using ultrahigh resolution ophthalmic OCT at 1050 nm. *Opt Express* 2003;11(17):1980–6. [PubMed: 19466083]
11. Unterhuber A, Povazay B, Hermann B, Sattmann H, Chavez-Pirson A, Drexler W. In vivo retinal optical coherence tomography at 1040 nm - enhanced penetration into the choroid. *Opt Express* 2005;13(9):3252–8. [PubMed: 19495226]
12. Lee EC, de Boer JF, Mujat M, Lim H, Yun SH. In vivo optical frequency domain imaging of human retina and choroid. *Opt Express* 2006;14(10):4403–11. [PubMed: 19516592]
13. Povazay B, Hermann B, Unterhuber A, et al. Three-dimensional optical coherence tomography at 1050 nm versus 800 nm in retinal pathologies: enhanced performance and choroidal penetration in cataract patients. *J Biomed Opt* 2007;12(4):041211. [PubMed: 17867800]
14. Srinivasan VJ, Adler DC, Chen Y, et al. Ultrahigh-speed optical coherence tomography for three-dimensional and en face imaging of the retina and optic nerve head. *Invest Ophthalmol Vis Sci* 2008;49(11):5103–10. [PubMed: 18658089]
15. Yasuno Y, Miura M, Kawana K, et al. Visualization of sub-retinal pigment epithelium morphologies of exudative macular diseases by high-penetration optical coherence tomography. *Invest Ophthalmol Vis Sci* 2009;50(1):405–13. [PubMed: 18676629]
16. Ikuno Y, Kawaguchi K, Yasuno Y, Nouchi T. Choroidal Thickness in Healthy Japanese Subjects. *Invest Ophthalmol Vis Sci* 2010;51(4):2173–6. [PubMed: 19892874]
17. Chen TC, Cense B, Miller JW, et al. Histologic correlation of in vivo optical coherence tomography images of the human retina. *Am J Ophthalmol* 2006;141(6):1165–8. [PubMed: 16765704]
18. Anger EM, Unterhuber A, Hermann B, et al. Ultrahigh resolution optical coherence tomography of the monkey fovea. Identification of retinal sublayers by correlation with semithin histology sections. *Exp Eye Res* 2004;78(6):1117–25. [PubMed: 15109918]

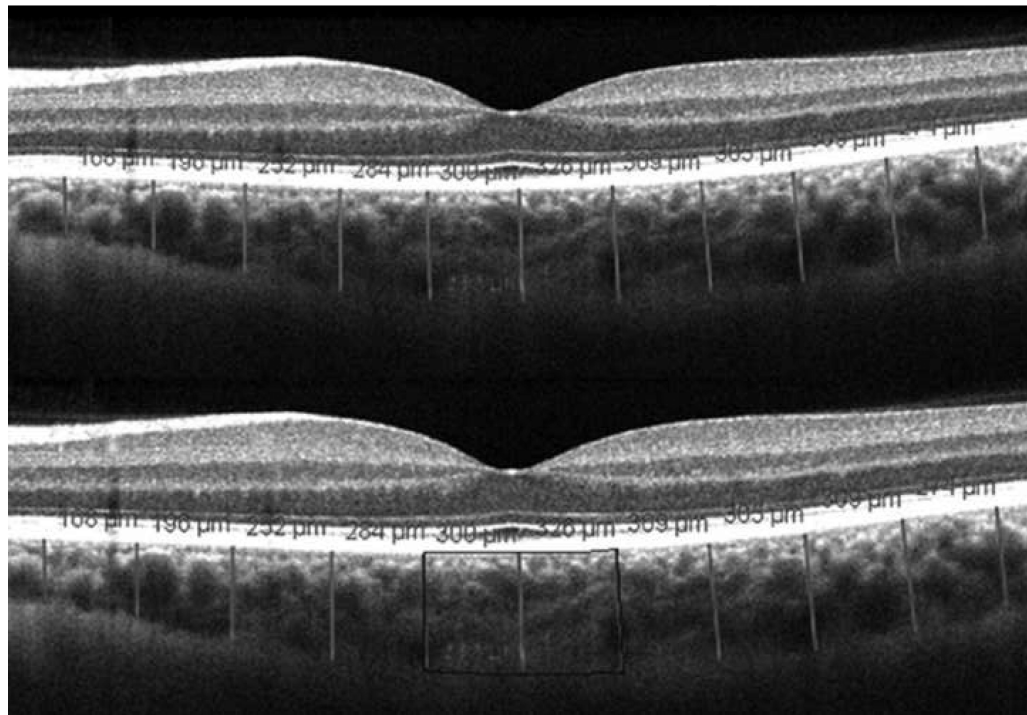


FIGURE 1. Choroidal thickness measurements on Cirrus HD-OCT high definition 1 line raster scans

(Top) Demonstration of normal choroidal thickness measured at 500 μm intervals, up to 2500 μm temporal and nasal to the fovea. Perpendicular lines were drawn from posterior edge of the retinal pigment epithelium to the choroid/sclera junction using Cirrus HD-OCT software. (Bottom) Central 1 mm cross-sectional area of choroid measured using ImageJ analysis software; outlined area is 0.32 mm^2 .

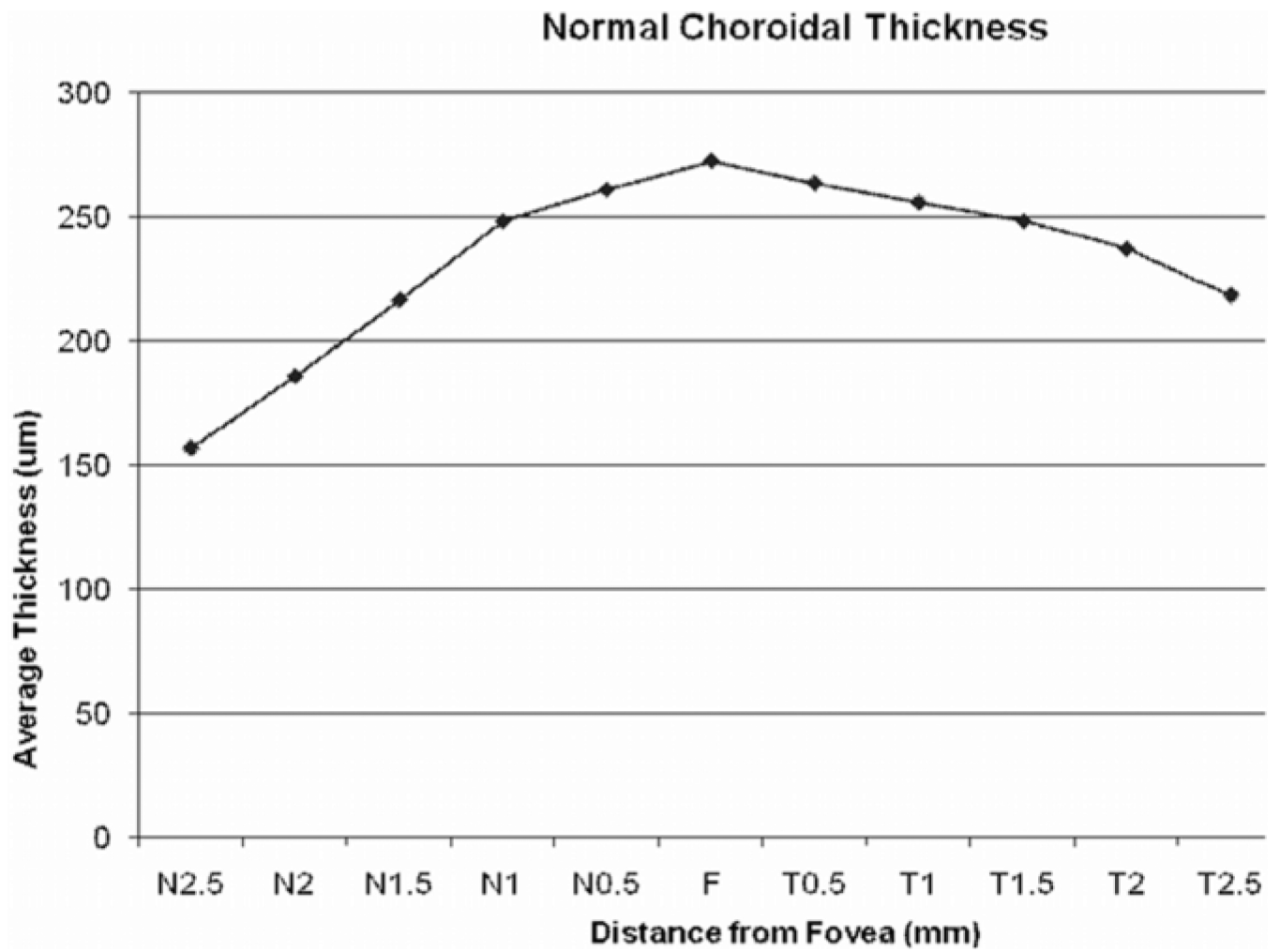


FIGURE 2. Graph of mean macular choroidal thickness in normal eyes
Mean thickness at each of the 11 locations measured at 500 µm (0.5 mm) intervals temporal (T) and nasal (N) to the fovea (F).

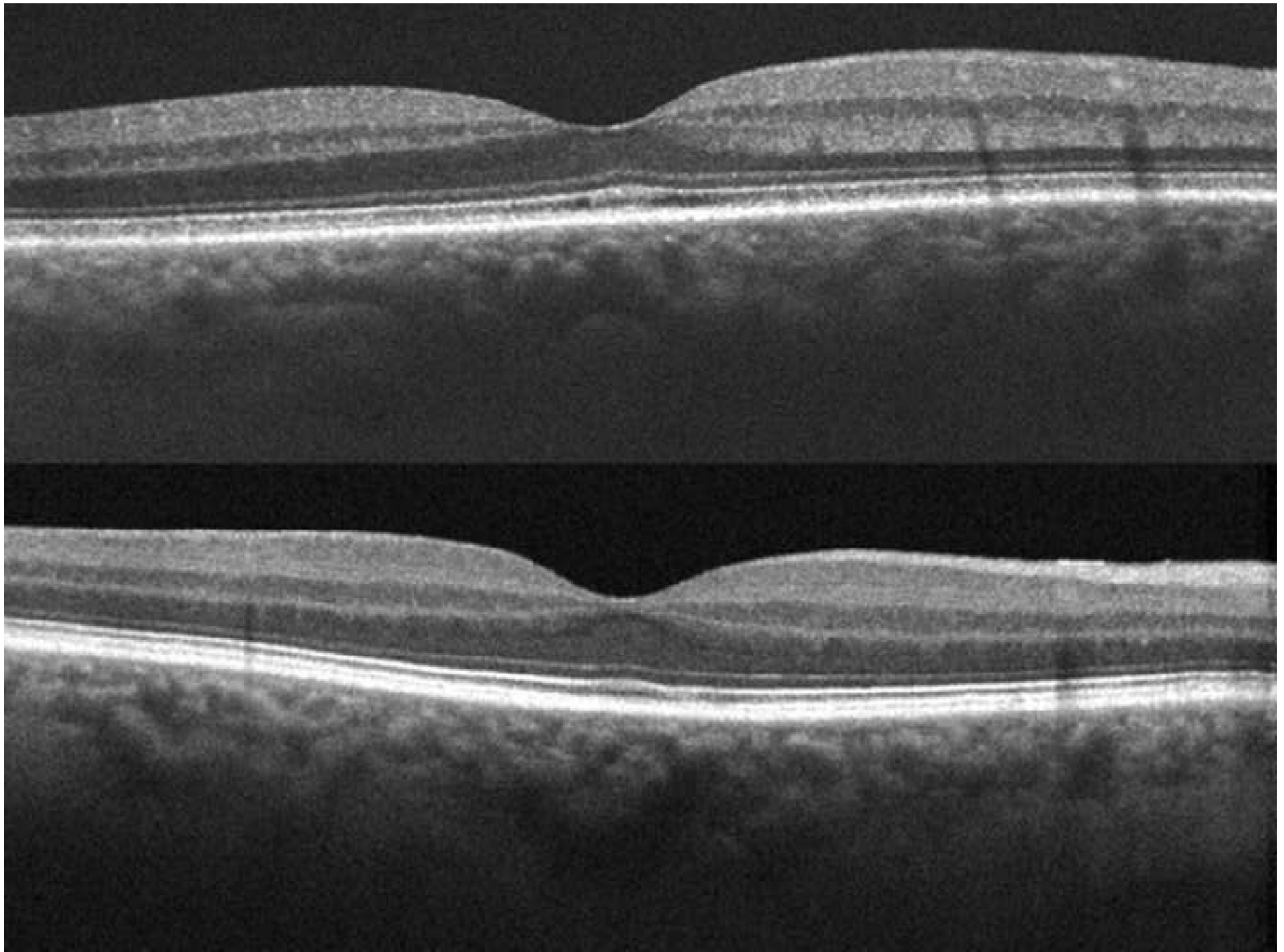


FIGURE 3. Cirrus HD-OCT 1 line raster scans demonstrating poor visualization of posterior choroid/sclera junction

Example OCT images from two different subjects with (Top) 2+ NSC and (Bottom) a PCIOL respectively in which full choroidal thickness could not be assessed and measurements could not be performed.

TABLE 1

Mean Choroidal Thickness and Inter-observer Correlation of Measurements

Location (mm from fovea)	Mean Choroidal Thickness (μm)	Inter-observer Correlation (r)	P value
Temporal 2.5	218	0.88	< 0.0001
Temporal 2.0	237	0.89	< 0.0001
Temporal 1.5	248	0.90	< 0.0001
Temporal 1.0	256	0.88	< 0.0001
Temporal 0.5	264	0.94	< 0.0001
Fovea	272	0.92	< 0.0001
Nasal 0.5	261	0.92	< 0.0001
Nasal 1.0	248	0.90	< 0.0001
Nasal 1.5	217	0.91	< 0.0001
Nasal 2.0	186	0.95	< 0.0001
Nasal 2.5	157	0.94	< 0.0001