

# Osteochemonecrosis of the Jaws due to Bisphosphonate Treatments. Update

Rafael Gómez Font,<sup>1</sup> María Luisa Martínez García<sup>2</sup>, José Manuel Olmos Martínez<sup>3</sup>

(1) Director of the Master in Oral Surgery Program European University at Madrid

(2) Professor in the Master in Oral Surgery Program European University at Madrid

(3) Associate Professor of General Pathology. Medicine. University of Cantabria

## Correspondence:

Dr. Rafael Gómez-Font

C/ Meléndez Valdés 10.

28015-Madrid. Spain

E-mail: [rafael.gomez@uem.es](mailto:rafael.gomez@uem.es)

Received: 06/07/2007

Accepted: 15/02/2008

## Indexed in:

-Index Medicus / MEDLINE / PubMed  
-EMBASE, Excerpta Medica  
-SCOPUS  
-Índice Médico Español  
-IBECS

Gómez-Font, R, Martínez-García, ML, Olmos-Martínez JM. Osteochemonecrosis of the Jaws due to Bisphosphonate treatments. Update. *Med Oral Patol Oral Cir Bucal*. 2008 May;13(5):E318-24.

© Medicina Oral S. L. C.I.F. B 96689336 - ISSN 1698-6946

<http://www.medicinaoral.com/medoralfree01/v13i5/medoralv13i5p318.pdf>

## Abstract

Bisphosphonates (BP), were initially used in industry and later as a drug due to their great affinity to osseous tissue, because of their powerful antiresorptive effect as a treatment in various osteopathies, such as osteoporosis, Paget disease or hypercalcemia associated with some malignant tumors, as myeloma or breast cancer.

They are administered orally or intravenously, and although well tolerated, the most frequent side effects are gastrointestinal, in addition to osteonecrosis when they are administered via endovenous.

The aim of this work has been to evaluate the existing publications in accredited scientific literature on bisphosphonates and their action mechanism and the relationship with the appearance of osteonecrosis of the jaws.

Although the mechanism by which osteonecrosis of the jaws develops is not known exactly, there seems to be influence by osteoclast inhibition, antiangiogenic action, an inhibitory effect on the cellular cycle by the keratinocytes, as well as, reinforcement of the chemiotoxic action in oncological patients treated with other drugs.

Clinically, it ranges from a non-specificity of symptoms to lesions such as osteomyelitis with necrosis and osseous sequestrs that may be accompanied by fetor ex oris, with the appearance of many Actinomyces contaminated lesions.

As for published antecedents on osteonecrosis due to bisphosphonate treatment found until 2006: 46.5% had a previous diagnosis of multiple myeloma; 38.8% were patients with metastatic breast cancer; 6.2% patients of metastatic prostate cancer; 4.1% suffered from osteoporosis; 3.5% from other metastatic diseases and 0.8% had Paget disease.

The drugs that seem to have the highest incidence of osteochemonecrosis are: zoledronate, pamidronate, alendronate, risendronate and ibandronate, from the greatest to the least. Additionally, the risk of osteonecrosis being produced is accumulative and may reach 21% in the third year of intravenous bisphosphonate use.

**Key words:** *Osteonecrosis, necrosis due to phosphorus, bisphosphonates, diphosphonates, myeloma, breast cancer, metastatic cancer, Osteoporosis.*

## Introduction

Bisphosphonates (BP), synthesized in the mid 19th century by German chemists, were initially used in industry due to their capacity to prevent the deposit of calcium carbonate, which made them specially useful in avoiding the deposit of calcium salt incrustation in piping and pipelines. Later it was shown that they had great affinity with osseous tissue, where they inhibited the conversion of

amorphous calcium phosphate in hydroxyapatite and they reduced the dissolution speed of the latter (1, 2). From the chemical viewpoint, bisphosphonates are analogous pyrophosphate structures in which central oxygen has been replaced by carbon, which makes these structures have a low bioavailability and facilitates their binding to hydroxyapatite osseous crystals. (2)

The first clinical applications of these drugs, at the end

of the 70s, were due to their great affinity to calcium phosphate and they were used to perform osseous gamma-graphies with Tc99m. They were also used as toothpaste ingredients, given their anti-tartar and anti-plaque effects. But, doubtless it is their powerful anti-resorptive effect which has permitted them to become the treatment of choice for various osteopathies in which there is excessive bone resorption, as are osteoporosis, Paget disease or hypercalcemia associated with some malignant tumors such as myeloma or breast cancer (1, 2, 3).

Administered orally (OA) or intravenously (IV), they are usually well tolerated, but the most frequent side effects are gastrointestinal, although in recent years the existence of osteonecrosis of the jaws has also been described when these drugs are administered via endovenous.

There is similarity between osteonecrosis induced by bisphosphonates and the historical entity of "mandibular necrosis by phosphorous". Phosphorous industry workers suffered severe oral ulcers with great pain, nauseating odor, necrosis with osseous sequestrs that were worsened following dental extraction, and high mortality due to infections. These disorders were also observed in the 20th century in missile industry workers due to contact with white phosphorous, and in the watch industry due to making luminescent watch faces, until protection measures changed in these work areas (1).

**Material and Method**

The aim of this work has been the bibliographical search in MEDLINE, PubMed, and Cochrane Register of controlled Trials between 1996 and 2006 by using the MeSH and the terms: Osteonecrosis, necrosis by phosphorous, bisphosphonates, diphosphonates, Osteoporosis, myeloma, breast cancer, metastatic cancer.

Noteworthy of special attention have been the series of cases with patients of osteonecrosis of the jaws associated with bisphosphonates and also the descriptions of 1 or 2 isolated cases (5, 9, 14, 15).

**Chemical composition**

Bisphosphonates have a chemical composition similar to pyrophosphates, endogenous regulators of osseous mineralization and similar effects. The difference is in the bond of the 2 phosphate groups, which in the case of bisphosphonates are joined by phosphoethers (P-C-P) and in pyrophosphates by phosphoanhydrides (P-O-P). This bond makes them more resistant to pyrophosphatase and to hydrolysis in acid conditions (1, 2). The central ring is essential for bonding the osseous hydroxyapatite and the lateral chains are variable, and they increase the anti-resorptive power of the drug and may be of two types: a terminal amino chain or a cyclic nitrogen chain (R1 or R2) (Figure 1).

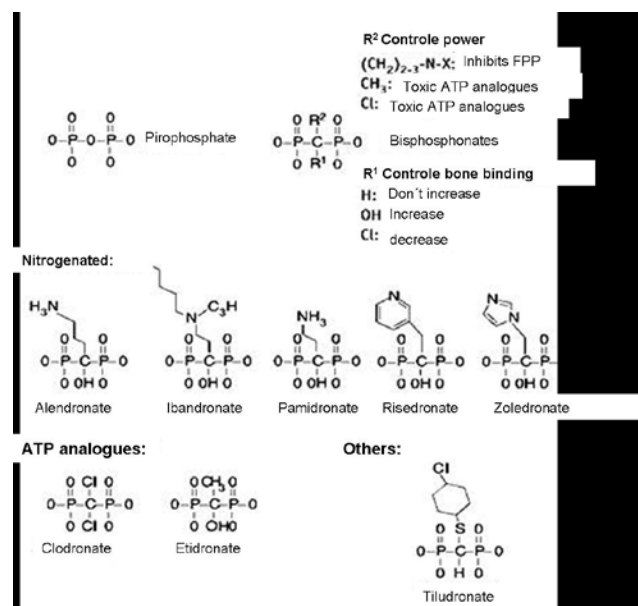


Fig. 1. Chemical structure.

There are two families of these drugs (Table 1):

- 1.- Those containing nitrogen:
  - Alendronate (Fosamax®, MSD)
  - Risedronate (Actonel®, Sanofi-Aventis; Acrel®, Vita Científica)
  - Pamidronate (Aredia®, Novartis)
  - Zoledronate (Zometa®, Novartis)
  - Ibandronate (Boniva®, Roche)
- 2.- Those not containing nitrogen:
  - Etidronate (Difosfen®, Rubio; Osteum®, Viñas)
  - Tiludronate (Skelide®, Sanofi-Aventis) fos®, Schering)

*- Action mechanism and clinical application*

Biphosphonates (BP), powerful inhibitors of osteoclastic activity, have a rather short average lifespan in blood, between 30 minutes and 2 hours, but once they are incorporated into bone, they can remain there for up to 12 years without deteriorating (1,3). The excretion of the drugs is carried out renally without metabolic alteration. BP structure determines their bone binding, their power and their intracellular effects. The oldest and least powerful BPs, such as etidronate, clodronate and tiludronate, the so called first generation BP, are captured by osteoclasts and converted into ATP toxic analogues. Nevertheless, aminobisphosphonates (N-BP) act by means of pharnesildisphosphate synthase inhibition (FPP-synthase), an enzyme involved in cholesterol synthesis from mevalonate. The latter blocks a collateral pathway that controls protein geranyl-geranylation, which leads to inactivation of GTPases and interference in the signal transmission

**Table 1.** Formula, doses, administration vias. ( N-BP= Nitrogenated Bisphosphonates)

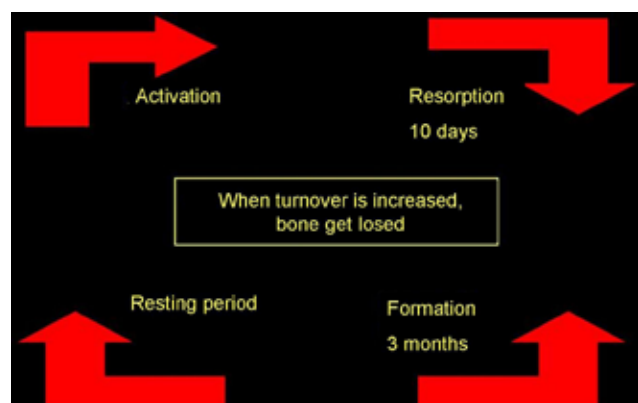
Name	Doses	Via	Administration	N-BP	Approved by FDA
Ethidronate	400 mg	Oral	Intermittent	No	1977
Clodronate	800 mg	Oral	Daily	No	Not approved in USA; Yes in U.E.
	300 mg	IV	Intermittent		
Tiludronate	200mg	Oral	Intermittent	No	1997
Pamidronate	30 a 90 mg	IV	Intermittent	Yes	1991
Alendronate	10 mg	Oral	Daily	Yes	1995
	70 mg	Oral	Weekly		
Risedronate	5 mg	Oral	Daily	Yes	1998
	35 mg	Oral	Weekly		
Zoledronate	4-5 mg	IV	Intermittent	Yes	2001
Ibandronate	2,5 mg	Oral	Daily	Yes	2003-2005-2006
	150 mg	Oral	Monthly		
	3 mg	IV	Intermittent		

of some cytokines, with the consequent inhibition of osteoclastic activity. Apoptosis of the osteoclasts is also induced, but, unlike what occurs with first generation BP, the apoptosis does not constitute a necessary step in resorption inhibition (2).

The capacity of BP to inhibit osteoclastic activity, and the consequent reduction in osseous turnover, has been used to treat various osseous diseases that are characterized by an increase in remodeling (Figure 2). It has been demonstrated that biphosphonates increase osseous mineral density and reduce fractures in women with post-menopausal osteoporosis. These drugs are also efficient in preventing bone mass loss caused by aging, hypoestrogenism and the use of glucocorticoids. Their usefulness has also been shown in the treatment of other processes such as Paget disease, fibrous displasia, osteogenesis imperfecta, heterotopic ossifications and tumoral hypercalcemia. Finally, it has recently been pointed out that BP may exercise an

anti-tumoral effect by hindering the development of osseous metastasis (2, 3, 8). Aminobisphosphonates favor tumoral cell apoptosis and inhibit the binding of the same to the intracellular matriz, therefore hindering tumoral invasion (4, 8). They also possess a certain anti-angiogenic capacity, which would reinforce their anti-tumoral activity (1, 3).

The main limitation of oral bisphosphonates is their poor oral absorption (<1%) and their adverse effects on the digestive tract, above all esophagal irritation. Furthermore, oral administration guidelines are inconvenient for many patients, and it becomes imposible to carry them out on patients confined to bed transitorily or for prolonged periods, thus some compounds have been developed that may be administered intravenously. They are usually well tolerated, although on occasions flu-like manifestations and transitory hypocalcemia are observed. It is also advisable to monitor plasma creatinine, since an adjustment of the dosis or the administration interval may be required in the case of renal insufficiency. Moreover, intravenous BP administration is the form that has most often been associated with the development of osteonecrosis (5, 6, 8, 13) (See Table 1 with doses and forms of administration).



**Fig. 2.** Bone remodeling.

**Pathogenesis of osteonecrosis**

Although the mechanism by which osteonecrosis of the jaws develops is not known exactly, the cause is believed to be constant exposure to crevicular fluid components by means of the periodontal space. The inflammation habitually existing there ,requires increased osseous turnover in order to heal, as happens following a periodontal abscess, caries with pulpal affectation or exodoncy. The inflammation itself favors cytokine and RANKL release whcih act by stimulating resorption (3).

In edentulous patients with badly adapted prostheses, chronic gum and underlying osseous crest irritation could

also favor the development of oral inflammation with an increase in turnover and osteonecrosis. The area most susceptible to suffering this osteochemionecrosis is the alveolar crest and in general, the posterior lingual mandibular region. At times there is some coexisting torus mandibularis which continuously damages the periosteum and mucous membranes. The decrease in bone replacement induced by the bisphosphonates reduces the phenomenon of bone repair, thus favoring the development of areas of sequestrum due to osteomyelitis and osteonecrosis (2, 5). Likewise, the anti-angiogenic property strengthens the ischemic effects found in the area.

Bisphosphonates also produce an inhibitory effect on the keratinocyte cellular cycle, which hinders the habitual mucous repair mechanisms (2, 5, 6).

The accumulative effect of all these actions causes continuous damage to osseous repair when faced with any minimal injury (5).

Another added factor in oncological patients is the administration of other substances such as corticoids and chemotherapies that alter inflammation mechanisms, and on being anti-angiogenic to many of them, they reinforce the chemotoxic action of bisphosphonates (2, 3, 7).

#### *- Clinical injuries and histology*

At times the onset is non-specific; the patient notices certain discomfort around a tooth or simply a mucosa ulceration, with a greater or lesser degree of pain and inflammation. The injuries end up as osteomyelitis with necrosis and osseous sequestrum that may fistulate the skin and be accompanied by acute fetor ex oris (3).

Cases of paraesthesia of the 5th pair mandible ramus have been described, or even total anaesthesia if the necrotic lesions' affection reached the inferior dental canal (9). Many lesions seem contaminated following the microbiological study with *Actinomyces* (2, 5, 10, 11) but it must be taken into account that this bacteria habitually colonizes the oral cavity.

Although histologically the necrosis is similar to that observed in osteoradionecrosis, in the last one alternates dead areas with residual nests of living bone. There are inflammatory infiltration and fibrosis in the medullary spaces in both cases. Regarding blood vessel obliteration, this is greater in osteoradionecrosis (10, 22).

A pseudo-rodent ulcer transformation is also observed instead of necrotic bone (10).

In initial phases, radiology is usually rather inspecific, with the observation of widening of the periodontal ligament indistinguishable from periodontal infection. Subsequently badly defined radiopaque lesions appeared which were accompanied by mandibular fracture in some cases (3).

Risk factors associated with osteochemionecrosis due to bisphosphonates are diverse. Firstly, there is the influence of the type, doses and administration via of these drugs. Most cases have been described in cancer patients who receive high doses of bisphosphonates (mainly zoledronate

and pamidronate) intravenously. In this sense it should be pointed out that the doses used in oncological patients are 12 times higher than those used in osteoporosis. Nevertheless, some cases have also been described in women with postmenopausal osteoporosis who received treatment with oral aminobisphosphonates (10 mg of alendronate daily or 2.5 mg of ibandronate daily) (12).

In a review published by Shane in May 2006 (3), a small number of cases was seen of osteonecrosis in patients treated for osteoporosis and 5 in patients treated for Paget Disease, which represents less than 5% of all osteonecrosis cases published worldwide.

Treatment duration is also a relevant factor. In general exposure to the drug is usually prolonged (from 9 to 14 months), although cases have been seen following short periods of treatment (4 months). On the other hand, the existence of repeated traumatism to the oral mucous membrane or dentoalveolar surgery to treat dental infections difficult to resolve in another manner also seem to influence the development of this process (5,6,12,23).

Finally, smokers, diabetic patients or those with peripheral vascular diseases, as well as those who receive concomitant treatments with corticosteroids, antineoplastics (thalidomide, Bortezomib...) must be evaluated in greater detail (12, 23). Marx et al (24) recently talk about a risk factor which may change our outcome in oral surgery: the morning serum values of CTX terminal telopeptide. If this value is less than 100 pg/ml, osteonecrosis risk is high; if between 100-150 pg/ml, risk is medium. If the value is over 150, risk is low.

## **Results and Discussion**

During the growth period, the skeleton experiences a series of changes that lead to a progressive increase in bone thickness and length ("bone modeling"). Furthermore, once development has finished, the skeleton does not remain inert, rather it continues renewing itself, although without perceivable changes in its shape or size. This continuous renovation process is known as osseous remodeling, and it is carried out through the destruction by osteoclasts of small microscopic tissue units, scattered throughout the skeleton, which are subsequently replaced by new tissue formed by the osteoblasts. The referred units are known by the name of bone remodeling units, BRU, and they are integrated by osteoclasts, osteoblasts, along with the cells derived from the latter (osteocytes) and other accessory cells of uncertain significance. The difference between the amount of bone that is destroyed and that which is formed in each of the BRU is known as "osseous balance" (7). Under normal conditions, its value is zero until the age of 30-40 years, but from this age, there is a slight negative balance of approximately 3%, which explains the bone mass loss produced with ageing and osteoporosis (Figure 3). The speed of osseous renovation, that is to say, the volume of renewed bone in a time unit, is known by the term "replacement" or "bone turnover" (13).

Bisphosphonates bind avidly to hydroxyapatite crystals situated in osseous surfaces, especially in areas of active remodeling and they remain bound to the skeleton during prolonged periods of time, since they are not susceptible to enzymatic degradation by osseous pyrophosphatases. From here they are released and internalized by osteoclasts, in which they provoke a decrease in resorptive activity and therefore in bone turnover. Prolonged treatment with these drugs may cause excessive suppression of remodeling (the so-called “frozen bone”), which determines a reduction in the normal phenomena of bone repair, which would favor the accumulation of microlesions in the skeleton and the consequent appearance of areas of osteonecrosis (5) (Figure 3).

In a review of the 368 cases of osteochemionecrosis following continuous administration of bisphosphonates, published by various authors up to May 2006, 46.5% had prior diagnosis of multiple myeloma, 38.8% was patients with metastatic breast cancer; 6.2% of metastatic prostate cancer; 4.1% suffered from osteoporosis; 3.5% other metastatic diseases and 0.8% was diagnosed with Paget disease (3).

The drugs that produce the greatest incidence of osteochemionecrosis are: zoledronate, pamidronate, alendronate, alendronate, risendronate and ibandronate, from greatest to least (23).

The risk of osteonecrosis being produced is cumulative, and it may reach 21% in the third year of intravenous bisphosphonate use (3, 23).

Marx (6) and Migliorati (2) suggest that bisphosphonates are directly responsible for the osteochemionecrosis in their patients. For Bagan (14) the patients take many contributing drugs in the cases that they present: tamoxifene, cyclophosphamide, 5-fluorouracil, adriamycin, thalidomide.....

For Marx (6) 77 % of their cases appear following exodonties, likewise for 70 % of Bagán’s cases (14), for the remainder this is not true. 39% of the cases presented by Farrugia et al. had a prior dental treatment (13). Pastor (15) relate in their 3 documented cases prior dental extraction. Melo (9) describe it as an antecedent in most of their 11 cases.

In general, there is 60% incidence in mandibula, 30% in upper jaw and the remainder in both (3, 23).

For Hansen (10) there are more cases in men, while for Marx (6) the 3:2 ratio favors women.

The risk of suffering osteochemionecrosis in patients who take oral aminobisphosphonates (for example, alendronate), after undergoing a dental treatment such as exodony, implants or periodoncy is unknown, although there are very few described cases. Gonzalez Moles et al (21) describe ulcerations in the oral mucous membranes of patients treated with oral bisphosphonates in osteoporosis treatment. Starck (16) describe a case of mandibular osteonecrosis in a patient treated with aminobisphosphonates due to her osteoporosis, following the fitting of osseointegrated implants. On the other hand, according to a study by Narai (17) following the administration of alendronate to rats with induced osteoporosis and then fitting them with implants, the removal torque increased significantly.

Bone remodeling and resorption play an important role in normal bone homeostasis. When osteoclastic action begins, there is a release of cytokines and growth factors toward essential osseous matrix which are essential for maturing of new bone. Inhibition of new bone formation may affect bone quality during growth and the healing of fractures. Cases of children’s bones in growth are documented with a great degree of esclerosis in the meta-

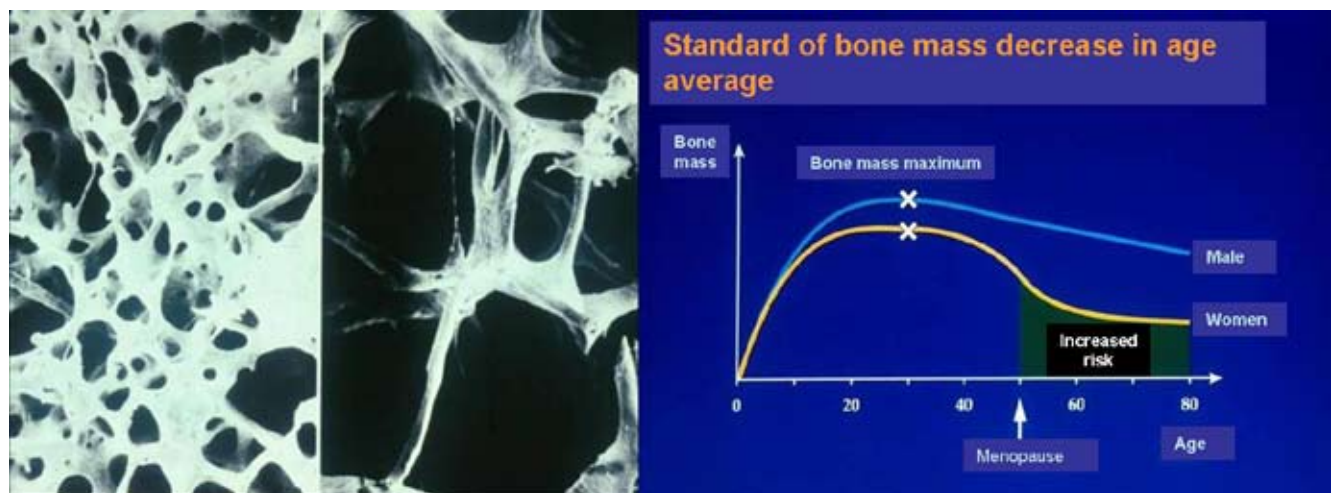


Fig. 3. Normal and osteoporotic bone and gold standar of bone mass with the age.

fisaria area (osteopetrosis) after receiving bisphosphonate treatment for 2 years (18,19,20).

Some cytokines activate resorption and during this process some substances are released that are buried in bone matrix (growth factors) that carry out an important role in the “hook” process. On the other hand, it is not demonstrated that treatment with BP delays the consolidation of fractures, at least in adults. Furthermore, from the outset BP treatment is counter-indicated in children, because of this and other actions (18,19,20).

Pamidronate and many other bisphosphonates have been associated following IV administration with an acute reaction phase with fever, (pseudogripal symptoms which have not been given importance), and the release of various cytokines such as interleukine 6, TNF - $\alpha$ . reactive C protein and elastase (5).

- Preventive recommendations

In June 2004 a panel of experts proposed a series of recommendations for handling patients with osteochemionecrosis of the jaws treated with aminobisphosphonates (3). Patients were classified into three groups:

- 1.- Those that are going to begin therapy. Here patients with osteoporosis treated with oral alendronate type aminobisphosphonates are included.
- 2.- Patients without osteonecrosis in aminobisphosphonate therapy.
- 3.- Patients with osteochemionecrosis.

The preventive treatment that must be given to each group of patients is shown in Table 2 and it is the same one that is received by patients who are going to undergo radiation to the head and neck, as well as those who are going to have a bone marrow transplant (23,24,25,26).

Handling patients with osteochemionecrosis established in the jaws is very complex. Surgical debridement is not effective and may even enlarge the lesions. There are no security margins of viable bleeding bone as in the treatment of osteoradionecrosis (5,9). Neither has therapy with hyperbaric oxygen been effective. When bone is left exposed

vinyl pluggers may be adapted to cover it, while taking into account that they themselves may microtraumatize the soft tissue and aggravate the situation (2).

The best option seems to be rather long term therapy with systematic antibiotics, (penicillins with clavulanic acid, metronidazol, doxycycline in allergic patients and clyndamicine) and 0.12% chlorhexidine rinses, 3 or 4 times a day, according to all authors consulted (2,3,5,8,9,23). Follow-up every 2 or 3 weeks to evaluate the lack of supuration or pain is necessary, although in many cases the lack of healing or mucosa closing is confirmed. The most aggressive surgical treatment is not well approved now and, physicians better survey the oral lesions and go with the conservative measures (23,24).

The patient must be informed of the risk of any oral operation if he is going to treated long term with aminobisphosphonates, and he must weigh the pros and cons with the internist, the oncologist and the odontologist (2).

There is a wide ranging discussion on whether or not to suspend bisphosphonate therapy once lesions have been produced (2,3,13,15). The motive is the long bone permanence of the drugs, even years later. On the other hand, if they are suspended, the antiangiogenic effect ceases and they could improve soft tissues and periostio. Marx (6) recommends suspending the therapy for 2 months and continuing the oral hygiene measures, antibiotics and oral lesion follow-up every 3-4 months. However, the same author recently (24) talk about “therapeutic holidays” of bisphosphonates during 6-9 months in order to recover CTX values out of 25,9 pg/ml each month ,and cross the risk area.

There is controversy regarding oseointegrated implants, and much shortage of studies, but in general, it is recommended to avoid them as any other surgical procedure. Patients treated with alendronate or any other oral aminobisphosphonate must also be warned of the risks, but this should be done by telling them that there are very few cases described of osteochemionecrosis in oral treatments, which is probable due to the low doses and slight potency.

**Table 2.** Purposes of preventive measures for patients treated with aminobisphosphonates (10).

Patients	Treatments
<b>Group 1</b>	Treat active oral infections, impacted teeth, Eliminate teeth not able to be restaured and periodontal one with bad prognose. Dental appointments/ 6 months.2 prophylax /year. Endodontics and caries treatment.
<b>Group 2</b>	< 3 months of therapy:= treatment than group 1 >3 months of therapy: avoid surgical procedures (endodontics, scaling and debridgement).Administrate systemic antibiotics. Simple dentalextraction with small bone manipulation and survey until healing.
<b>Group 3</b>	= as group 2 with > 3 months of therapy .Diagnose with CT .Necrotic bone extirpation with small trauma .Clorhexidine 0, 12%. Or mouthrinse with H2O2.Antibiotics in monotherapy or combined. Analgesics .Soft layer on oral prótesis until improvement.

If there are already implants, it is advisable to carry out close follow-up and, and if it were to occur, dismantle the protetic structure and leave the implants submerged (1). Wearers of removable prosthesis must be warned of the risks, with the elimination of fin edges and by adapting a tissue conditioner to their inner side (1,2,6,8,9).

## Conclusions

Although incidence is very low in comparison with the millions of treatments prescribed worldwide, osteonecrosis of the jaws constitutes a new complication described in patients treated with bisphosphonates. Most of the cases develop in patients with multiple myeloma or metastatic cancers who receive intravenous treatment with aminobisphosphonates, although there have also been described isolated cases in osteoporotic women treated with oral BP. Preventive odontological treatments must be applied before and during therapy with these drugs, and in general, they must be suspended during a time if lesions are produced until there is improvement in the process, even by considering other therapeutic alternatives.

There still remain many doubts to resolve regarding the subject. In clinical trials carried out with aminobisphosphonates, it has been confirmed that these drugs are effective in reducing osteoporotic fractures, and among the adverse reactions, the incidence of osteonecrosis was minimal or nonexistent. Even with ibandronate IV, the latest to appear, cases of osteonecrosis were not observed in the trials published to date. In fact, the secondary effects observed in clinical trials are those in the technical description sheets of the drugs before their commercialization. Something else is that these consequences may have been observed in habitual clinical practice after carrying out a great number of treatments worldwide. Due to this, it is advisable to publish bibliographical reviews of the casuistry that may appear.

A task force is being organized in the Association for Bone and Mineral Research (ASBMR) to aid scientists, doctors, dentists and oral surgeons in their treatment and recommendations to patients who take bisphosphonates for the treatment of osteoporosis or Paget disease.

## References

- Cheng A, Mavrokokki A, Carter G, Stein B, Fazzalari NL, Wilson DF, et al. The dental implications of bisphosphonates and bone disease. *Aust Dent J*. 2005 Dec;50(4 Suppl 2):S4-13.
- Migliorati CA, Casiglia J, Epstein J, Jacobsen PL, Siegel MA, Woo SB. Managing the care of patients with bisphosphonate-associated osteonecrosis: an American Academy of Oral Medicine position paper. *J Am Dent Assoc*. 2005 Dec;136(12):1658-68.
- Woo SB, Hellstein JW, Kalmar JR. Narrative [corrected] review: bisphosphonates and osteonecrosis of the jaws. *Ann Intern Med*. 2006 May 16;144(10):753-61.
- Green JR. Bisphosphonates: preclinical review. *Oncologist*. 2004;9 Suppl 4:3-13.
- Ruggiero SL, Mehrotra B, Rosenberg TJ, Engroff SL. Osteonecrosis of the jaws associated with the use of bisphosphonates: a review of 63 cases. *J Oral Maxillofac Surg*. 2004 May;62(5):527-34.
- Marx RE. Pamidronate (Aredia) and zoledronate (Zometa) induced avascular necrosis of the jaws: a growing epidemic. *J Oral Maxillofac Surg*. 2003 Sep;61(9):1115-7.
- Olmos Martínez JM, Gonzalez Macías J. Nuevos aspectos del remodelado óseo. Departamento de Medicina Interna. Hospital Universitario Marqués de Valdecilla. Cantabria. en "Introducción: fisiopatología del remodelado óseo". En: Nogués X ed. Formadores de hueso. Barcelona, Scientific Communication Management; 2005: 13-25.
- Ponte Fernández N, Estefanía Fresco R, Aguirre Urizar JM. Bisphosphonates and oral pathology I. General and preventive aspects. *Med Oral Patol Oral Cir Bucal*. 2006 Aug 1;11(5):E396-400.
- Melo MD, Obeid G. Osteonecrosis of the jaws in patients with a history of receiving bisphosphonate therapy: strategies for prevention and early recognition. *J Am Dent Assoc*. 2005 Dec;136(12):1675-81.
- Hansen T, Kunkel M, Weber A, James Kirkpatrick C. Osteonecrosis of the jaws in patients treated with bisphosphonates - histomorphologic analysis in comparison with infected osteoradionecrosis. *J Oral Pathol Med*. 2006 Mar;35(3):155-60.
- Scully C. Potential adverse effects. *Br Dent J*. 2006 Feb 11;200(3):153.
- Shane E, Goldring S, Christakos S, Drezner M, Eisman J, Silverman S, et al. Osteonecrosis of the jaw: more research needed. *J Bone Miner Res*. 2006 Oct;21(10):1503-5.
- Farrugia MC, Summerlin DJ, Krowiak E, Huntley T, Freeman S, Borrowdale R, et al. Osteonecrosis of the mandible or maxilla associated with the use of new generation bisphosphonates. *Laryngoscope*. 2006 Jan;116(1):115-20.
- Bagan JV, Murillo J, Jimenez Y, Poveda R, Milian MA, Sanchis JM, et al. Avascular jaw osteonecrosis in association with cancer chemotherapy: series of 10 cases. *J Oral Pathol Med*. 2005 Feb;34(2):120-3.
- Pastor-Zuazaga D, Garatea-Crelgo J, Martino-Gorbea R, Etayo-Pérez A, Sebastián-López C. Osteonecrosis of the jaws and bisphosphonates. Report of three cases. *Med Oral Patol Oral Cir Bucal*. 2006 Jan 1;11(1):E76-9.
- Starck WJ, Epker BN. Failure of osseointegrated dental implants after diphosphonate therapy for osteoporosis: a case report. *Int J Oral Maxillofac Implants*. 1995 Jan-Feb;10(1):74-8.
- Narai S, Nagahata S. Effects of alendronate on the removal torque of implants in rats with induced osteoporosis. *Int J Oral Maxillofac Implants*. 2003 Mar-Apr;18(2):218-23.
- Brummen C, Hamdy NA, Papapoulos SE. Long-term effects of bisphosphonates on the growing skeleton. Studies of young patients with severe osteoporosis. *Medicine (Baltimore)*. 1997 Jul;76(4):266-83.
- Whyte MP, Wenkert D, Clements KL, McAlister WH, Mumm S. Bisphosphonate-induced osteopetrosis. *N Engl J Med*. 2003 Jul 31;349(5):457-63.
- Glorieux FH, Bishop NJ, Plotkin H, Chabot G, Lanoue G, Travers R. Cyclic administration of pamidronate in children with severe osteogenesis imperfecta. *N Engl J Med*. 1998 Oct 1;339(14):947-52.
- Gonzalez-Moles MA, Bagan-Sebastian JV. Alendronate-related oral mucosa ulcerations. *J Oral Pathol Med*. 2000 Nov;29(10):514-8.
- Markiewicz MR, Margarone JE 3rd, Campbell JH, Aguirre A. Bisphosphonate-associated osteonecrosis of the jaws: a review of current knowledge. *J Am Dent Assoc*. 2005 Dec;136(12):1669-74.
- Estefanía Fresco R, Ponte Fernández R, Aguirre Urizar JM. Bisphosphonates and oral pathology II. Osteonecrosis of the jaws: review of the literature before 2005. *Med Oral Patol Oral Cir Bucal*. 2006 Nov 1;11(6):E456-61.
- Marx RE, Cillo JE Jr, Ulloa JJ. Oral bisphosphonate-induced osteonecrosis: risk factors, prediction of risk using serum CTX testing, prevention, and treatment. *J Oral Maxillofac Surg*. 2007 Dec;65(12):2397-410.
- Bagán J, Blade J, Cozar JM, Constela M, García Sanz R, Gómez Veiga F, et al. Recommendations for the prevention, diagnosis, and treatment of osteonecrosis of the jaw (ONJ) in cancer patients treated with bisphosphonates. *Med Oral Patol Oral Cir Bucal*. 2007 Aug 1;12(4):E336-40.
- Heras Rincón I, Zubillaga Rodríguez I, Castrillo Tambay M, Montalvo Moreno JJ. Osteonecrosis of the jaws and bisphosphonates. Report of fifteen cases. Therapeutic recommendations. *Med Oral Patol Oral Cir Bucal*. 2007 Aug 1;12(4):E267-71.