

Flap repositioning versus conventional suturing in third molar surgery

Jose M. Sanchis Bielsa ¹, Sergio Hernández Bazán ², Miguel Peñarrocha Diago ³

(1) Staff physician, Service of Stomatology, Valencia University General Hospital. Associate Professor of Oral Surgery. Valencia University Medical and Dental School

(2) Degree in Dental Surgery. Associate Professor of Oral Medicine. Valencia University Medical and Dental School

(3) Chairman of Oral Surgery. Valencia University Medical and Dental School. Valencia (Spain)

Correspondence:

Dr. Jose M. Sanchis-Bielsa

Clínica Odontológica

Gascó Oliag 1

46021 - Valencia, Spain

E-mail: sanchisj@uv.es

Received: 9/03/2007

Accepted: 1/12/2007

Indexed in:

-Index Medicus / MEDLINE / PubMed
-EMBASE, Excerpta Medica
-SCOPUS
-Indice Médico Español
-IBECs

Sanchis-Bielsa JM, Hernández-Bazán S, Peñarrocha-Diago M. Flap repositioning versus conventional suturing in third molar surgery. *Med Oral Patol Oral Cir Bucal*. 2008 Feb;13(2):E138-42.

© Medicina Oral S. L. C.I.F. B 96689336 - ISSN 1698-6946

URL: <http://www.medicinaoral.com/medoralfree01/v13i2/medoralv13i2p138.pdf>

Summary

Objectives: A comparative study is made of two types of flaps in semi-impacted third molar surgery and their relation to the postoperative period (pain, swelling and trismus).

Material and methods: Twenty-five healthy patients were subjected to surgical extraction of both semi-impacted lower third molars, located in a similar clinical and radiographic position. In 25 cases the wound was sutured using a reflection flap (healing by first intention), while in the 25 contralateral cases the conventional technique was used (simple approximation of the wound margins). Pain, swelling and trismus were evaluated, during the first week of the postoperative period.

Results: There was lesser pain, swelling and trismus after extraction of a semi-impacted third molar when healing took place by second intention (simple approximation of the margins), than in the case of healing by first intention (flap repositioning and margin-to-margin suturing).

Conclusions: The postoperative course proved worse when using a reflection flap for healing by first intention than on suturing by simple approximation of the wound margins.

Key words: *Third molars, reflection flap, third molar surgery.*

Introduction

Impacted third molar surgery is characterized by postoperative pain, swelling and trismus. These symptoms in turn depend on a number of factors such as the duration of the operation, the difficulty surgery, the magnitude of the osteotomy, the lack of oral hygiene, or the experience of the surgeon (1-3). Regarding the use of flaps, different designs have been used to minimize periodontal damage in the case of second molars (4-7). The postoperative course is worse the larger the raised mucoperiosteal flap (8,9), and there is some controversy over the use of wound healing by first intention or partial closure (wound healing by second intention)(10-12).

In 1936, Rehrmann (13) proposed a flap repositioning technique to secure healing by first intention after the

extraction of lower third molars. With this approach complete wound sealing was achieved, and contamination from the oral cavity was avoided. However, in recent years, some authors (14) have suggested that primary closure of the wound prevents drainage of the latter - thereby worsening the postoperative pain and the swelling. Some authors (11,15) have recommended the possibility of leaving surgical drains in the region of the wound, after observing an improved postoperative course in these patients compared with individuals subjected to primary closure. Recently Waite and Cherala (16) have reported very good results after 1280 surgical extractions of mandibular third molars involving the raising of a small conservative flap that is passively repositioned without suturing.

The present study compares the secondary postoperative

manifestations (pain, swelling and trismus) recorded in 25 patients, after 50 third molar surgical extractions. In 25 cases primary closure of the wound was carried out by means of the Rehrmann sliding flap, while in the other 25 contralateral molars simple closure with healing by second intention was carried out.

Material and Methods

A follow-up study was made of the extraction of impacted mandibular third molars between January 2004 and April 2004. Healthy women were selected, without medication and with the two lower third molars in the same position (and thus presenting similar surgical extraction difficulty). Informed consent was obtained from all the patients. The teeth all presented class II difficulty. The molars were submucosal or class III, and were partially impacted in bone. Erupted (class I) or totally intrabony molars (class IV) were excluded (16). A total of 58 semi-impacted molars were removed in 29 women between 18 and 31 years of age. The following data relating to extraction difficulty were recorded: surgical time, ostectomy time and the need (or not) for tooth sectioning. Four patients that failed to complete the postoperative follow-up were excluded.

Postoperative pain was scored by means of a 10-cm visual analog scale (VAS) from zero (no pain) to 10 (worst pain imaginable). Six and 12 hours after the operation, and then once daily during the subsequent 6 days, the patients scored their pain on the VAS, followed by millimetric measurement to convert to numerical values. The patients also recorded daily analgesic use, in addition to the prescribed medication.

Subjective assessment was made of swelling (on days 2 and 7 postextraction), based on a 4-point scale: 1 = no swelling, 2 = mild swelling (intraoral swelling and edema of the operated zone), 3 = moderate swelling (intraoral and extraoral swelling and edema), and 4 = severe swelling (intraoral, extraoral and facial swelling and edema). Such swelling was measured by both the patient and one of the investigators (SHB).

In order to objectively evaluate swelling, two distances were measured: (a) from a point located at mandibular angle level and marked with henna, to the interincisal point, referred to as the angle - interincisal point distance (AID); and (b) from the tragus to the interincisal point, referred to as the tragus - interincisal point distance (TID). The measurements were made before the operation and again two and seven days after extraction, using a non-extensible measuring tape.

Before surgery, we evaluated oral aperture, measured from the incisal margin of the upper incisor to the incisal margin of the lower incisor, in order to assess postoperative trismus.

Surgical technique

In all cases protocolized molar extraction was carried out, involving the raising of a vestibular triangular mucoperios-

teal flap with distal incision and vestibular release, minimal ostectomy, and tooth sectioning where required.

In each patient, the incision margins were joined and sutured, without closing the wound, on one side, seeking healing by second intention (Technique 1). On the contralateral side the flap was repositioned to allow healing by first intention (Technique 2). Suturing was carried out with 3/0 silk, and a one-month period was allowed to elapse between extraction on one side and extraction on the contralateral side (Figures 1 and 2).

Following the operation, the patients were prescribed amoxicillin 500 mg/8 hours during 7 days, ibuprofen 600 mg/8 hours during 3 days, and magnesium metamizol (575 mg) in the event of pain. All patients were instructed to perform three daily rinses with 0.12% chlorhexidine.

Statistical analysis

The quantitative statistical analysis was carried out using the SPSS (Statistical Package for the Social Sciences) version 10. The categorical variables of interest were correlated using the chi-square test, with mixed factorial analysis of variance (ANOVA) for studying the course of swelling and pain over time. Analysis of covariance (ANCOVA) in turn was used to assess the course of the clinical pain score over time, with statistical control of the number of analgesics used in the 7 days after the operation.

Results

Twenty-five healthy women between 18 and 31 years of age were studied. A total of semi-impacted 50 molars were removed. The mean surgical time was 4.2 minutes (range 2-30 minutes). In 28% of the cases an ostectomy was performed, with tooth sectioning in four cases (two of them coronal and radicular). These variables were homogeneous for both suture techniques studied; as a result, there were no significant differences in the difficulty of the cases.

Postoperative pain

The maximum postoperative pain was recorded after between 6 and 12 hours with both techniques. Although the mean pain was slightly greater with Technique 2, the difference with respect to Technique 1 was not statistically significant ($p > 0.05$) (Fig. 3). Mean analgesic use was similar with both techniques, though after 7 days the patients subjected to Technique 1 required less analgesia (mean 0.5) than those subjected to Technique 2 (mean 2.2) ($t = 0.02$).

Subjective swelling

Swelling as scored by the patient was greater after two days (mean=2.7) than after 7 days (mean=1.3). With Technique 1, swelling was significantly less intense (mean=1.6) than with Technique 2 (mean=2.4) ($p < 0.05$).

Mean swelling scored by the investigator after two days was 2.4, versus 1.1 after 7 days. Significant differences in mean score were recorded according to the surgical technique used ($F = 12.960$, $p < 0.05$) - the mean score with Technique 1 (mean=1.4) being lower than with Technique 2 (mean=2.1) (Fig. 4).

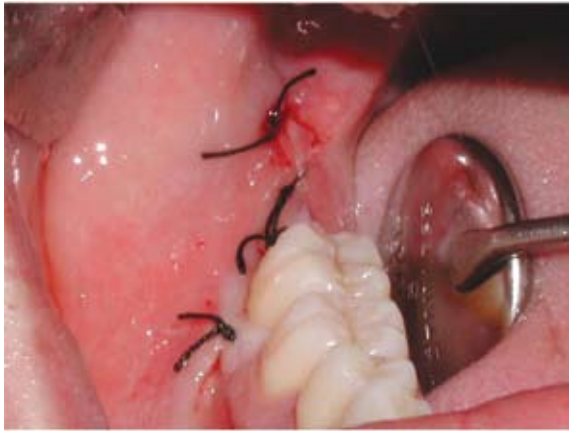

Fig. 1. Closure by flap repositioning. Technique 2 (healing by first intention).

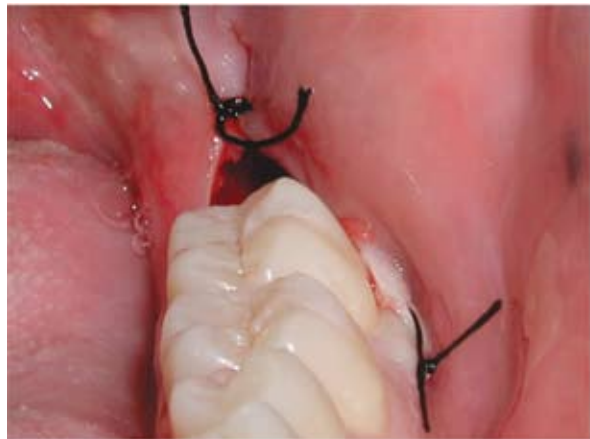

Fig. 2. Closure by approximation of wound margins. Technique 1 (healing by second intention).

Fig. 3. Similar pain score tracings with both techniques, as determined by the patient on a visual analog scale (VAS) ($F=1.578, p>0.05$). Technique 1: Conventional suturing. Technique 2: Flap repositioning.

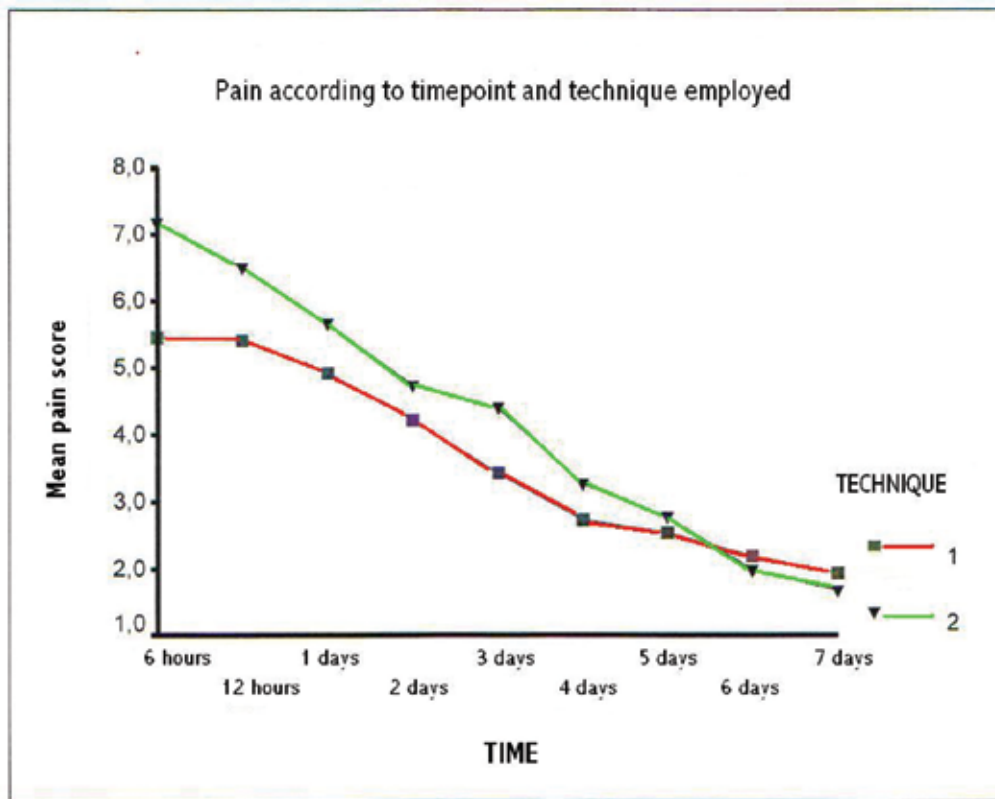
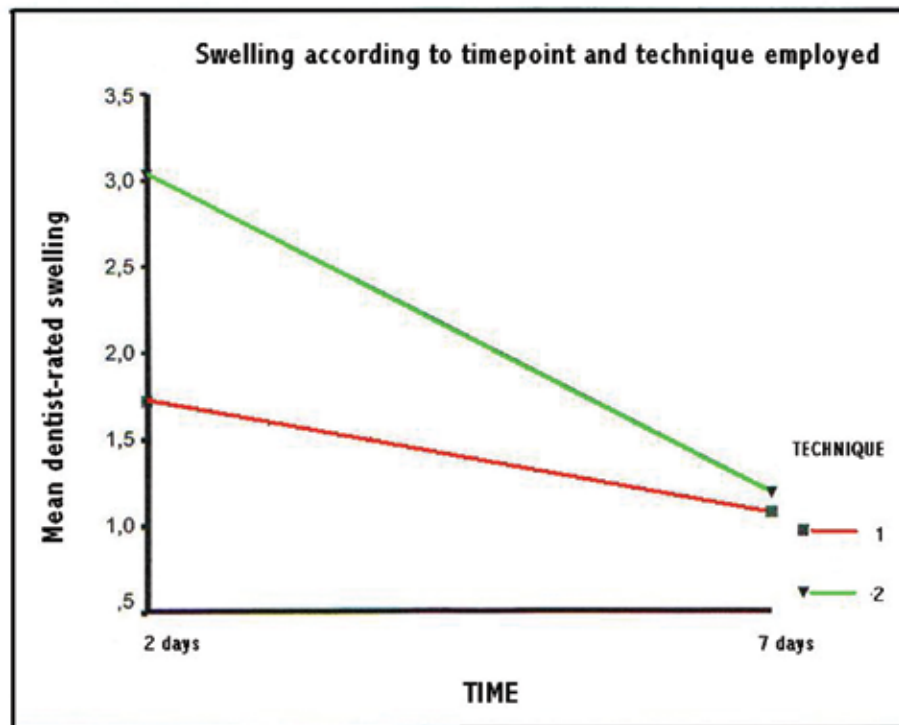


Fig. 4. Subjective swelling as rated by the investigator ($F=12.960$, $p<0.05$). Technique 1: Conventional suturing. Technique 2: Flap repositioning.



Objective swelling

Significant differences were recorded in the mean values according to the surgical technique used ($F=17.33$, $p<0.05$) - the mean increase in AID being smaller with Technique 1 (mean = 0.15 mm) than with Technique 2 (mean = 0.36 mm).

Regarding TID, Technique 1 showed lesser mean swelling (mean = 0.0002 mm) than Technique 2 (mean = 0.12 mm) ($F=15.17$, $p<0.05$).

Trismus

The reduction in oral aperture was significantly greater after two days (mean = 17.5) than after 7 days (mean = 6.4). In addition, differences in trismus were observed according to the surgical technique employed. In effect, Technique 1 showed significantly lesser mean trismus (mean = 9.9) than Technique 2 (mean = 14.1) ($F = 6.960$, $p<0.05$).

Discussion

Different incisions have been proposed in third molar surgery to offer a better surgical field and to minimize postoperative discomfort for the patient (17). With the purpose of securing primary closure of the wound, Jakse et al. (18) reported better results when using a sliding-

sutured triangular flap than when using a mucogingival flap. According to these authors, primary closure of the flap avoids suture dehiscence and improves wound healing. However, in the opinion of other investigators (9,11), healing by second intention, where wound drainage is facilitated, causes less patient discomfort.

The measures of swelling and pain were recorded by means of a visual analog scale (VAS), which according to Berge (19) is an effective (albeit subjective) measurement option. In addition, swelling in our study was also documented by an objective technique involving the measurement of the distance between two facial anatomical points - in a way similar to the procedure adopted by other authors (15). Dubois et al. (10) performed the surgical removal of both lower molars. According to these authors, and coinciding with our own observations, pain and swelling were greater when the surgical wound healed by first intention. Holland and Hindle (20) likewise reported more pain and swelling in those cases where primary closure was carried out. However, after one month the surgical wound showed a better appearance in these patients than in those where closure and healing by second intention was carried out. In contrast, Suddhasthira et al. (21) reported no diffe-

rences according to the type of wound healing involved. Brabander and Cattaneo (11) likewise observed no statistically significant differences in pain, swelling and trismus between two groups of patients subjected to primary flap closure using the conventional technique and to simple wound closure with healing by second intention. Nevertheless, all the data point to a better postoperative course with secondary wound closure. In our series we recorded greater trismus with primary closure.

Some authors (15) suggested primary closure of the flap, but keeping a drain in place during 72 hours. While this measure had no impact upon postoperative pain, it did reduce the swelling. In contrast, Saglam (22) compared the postoperative course of primary wound closure with and without placement of a drain, and recorded lesser pain, swelling and trismus in the latter group.

On the basis of the recent studies published by Pascualini et al. (12), hermetic primary closure of the surgical wound causes more postoperative pain and swelling than simple closure with approximation of the margins.

References

- García García A, Gude Sampedro F, Gandara Rey J, Gallas Torreira M. Trismus and pain after removal of impacted lower third molars. *J Oral Maxillofac Surg.* 1997 Nov;55(11):1223-6.
- Capuzzi P, Montebugnoli L, Vaccaro MA. Extraction of impacted third molars. A longitudinal prospective study on factors that affect postoperative recovery. *Oral Surg Oral Med Oral Pathol.* 1994 Apr;77(4):341-3.
- Peñarocha M, Sanchis JM, Sáez U, Gay C, Bagán JV. Oral hygiene and postoperative pain after mandibular third molar surgery. *Oral Surg Oral Med Oral Pathol Oral Radiol Endod.* 2001 Sep;92(3):260-4.
- Stephens RJ, App GR, Foreman DW. Periodontal evaluation of two mucoperiosteal flaps used in removing impacted mandibular third molars. *J Oral Maxillofac Surg.* 1983 Nov;41(11):719-24.
- Quee TA, Gosselin D, Millar EP, Stamm JW. Surgical removal of the fully impacted mandibular third molar. The influence of flap design and alveolar bone height on the periodontal status of the second molar. *J Periodontol.* 1985 Oct;56(10):625-30.
- Groves BJ, Moore JR. The periodontal implications of flap design in lower third molar extractions. *Dent Pract Dent Rec.* 1970 May;20(9):297-304.
- Nageshwar . Comma incision for impacted mandibular third molars. *J Oral Maxillofac Surg.* 2002 Dec;60(12):1506-9.
- García García A, Gude Sampedro F, Gallas Torrella M, Gándara Vila P, Madriñán-Graña P, Gándara-Rey JM. Trismus and pain after removal of a lower third molar. Effects of raising a mucoperiosteal flap. *Med Oral.* 2001 Nov-Dec;6(5):391-6.
- Clauser C, Barone R. Effect of incision and flap reflection on postoperative pain after the removal of partially impacted mandibular third molars. *Quintessence Int.* 1994 Dec;25(12):845-9.
- Dubois DD, Pizer ME, Chinnis RJ. Comparison of primary and secondary closure techniques after removal of impacted mandibular third molars. *J Oral Maxillofac Surg.* 1982 Oct;40(10):631-4.
- De Brabander EC, Cattaneo G. The effect of surgical drain together with a secondary closure technique on postoperative trismus, swelling and pain after mandibular third molar surgery. *Int J Oral Maxillofac Surg.* 1988 Apr;17(2):119-21.
- Pasqualini D, Cocero N, Castella A, Mela L, Bracco P. Primary and secondary closure of the surgical wound after removal of impacted mandibular third molars: a comparative study. *Int J Oral Maxillofac Surg.* 2005 Jan;34(1):52-7.
- Rehrmann A. Eine methode zur SchlieBungvon Kieferhöhlenperforationen. *Dtsch Zahnärztl Wschr* 1936;39:1136-40
- Flynn TR, Hoekstra CW, Lawrence FR. The use of drains in oral and maxillofacial surgery: a review and a new approach. *J Oral Maxillofac Surg.* 1983 Aug;41(8):508-11.
- Rakprasitkul S, Pairuchvej V. Mandibular third molar surgery with primary closure and tube drain. *Int J Oral Maxillofac Surg.* 1997 Jun;26(3):187-90.
- Waite PD, Cherala S. Surgical outcomes for suture-less surgery in 366 impacted third molar patients. *J Oral Maxillofac Surg.* 2006 Apr;64(4):669-73.
- Alling CC 3rd, Catone GA. Management of impacted teeth. *J Oral Maxillofac Surg.* 1993 Jan;51(1 Suppl 1):3-6.
- Jakse N, Bankaoglu V, Wimmer G, Eskici A, Pertl C. Primary wound healing after lower third molar surgery: evaluation of 2 different flap designs. *Oral Surg Oral Med Oral Pathol Oral Radiol Endod.* 2002 Jan;93(1):7-12.
- Berge TI. The use of a visual analogue scale in observer assessment of postoperative swelling subsequent to third-molar surgery. *Acta Odontol Scand.* 1989 Jun;47(3):167-74.
- Holland CS, Hindle MO. The influence of closure or dressing of third molar sockets on post-operative swelling and pain. *Br J Oral Maxillofac Surg.* 1984 Feb;22(1):65-71.
- Suddhasthira T, Chaiwat S, Sattapongsda P. The comparison study of primary and secondary closure technique after removal of impacted mandibular third molars. *Thai J Oral Maxillofac Surg* 1991;5:67-73.
- Sağlam AA. Effects of tube drain with primary closure technique on postoperative trismus and swelling after removal of fully impacted mandibular third molars. *Quintessence Int.* 2003 Feb;34(2):143-7.