

Oral complaints in progressive systemic sclerosis: Two cases report

Cláudia Cazal ¹, Ana Paula Veras Sobral ², Ridel Frota Sá Nogueira Neves ³, Francisco Wagner Vasconcelos Freire Filho ⁴, Álvaro Bezerra Cardoso ⁵, Márcia Maria Fonseca da Silveira ²

- (1) PhD, Oral Pathology Department of the Dentistry School of CESMAC
 (2) PhD, Oral Medicine Department of the Dentistry School of the University of Pernambuco
 (3) PhD, University of Pernambuco
 (4) PhD, Surgery Department of the Dentistry School of the University of Fortaleza
 (5) MS, Federal University of Paraíba

Correspondence:

Dr. Ana Paula Veras Sobral
 Rua Monte Alverne, 107/05
 Hipódromo – Recife – PE – Brazil
 ZIP Code 52041-610
 E-mail: anapvsobral@yahoo.com.br

Received: 27/01/2007
 Accepted: 6/12/2007

Indexed in:
 -Index Medicus / MEDLINE / PubMed
 -EMBASE, Excerpta Medica
 -SCOPUS
 -Índice Médico Español
 -IBECIS

Cazal C, Sobral APV, Neves RFN, Freire-Filho FWV, Cardoso AB, da Silveira MMF. Oral complaints in progressive systemic sclerosis: Two cases report. *Med Oral Patol Oral Cir Bucal*. 2008 Feb;13(2):E114-8.
 © Medicina Oral S. L. C.I.F. B 96689336 - ISSN 1698-6946
<http://www.medicinaoral.com/medoralfree01/v13i2/medoralv13i2p114.pdf>

Abstract

Progressive systemic sclerosis is a chronic sclerotic disease which causes diffuse, increased deposition of extracellular matrix in connective tissue with vascular abnormalities, resulting in tissue hypoxia. Aesthetic and facial dysfunction are followed by important oral and facial manifestation of disturbances such as xerostomia, the lack of saliva in the mouth, and its associated complications. Most clinical manifestations begin with tongue rigidity. The facial skin changes and bone resorption of mandible angle are often reported. Other systemic changes include the involvement of internal organs which leads to serious complications as well as disorders in the cardiac muscle and Raynaud's phenomenon. The objective of this paper is to report two cases of systemic sclerosis in patients with oral and facial manifestations of the disease. A brief review of the literature, focusing on deontological alterations is also presented.

Key words: *Systemic sclerosis, scleroderma, oral manifestations.*

Introduction

Progressive systemic sclerosis (PSS), also known as scleroderma, is a disorder of the connective tissue characterized by fibrosis of the skin, blood vessels and visceral organs. The involvement of the skin together with the quality of its mobility, particularly in the distal portions of the extremities, is by far the its most obvious symptom. An early indicator of systemic sclerosis is Raynaud's phenomenon, characterized by a painful digital ischemia, which results in local resorption of terminal phalanges. Survival of scleroderma patients is determined by the severity of visceral involvement (1).

Oral and facial tissues are often affected, presenting very characteristic features. Most clinical manifestations begin

with tongue rigidity and classic facial skin hardening, which gives it a classic mask-like appearance. A very limited opening of the oral orifice besides bone resorption at the angle of the mandible are often reported (2-4).

The exact mechanism of the fibrotic changes is unknown, but hyperplastic changes of collagen have been documented (4). Also, inflammatory changes and globulin deposits were found in blood vessel walls, which apparently explain the basis for altered collagen. The pathological findings indicate that fibroblasts are activated to produce excessive amounts of collagen and other components of the cellular matrix. Moreover, an autoimmune mechanism can be involved because patients with systemic sclerosis show high levels of highly specific and non-specific circulating

autoantibodies, i.e., against DNA topoisomerase, centromeric protein B, RNA polymerases II, laminin S and vimentin (5). Whether these genetic alterations are clinically or pathogenetically relevant remains to be seen.

The high prevalence of autoantibodies in serological markers suggests that immune activation of scleroderma is localized and targets skin. Complicated cytokine cascades seem to be involved in the development of this disorder (1). More investigation is required to show that the development of systemic sclerosis is similar to that of localized scleroderma.

PSS is a fatal, multisystem disease. Prognosis is uncertain; abnormal motion of the mandible, subluxation or fracture are very possible. In addition, progressive vascular fibrosis and deficient wound healing make any necessary surgical procedure difficult and hazardous (6).

This article set out to report two cases of systemic sclerosis in patients with oral and facial manifestations of the disease. A brief review of the literature is presented, focusing on deontological alterations.

Case Report

Case # 1

A 34-year-old caucasian woman was referred to the Dentistry School with a chief complaint of tooth pain and facial deformity. Her past medical history revealed that she had been first diagnosed with Lupus, and afterwards with PPS. The latter was about 10 years ago. Her medical treatment included colchicine and nifedipine prescription. Extra-oral examination showed taut, thickened and rigid skin, there was a morphologic modification of the angle and body of the jaw (Figures 1A and 1B), a marked decrease in width of oral orifice, and thinned lips (Figures 1C). Intra-oral examination showed no alteration of in the mucosa, but tongue rigidity and decay of the maxillary right second molar. There was ulceration and loss of the fingertips and toe tips associated with Raynaud's phenomenon (Figure 1D). Panoramic radiograph showed bilateral mandibular angle resorption and complete coronoid process osteolysis (Figure 1E). Endodontic treatment was not provided due to the oral aperture limitation and, to relief pain, tooth removal was the treatment elected. Patient was taught oral hygiene procedures and after a two-year clinical follow-up is free of complaints.

Case #2

A 30-year-old caucasian woman, diagnosed with PSS thirteen years ago was referred to Maxillofacial Surgery Service complaining of tooth pain. Her medical treatment included ciclofosfamide, diotiagen and omeprazol prescription. She had also been prescribed physiotherapy. Clinically, the patient presented with tightening of the facial skin, limitation of oral orifice (Figures 2A and 2B), tongue rigidity, thinning lips, and destruction of fingertips associated with Raynaud's phenomenon (Figure 2C).

Radiographs revealed severe loss of coronoid process and incipient loss of mandibular angle (Figure 2D). Periapical radiographs showed enlargement of periodontal space mainly on molars (Figure 2F). An extensive decay process could be observed in the mandibular right third molar. Surgical removal of the tooth was arranged since endodontic treatment was not possible due to limited oral opening. Patient died after one-year follow-up on account of systemic complications.

Discussion

Scleroderma or PSS, a rare condition, (2,6,7) was first characterized as a single condition in 1752 by Curzio of Naples (8). It generally affects woman between 30 and 50 years of age, with and has a low prevalence (130 per million) (9).

There are two clinical entities of scleroderma: localized scleroderma and PSS. Systemic sclerosis differs from localized scleroderma because it is accompanied by Raynaud's phenomenon, acrosclerosis, and internal organ involvement.

PSS often affects oral and perioral tissues, but the most common clinical manifestations is are facial and tongue rigidity, and thinning lips (2, 3, 7, 8). The two cases presented here had been diagnosed with PSS at least 10 years before.

Both patients, females, aged 30 and 34 years respectively, exhibited all the facial and oral characteristics of PSS mentioned, but for the first patient, severe resorption of the mandibular angle appears to have led to facial modification which was part of her complaint. Osteolysis occurs mainly in areas of bone prominences covered by thin skin and subcutaneous tissue and can be attributed to the local pressure of the ischemic overlying tissues (2, 3). The condyle and the coronoid process, and posterior border of the ascending ramus are frequently involved (2, 3, 10); and in some cases, so there may be mandibular resorption and painful trigeminal neuropathy caused by nerve compression (11).

The interincisal distance is significantly decreased in most patients with PSS (7). Limitation of mouth opening and reduced movement of the cheeks and tongue usually leads to deterioration in dental health. Yet, oral and facial manifestations associated with sclerodactyly may result in an even more rapid decline. Therefore, regular oral examination should be recommended (6). Maintenance of existing dentition is important because microstomia can make the prosthetic replacement difficult.

Nagy et al. (7) found that 69% (n=22) of patients had salivary hypofunction, keratoconjunctivitis sicca or both. Differently from Nagy et al, patients here mentioned presented with none of these alterations.

Oral exercises and stretching of the facial skin and oral musculature may help to maintain oral opening, oral health and mastication (8). Surgical procedures to enlarge

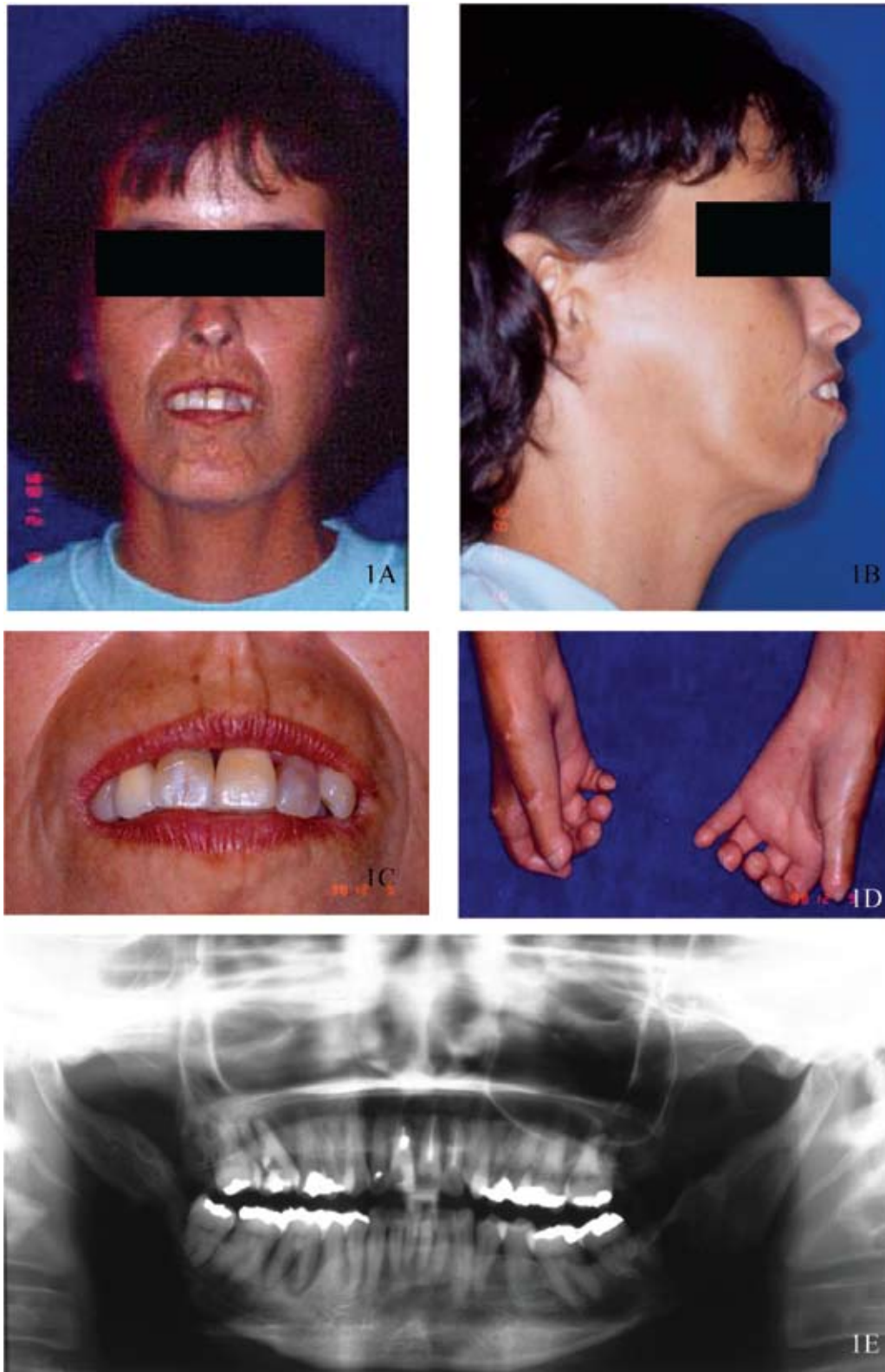

Fig. 1. A. First patient's masklike face. B. Morphological change of the angle and body of the jaw. C. Thinning aspects of lips. D. Note that fingers are fixed in a clawlike position. E. Panoramic radiographic evaluation may show a characteristic bilateral resorption of the angle and coronoid process.

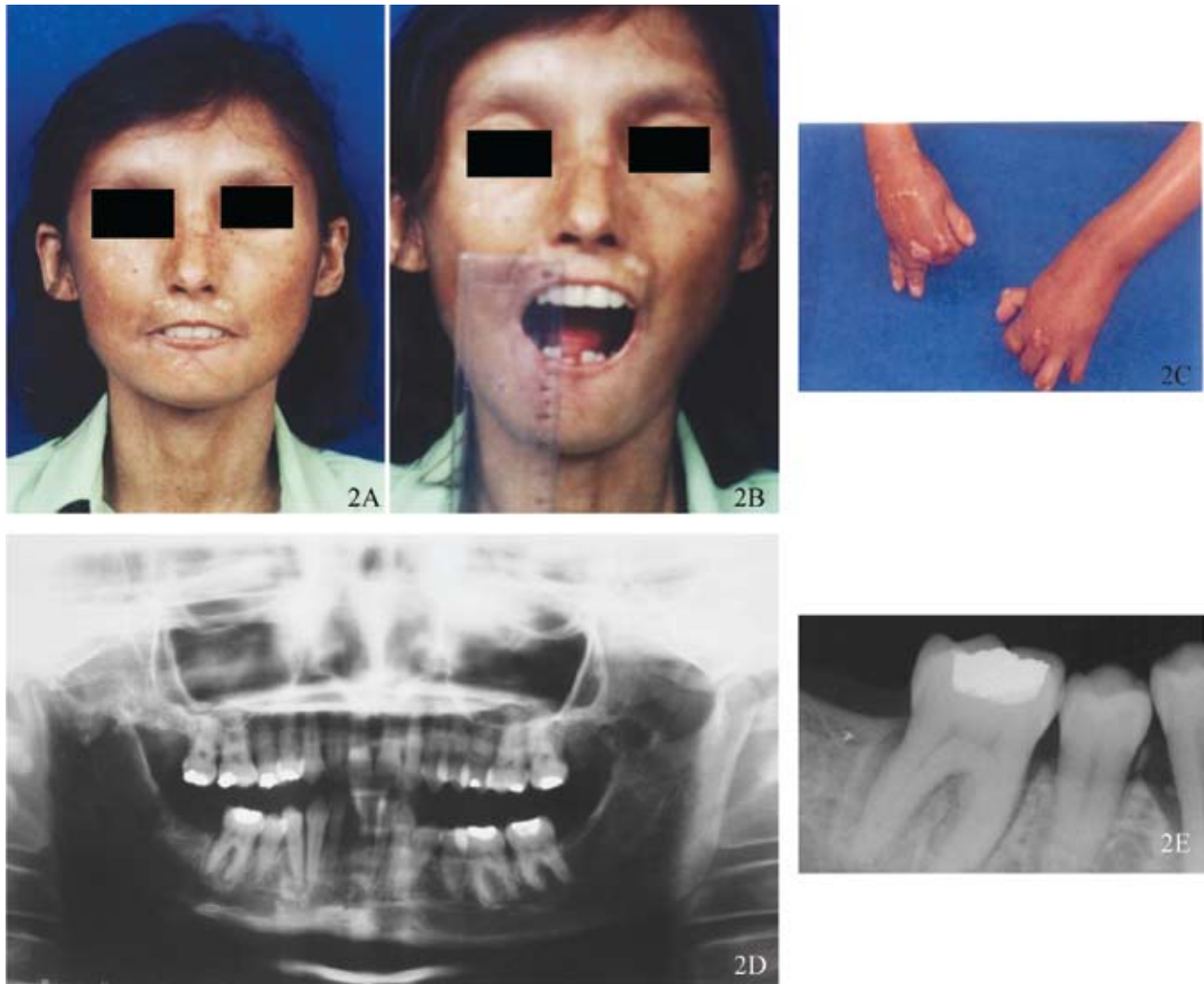


Fig. 2. A. Involvement of the facial skin in the second patient. B. Limitation of mouth opening. C. Evidence of the tense, shiny appearance of the skin. D. Radiographs show loss of coronoid process and mandibular angle. E. Enlargement of periodontal space on molar.

the oral orifice have been described (11). Other recommended aids are eating a balanced diet and using electric toothbrush and anti-bacterial mouthwashes (8).

A radiographic study of PSS patients reveals a great incidence of periodontal ligament space enlargement. Maxilla and mandible are equally involved, and posterior teeth are more frequently involved than anterior teeth (6). However, this feature was observed only in the second patient who exhibited localized areas with wide periodontal ligament space. There is no satisfactory explanation for such widening, which is not very often associated with periodontal disease (4).

In PSS, all oral tissues are affected, causing limited oral function such as decrease in the maximal oral aperture, impaired healing, wide periodontal ligament spaces and neurological symptoms, which may be present to varying

degrees. General dentists should monitor PSS patients periodically, performing clinical and radiological examinations, so as to follow the course of the disease and prevent poor oral hygiene, loss of teeth, and periodontitis.

References

1. Takehara K, Sato S. Localized scleroderma is an autoimmune disorder. *Rheumatology (Oxford)*. 2005 Mar;44(3):274-9.
2. Caplan HI, Benny RA. Total osteolysis of the mandibular condyle in progressive systemic sclerosis. *Oral Surg Oral Med Oral Pathol*. 1978 Sep;46(3):362-6.
3. Wardrop RW, Heggie AA. Progressive systemic sclerosis--oro-facial manifestations. Case report. *Aust Dent J*. 1987 Aug;32(4):258-62.
4. Marmary Y, Glaiss R, Pisanty S. Scleroderma: oral manifestations. *Oral Surg Oral Med Oral Pathol*. 1981 Jul;52(1):32-7.
5. Zhou X, Tan FK, Xiong M, Milewicz DM, Feghali CA, Fritzler MJ, et al. Systemic sclerosis (scleroderma): specific autoantigen genes are selectively overexpressed in scleroderma fibroblasts. *J Immunol*. 2001 Dec 15;167(12):7126-33.

6. Cankaya H, Kabasakal Y. Mandibular resorption due to progressive systemic sclerosis: a case report. *J Oral Maxillofac Surg.* 2001 May;59(5):565-7.
7. Nagy G, Kovács J, Zeher M, Czirják L. Analysis of the oral manifestations of systemic sclerosis. *Oral Surg Oral Med Oral Pathol.* 1994 Feb;77(2):141-6.
8. Naylor WP. Oral management of the scleroderma patient. *J Am Dent Assoc.* 1982 Nov;105(5):814-7.
9. White SC, Frey NW, Blaschke DD, Ross MD, Clements PJ, Furst DE, et al. Oral radiographic changes in patients with progressive systemic sclerosis (scleroderma). *J Am Dent Assoc.* 1977 Jun;94(6):1178-82.
10. Fischhoff DK, Sirois D. Painful trigeminal neuropathy caused by severe mandibular resorption and nerve compression in a patient with systemic sclerosis: case report and literature review. *Oral Surg Oral Med Oral Pathol Oral Radiol Endod.* 2000 Oct;90(4):456-9.
11. Johns FR, Sandler NA, Ochs MW. The use of a triangular pedicle flap for oral commisuroplasty: report of a case. *J Oral Maxillofac Surg.* 1998 Feb;56(2):228-31.