

# Epstein-Barr virus in oral proliferative verrucous leukoplakia and squamous cell carcinoma: A preliminary study

Jose V. Bagan<sup>1</sup>, Yolanda Jiménez<sup>1</sup>, Judith Murillo<sup>1</sup>, Rafael Poveda<sup>1</sup>, José M. Diaz<sup>1</sup>, Carmen Gavaldá<sup>1</sup>, María Margaix<sup>1</sup>, Crispian Scully<sup>2</sup>, Trinidad M. Alberola<sup>3</sup>, Manuela Torres Puente<sup>3</sup>, Manuel Pérez Alonso<sup>3,4</sup>

(1) Oral Medicine, Valencia University, Department of Stomatology, University General Hospital, Valencia, Spain

(2) International Centres for Excellence in Dentistry, and Eastman Dental Institute for Oral Health Care Sciences University College London, London, UK

(3) Sistemas Genómicos SL, Unidad de Oncología Molecular, División Biomédica, Paterna, Spain

(4) Department of Genetics, University of Valencia, 46100 Burjasot, Spain

## Correspondence:

Prof Jose V. Bagan

Hospital General Universitario

Servicio de Estomatología

Avdal Tres Cruces s/n

46014 – Valencia, Spain

E-mail: [bagan@uv.es](mailto:bagan@uv.es)

Received: 6/10/2007

Accepted: 8/12/2007

## Indexed in:

-Index Medicus / MEDLINE / PubMed  
-EMBASE, Excerpta Medica  
-SCOPUS  
-Índice Médico Español  
-IBECs

Bagan JV, Jiménez Y, Murillo J, Poveda R, Diaz JM, Gavaldá C, Margaix M, Scully C, Alberola TM, Torres-Puente M, Pérez-Alonso M. Epstein-Barr virus in oral proliferative verrucous leukoplakia and squamous cell carcinoma: A preliminary study. *Med Oral Patol Oral Cir Bucal*. 2008 Feb;13(2):E110-3.

© Medicina Oral S. L. C.I.F. B 96689336 - ISSN 1698-6946

URL: <http://www.medicinaoral.com/medoralfree01/v13i2/medoralv13i2p110.pdf>

## Summary

The aim of this study was to analyze proliferative verrucous leukoplakia (PVL) and oral squamous cell carcinoma (OSCC) for the possible presence of Epstein-Barr virus (EBV).

We studied three groups: Sub-Group 1 was composed of 10 patients with PVL, (6 of whom had developed OSCC); Sub-Group 2 comprised 5 patients with OSCC but no preceding PVL; and Sub-Group 3 were 5 controls with clinically normal oral mucosa. Oral biopsies from all cases were examined for Epstein-Barr virus (EBV) by nested PCR.

EBV was detected in 60% of Sub-Group 1 patients (PVL) and in 40% of Sub-Group 2 (OSCC), but in 0% of Sub-Group 3 (controls).

**Key words:** Proliferative verrucous leukoplakia, carcinoma, Epstein-Barr virus.

## Introduction

Proliferative verrucous leukoplakia (PVL), first described by Hansen, (1985), (1) has a high risk of malignant transformation to carcinoma – especially to oral squamous cell carcinoma (OSCC) (2-5). The aetiology of PVL is unclear but the aetiology of OSCC may involve tobacco, alcohol, and viruses including human papillomavirus (HPV) (6).

An association has also been reported between HPV and PVL (7-11), particularly HPV16 and HPV18, but HPV were found in only a small number of cases, and other authors have been unable to find any such association (12-14). For example, Campisi et al. (13) using nested polymerase chain reaction (PCR) – a sensitive technique- studied 58 cases of PVL compared with 90 cases of other oral leukoplakias and concluded that PVL is not more likely to be associated with HPV infection than is

conventional leukoplakia. Using PCR we also could not find an association (14).

Epstein-Barr virus (EBV) has been implicated in a range of malignant neoplasms, including in some studies, in the aetiology of OSCC (15-18) though not in all (19) but we have not found any study which examined the possible role of EBV in PVL.

The aim of this preliminary study was to analyze the possible implication of EBV in a series of patients with proliferative verrucous leukoplakia (PVL).

## Material and Methods

The study group consisted of 20 adult subjects, with local ethical committee authorisation, examining oral biopsies by nested polymerase chain reaction (PCR). The clinical data of the patients are summarized in Table 1. The study

**Table 1.** Clinical, histological and nested PCR results for EBV in Sub-Groups 1 (PVL); 2 (OSCC) and 3 (controls).

Case	Sub-Group	Age	Gender	Oral locations of the lesions	Histology	EBV
1	1	75	Female	Gingiva, Palate	OSCC	+
2	1	74	Female	Gingiva, Palate, Tongue, Buccal mucosa	OSCC	+
3	1	90	Female	Gingiva, Palate, Tongue, Buccal mucosa	OSCC	+
4	1	84	Female	Gingiva, Tongue, Buccal mucosa	Verrucous carcinoma	+
5	1	81	Female	Gingiva, Tongue, Buccal mucosa	Hyperkeratosis Dysplasia	+
6	1	68	Female	Gingiva, Tongue	Hyperkeratosis Dysplasia	+
7	1	57	Female	Gingiva, Buccal mucosa	OSCC	-
8	1	79	Female	Gingiva, Tongue	OSCC	-
9	1	78	Female	Gingiva, Tongue	Hyperkeratosis Dysplasia	-
10	1	53	Female	Gingiva, Tongue, Palate, Buccal mucosa	Hyperkeratosis Dysplasia	-
11	2	66	Male	Sof palate	OSCC	+
12	2	69	Male	Buccal mucosa	OSCC	+
13	2	65	Female	Gingiva	OSCC	-
14	2	69	Male	Tongue	OSCC	-
15	2	37	Male	Gingiva	OSCC	-
16	3	35	Male	-	No lesions	-
17	3	21	Female	-	No lesions	-
18	3	48	Female	-	No lesions	-
19	3	45	Male	-	No lesions	-
20	3	18	Male	-	No lesions	-

Sub-Group 1: PVL

Sub-Group 2: OSCC without a background of PVL

Sub-Group 3: Control – no lesions

EBV: PCR results positive for Epstein-Barr Virus.

**Table 2.** Primer sequences employed for qualitative detection of Epstein-Barr Virus [EBV] DNA.

Primer	Sequence [5'-3']
EBV outerF	GAGACCGAAGTGAAGGCCCT
EBV outerR	GGTGCCTTCTTAGGAGCTGT
EBV innerF	GCCAGAGGTAAGTGGACTTTAAT
EBV innerR	GAGGGGACCCTGAGACGGGT

group comprised 3 sub-groups; in all three sub-groups we took a biopsy under local anaesthesia and divided it in two fragments, one for conventional histopathological analysis and the rest for the biomolecular study after freezing the sample at  $-80^{\circ}\text{C}$ .

Sub-Group 1 were 10 patients with PVL diagnosed according to the criteria of Hansen et al. (1), 6 of whom had developed oral squamous cell carcinoma (OSCC) and the remaining 4 had some degree of hyperkeratosis with dysplasia but did not show histological signs of OSCC. The main age of Sub-Group 1 was 71.9 years, and all were females. Lesional biopsy was used.

Sub-Group 2 comprised 5 patients with OSCC but without any background of PVL. Lesional biopsy was used.

Sub-Group 3 came from a randomly selected healthy control group - 5 patients who came for third molar removal. We took an incisional biopsy of the oral mucosa in a clinically normal area from the third molar flap site.

All cases were examined by nested PCR for biomarkers of EBV, in the following way:

#### DNA Extraction

DNA from frozen tissue was extracted using the High Pure PCR Template Preparation Extraction Kit (Roche), following the instructions of the manufacturer: the tissue was incubated at  $55^{\circ}\text{C}$  with a Roche lysis buffer and  $40\ \mu\text{l}$  of Roche proteinase K. DNA was eluted in  $200\ \mu\text{l}$  of  $\text{H}_2\text{O}$ .

DNA from oral rinse samples was extracted, after transferring the sample into a 15ml sterile tube and centrifuging for 2 minutes at 4000 rpm in order to obtain a cellular precipitate.

The precipitate was resuspended in  $200\ \mu\text{l}$  of PBS buffer. The extractions were carried out using the QIAamp DNA blood Midi Extraction Kit (QIAGEN), following the instructions of the manufacturer. The DNA was eluted in  $200\ \mu\text{l}$  of  $\text{H}_2\text{O}$ .

#### Qualitative Detection of Epstein Barr Virus (EBV) DNA by PCR

Detection of EBV was carried out by nested PCR. Primary PCR amplifications of the processed samples were performed in a reaction volume of  $25\ \mu\text{l}$ , containing  $2.5\ \mu\text{l}$  of 10X PCR buffer (100 mM Tris-HCl, 500 mM KCl),  $2.5\ \mu\text{l}$  of

$\text{MgCl}_2$  25 mM,  $0.5\ \mu\text{l}$  of 10mM dNTPs,  $0.5\ \mu\text{l}$  of each 20  $\mu\text{M}$  forward and reverse EBV outer primers (Table 2),  $0.5\ \text{U}$  of Taq DNA polymerase GOLD (Applied Biosystems) and  $5\ \mu\text{l}$  of the DNA extracted from the processed samples. Secondary PCR amplifications were carried out under the same buffer conditions described for primary PCR amplification in a reaction volume of  $50\ \mu\text{l}$  containing forward and reverse EBV inner primers instead of outer ones and  $1\ \mu\text{l}$  of the primary PCR. As a positive control for each PCR reaction, we used quantitated viral DNA from B95-8 strain of Epstein Barr Virus (Advanced Biotechnologies, Inc.). Our limit of detection was 10 copies of virus per amplification. As a negative control, we used the same components described previously but without DNA.

All PCR reactions were performed in a Biometra T3 or in a T1 thermocycler at the same conditions: an initial denaturing step of 2 min at  $94^{\circ}\text{C}$  followed by 35 cycles of 30 sec at  $94^{\circ}\text{C}$ , 30 sec at  $55^{\circ}\text{C}$  and 30 sec at  $72^{\circ}\text{C}$  and a final elongation step of 5 min at  $72^{\circ}\text{C}$ .

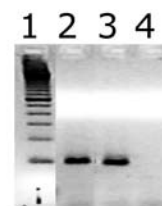
Presence of PCR-amplifiable DNA as well as absence of PCR inhibitors were tested by amplification of human  $\beta$ -globin gene as previously described (14).

The products of amplification were visualized by electrophoresis in 2% agarose gel, stained with ethidium bromide.

#### Results

The results of the study are shown in table 1. We have highlighted the fact that we detected EBV by nested PCR in 60% of Sub-Group 1 patients (PVL) but if we consider only those patients with OSCC in Sub-Group 1, the EBV positivity was slightly higher at 66,6%. (Fig. 1); in 40% of Sub-Group 2 (OSCC); and in 0% of Sub-Group 3 (controls).

**Fig. 1.** Electrophoretic analysis of PCR products.



Lane1: 100 pb DNA Ladder [GibcoBRL]; Lane 2: EBV detection PCR reaction from a positive sample; Lane 3: positive control for EBV amplification; Lane 4: negative PCR control reaction.

## Discussion

Proliferative verrucous leukoplakia (PVL) is a slow growing lesion which typically affects several areas (5), has a high tendency to recur after treatment, and has a high rate of malignant transformation and a recognized field cancerization (20,21) which makes it possible to study the implications of some viruses in this disease. In the present study we identified EBV in PVL and OSCC. However, although we detected EBV in PVL and in a higher percentage of patients with PVL when compared with the OSCC cases without PVL we have no evidence of any direct role of it in the aetiology as it might be a simple associated infection in the context of an epithelium with severe multiple alterations over a long period. We recognize that we are reporting only a small sample of cases to support any role of EBV in PVL or OSCC, but our positive results may encourage other investigations with a greater number of patients.

After initial infection, it is known that EBV persists in oral epithelial cells and often replicates in them (17). EBV is the proven aetiological agent of nasopharyngeal carcinoma and is also associated with oral hairy leukoplakia, lymphoproliferative disease, B-cell lymphomas and lymphoepithelial carcinoma (22). Several authors have previously studied the possible implication of EBV in OSCC, but with controversial results (15-19). In particular, Anwar et al. (23), Goldenberg et al. (24), Yang et al. (25) were unable to implicate EBV in OSCC. In contrast, Higa et al. (15) found a large number of EBV infections in their OSCC. EBV type B was detected in 36% of EBV-related OSCC in Japan but other authors such as Shimakage et al. (17) using mRNA in situ hybridization, immunofluorescence staining, reverse transcriptase-polymerase chain reaction (RT-PCR) and polymerase chain reaction (PCR) did not find EBV. This is a preliminary study about the possible presence of EBV within PVL, and the method used cannot distinguish EBV in epithelium from EBV in infiltrating B cells.

## References

- Hansen LS, Olson JA, Silverman S Jr. Proliferative verrucous leukoplakia. A long-term study of thirty patients. *Oral Surg Oral Med Oral Pathol.* 1985 Sep;60(3):285-98
- Silverman S Jr, Gorsky M. Proliferative verrucous leukoplakia: a follow-up study of 54 cases. *Oral Surg Oral Med Oral Pathol Oral Radiol Endod.* 1997 Aug;84(2):154-7.
- Zakrzewska JM, Lopes V, Speight P, Hopper C. Proliferative verrucous leukoplakia: a report of ten cases. *Oral Surg Oral Med Oral Pathol Oral Radiol Endod.* 1996 Oct;82(4):396-401
- Navarro CM, Sposto MR, Sgavioli-Massucato EM, Onofre MA. Transformation of proliferative verrucous leukoplakia to oral carcinoma: a ten years follow-up. *Med Oral.* 2004 May-Jul;9(3):229-33
- Bagan JV, Jimenez Y, Sanchis JM, Poveda R, Milian MA, Murillo J, et al. Proliferative verrucous leukoplakia; high incidence of gingival squamous cell carcinoma. *Journal of Oral Pathology and Medicine.* 2003 Aug;32(7):379-82.
- Gillison ML. Current topics in the epidemiology of oral cavity and oropharyngeal cancers. *Head Neck.* 2007 Aug;29(8):779-92
- Eversole LR. Papillary lesions of the oral cavity: relationship to human

- papillomaviruses. *J Calif Dent Assoc.* 2000 Dec;28(12):922-7.
- Ostwald C, Rutsatz K, Schweder J, Schmidt W, Gundlach K, Barten M. Human papillomavirus 6/11, 16 and 18 in oral carcinomas and benign oral lesions. *Med Microbiol Immunol (Berl).* 2003 Aug;192(3):145-8.
- Palefsky JM, Silverman S Jr, Abdel-Salaam M, Daniels TE, Greenspan JS. Association between proliferative verrucous leukoplakia and infection with human papillomavirus type 16. *J Oral Pathol Med.* 1995 May;24(5):193-7.
- Summersgill KF, Smith EM, Levy BT, Allen JM, Haugen TH, Turek LP. Human papillomavirus in the oral cavities of children and adolescents. *Oral Surg Oral Med Oral Pathol Oral Radiol Endod.* 2001 Jan;91(1):62-9
- Gopalakrishnan R, Weghorst CM, Lehman TA, Calvert RJ, Bijur G, Sabourin CL, et al. Mutated and wild-type p53 expression and HPV integration in proliferative verrucous leukoplakia and oral squamous cell carcinoma. *Oral Surg Oral Med Oral Pathol Oral Radiol Endod.* 1997 Apr;83(4):471-7.
- Fettig A, Pogrel Ma, Silverman S Jr, Bramanti TE, Da Costa M, Regezi JA. Proliferative verrucous leukoplakia of the gingiva. *Oral Surg Oral Med Oral Pathol Oral Radiol Endod.* 2000 Dec;90(6):723-30.
- Campisi G, Giovannelli L, Ammatuna P, Capra G, Colella G, Di Liberto C, et al. Proliferative verrucous vs conventional leukoplakia: no significantly increased risk of HPV infection. *Oral Oncol.* 2004 Sep;40(8):835-40.
- Bagan JV, Jimenez Y, Murillo J, Gavaldá C, Poveda R, Scully C, et al. Lack of association between proliferative verrucous leukoplakia and human papillomavirus infection. *J Oral Maxillofac Surg.* 2007 Jan;65(1):46-9.
- Higa M, Kinjo T, Kamiyama K, Chinen K, Iwamasa T, Arasaki A, Sunakawa H. Epstein-Barr virus (EBV)-related oral squamous cell carcinoma in Okinawa, a subtropical island, in southern Japan--simultaneously infected with human papillomavirus (HPV). *Oral Oncol.* 2003 Jun;39(4):405-14
- Szkaradkiewicz A, Kruk-Zagajewska A, Wal M, Jopek A, Wierzbicka M, Kuch A. Epstein-Barr virus and human papillomavirus infections and oropharyngeal squamous cell carcinomas. *Clin Exp Med.* 2002 Nov;2(3):137-41.
- Shimakage M, Horii K, Tempaku A, Kakudo K, Shirasaka T, Sasagawa T. Association of Epstein-Barr virus with oral cancers. *Hum Pathol. Hum Pathol.* 2002 Jun;33(6):608-14.
- Gonzalez-Moles MA, Gutierrez J, Rodriguez MJ, Ruiz-Avila I, Rodriguez-Archilla A. Epstein-Barr virus latent membrane protein-1 (LMP-1) expression in oral squamous cell carcinoma. *Laryngoscope.* 2002 Mar;112(3):482-7.
- Iamaroon A, Khemaleelakul U, Pongsirivet S, Pintong J. Co-expression of p53 and Ki67 and lack of EBV expression in oral squamous cell carcinoma. *J Oral Pathol Med.* 2004 Jan;33(1):30-6.
- Bagán JV, Murillo J, Poveda R, Gavaldá C, Jiménez Y, Scully C. Proliferative verrucous leukoplakia: unusual locations of oral squamous cell carcinomas, and field cancerization as shown by the appearance of multiple OSCCs. *Oral Oncol.* 2004 Apr;40(4):440-3.
- Feller L, Wood NH, Raubenheimer EJ. Proliferative verrucous leukoplakia and field cancerization: report of a case. *J Int Acad Periodontol.* 2006 Apr;8(2):67-70.
- Flaitz CM, Hicks MJ. Molecular piracy: the viral link to carcinogenesis. *Oral Oncol.* 1998 Nov;34(6):448-53.
- Anwar M, Koriyama C, Naveed IA, Hamid S, Ahmad M, Itoh T, et al. Epstein-barr virus detection in tumors of upper gastrointestinal tract. An in situ hybridization study in Pakistan. *J Exp Clin Cancer Res.* 2005 Sep;24(3):379-85.
- Goldenberg D, Benoit NE, Begum S, Westra WH, Cohen Y, Koch WM, Sidransky D, Califano JA. Epstein-Barr virus in head and neck cancer assessed by quantitative polymerase chain reaction. *Laryngoscope.* 2004 Jun;114(6):1027-31.
- Yang YY, Koh LW, Tsai JH, Tsai CH, Wong EF, Lin SJ, Yang CC. Involvement of viral and chemical factors with oral cancer in Taiwan. *Jpn J Clin Oncol.* 2004 Apr;34(4):176-83.