

The meridian incision: A technical modification in the conservative surgery of the impacted maxillary canine

José V. Pascual Gil ¹, Mariano Marqués Mateo ², Miguel Puche Torres ², Luis Miragall Alba ², Maria Eugenia Iglesias Gimilio ², Raquel Villar Puchades ³

(1) Chief. Professor of Maxillofacial Surgery. Department of Surgery. School of Medicine. University of Valencia

(2) Maxillofacial Surgeon

(3) Resident in Maxillofacial Surgery. Department of Maxillofacial Surgery. Hospital Clínico Universitario of Valencia. Valencia, Spain

Correspondence:

Dr. J. V. Pascual Gil

Calle Alemania, 6, 4^a

46010 Valencia, Spain

E-mail: jose.v.pascual@uv.es

Received: 20-04-2007

Accepted: 7-09-2007

Indexed in:

-Index Medicus / MEDLINE / PubMed
-EMBASE, Excerpta Medica
-SCOPUS
-Indice Médico Español
-IBECs

Pascual-Gil, JV, Marqués-Mateo M, Puche-Torres M, Miragall-Alba L, Iglesias-Gimilio ME, Villar-Puchades R. The meridian incision: A technical modification in the conservative surgery of the impacted maxillary canine. *Med Oral Patol Oral Cir Bucal*. 2008 Jan 1;13(1):E36-8.

© Medicina Oral S. L. C.I.F. B 96689336 - ISSN 1698-6946

<http://www.medicinaoral.com/medoralfree01/v13i1/medoralv13i1p38.pdf>

Abstract

We describe a technical modification of the apical repositioning flap in the conservative surgical treatment of the impacted canine in buccal position. This amendment improves the tooth's eventual visualization, thus permitting a better evolutive follow-up of its eruption process and, most importantly, providing the tooth with buccal attached gingiva that will accompany it in its downward progression, procuring a cervical contour without retraction, a satisfactory esthetic outcome and a physiologically correct periodontal ridge.

The traditional apical repositioning flap also bestows the canine with attached gingiva; however, since the flap is sutured apically and its width is significantly smaller than the remaining surgical defect, the wound's closure is compromised at one of its edges and often requires healing by second intention at an undesired location next to the buccal sulcus.

We believe the introduction of the meridian incision is a simple, expedient technical modification with efficient results.

Key words: *Impacted canine, surgical exposure, guided eruption, apical repositioning.*

Introduction

The maxillary canine is second only to the third molar in its frequency of impaction. Genetic factors have been pointed out as the primary origin of most impactions of maxillary canine teeth (1); other aetiologic agents, though individually unnecessary, may coexist.

It has been estimated that 1 to 3% of the population has an impacted maxillary canine. Females are more frequently involved than males (2).

Many surgical procedures have been attempted in past years. Initially, the customary treatment option was surgical removal. However, the canine's essential anatomical, functional and esthetic roles soon encouraged the development of alternative conservative approaches.

Transplantation trials began later, intending to transfer the tooth from its place of impaction to its correct position

in the dental arch (3). However, disappointing half-term results are obtained in a high percentage of cases due to root resorption. Thus, the indications for this technique, unless at very early stages, are very limited.

Currently, stimulating dental eruption by means of surgical exposure and subsequent orthodontic assistance is the most prevailing treatment option for impacted maxillary canines. It is referred to as "guided eruption" or, more commonly, "surgical exposure".

Impacted canine teeth can be located palatally or buccally with respect to the dental arch. They may also be situated in the midalveolar area. It is important to point out that each particular location entails different conditions of surgical accessibility and expected periodontal results, hence requiring a specific management strategy.

In the case of palatal displacement, canine emergence will

certainly meet with attached gingiva at its cementoenamel junction, since it is completely surrounded by masticatory mucosa (4). No consequences will thus arise from surgical access through full-thickness flap reflection after crevicular incision or excision of overlying pericoronal gingiva. On the other hand, when the canine is in buccal position (or vertically in the arch itself), the scarce availability of attached gingiva calls for closed techniques (replacing the flap to its original position) or apical repositioning flap procedures (4-8).

Currently, the preferred approach is the apical repositioning technique, which may incorporate various lateral translation adjustments. Nevertheless, we have observed this procedure is linked to certain inherent difficulties and disadvantages we will purposely consider in the discussion section.

Intending to improve the periodontal status of the involved canine, we have introduced certain modifications to the classical apical repositioning flap procedure and we have clinically corroborated the benefits.

Objective, Method and Discussion

We describe a technical modification of the traditional apical repositioning flap procedure with the aim to obtain an efficient attached gingiva that will “await” the canine’s eruption and adhere to its buccal neck.

Traditional apical repositioning becomes problematical when, as it is often necessary, discharge incisions are made divergently towards the buccal sulcus. In these cases, the resultant flap is inconveniently short when sutured to its new location; while it is appropriately drawn to its correct position at one side, wound edges become too separated from each other at the opposite side, where primary closure is thus disrupted. Intending to avoid (or rather assume) this plight, some authors recommend lateral translation combined with apical repositioning (9).

The alternative method we propose is based in the following guidelines:

Before performing the incisions that will delimit the flap, the limit between attached and free gingiva (mucogingival junction) is identified (Figure 1.1).

Vertically in the edentulous space, at the mucogingival junction, preliminary markings are easily tattooed with an anesthesia needle and Chinese ink (Figure 1.2).

Next, the necessary incisions to obtain a classical flap are carried out. Discharge incisions may be divergent in the apical direction; in fact, this is even convenient, for they will produce a greater surgical field that will aid canine crown exposure. These incisions must be designed respecting the mesial gingiva of the lateral incisor and the distal gingiva of the first premolar (Figure 1).

At this point, it is important to emphasize that both incisions should be directed towards the palatal aspect of the maxilla as much as possible in order to obtain the maximal fibromucose surface (Figure 1, A). However, this will not be feasible if the deciduous canine must be

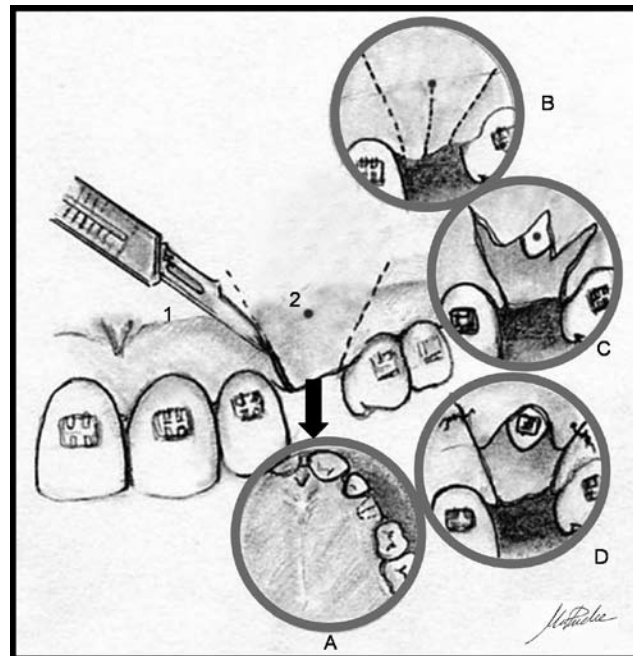


Fig. 1.
1: Mucogingival junction. 2: Ink mark.
A: Palatal prolongation of the incision. B: Meridian incision. C and D: Flaps and suture.

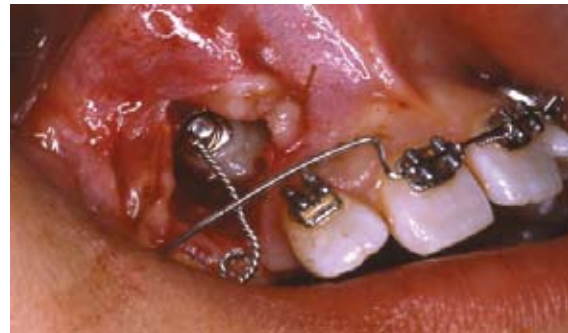

Fig. 2. Flap sutured to place after meridian incision.

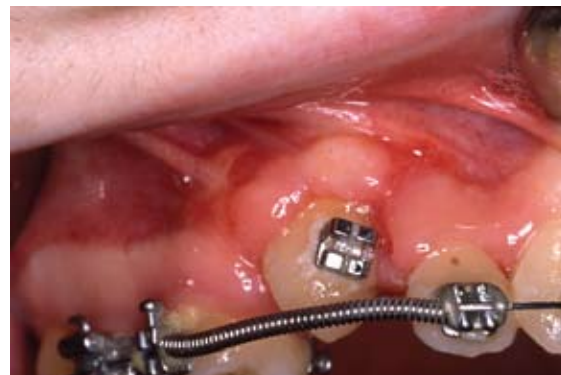

Fig. 3. Erupted canine with attached gingiva at its cervical area.

removed during the same appointment. Consequently, it is highly recommendable to anticipate this situation and remove the deciduous canine approximately two months before, giving the wound enough time to become covered by new gingiva.

Once all the incisions are made, the flap is raised. A window of the overlying bone is removed and the tooth is exposed up to its crown equator. A bracket may be bonded at this time.

Closure is what differentiates this procedure from the traditional apical repositioning technique: After revising the flap, the ink mark at the mucogingival junction is identified. A full-thickness incision is then made, extending from 1 mm below the referred marking to the flap's occlusal margin, dividing the flap into two halves; this is what we call "meridian incision", since it is halfway between both discharge incisions, equidistant and vertical (Figure 1, B). Hence, two vertexes (more or less acute) are obtained (Figure 1, C). Each of these is then sutured apically to the edge of its homolateral discharge incision; the two divergent flaps must be drawn away from each other as much as possible (Figure 1, D).

Figure 2 summarizes this procedure's clinical results.

Consequently, this technique will ensure that all cells of the gingival epithelium contacting the cemento-enamel junction of the descending canine will be genetically determined to adhere to the cervical dentine (since they come from attached gingiva). The lateral areas (close to the former vertexes of the flap) will descend with the canine and merge with the attached gingiva of the adjacent teeth (Figure 3).

Conclusions

The meridian incision is an efficient, technically simple modification of the apical repositioning flap. Its application requires identification of the mucogingival junction, tattooing preliminary markings at the convenient place, full-thickness meridian incision of the flap and suturing of the flap vertexes in an apicolateral direction. We believe the introduction of this technique is significantly advantageous and avoids possible inconveniences derived from the traditional apical repositioning procedure, especially when the canine is impacted very apically.

References

1. Peck S, Peck L, Kataja M. The palatally displaced canine as a dental anomaly of genetic origin. *Angle Orthod*. 1994;64(4):249-56.
2. Thilander B, Jakobsson SO. Local factors in impaction of maxillary canines. *Acta Odontol Scand*. 1968 May;26(2):145-68.
3. Andreassen J, Petersen J, Laskin D. Text book and color atlas of tooth impactions. Diagnosis, treatment and prevention. Copenhagen: Munksgaard; 1997. p. 147-50.
4. Arcas A. Opciones quirúrgicas en la fenestración de dientes incluidos. *Rev Esp Ortod*. 2001; 31: 99-105.
5. Vanarsdall RL, Corn H. Soft-tissue management of labially positioned unerupted teeth. *Am J Orthod*. 1977 Jul;72(1):53-64.
6. Macias-Escalada E, Cobo J, Carlos F, Pardo B. Abordaje ortodóncico quirúrgico de las inclusiones dentarias. *RCOE*. 2005;10:69-82.

7. Zamalloa I. Caninos incluidos. Implicaciones clínicas: análisis de 50 casos. *Ortodon Esp*. 2004;44:116-26.

8. Kokich VG. Surgical and orthodontic management of impacted maxillary canines. *Am J Orthod Dentofacial Orthop*. 2004 Sep;126(3):278-83.

9. Korbendau JM, Guyomard F. Periodontal surgery to position canine teeth in vestibular dystrophy. *Rev Orthop Dento Faciale*. 1980 Oct;14(4):459-77.