

Solitary angiokeratoma of the tongue

Netta Sion-Vardy ¹, Esther Manor ², Max Puterman ³, Lipa Bodner ⁴

(1) Department of Pathology

(2) Genetic Institute

(3) Department of Otolaryngology Head and Neck Surgery

(4) Department of Oral and Maxillofacial Surgery, Soroka University Medical Center and Ben Gurion University of the Negev, Beer-Sheva. Israel

Correspondence:

Prof. Lipa Bodner,

Department of OMF Surgery,

Soroka University Medical Center,

P.O. Box 151,

Beer-Sheva 84101, Israel.

E-mail: lbodner@bgu.ac.il

Received: 20-04-2007

Accepted: 16-09-2007

Sion-Vardy N, Manor E, Puterman M, Bodner L. Solitary angiokeratoma of the tongue. *Med Oral Patol Oral Cir Bucal*. 2008 Jan1;13(1):E12-4.

© Medicina Oral S. L. C.I.F. B 96689336 - ISSN 1698-6946

<http://www.medicinaoral.com/medoralfree01/v13i1/medoralv13i1p12.pdf>

Indexed in:

-Index Medicus / MEDLINE / PubMed
-EMBASE, Excerpta Medica
-SCOPUS
-Indice Médico Español
-IBECS

Abstract

Angiokeratoma is a rare cutaneous lesion. It can be either a generalized systemic form, presenting as multiple asymptomatic papules on the skin, associated with metabolic diseases or a solitary cutaneous form. Oral cavity involvement is more common in the systemic form, as a part of a more generalized cutaneous disease, but very rare in the localized form of angiokeratoma.

A 45-year-old female presented with a painless lesion on the tongue of one months duration, which bled occasionally. On clinical examination, a lesion of approximately 5 mm in diameter was observed on the left surface of the tongue.

The lesion was purple in color with a granulomatous appearance. There were no other changes in the oral mucosa. On dermatologic examination, no angiokeratomas were found, anywhere on the skin. The lesion was excised under local anesthesia. The histologic diagnosis was angiokeratoma.

A case of a solitary angiokeratoma of the tongue is reported. We report here the third intra-oral case and the second case in the tongue with solitary angiokeratoma.

Key words: *Solitary angiokeratoma, oral cavity, tongue.*

Introduction

Angiokeratoma, is rare cutaneous vascular disorder of the dermis, associated with hyperkeratosis of the epidermis. It can be divided into localized and systemic form. The localized forms include: (a) solitary angiokeratoma of the legs (b) localized angiokeratoma of the scrotum and vulva (Fordyce type), (c) congenital form, angiokeratoma circumscriptum, usually unilaterally on the leg, foot thigh or buttock (d) bilateral angiokeratoma on the dorsa of fingers and toes (Mibelli type).

The generalized systemic form is usually associated with a metabolic disorder, the most common being Fabry's disease and fucosidosis (1-3).

All types share similar histologic features but differ clinically. The Fabry type is a metabolic disorder that results from an inherited deficiency of alpha-galactosidase (4). Similar cutaneous manifestations may be seen in fucosidosis a beta-mannosidase deficiency (5,6). The Mibelli and Fordyce types are defined by their clinical rather than histological features. In all these forms multiple angiokeratomas can be seen.

Histologically, angiokeratoma is characterized by hyperkeratosis, acanthosis and dilated vascular spaces with or without organizing thrombi in the papillary dermis. The vascular spaces are partly or completely enclosed by elongated rete ridges. In Fabry's disease and fucosidosis,

swollen and vacuolated endothelial cells are also identified in the vascular spaces.

Oral angiokeratoma is rare . It is usually seen in Fabry's disease and fucosidosis as a more generalized cutaneous disease. Solitary oral angiokeratoma is very rare and only two caes have been reported previously (7,8).

In this report we describe a solitary angiokeratoma of the tongue.

Case report

A 45-year-old female presented with a painless lesion, of one months duration involving the tongue, which bled occasionally. On clinical examination, a lesion of approximately 5 mm in diameter was observed on the left surface of the tongue.

The lesion was purple in color with a granulomatous appearance (Fig 1). There were no other changes in the oral mucosa. Under local anesthesia the lesion was excised and sent for histopathological examination. .

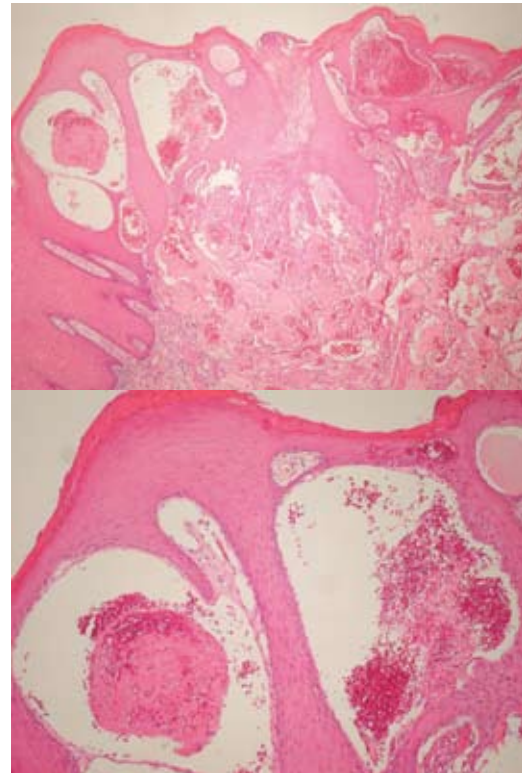
Histopathologic findings included squamous epithelium with acanthosis, parakeratosis and papillomatosis. Large dilated vascular spaces lined by normal appearing endothelium and filled with blood were present and surrounded by elongated rete ridges. Fibrin thrombi were present in some of the dilated vessels.

The lesion involved the subepithelial tissue (lamina propria) and reached the muscular tissue (Fig 2). The histologic diagnosis was angiokeratoma.

On dermatologic examination, no angiokeratomas were found anywhere on the skin.

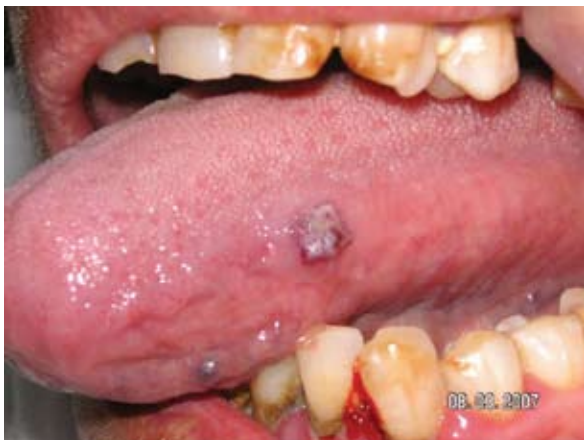

Fig 1. An erythematous papule over the left lateral surface of the tongue.



H&E x 40

H&E x 200

Fig. 2. Angiokeratoma showing parakeratosis and dilated blood vessels surrounded peripherally by epithelial collarettes. Fibrin thrombus is present in the lumen of one of the vessels (left) .

Discussion

Solitary angiokeratoma occurs predominantly on the lower extremities (9), but may also be found in other sites, such as penis, vulva and clitoris (1,10). Oral cavity angiokeratoma is rare. It is most commonly found as a component of the generalized systemic disorder in Fabry's disease or fucosidosis, where multiple angiokeratomas can be found on the skin and the oral mucosa. Oral angiokeratoma affecting the tongue can also be in the congenital form, angiokeratoma circumscriptum (11-13), in the Fordyce type, where angiokeratoma of the scrotum is associated with angiokeratoma of the tongue (14,15) or angiokeratomas occurring simultaneously in the jejunum, scrotum and oral cavity (16).

In the present case the lesion was solitary and there were no other lesions on the skin or in the oral cavity. The presence of a solitary angiokeratoma in the oral cavity in a patient without metabolic disease has been reported previously in two cases. One was in the buccal mucosa of an 82-year-old male (7) and the other was in the tongue of a 54-year-old female (8). Our case is the third reported case in the oral cavity and the second case in the tongue.

Oral angiokeratoma has histologic features similar to those arising on the skin. In both sites acanthosis and papillomatosis of the squamous epithelium can be seen

(17). However, while the cutaneous lesions show hyperorthokeratosis, the oral lesions show more hyperparakeratosis. Most of the vascular spaces were surrounded by elongated rete ridges with thrombi noted within the dilated vascular spaces. These features were also present in the oral lesions.

Angiokeratoma is a dark, irregular lesion which bleeds occasionally. Therefore it can be mistaken clinically for melanocytic nevus, malignant melanoma, verruca vulgaris, hemangioma, capillary aneurysm, Spitz nevus or focal epithelial hyperplasia (2, 18). The excisional biopsy with meticulous histologic examination is important to confirm the diagnosis, as demonstrated in our case.

The pathogenesis of angiokeratoma is still uncertain. It is thought that the primary event is vascular ectasia within the papillary dermis just beneath the basement membrane. The epidermal pathological changes seem to be a secondary reaction.

It has been speculated that the increased proliferative capacity on the surface of vascular malformations and the close proximity of the vascular spaces to the epidermis in angiokeratoma, could explain the reactive epidermal growth (2).

Treatment of oral angiokeratoma is surgical excision. It is required for histopathologic diagnosis and to cease episodes of bleeding or discomfort and to search for possible causative factors.

References

- Imperial R, Helwig EB. Angiokeratoma of the vulva. *Obstet Gynecol.* 1967 Mar;29(3):307-12.
- Schiller PI, Itin PH. Angiokeratomas: an update. *Dermatology.* 1996;193(4):275-82.
- Baccaglioni L, Schiffmann R, Brennan MT, Lancaster HE Jr, Kulkarni AB, Brahim JS. Oral and craniofacial findings in Fabry's disease: a report of 13 patients. *Oral Surg Oral Med Oral Pathol Oral Radiol Endod.* 2001 Oct;92(4):415-9.
- Möhrenschlager M, Braun-Falco M, Ring J, Abeck D. Fabry disease: recognition and management of cutaneous manifestations. *Am J Clin Dermatol.* 2003;4(3):189-96.
- Dvoretzky I, Fisher BK. Fucosidosis. *Int J Dermatol.* 1979 Apr;18(3):213-6.
- Rodríguez-Serna M, Botella-Estrada R, Chabás A, Coll MJ, Oliver V, Febrer MI, et al. Angiokeratoma corporis diffusum associated with beta-mannosidase deficiency. *Arch Dermatol.* 1996 Oct;132(10):1219-22.
- Leung CS, Jordan RC. Solitary angiokeratoma of the oral cavity. *Oral Surg Oral Med Oral Pathol Oral Radiol Endod.* 1997 Jul;84(1):51-3.
- Siponen M, Penna T, Apaja-Sarkkinen M, Palatsi R, Salo T. Solitary angiokeratoma of the tongue. *J Oral Pathol Med.* 2006 Apr;35(4):252-3.
- Gomi H, Eriyama Y, Horikawa E, Miura T. Solitary angiokeratoma. *J Dermatol.* 1988 Aug;15(4):349-50.
- McNeely TB. Angiokeratoma of the clitoris. *Arch Pathol Lab Med.* 1992 Aug;116(8):880-1.
- Kumar MV, Thappa DM, Shanmugam S, Ratnakar C. Angiokeratoma circumscriptum of the oral cavity. *Acta Derm Venereol.* 1998 Nov;78(6):472.
- Bhargava P, Bhargava S, Mathur D, Agarwal US, Bhargava R. Angiokeratoma of tongue. *Indian J Dermatol Venereol Leprol.* 2001 Sep-Oct;67(5):270.
- Vijaikumar M, Thappa DM, Karthikeyan K, Jayanthi S. Angiokeratoma circumscriptum of the tongue. *Pediatr Dermatol.* 2003 Mar-Apr;20(2):180-2.
- Karthikeyan K, Sethuraman G, Thappa DM. Angiokeratoma of the oral cavity and scrotum. *J Dermatol.* 2000 Feb;27(2):131-2.
- Jansen T, Bechara FG, Stücker M, Altmeyer P. Angiokeratoma of the scrotum (Fordyce type) associated with angiokeratoma of the oral cavity. *Acta Derm Venereol.* 2002;82(3):208-10.
- Rappaport I, Shiffman MA. Multiple phlebectasia involving jejunum, oral cavity, and scrotum. *JAMA.* 1963 Aug 10;185:437-40.
- Young WG, Sauk JJ Jr, Pihlstrom B, Fish AJ. Histopathology and electron and immunofluorescence microscopy of gingivitis granulomatosa associated with glossitis and cheilitis in a case of Anderson-Fabry disease. *Oral Surg Oral Med Oral Pathol.* 1978 Oct;46(4):540-54.
- Segura-Saint-Gerons R, Toro-Rojas M, Ceballos-Salobreña A, Aparicio-Soria JL, Fuentes-Vaamonde H. Focal epithelial hyperplasia. A rare disease in our area. *Med Oral Patol Oral Cir Bucal.* 2005 Mar-Apr;10(2):128-31.