



REVISTA DE
GASTROENTEROLOGÍA
DE MÉXICO

www.elsevier.es/rgmx



CLINICAL IMAGE IN GASTROENTEROLOGY

Endoscopic diagnosis of an intramural hematoma presenting as an anticoagulant ileus[☆]

Diagnóstico endoscópico de un hematoma intramural que se presentó como íleo por anticoagulantes

J. Fonseca^{a,*}, T. Meira^b, A. Nunes^b

^a Departamento de Gastroenterología, GENE-Grupo de Estudio de Nutrición Enteral, Hospital García de Orta, Almada, Portugal

^b Departamento de Gastroenterología, Hospital García de Orta, Almada, Portugal

A 73-year-old man with hypertension and atrial fibrillation under warfarin was admitted with abdominal pain, distension, and dark blood hematemesis. He presented with anemia (Hb-8.4g/dL), prolonged prothrombin time and partial thromboplastin time with an INR >15. An endoscopy was performed. No lesions were identified, reporting only blood in the duodenum. A 150 cm long pediatric colonoscope was introduced disclosing purple mucosa with ulcerations in the distal duodenum with spontaneous bleeding (Fig. 1a). As the endoscope passed into the jejunum, large and deeper ulcers were observed (Fig. 1b). Approximately 15 cm distal to the

Treitz angle (Fig. 1c), the bowel was extremely edematous presenting as circumferential ischemic necrosis. The ulcerations became deeper and about 25 cm distal to the Treitz angle (Fig. 1d), there was complete luminal obstruction. The CT-scan showed a thickened wall of the distal duodenum and proximal jejunum, with edema and intramural hemorrhage (Fig. 2), without arterial or venous obstruction. Spontaneous small bowel hematoma is a rare complication of anticoagulant therapy. To the best of our knowledge, this is the first case of an intramural hematoma causing anticoagulant ileus, whose primary diagnosis was made through endoscopy.

[☆] Please cite this article as: Fonseca J, Meira T, Nunes A. Diagnóstico endoscópico de un hematoma intramural que se presentó como íleo por anticoagulantes. Revista de Gastroenterología de México. 2013;78:249–250.

* Corresponding author at: Serviço de Gastreenterologia, Hospital Garcia de Orta, Avenida Torrado da Silva, 2801-951 Almada, Portugal. Phone: +351212726866.

E-mail address: jorgedafonseca@hotmail.com (J. Fonseca).

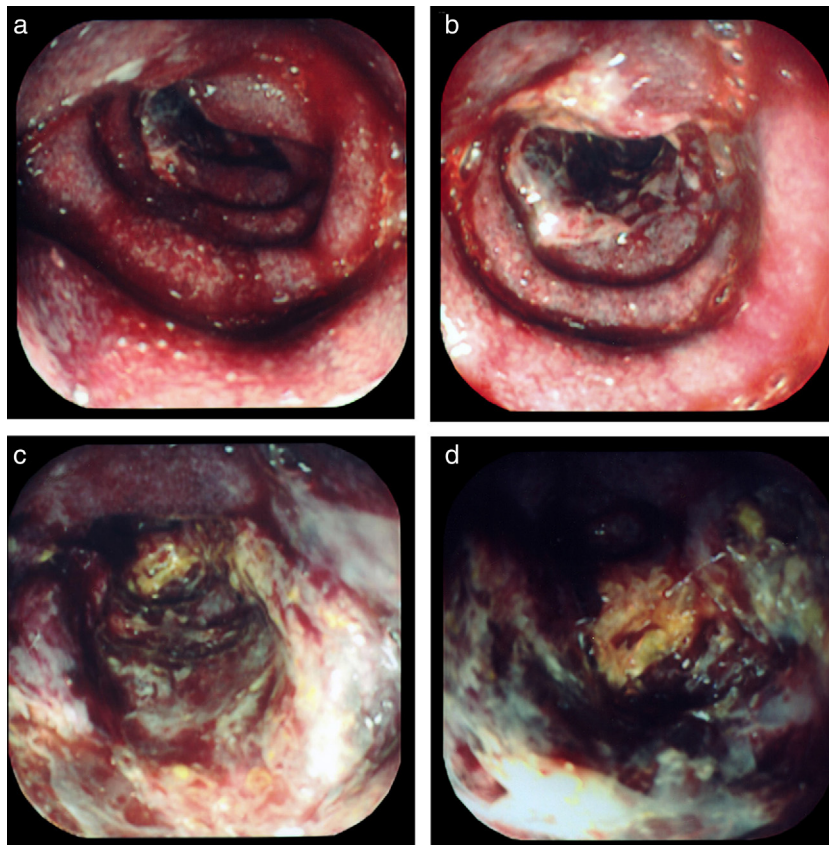


Figure 1 Endoscopic aspect of the intramural hematoma.

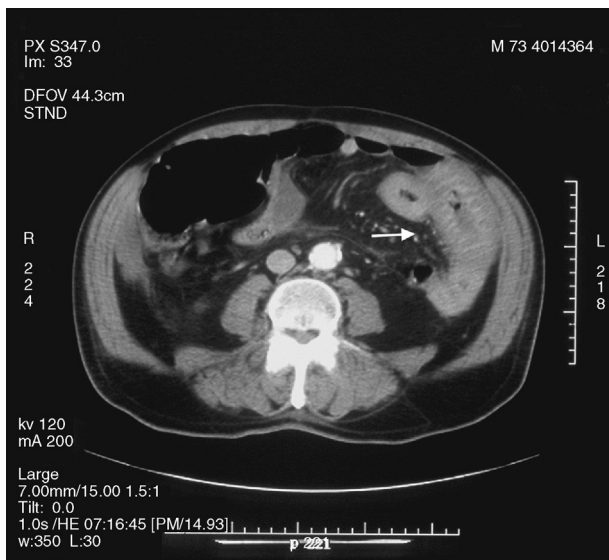

Figure 2 Computerized tomography scan showing edema and intramural hemorrhage in the distal duodenum and the proximal jejunum (arrow).

Financial disclosure

No financial support was received in relation to this article.

Conflict of interest

The authors declare that there is no conflict of interest.