

Ticking time bomb: abdominal aortal aneurism detected at prehospital level

VLADA TAMBURKOVSKI, SLADJANA ANĐELIĆ

Municipal EMS Institute, Belgrade, Serbia

Correspondence:

Sladjana Andjelic

Municipal EMS Institute of Belgrade

Franse dEperea 5, 11000 Belgrade, Serbia

Phone: +381641245757

E-mail: novizivot94@gmail.com

ABSTRACT

The cause of sudden death is increasingly more frequent due to abdominal aortal aneurism (AAA). This ticking “time bomb” in the abdomen is particularly inconvenient for diagnosis and treatment at the prehospital level. We present a rare case of prehospitally detected AAA that like the ticking time bomb threatened to rupture.

Case scenario. A 66 years old male called Emergency Medical Services (EMS) due to unbearable pain (9/10 at the pain intensity scale) of crescendo type in the right gluteal region and the right hip. Four days before, due to a sudden feeling of pain within the above quoted region he underwent neurological, orthopedic and urological examinations. The diagnosis of coxarthrosis/coxalgia was made. He was treated with analgesics with suggested rest. Anamnestically, he was previously healthy, without family history of AAA. He is a several-year smoker and hypertonic. Physical findings: conscious, orientated, eupnoic, afebrile, normal skin color, with visible mucosa, excessive sweating and obesity. Auscultatory findings of the lungs and heart were also within normal limits. SaO₂ = 99%. Blood pressure (BP) on both hands was 170/100 mmHg. ECG: sinus rhythm with a frequency of 80/min, without acute ST-T changes. The abdomen above the chest was with palpable pulsating tumefaction (size 5-6 cm) in the right inguinum that was respiratory immovable. Lazarević sign negative. Prehospital diagnosis was made: suspected AAA. On admission: treated as the emergency case, after multislice computed tomography (MSCT) and angiographic findings indication for emergency surgical intervention was made. He was of good general condition and satisfactory local status. Ten days after surgery the patient was released from hospital with prescribed antihypertensive and antiaggregant therapy,

and was also forbidden smoking.

Conclusion. The reported case is the confirmation that AAA represents a ticking “time bomb” in the organism that requires emergency prehospital recognition, emergency care and high emergency transport to a hospital.

Key words: aneurism, abdominal aorta, ticking time, bomb, prehospital, detection

INTRODUCTION

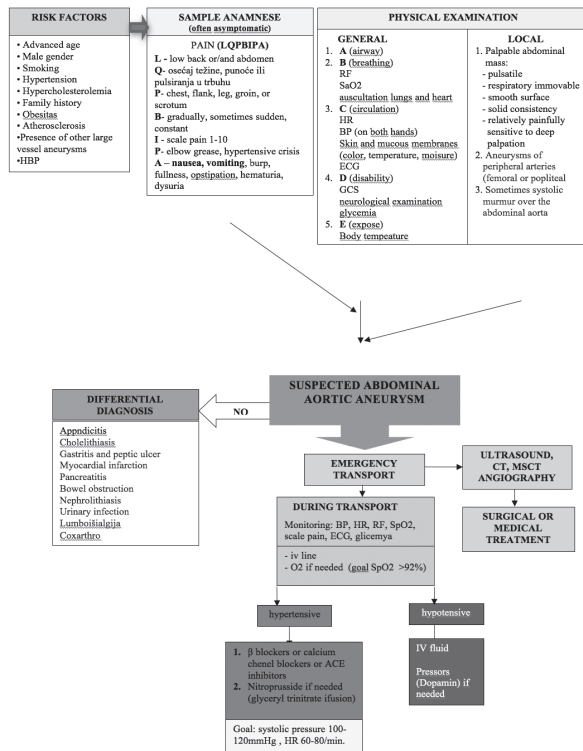
Abdominal aortal aneurism (AAA) is one of the most significant vascular diseases with life-threatening complications. Most significant are rupture and massive bleeding, thrombosis and distal embolization with the consequent irreversible ischemia of the lower extremities, dissection and thrombosis of visceral organs arteries. (1) It is the third leading cause of sudden death in males aged over 60 years. (2) Population is more than before exposed to risk factors that influence the occurrence and development of this disease (smoking, hypertension, obesity, dislipidemia, atherosclerosis). These are the main causes of the increase in the number of the diseased as undoubtedly confirmed by epidemiological data. Recently, 150.000 new AAAs have been disclosed in the USA. In the Western Europe there are over 700.000 persons suffering of AAA. Although we do not belong to highly developed countries, identical trend has been also registered in Serbia, particularly in regard to the complicated forms of AAA. (2) Mostly asymptomatic, AAA has been termed the “silent killer” because it often remains undiagnosed until the moment of rapture or death of the patient. (3,4) According to the recently published articles AAA is considered the ticking time bomb (5) that can develop into catastrophe. (6)

Although today there are sophisticated methods for early detection of AAA, even those of large diameter are still discovered as the incidental finding of ultrasound examination performed from other reasons. The frequency of discovering AAA by clinical examination at the Emergency medical service (EMS) is exceptionally low despite the fact that it does not require any diagnostic equipment. (2) This clearly points out that the basic physical examination of a patient is most often neglected or inadequately carried out. In diagnosing AAA EMS physicians could be helped by internal protocols like that of Belgrade (algorithm 1).

We are presenting a rare case of prehospitally detected AAA that like a ticking time bomb threatened to rupture.

CASE REPORT

EMS team was dispatched at 01:34 a.m. to a 66-year-old male moaning due to a high intensity pain in the right gluteal region and the right hip. The pain did not involve the region outside this zone. It was of crescendo type: it started during the previous day at about 8 a.m. out of complete health, without provocative factors (injury) to increase in frequency and intensity at about 8:00 p.m. At the time of EMS call the pain was constant and unbearable (9/10 on intensity pain scale). Due to a suddenly developed pain in the above mentioned region, four days before he had been examined neurologically, orthopedically and urologically. After laboratory analysis, X-ray of pelvis and spine the diagnosis of coxarthrosis/coxalgia was made; pain of the right gluteal region. The patient was treated with analgesics. Rest was suggested. According to a previous anamnestic assessment the patient had been in full health and without family history of AAA.



Algorithm 1. Internal protocols for diagnosing abdominal aortal aneurism (AAA)

The patient is a long-term smoker and hypertonic.

On examination: conscious, orientated, eupnoic, afebrile, normal skin color, with visible mucosa, excessive sweating and obese. Cardiac action rhythmical, other sounds clear and without murmurs. Blood pressure (BP) was 170/100 mmHg on both hands. X-ray: sinus rhythm, rate of 80/min, without acute ST-T changes. Lung auscultation: vesicular breath, oxygen saturation SaO2 99%. The abdomen was above the chest midline, with palpable pulsating tumefaction in the right inguinum, which was respiratory unmovable although painfully sensitive on deep palpation. According to the subjective assessment of the physician the size of the tumefaction size was 5-6 cm, Lazarevic was negative. Pre-hospital diagnosis: suspected abdominal aortal aneurism. Under monitoring of BP, ECG, SaO2 the patient was transported to the Hospital for Vascular and Endovascular Surgery of the Clinical Center of Serbia. The patient was treated with antihypertensive medication (Captopril 25 mg tablets). Emergency admission: he was examined in the hospital, laboratory findings were obtained as well as ultrasound and multi-detector computed tomography (MDCT)

angiography (juxtarenal aortal aneurism with the maximal thrombus dimension of about 86 mm with signs of threatening rupture and aneurism of both common iliac arteries). Indication was made for emergency surgical treatment. He was of good general condition and satisfactory local status; ten days after surgery the patient was released from hospital with prescribed antihypertensive and antiaggregant drug treatment and forbidden smoking.

DISCUSSION

Pain as a protective mechanism is a signal of warning that directly points at existing disorder in the organism. (7) It is the initial factor that in our case prompted a previously healthy person to call EMS. At the same time this was also a signal to the physician to undertake all available diagnostic methods so as to detect the cause of pain. The occurrence of AAA is often followed by pain that is localized deeply in the abdomen, always present, of typical character for abdominal pain, most frequently propagating toward the lumbosacral region. (2) In the literature AAA is described in patients with low back pain, (8) however,

this is the first AAA case with pain that manifested in the right gluteal region and the right hip. In our patient, intensive pain in this region masked the clinical feature and deceived hospital physicians who in the diagnostic analysis focused exclusively at the punctum maximum of pain. (7) Perpetually present, crescendo type of pain, resistant to the prescribed analgesic therapy, increased the EMS physicians' index of suspicion for a more serious disease. Even in the absence of typical clinical features, the knowledge of risk factors for the occurrence and development of AAA can enable its timely discovery. Although, according to the European Society of Cardiology (ESC) guidelines, family history is a strong predictor for the development of AAA, (1) anamnestic data obtained from our patient did not confirm such opinion. However, male gender, the age of over 65 years, smoking and hypertension were the clear risk factors for the development of this disease.

AAA diagnostics begins with physical examination of the abdomen. For the time being it is the only diagnostic method possible at the prehospital level in Serbia. For the correct presentation of physical findings it is necessary to have knowledge of the topographic-anatomic division of the anterior abdominal wall. (7) AAA can be registered by a careful palpation of the abdomen. It is described as a pulsatile abdominal mass, respiratory immovable, of smooth surface, hard consistence, relatively painfully sensitive on deep palpation. (2) Patients themselves can often notice the appearance of abdominal pulsations. Occasionally systolic murmur can be heard above the aorta by auscultation, while pulse above the femoral arteries is weakened. Still, sometimes even large aneurysms of the abdominal aorta can be difficult to disclose by objective physical examination of the patient, particularly in obese persons. AAA diameter is an important means for the accuracy of physical examination. If the diameter, as in our patient, is over 5 cm AAA can be detected by palpation in 75% of cases, while in the diameter lower than 4 cm it is possible in less than 30% of cases. (9) These data should be taken conditionally, because obesity makes physical examination of the abdomen difficult or even impossible. Due to the obesity of our patient the size of AAA could not be even determined at the prehospital level. The final diagnosis was made after obtained ultrasonographic and multislice computed tomography (MSCT) angiographic findings, which is de facto in accordance with up-to-date worldwide and

national guidelines. (1,2) Abdominal aortal aneurisms of infrarenal localization, as in the presented case, represent high risk surgical procedures. Aneurismal rupture of the abdominal aortal infrarenal segment is an emergency hospital condition with a high mortality rate prior to the patient even reaching a hospital. (10) Extremely high risk of rupture exists already at the diameter changes of over 8 cm and it increases exponentially with every millimeter in diameter changes, and therefore

aneurisms of over 8 cm in diameter are regarded as gigantic. Most aortic aneurisms remain undetected until manifested by an unexpected catastrophic event, i.e. rupture which is associated with the mortality of ruptured aneurisms rating even up to 90%. (3,4) The disturbing fact is that the rupture of a large AAA can even occur without the manifestation of previous symptoms.

Conclusion

Despite the progress achieved over the last decades in the field of prehospital di-

agnostics and therapy, AAA remains a great challenge for EMS physicians. The introduction of internal protocols like Belgrade's can facilitate early recognition of AAA under out-hospital conditions. The presented case is the confirmation that AAA represents a ticking time bomb in the organism that requires urgent recognition, emergency health-care and the highest-priority transport to a hospital.

REFERENCES

1. Erbel R, Aboyans V, Boileau C, Bossone E, Bartolomeo RD, Eggebrecht H, et al. ESC Committee for Practice Guidelines. 2014 ESC Guidelines on the diagnosis and treatment of aortic diseases: Document covering acute and chronic aortic diseases of the thoracic and abdominal aorta of the adult. The Task Force for the Diagnosis and Treatment of Aortic Diseases of the European Society of Cardiology (ESC). *Eur Heart J* 2014 Nov 1;35(41):2873-926. doi: 10.1093/eurheartj/ehu281.
2. Republička stručna komisija za izradu i implementaciju Vodiča dobre kliničke prakse. Ministarstvo zdravlja Republike Srbije. Milašinović G. (ed). Nacionalni vodič dobre kliničke prakse: Aneurizmatiska bolest trbušne aorte. Beograd: Agencija za akreditaciju zdravstvenih ustanova Srbije, 2013.
3. Gordon PA, Toursarkissian B. Treatment of abdominal aortic aneurysms: the role of endovascular repair. *AORN J* 2014;100(3):241-59. doi: 10.1016/j.aorn.2014.01.025.
4. Elefteriades JA, Sang A, Kuzmik G and Hornick M. Guilt by association: paradigm for detecting a silent killer (thoracic aortic aneurysm). *Open Heart* 2015;2: e000169. doi:10.1136/openhrt-2014-000169.
5. Howell CM, Rabener MJ. Abdominal aortic aneurysm: A ticking time bomb. *JAAPA* 2016;29(3):32-6. doi: 10.1097/01.JAA.0000480855.07045.50.
6. Girardeau RP. TICKING TIME BOMB. How aortic aneurysms become aortic catastrophes. *JEMS*. 2016; 41(3):56-60, 62.
7. Jovanović M, Jović M, Jolić A. Diferencijalna dijagnoza abdominalnog bola u prehospitalnim uslovima. *TMG* 2006;31(3):102-15.
8. Van Wyngaarden JJ, Ross MD, Hando BR. Abdominal aortic aneurysm in a patient with low back pain. *J Orthop Sports Phys Ther* 2014;44(7):500-07. doi: 10.2519/jospt.2014.4935.
9. Fink HA, Lederle FA, Roth CS, Bowles CA, Nelson DB, Haas MA. The accuracy of physical examination to detect abdominal aortic aneurysm. *Arch Intern Med* 2000;160:833-6.
10. Juković M, Koković T, Nikolić D, Ilić D, and Till V. Lower back pain – silent symptom of chronic infrarenal abdominal aneurysm rupture. *Med Pregl* 2016;69(3-4):115-7.