

EUR 125.e

EUROPEAN ATOMIC ENERGY COMMUNITY – EURATOM

**RECENT DATA
ON THE TREATMENT OF RADIATION INJURIES**

by

A. MASSART and J. RODESCH

1963



Medical Service

LEGAL NOTICE

This document was prepared under the sponsorship of the Commission of the European Atomic Energy Community (EURATOM).

Neither the EURATOM Commission, its contractors nor any person acting on their behalf:

- 1 — Make any warranty or representation, express or implied, with respect to the accuracy, completeness, or usefulness of the information contained in this document, or that the use of any information, apparatus, method, or process disclosed in this document may not infringe privately owned rights; or
- 2 — Assume any liability with respect to the use of, or for damages resulting from the use of any information, apparatus, method or process disclosed in this document.

The authors' names are listed in alphabetical order.

This report can be obtained, at the price of Belgian Francs 120,—, from: PRESSES ACADEMIQUES EUROPEENNES - 98, Chaussée de Charleroi, Brussels 6.

Please remit payments to:

- BANQUE DE LA SOCIETE GENERALE (Agence Ma Campagne) - Brussels - account No. 964.558,
- BELGIAN AMERICAN BANK AND TRUST COMPANY - New York - account No. 121.86,
- LLOYDS BANK (Foreign) Ltd. - 10 Moorgate -

giving the reference: "EUR 125.e - Recent data on the treatment of radiation injuries."

Printed by Snoeck-Ducaju & Fils, Ghent.
Brussels, December 1963.

EUR 125.e

RECENT DATA ON THE TREATMENT OF RADIOLESIONS
by A. MASSART and J. RODESCH

European Atomic Energy Community - EURATOM
Medical Service
Brussels, December 1963 - Pages 29

Previous observations have opened up new possibilities in the treatment of radiolesions.

The padutin-depot (kallikrein) method has been successfully used in the medical treatment of a late-developing radionecrosis for which the only other solution available was amputation. The results obtained from the research carried out pursuant to these findings prompted the authors to take stock of the more recent clinical and scientific data obtained concerning the new method of treatment.

A preliminary survey of the chemical, physiological and pharmacological properties of padutin is followed by a general outline of radiolesion pathology. The authors then describe 6 cases in which cures were effected, illustrations of which are given in the text.

EUR 125.e

RECENT DATA ON THE TREATMENT OF RADIOLESIONS
by A. MASSART and J. RODESCH

European Atomic Energy Community - EURATOM
Medical Service
Brussels, December 1963 - Pages 29

Previous observations have opened up new possibilities in the treatment of radiolesions.

The padutin-depot (kallikrein) method has been successfully used in the medical treatment of a late-developing radionecrosis for which the only other solution available was amputation. The results obtained from the research carried out pursuant to these findings prompted the authors to take stock of the more recent clinical and scientific data obtained concerning the new method of treatment.

A preliminary survey of the chemical, physiological and pharmacological properties of padutin is followed by a general outline of radiolesion pathology. The authors then describe 6 cases in which cures were effected, illustrations of which are given in the text.

EUR 125.e

RECENT DATA ON THE TREATMENT OF RADIOLESIONS
by A. MASSART and J. RODESCH

European Atomic Energy Community - EURATOM
Medical Service
Brussels, December 1963 - Pages 29

Previous observations have opened up new possibilities in the treatment of radiolesions.

The padutin-depot (kallikrein) method has been successfully used in the medical treatment of a late-developing radionecrosis for which the only other solution available was amputation. The results obtained from the research carried out pursuant to these findings prompted the authors to take stock of the more recent clinical and scientific data obtained concerning the new method of treatment.

A preliminary survey of the chemical, physiological and pharmacological properties of padutin is followed by a general outline of radiolesion pathology. The authors then describe 6 cases in which cures were effected, illustrations of which are given in the text.

The radiolesions in question differed in origin, intensity and age and represented accidental radiodermatitis and radionecroses contracted in industry, research and radiotherapy.

The duration of the treatment required depends on whether the lesion becomes apparent early or late and also on the physical conditions in which irradiation occurred. Normal cicatrization was induced in the extremely stubborn radionecrosis dating back 37 years, for example, after treatment lasting one year. An early-developing ulcerated radiodermatitis was cured in six weeks.

The effect of padutin is also discussed, the view advanced being that the substance possesses trophic properties in addition to its well known function as a peripheric vasodilator. The nutrition of the cells is restored by improving the capillary system, which is impaired by irradiation. The granulations and epithelization are stimulated and healing is rapid and permanent. Mechanical trauma at the point of the original radiolesion does not give rise to any complications.

The possibility is considered of achieving similar results by applying the same treatment to radionecroses of the bone.

The radiolesions in question differed in origin, intensity and age and represented accidental radiodermatitis and radionecroses contracted in industry, research and radiotherapy.

The duration of the treatment required depends on whether the lesion becomes apparent early or late and also on the physical conditions in which irradiation occurred. Normal cicatrization was induced in the extremely stubborn radionecrosis dating back 37 years, for example, after treatment lasting one year. An early-developing ulcerated radiodermatitis was cured in six weeks.

The effect of padutin is also discussed, the view advanced being that the substance possesses trophic properties in addition to its well known function as a peripheric vasodilator. The nutrition of the cells is restored by improving the capillary system, which is impaired by irradiation. The granulations and epithelization are stimulated and healing is rapid and permanent. Mechanical trauma at the point of the original radiolesion does not give rise to any complications.

The possibility is considered of achieving similar results by applying the same treatment to radionecroses of the bone.

The radiolesions in question differed in origin, intensity and age and represented accidental radiodermatitis and radionecroses contracted in industry, research and radiotherapy.

The duration of the treatment required depends on whether the lesion becomes apparent early or late and also on the physical conditions in which irradiation occurred. Normal cicatrization was induced in the extremely stubborn radionecrosis dating back 37 years, for example, after treatment lasting one year. An early-developing ulcerated radiodermatitis was cured in six weeks.

The effect of padutin is also discussed, the view advanced being that the substance possesses trophic properties in addition to its well known function as a peripheric vasodilator. The nutrition of the cells is restored by improving the capillary system, which is impaired by irradiation. The granulations and epithelization are stimulated and healing is rapid and permanent. Mechanical trauma at the point of the original radiolesion does not give rise to any complications.

The possibility is considered of achieving similar results by applying the same treatment to radionecroses of the bone.

EUR 125.e

EUROPEAN ATOMIC ENERGY COMMUNITY – EURATOM

**RECENT DATA
ON THE TREATMENT OF RADIATION INJURIES**

by

A. MASSART and J. RODESCH

1963



Medical Service

CONTENTS

1 — INTRODUCTION	6
2 — THE ORIGIN AND NATURE OF PADUTIN	7
3 — CHEMICAL PROPERTIES	8
4 — PHYSIOLOGY AND PHARMACOLOGY	8
5 — "PADUTIN-DEPOT"	10
6 — THE THERAPEUTIC POSSIBILITIES	11
7 — THE BIOLOGICAL ASPECT OF RADIATION INJURIES	11
7.1 Cutaneous radiation injuries	12
7.1.1 Erythema	12
7.1.2 Early radiodermatitis	14
7.1.3 Late radiodermatitis	14
7.2 Complications of late radiodermatitis	15
7.2.1 Ulcerations	15
7.2.2 Malignant formations	15
8 — THE SEARCH FOR A THERAPY FOR RADIATION INJURIES	15
8.1 Bullate radiodermatitis (Industry)	16
8.2 Late radiodermatitis (Research Laboratory)	18
8.3 Late radionecrosis (Curietherapy)	20
8.4 Delayed radionecrosis (X-ray therapy)	21
8.5 Late radionecrosis (X-ray therapy and Curietherapy)	23
8.6 Severe late ulcerative radionecrosis (Curietherapy)	24
9 — THE BONE-TISSUE	27
LITERATURE	29

RECENT DATA ON THE TREATMENT OF RADIATION INJURIES

SUMMARY

Previous observations have opened up new possibilities in the treatment of radiolesions.

The Padutin-dépôt (kallikrein) method has been successfully used in the medical treatment of a late-developing radionecrosis for which the only other solution available was amputation. The results obtained from the research carried out pursuant to these findings prompted the authors to take stock of the more recent clinical and scientific data obtained concerning the new method of treatment.

A preliminary survey of the chemical, physiological and pharmacological properties of padutin is followed by a general outline of radiolesion pathology. The authors then describe 6 cases in which cures were effected, illustrations of which are given in the text.

The radiolesions in question differed in origin, intensity and age and represented accidental radio-dermatitis and radionecroses contracted in industry, research and radiotherapy.

The duration of the treatment required depends on whether the lesion becomes apparent early or late and also on the physical conditions in which irradiation occurred. Normal cicatrization was induced in the extremely stubborn radionecrosis dating back 37 years, for example, after treatment lasting one year. An early-developing ulcerated radiodermatitis was cured in six weeks.

The effect of padutin is also discussed, the view advanced being that the substance possesses trophic properties in addition to its well-known function as a peripheral vasodilator. The nutrition of the cells is restored by improving the capillary system, which is impaired by irradiation. The granulation and epithelization are stimulated and healing is rapid and permanent. Mechanical trauma at the point of the original radiolesion does not give rise to any complications.

The possibility is considered of achieving similar results by applying the same treatment to radionecroses of the bone.

« La médecine est l'art de guérir,
elle n'est que cela. »
(*"Medicine is the art of healing,
nothing else."*)

(Trousseau)

1 — INTRODUCTION

Since the discovery of X-rays the problem dealing with medical therapy for lesions induced by ionizing radiations has been discussed in numerous studies of all kinds.

Despite the diversity of techniques used and pharmaceutical products employed, the results obtained so far have generally proved disappointing.

It is unfortunate to find that most physicians, observing the failure of medical therapy, regard surgery as the only effective method of checking the course of the disease.

On the practical level this means that grafting, with varying degrees of success, is resorted to for lesions of soft parts, and as regards the extremities, which are very often affected, faith is ultimately placed in rapid and drastic amputation of the phalanges and fingers [1].

The Euratom Medical Service has studied this problem, which falls within its immediate competence.

Starting out from the premise that lesions due to radiation are not necessarily specific, i.e. ionizing radiation leads to disorders of the organism which are anatomically and biochemically comparable to those caused by other harmful agents, we have attempted to apply to the treatment of radiation injuries a therapy which has been tried out on cases of atonic injuries and gangrene of the extremities.

We have already suggested certain new therapeutical possibilities for lesions produced by ionizing radiations [2] and reported a case of retarded radionecrosis for which the only cure was thought to be amputation, but which to all appearances was completely and finally healed by means of an intensive treatment with "PADUTIN-DEPOT" (kallikrein) [3].

Following these results, which exceeded all our expectations, and thanks to the encouragement given by university bodies and the understanding and active support of the Euratom Commission, the Medical Service, in cooperation with research workers in other fields, has carried out work designed to reproduce the healing phenomenon and, as far as possible, to provide users of ionizing radiations with a treatment which can be employed in radiotherapy, industry and research laboratories. This new technique, far from being a substitute for safeguards against health hazards, is intended as a supplement to the latter in cases of accidental irradiation which, despite safety precautions, occur far more often than one might venture to suppose. This was confirmed, moreover, as soon as the first results had been published, when requests for information and offers of cooperation poured in from all sides.

The new technique has been adopted by hospital services, research institutes and industrial concerns. The results have been pooled and analysed at the Euratom Medical Service where we are trying to establish the optimum conditions governing the use of this substance.

The Euratom Commission has also entered into a research contract with the University of Strasbourg (Professor Mandel) to which the BAYER Manufacturing Co, producing the drug, are making a considerable financial contribution. The research work relates to animal subjects and aims at the large-scale reproduction of the phenomena.

The study also covers research into the mechanism of the radiation injury and its treatment. The chemical constitution of padutin will also be investigated as well as the possible association of other substances with it. We may mention, for example, the deintoxicants used for eliminating the noxious agents resulting from the catabolism of certain vital substances as well as certain vitamins.

Research began on October 1st, 1962, and we shall not fail to report on it as the work progresses.

The results obtained to date on human material are extremely encouraging.

Before describing the clinical observations sent to the Euratom Medical Service we thought it appropriate to give some details on the nature of the substance used and its chemical, physiological, pharmacological and pharmacodynamic properties.

For the sake of clarity we will give a brief outline of the histological constitution of the skin and the biological features of radiation injuries to the cutaneous tissue.

2 — THE ORIGIN AND NATURE OF PADUTIN

Kallikrein, marketed under the trade name padutin, was discovered by Frey in 1925 during research aimed at establishing the possible relationships between circulatory and renal activity.

To this end, in experiments on dogs Frey et al. [4] injected the various constituents of urine into the blood stream and measured manometrically the carotid pressure. The results were rather disappointing, but when total urine was injected instead of the separate constituents they were all the more impressive. A few cubic centimetres caused a considerable drop in mean tension and a stepping up of the pulse. Hence the depressive effect of urine was due to an unknown constituent.

After long and careful research the active substance was isolated and purified, and then standardized on dogs. One unit of padutin corresponds to the amount of substance which, when injected intravenously, causes the same drop in carotid pressure as that caused by the direct injection of 5 cc. of normal human urine taken from a volume of at least 50 l. and dialyzed for 24 h. in running water.

The vasodilating property of the material having been demonstrated in this way, an attempt was made to locate its site of production. It could not be the kidney because it was found impossible to pinpoint the substance in the blood.

It was shown by means of experiments that the urine of hematuria patients loses its vasodilating properties, a finding which led to the theory that kallikrein is combined in the blood with an inactivator normally present.

This theory was also confirmed by the fact that the vasodilating property was wholly reconstituted by acidification of the medium or by the effect of an enzyme (papain). The presence in the blood of the active constituent made it more difficult to discover its origin, in view of the fact that the organs were normally found to contain varying amounts of the substance.

Clinical observations showed that greater amounts of the substances sought are found in cystic formations of the pancreas. Total pancreatectomy caused a drop of about 90% of the proportion usually present in the urine.

It was obvious that the substance was a product of internal secretion of the pancreas, whence its name (Gr. kallikreas = pancreas).

But this organ is not the only producer, as the parotids also secrete a considerable amount of it. Kallikrein was termed "the hormone of the blood stream" because it answered the conditions required for this denomination: internal secretion, active in very small amounts, variable quantities in the blood, specific vasodilating action. But its designation as a "hormone" is challenged by some workers.

3 — CHEMICAL PROPERTIES

The chemical nature of padutin is not yet known exactly. Pharmacological and chemical analysis shows that it contains at least one free amino group, one phenol-hydroxylic or phenolcarboxylic group and one phenol or imidazol radical. It is an amphoteric substance which is sensitive to ultra-violet rays, light and heat.

Its isoelectric point is about pH 4.2. It is weakly soluble in water or 50% alcohol. It is, however, insoluble in alcohol and the usual organic solvents.

These characteristics and the fact that it is precipitated in the presence of sulphosalicylic acid, indicate that padutin would appear as a protein. It is already known to be a polypeptide having a molecular weight of from 30,000 to 50,000.

4 — PHYSIOLOGY AND PHARMACOLOGY

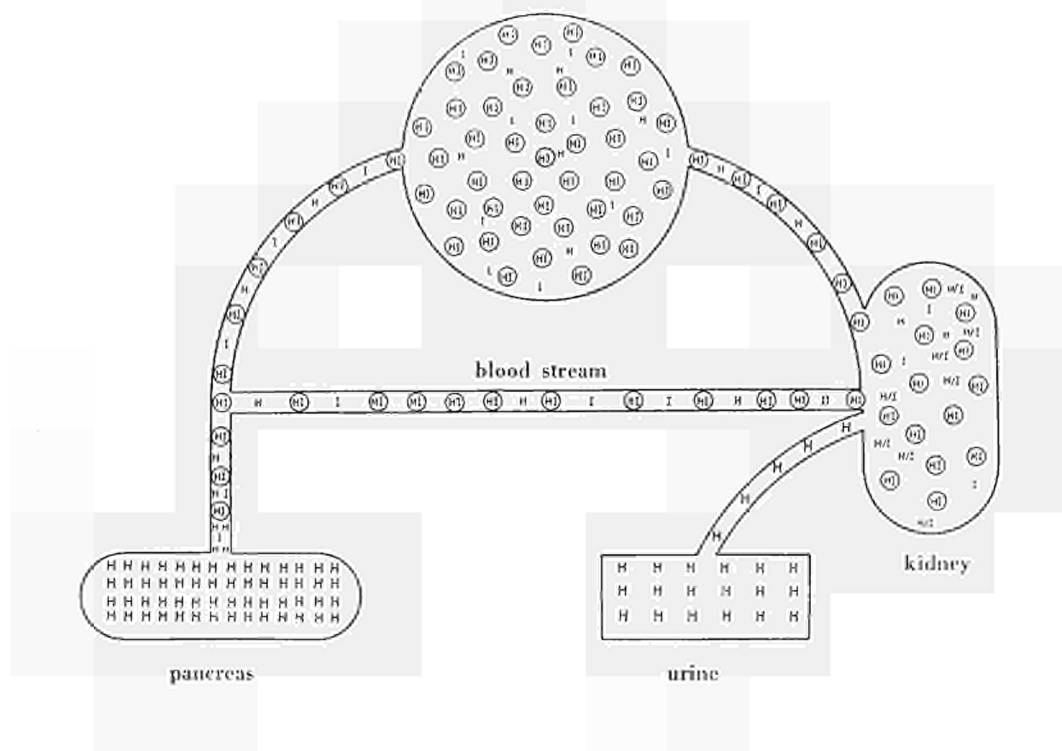
Kallikrein is partly discharged from the productive organs into the circulatory system and partly into the intestine. It is excreted in the urine in an active form.

The blood contains the "inactivator", a substance of a polypeptide character which neutralizes the activity of kallikrein. Padutin doubtless enters into a reversible chemical combination with the inactivator since it can be readily liberated from the compound and become active again. This cycle is illustrated by the following diagram.

Recent research work has revealed the presence of kallikrein in the blood in the active form in a proportion of 5%. Residual padutine is in the inactivated form (95 %).

The inactivation optimum ranges from pH 7.5 to 8.5. The equilibrium may be affected by very slight variations in acidity so that the kallikrein, liberated in the active form, will begin its pharmacodynamic action in the vessels.

Diagram I

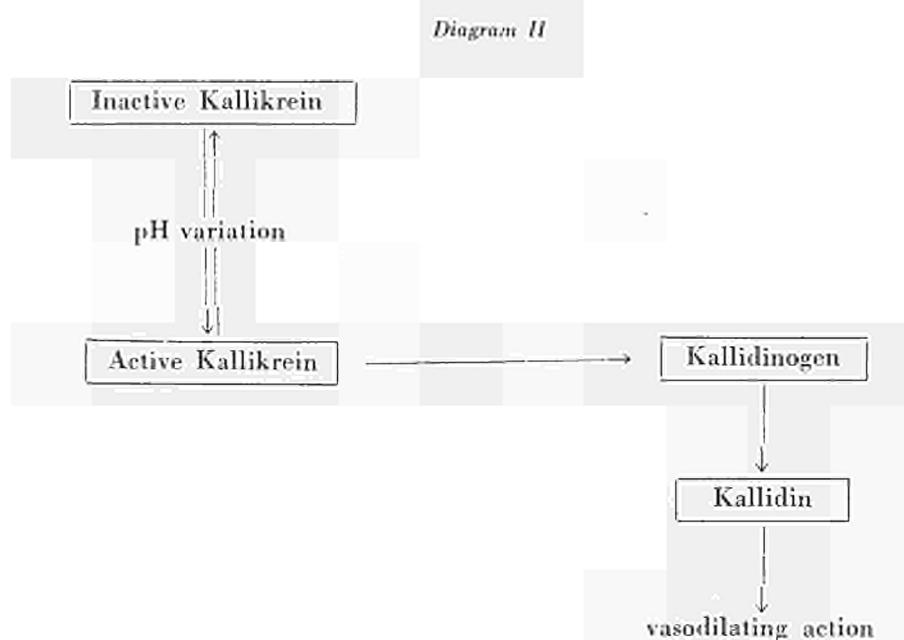


The kallikrein cycle
(according to FREY)

- H Kallikrein in active form (hormone)
- I Inactivator
- HI Inactive kallikrein

According to *Werle* [5], kallikrein in the active form is not the direct causal agent of the vasodilating action. Kallikrein is thought to act as a catalyst by liberating from "Kallidinogen", which is a seroalbumin compound, a peptide known as kallidin which is itself responsible for the effect on the vessels.

The mechanism may be depicted by the following diagram:



*Action-mechanism of kallikrein
(according to WERLE)*

In this regulation process, therefore, several substances act concurrently, viz. kallikrein, by its enzymatic action, kallidinogen by liberating kallidin, and finally the last-mentioned by its pharmacodynamic action on the vessels. Kallikrein and kallidinogen must therefore necessarily be present in the blood stream before any effect can be produced.

We have seen that the mechanism can be obtained by a slight variation of the pH towards the acid side. We get these conditions when there is an accumulation of metabolism end-products (e.g. lactic acid in the case of an important muscular activity, or by the action of cold or other external factors).

In the case of vascular lesions a compensatory action is observed which re-irrigates the collateral capillaries until now in the steady state, thereby helping, by means of an intensified irrigation, to increase the removal of the degradation products. Once the acidobasic balance is restored, kallikrein resumes its inactivated form.

5 — "PADUTIN-DEPOT"

Most of the vasodilating agents have only a very brief action time and therefore have to be administered at short intervals. Thus the continuous regulation of the circulatory stream is injured. It is therefore difficult to make use of its own natural powers of recovery.

For this reason "Padutin-Dépôt" or "Padutin-Retard" was created, which exerts a considerably delayed effect. This form is particularly suitable for long-term treatments.

Hence "Padutin-Dépôt" does not exert an immediate and brief effect, a certain latent period being required for the action to become apparent, but the results are lasting.

The active principle of Padutin-Dépôt is fixed to a high molecular weight colloid in a dry stable form. The drug is administered intramuscularly.

6 — THE THERAPEUTIC POSSIBILITIES

Apart from the effect which they produce on the main vascular system, padutin and Padutin-Dépôt have been found very useful in the treatment of peripheral circulatory disorders.

After padutin has been administered, the arterial irrigation is really increased in the vascular plexuses of the skin and subcutaneous tissue, as well as in the muscular tissue, and the venous reflux is simultaneously reinforced. Since the oxygen supply is stepped up and the tissue nutrition improved, regeneration and defence potential are distinctly enhanced, while epithelisation and granulations are stimulated. This shows the trophic action of padutin.

Thus we have seen a rapid regression of cutaneous infections accompanied by serious ulcerations which did not respond to antibiotics.

Excellent results were obtained in cases of lesions of the skin and deep layers of tissue in which the vascular system had altered by burns, frostbite, arteriosclerosis or endangeitis.

In the same way, skin grafts "take" much better on a base previously treated by padutin.

All these observations go to prove that padutin is a valuable remedy for slowly healing sores, which also include radiation injuries.

7 — THE BIOLOGICAL ASPECT OF RADIATION INJURIES

One of the first organs to be exposed to external ionizing radiation, with which we are concerned in this article, is the skin. With the exception of erythema, changes in the skin due to irradiation may be regarded as radiological accidents.

Accidents occurring in radiotherapy are usually due to technical mistakes. Radiation injuries in industry and research usually result from ignorance of the necessary physical safeguards. Radiation injuries are not generally observed at once, and existing data usually fail to mention such technical details as the type of radiation, the dose, dose rate, energy, field, etc. Since, however, the technical irradiation data determine the moment at which

radiation injuries appear, they are one of the most important factors from the therapeutical standpoint.

Skin lesions are divided into two groups, viz:

- (1) erythemas and cases of early radiodermatitis,
- (2) cases of late radiodermatitis and its complications.

Before discussing these two groups of lesions it may be useful to give some particulars about the constitution of normal skin.

The following cross-section diagram shows the various skin layers and components of the skin tissue.

Three clearly differentiated zones may be distinguished in the cutaneous tissue: *The epidermis*, consisting of horny layer resulting from keratinization, a transparent layer, and a granular layer. These last two layers are the keratinization phenomenon.

Deep down in the epidermis we find a dense layer of cells and a system of fibrils, together known as the stratum mucosum. This layer is responsible for the cohesion and rigidity of the entire skin structure.

Lastly, the layer separating the epidermis from the dermis is termed the basement membrane. The very important biological activity of this layer controls the biosynthesis of the elements of the skin. It also forms the path for nutrients issuing from the underlying vessels and connects the dermis to the epidermis.

The dermis consists of connective tissue with numerous capillaries and contains collagenous and elastic fibres. The latter are very susceptible to inflammation. Their disappearance is one of the causes of the oedema which, as will be shown below, is a concomitant of radiation injuries.

The hypodermis chiefly consists in adipose tissue and connective septa enclosing vessels and nervous system. Vessels are divided up into arteriole and capillary systems that irrigate the pilosebaceous follicles and the sweat glands, so that their destruction may lead to a breakdown in the glandular and pilose system.

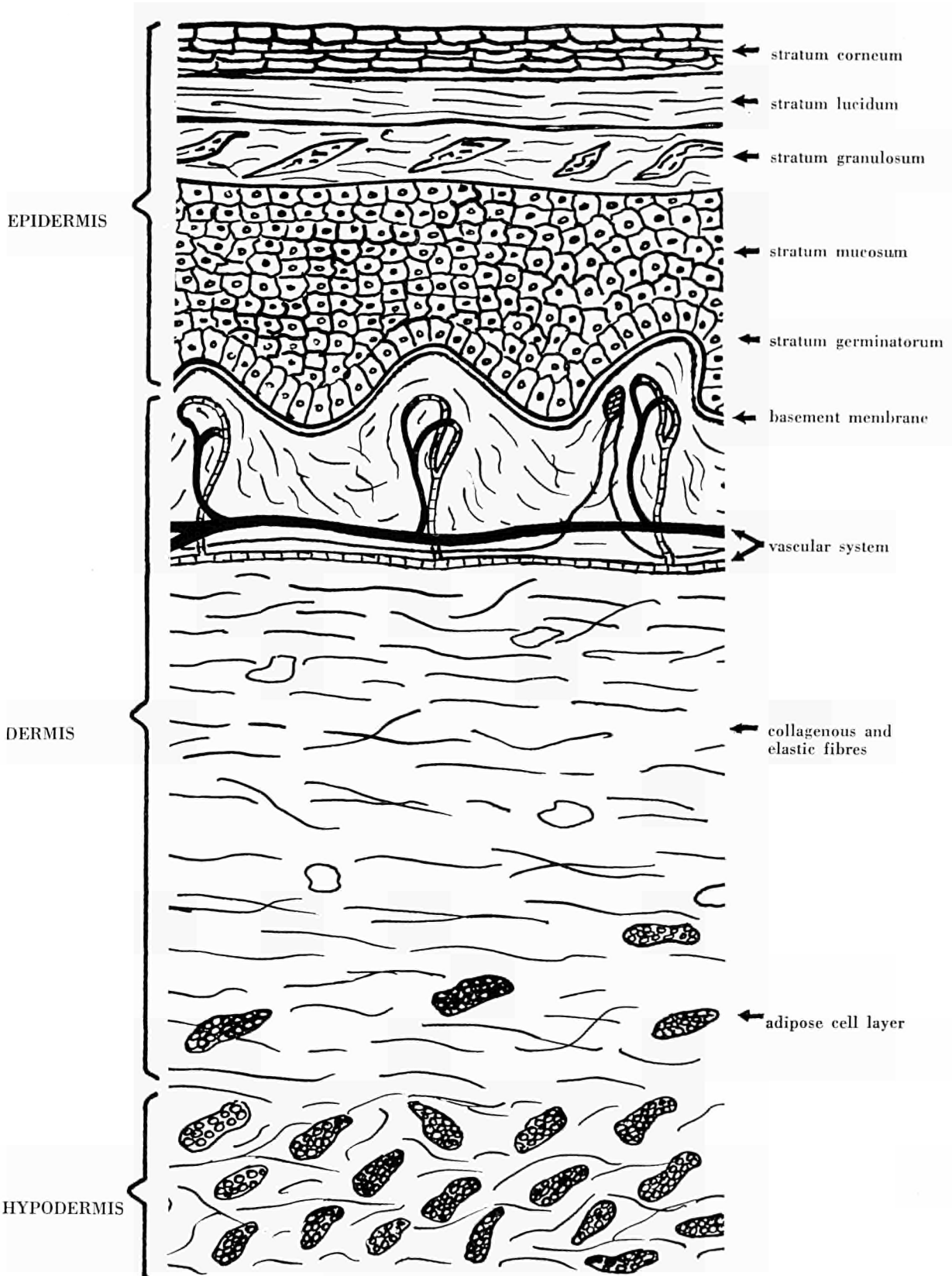
7.1 Cutaneous radiation injuries

Radiation injuries are characterized by symptoms that appear in successive waves.

7.1.1 Erythema

The first outbreak occurs during the 24 hours following irradiation. There are no appreciable changes in the epidermis.

In the dermis, lymphocytic and polymorphonuclear infiltration can be observed round the vessels (which are swollen), extending as far as the hair follicles and the sweat glands. This is, in short, an inflammatory outbreak due to a release of the products of protein catabolism.



CROSS-SECTION OF NORMAL SKIN

In the *second outbreak*, which occurs between the 12th and the 30th day, the injuries grow worse. The epidermis is affected and considerable cytological changes can be observed. The cells of the stratum mucosum are unequal in size and often show vacuolation. Mitoses are of rare occurrence and the basement layer is affected. Oedemata appear in the dermis and may lead to epilation.

During the *third outbreak*, which occurs between the 40th and the 60th day, the epidermis degenerates still further. The stratum mucosum becomes extremely thin and the cells of the basement layer become pycnotic. The cells of the dermis are swollen and show amitotic divisions. A certain degree of fibrositis can be observed.

7.1.2 *Early radiodermatitis*

The second and third outbreaks of erythema constitute what is known as primary radiodermatitis.

Secondary or erythematovesicular radiodermatitis appears at an earlier stage, i.e. between the 6th and 10th day following irradiation.

Vesicles form and afterwards burst, leaving painful running sores. The epidermis recovers within one to two months.

A more pronounced form is known as *bullate radiodermatitis*. This is characterised by epilation which may give rise to ulcerative processes. The epithelium is in a state of degeneration and the basement cells recrose. There is a considerable infiltration of oedemata into the dermis and the collagen loses its fibrillary appearance.

The vessels exhibit advanced atrophy of the septa, finally resulting in progressive blocking of the lumen. The layer of basement cells is destroyed, thereby weakening the dermo-epidermal junction. The dermal oedema raises the epithelium and blistering occurs. The epidermis, being thus deprived of the basement layer, loses its capacity for regeneration and is destroyed, the dermis being denuded as a result. Occasionally, however, peripheral epidermis can be seen proliferating all round the ulceration and covering the wound with a more or less normal tissue.

Tertiary radiodermatitis consists in an ulcerative process which invades the skin in depth. Radiodermatitis ulcers are very painful, show no tendency to cicatrize and do not respond to normal therapy. The ulceration is practically the same as that which appears as a complication in cases of late radiodermatitis.

7.1.3 *Late radiodermatitis*

Changes in the epidermis are the predominant feature of early radiodermatitis.

By contrast, in cases of late radiodermatitis the site involved is the dermis, epithelial lesions being only the result of changes in the connective tissues.

Late radiodermatitis may be due to early erythematous bullate or ulcerous radiodermatitis, or it may only appear after a fairly long latent period (from a few months to several years).

The essential feature of this type of radiodermatitis is an atrophy of the skin components and the substitution of sclerotic tissues for healthy ones.

Among the cellular constituents, collagen undergoes the most radical changes. The vascular system likewise undergoes considerable changes extending as far as complete degeneration.

In cases of serious retarded radiodermatitis the dermis may have entirely lost irrigating capacity. The cells are only fed by newly-formed vessels, the precursors of cicatrization, but incapable of preventing the onset of necrosis. The nervous system is also seriously affected.

7.2 Complications of late radiodermatitis

These complications may be of two types: ulcerations and cancerous formations.

7.2.1 *Ulcerations*

Late or chronic radiodermatitis ulcerates readily. The ulceration process may set in either spontaneously or after only a very slight trauma. The ulceration mechanism in cases of chronic radiodermatitis is entirely different from that described above with reference to early radiodermatitis. The ulcer is probably the result of a mechanical lesion of the epidermis, the cellular nutrition of which is seen to be impaired as a result of radiation. The site of ulceration is probably also in the connective tissue, i.e. the dermis. This latter necroses and the epithelium covering the mortified zone degenerates and sloughs off. The process is apparently bound up with a deficiency of the capillary system. Necrosis is then stabilized and persists in this state. There is no tendency towards cicatrization, no incipient granulation, and the lesion shows very little response to any therapeutical treatment.

7.2.2 *Malignant formations*

Neoplasms vary widely in appearance. Three forms of radiodermatitis tumours may be distinguished, viz. spinocellular epitheliomata, basocellular epitheliomata, and sarcomas.

The first two are the result of progressive alterations in the epidermis due to radiodermatitis degeneration.

Sarcoma is seldom observed following radiodermatitis. This malignant form affects the connective tissue. In the histological picture of these various forms there are disordered and vegetating cellular proliferations with occurrence of abnormal and giant cell types characteristic of cancerous transformations.

8 — THE SEARCH FOR A THERAPY FOR RADIATION INJURIES

We have seen that radiodermatitis, and especially radionecrosis, can be regarded as wounds with retarded cicatrization. It should be remembered that the delay in cicatrization

is primarily due to the elimination of the vascular system and hence to the breakdown in the supply of nutrients and oxygen to the cutaneous cells.

Owing to the vasodilatory effect which it produces on the peripheral vascular system, padutin, since it was first brought on the market, has been used for the treatment of a large number of lesions which showed no response to the usual therapy. Serious ulcerations such as those due to burns, frostbite, arteriosclerosis, endangeitis, etc., that do not respond to antibiotics, began to heal in a comparatively short time thanks to padutin.

It was obvious that padutin acted as a stimulous to granulations and epithelisation.

It is this vasodilating and trophic effect of padutin that prompted our recourse to the product in a last-ditch attempt at healing a radionecrosis of the hand for which amputation was the only other remedy.

The rapid cicatrization and apparently final healing bore out the accuracy of this theory, and padutin, as suggested by *Wolter* [6] in 1933, came on the scene as a new valuable remedy in the treatment of radionecroses in which medicine had previously been compelled to admit defeat and to leave the arena to surgery.

Since the publication of this result, padutin therapy has been practised by a large number of hospital and university services and in occupational medicine centres in Community countries.

In many instances the Euratom Medical Service has given advice and helped to provide prompt treatment, at the same time collecting information of value to research. Although still only fragmentary, some results sent to the Euratom Medical Service are worthy of being put on record.

Those using the new technique are at liberty to publish their observations in detail as they think fit. In fact, physical, biological and biochemical checks, coupled with continous and prolonged observation and experiments on animal material are required to prove beyond any possible doubt the efficacy and suitability of padutin in the treatment of serious radiation injuries.

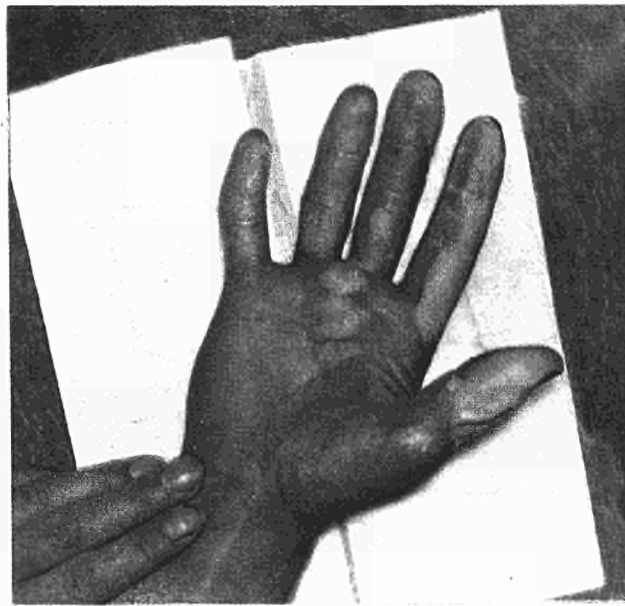
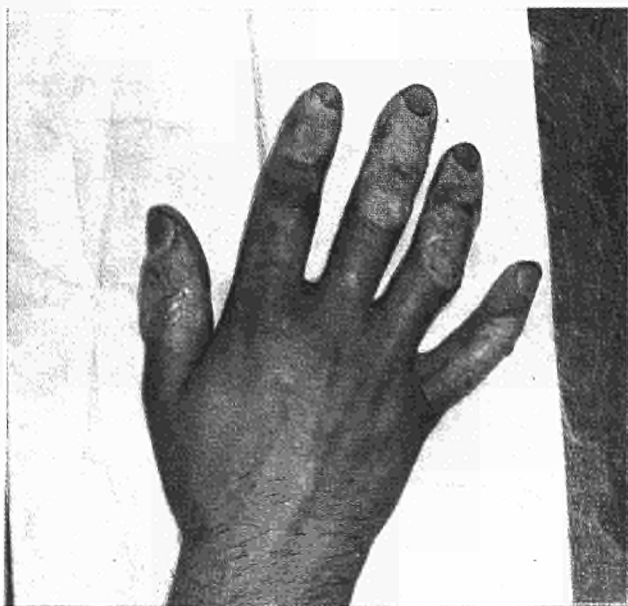Here we will only report results which may be considered significant. We have illustrated them by a series of photographs enabling readers to evaluate the phenomenon before, during and after treatment.

The cases described below extend over the entire range of radiation injuries, from early radioepidermitis to late radionecrosis with serious ulceration.

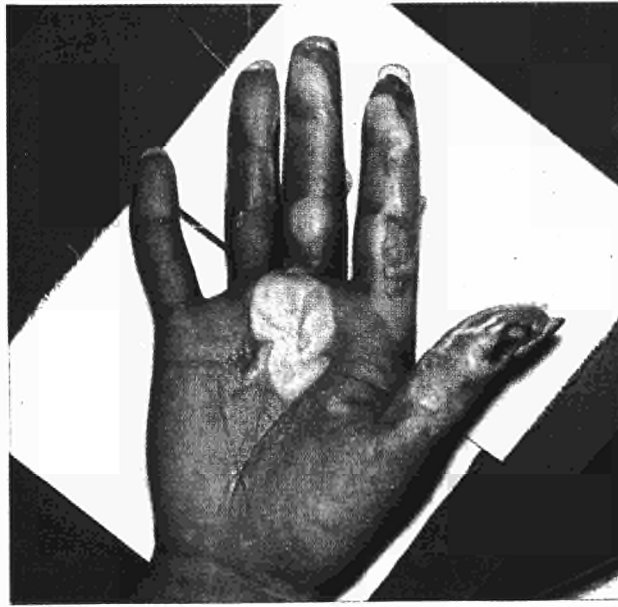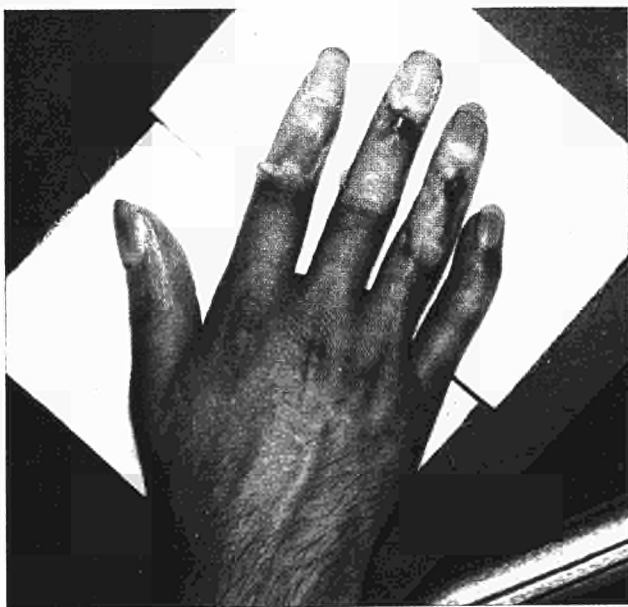8.1 Bullate radiodermatitis (Industry)

Case report: On 6 December 1961 a laboratory technician (K.D.) suffered accidental X-ray irradiation of the right hand. Presumed dose: 3000 r on the skin surface. Radiodermatitis

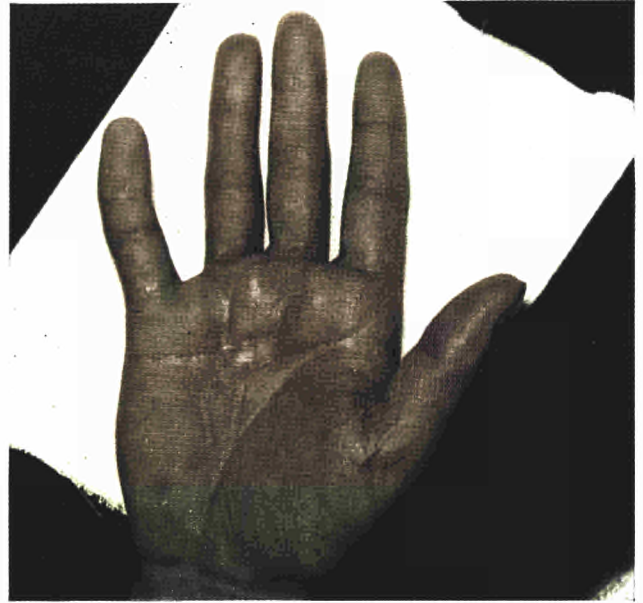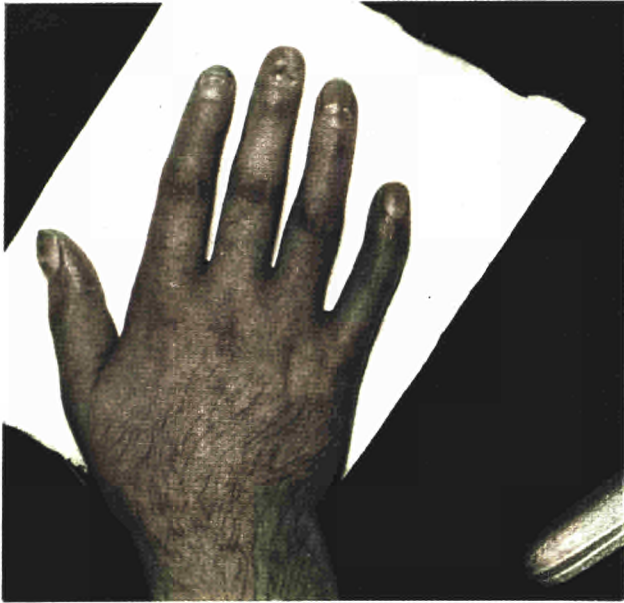immediately set in. Treatment with padutin resulted in a complete cure after six weeks of treatment. There has so far been no recurrence of the lesions.



The radiodermatitis three weeks after irradiation. It is a case of early radiodermatitis.



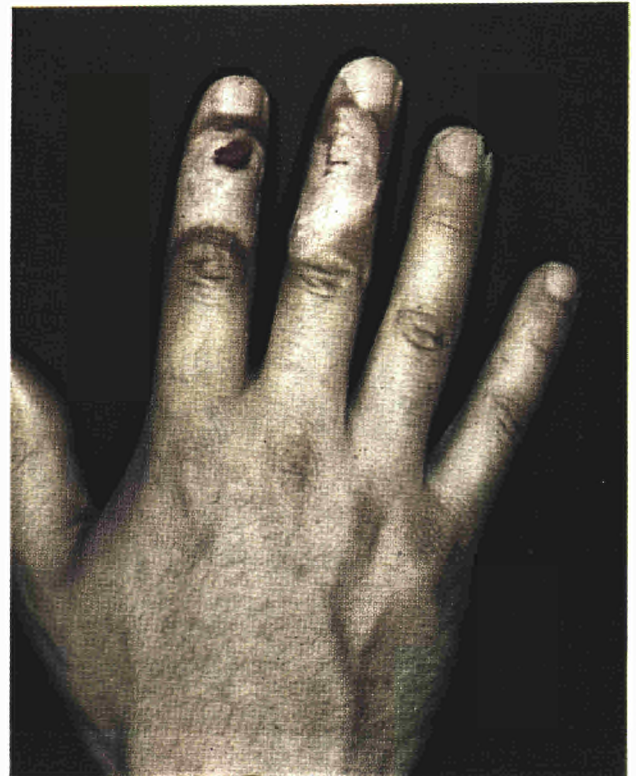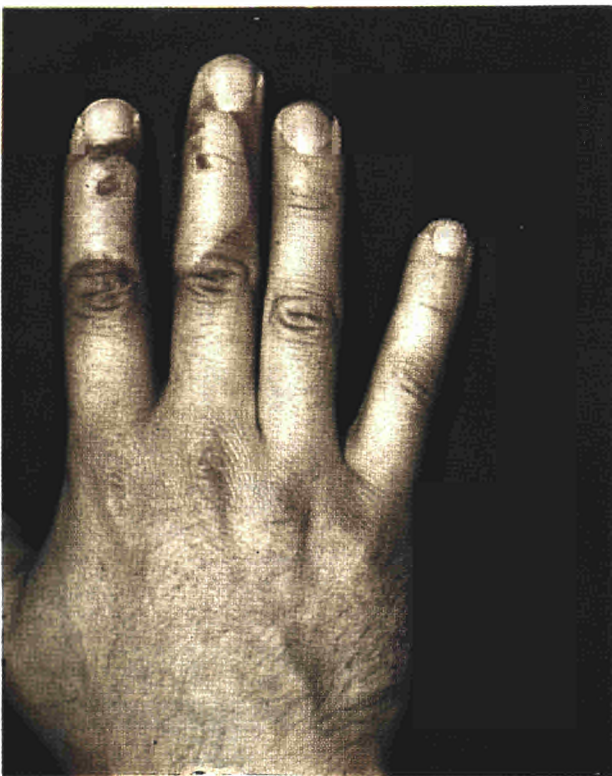Condition of the hand four weeks later, and 15 days after the start of padutin treatment.



Regeneration and cicatrization of the injured areas six weeks after the start of padutin treatment.

8.2 Late radiodermatitis (Research Laboratory)

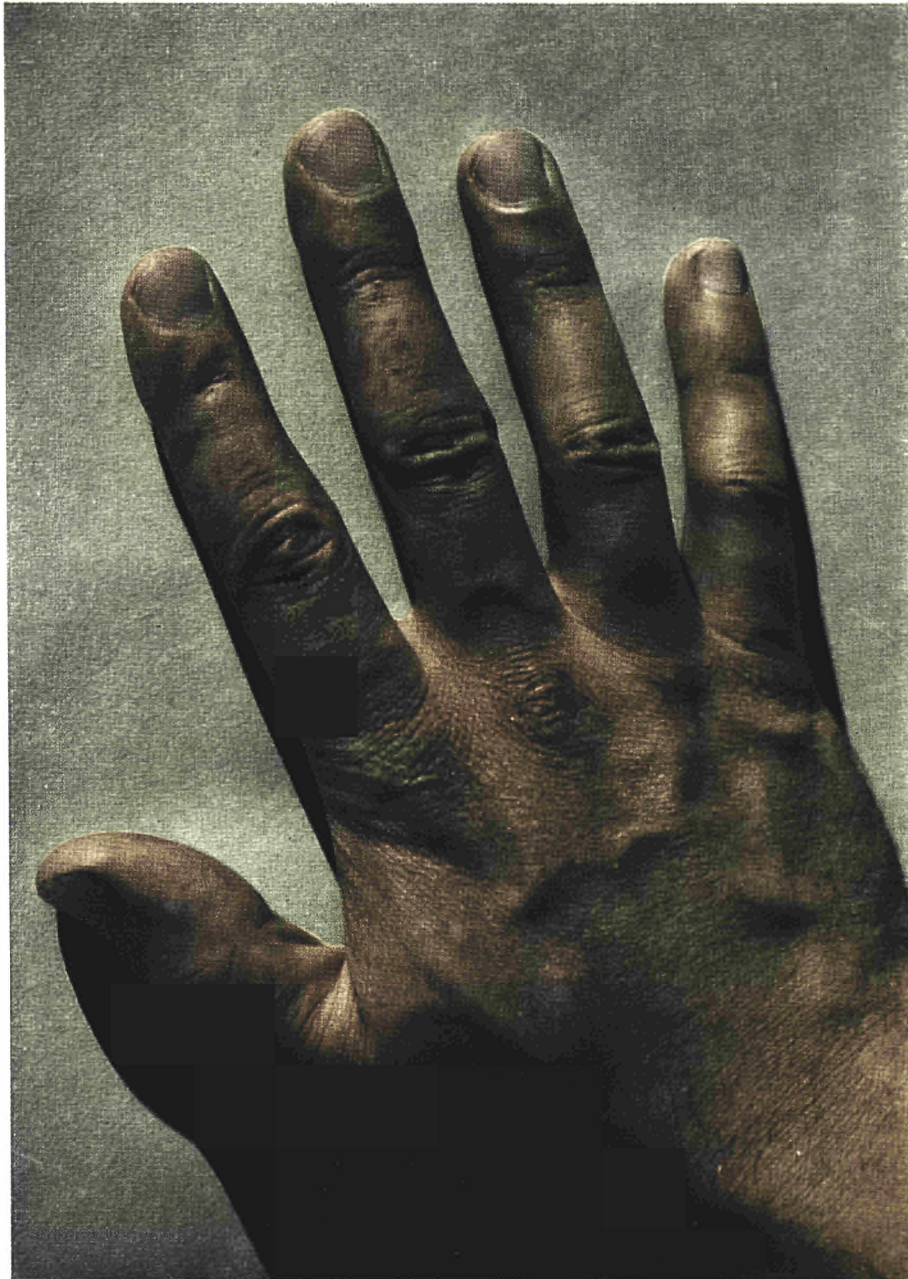
Case report: This was our first case of a cure, a report on which has already been published [3]. The following is a brief recapitulation of the case.



Development of radiodermatitis and onset of radionecrosis before treatment with padutin.

In December 1959 a spectrometry technician (M.J.) was accidentally irradiated on the hand with a substantial dose of X-rays. Presumed dose: 70,000 r. on the surface of the skin. A few days later radiodermatitis set in and developed in the following six months into ulcerative radionecrosis.

Six weeks' treatment with Padutine produced a complete cure and there has been no recurrence to date.

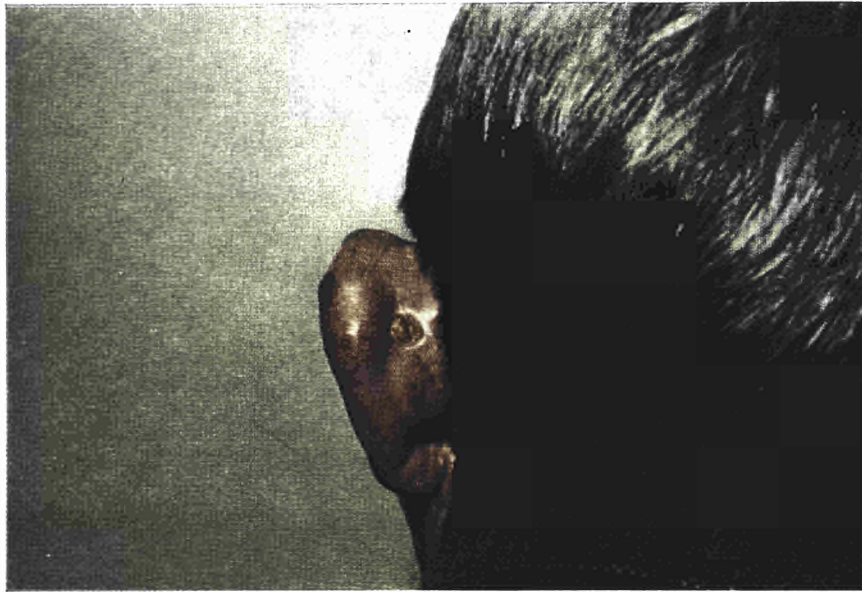

Complete cicatrization of the injured areas six weeks after treatment.

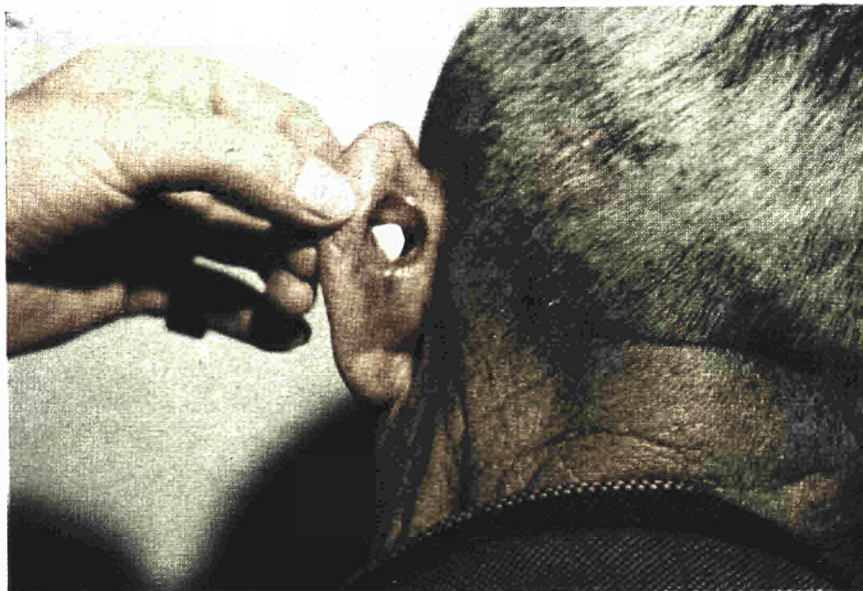8.3 Late Radionecrosis (Curietherapy)

Case report: A patient (B.L.) who in March 1960 had been given radium treatment for spinocellular epithelioma of the ear, exhibited one year later radionecrosis of the irradiated site.

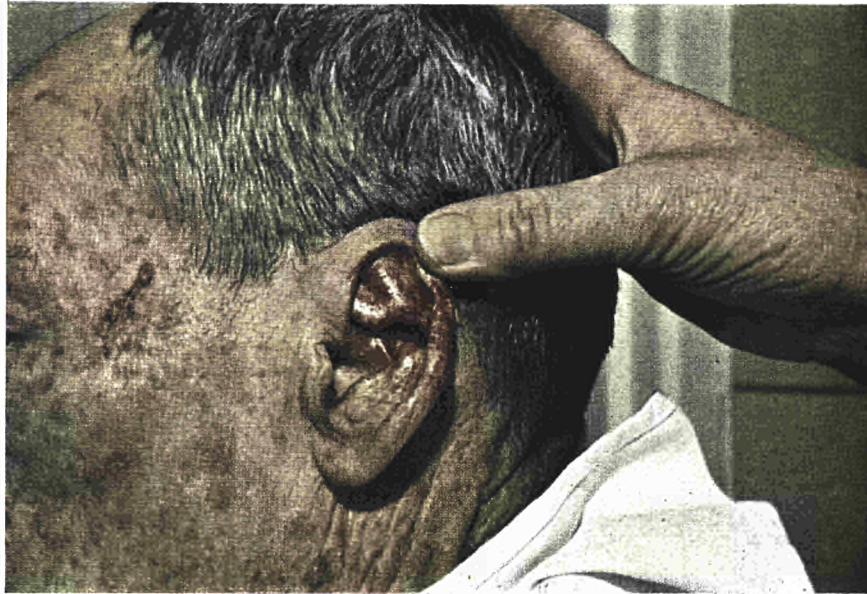The dose administered was 5,000 r. The ear is completely pierced by a deep ulceration. Intensive treatment with padutin is improving epithelization and stabilizing the lesions which have remained static up to now.



The lesion 18 months after irradiation.



State of the lesion shortly before application of padutin.

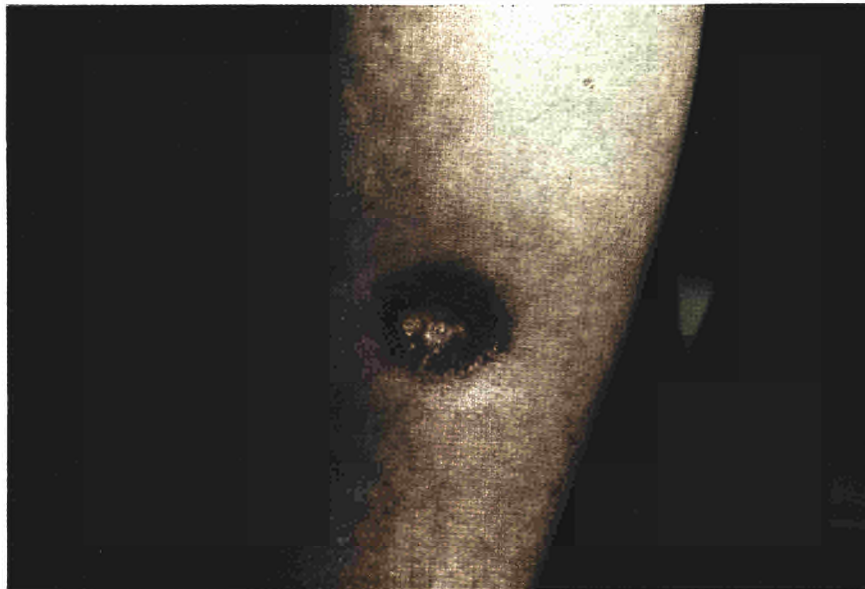


Clinical aspect one year after padutin treatment.

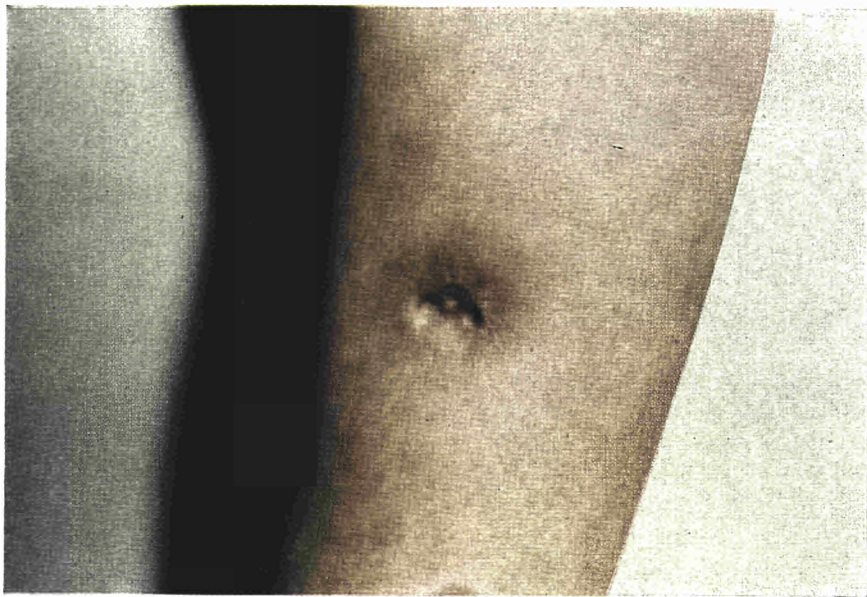8.4 Delayed radionecrosis (X-ray therapy)

Case report: In October 1961, five years after receiving X-ray treatment for cutaneous epithelioma of the leg, the patient (C.J.) exhibited radionecrosis. Dose administered: 6,000 r.

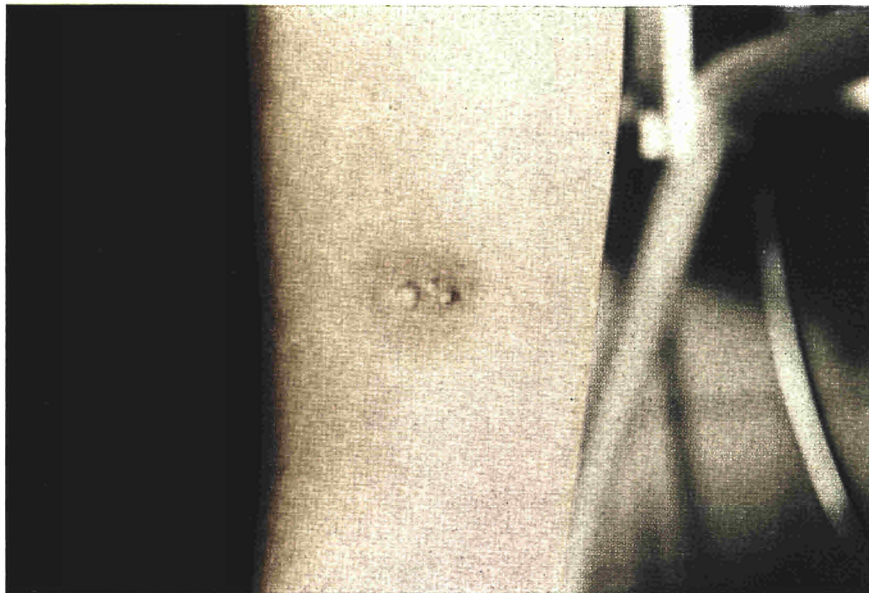
Sixty injections of padutin were necessary in order to bring about a cure. There has been no recurrence to date.



Appearance of the radionecrosis five years after irradiation.



State of the wound on completion of treatment.



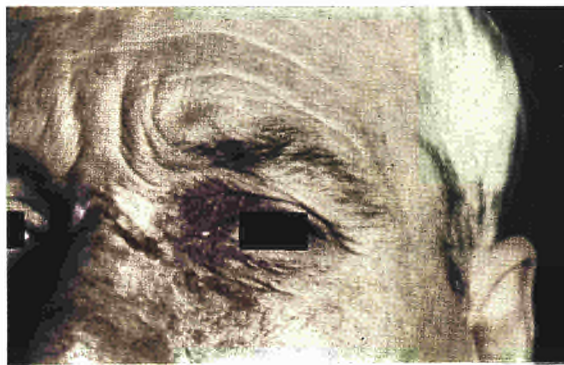
Clinical picture showing complete healing.

8.5 Late radionecrosis (X-ray therapy and Curietherapy)

Case report: Here we have a case of severe radionecrosis occurring after the patient (D.F.) had been given radiotherapy (4,800 r.) and Curietherapy (4,500 r.) for facial epithelioma.

In September 1961 a radiation lesion appeared at the base of the nose. This was a case of delayed radionecrosis occurring about ten years after the first radiological treatment.

A course of 15 padutin injections effected a spectacular cure which has been maintained to date.



Appearance of the lesion ten years after irradiation.



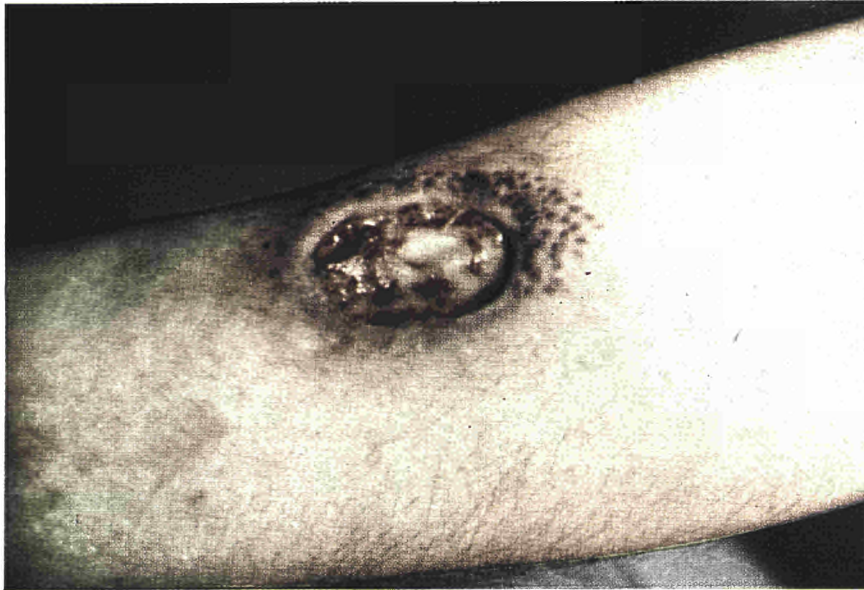Complete healing after 15 injections of padutin.

8.6 Severe late ulcerative radionecrosis (Curietherapy)

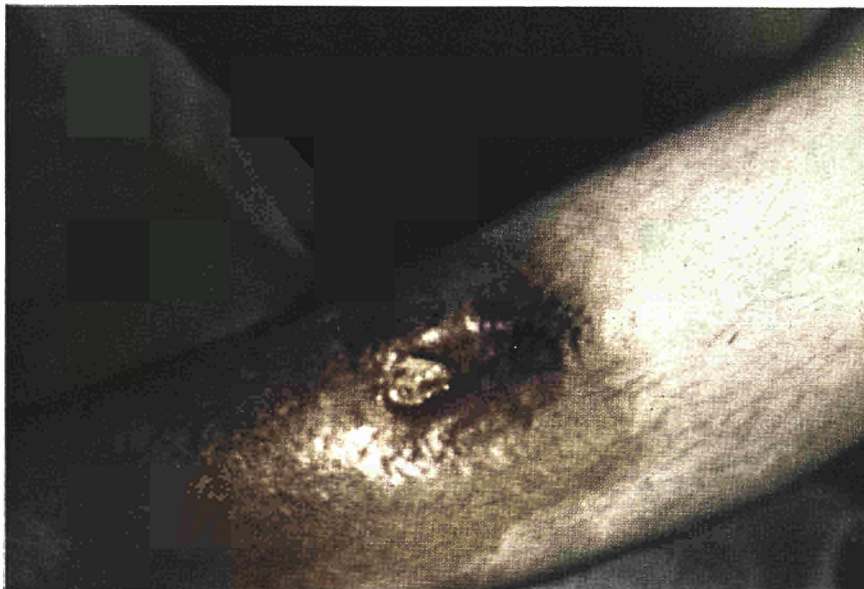
Case report: This radionecrosis, which dates back 37 years, appeared in 1923 as a result of a dosage error during the radium treatment of a pigmentary naevus on the leg.

The patient (F.Y.), who was then aged 7, was irradiated with about 30,000 r. An extremely obstinate radionecrosis set in and all subsequent treatment failed.

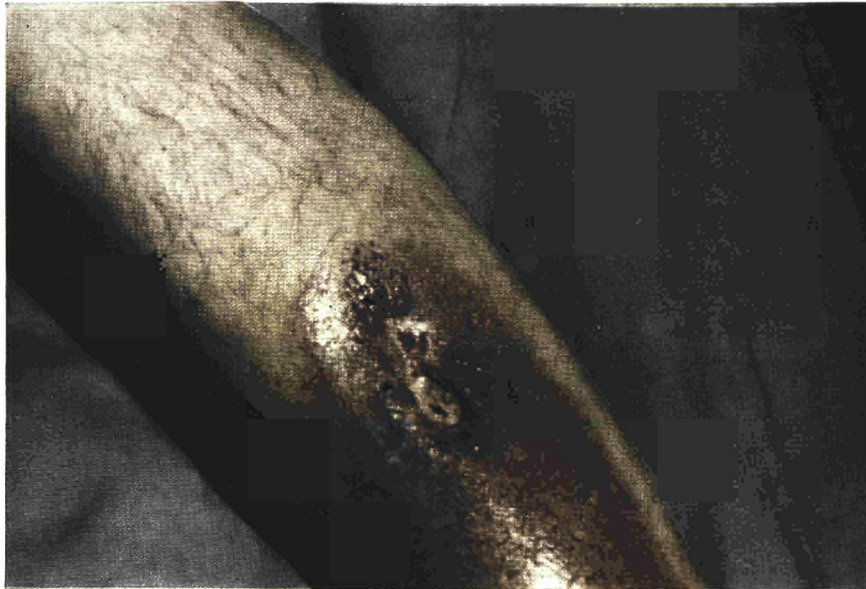
Padutin therapy was started on 1 October 1961. Although the response has been slow, there is now a distinct improvement in the clinical aspect of the wound. Cicatrization started and is still continuing.



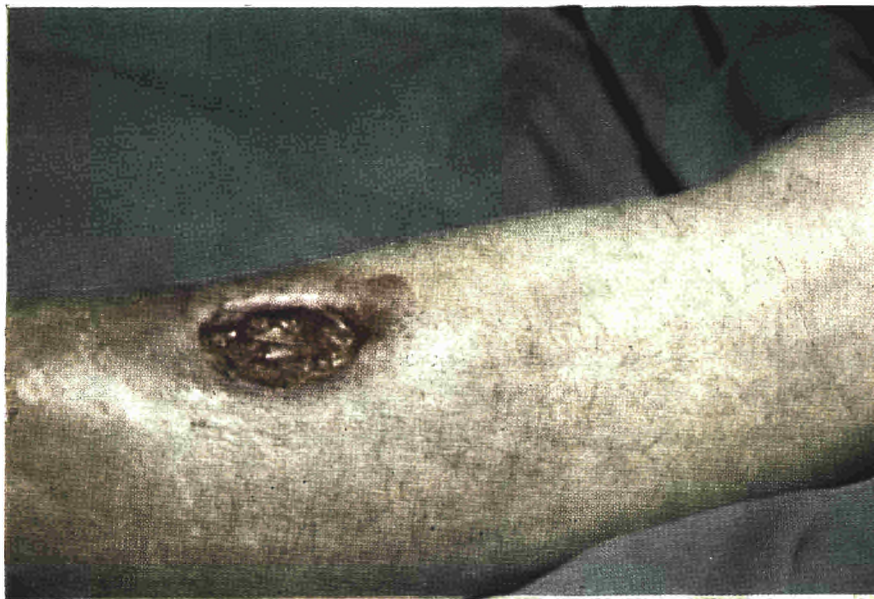State of the wound at the commencement of padutin treatment.
Calcification of an old scar.



Three months after therapy commenced a considerable stimulation was observed
in peripheral circulation at the site of the lesion.



Clinical aspect in the six month of treatment



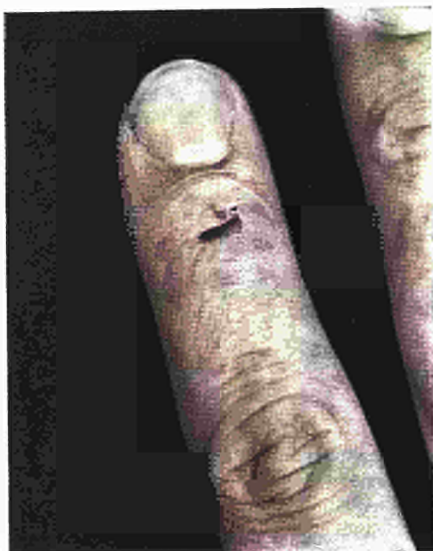
After twelve months treatment the wound has cleared up, the calcareous formation has disappeared, the base shows good irrigation, and cicatrization has begun.

In the course of this review we have seen that even a slight trauma can lead to the stage to which we have referred, viz. radiodermatitis complications. A site that has previously been affected by radiation does in fact lose a great deal of its reactive capacity, as a result of which any wounds in this area become readily subject to an ulcerative condition which is highly refractory to medical treatment.

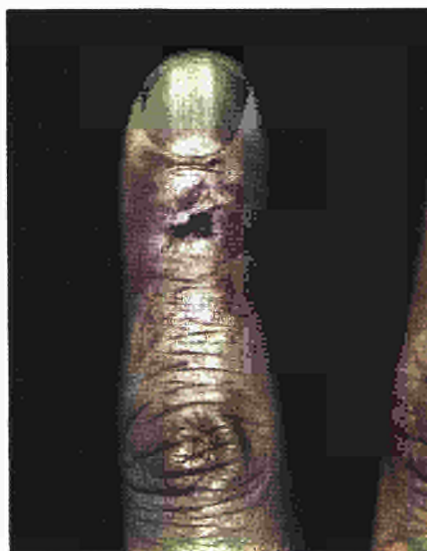
In this connection it is of interest to report a case of trauma occurring after padutin therapy.

A technician (M.J.), the circumstances of whose accident are described under (2), recently—i.e. some two years ago—suffered a mechanical injury on the exact site where the radiation lesion had previously occurred.

Clinical observation revealed an entirely normal cicatrization, showing that the padutin treatment had restored to the radiation-damaged tissues all its regenerative capacity.



Mechanical trauma on the site of the former radiation lesion.



The clinical picture shows normal cicatrization.

Throughout the experiments, we have observed that in addition to vasodilatory and probably trophic action, padutin has a number of *secondary effects* which are of no less importance from the standpoint of treatment.

It is a well-known fact that delayed radiodermatitis may produce extremely severe pain.

Dupont and co-workers [8] have noted histological anomalies of the nervous system at the site of the necrotic tissue. Even so, no certain relationship has been established between these changes and algesia. We have, however, observed on several occasions that padutin has a favourable effect on the pains, which it frequently eliminates altogether, and improves the patients' general condition, making him more able to stand protracted treatment.

Frey and co-workers [8] have also established the beneficial effect of padutin on the vegetative functions. The improved irrigation of the hypophysis and the adrenal glands activates the endocrine functions and boosts the resistance of the organism to bacterial infection, while at the same time cicatrization of the foci is stimulated.

The importance of padutin when used in conjunction with a bacteriostat is shown by the fact that its vasodilatory properties enable it to make patent the pathways to the foci of infection in which the capillary system is seriously impeded.

On several occasions we noted that during radionecrosis, and even radiodermatitis, the radiographic check showed distinct degeneration of the bone tissue.

This was mainly the case with radiation injuries to the extremities, in which the bone system is immediately below the skin, and also with certain curietherapy treatments. The degeneration of the bone system clearly depends on the nature and energy of the radiation and on the surface irradiated.

In the case of injuries to the hands, it is at the moment not possible to put the data available in a perspective which would enable us to state with any degree of certainty whether degeneration is attributable to irradiation or results from the fact that the affected member is immobilized in the course of the treatment.

According to previous works on the effect of padutin on the bone regeneration process, the substance appears to have a favourable effect as regards certain injuries characterized by decalcification and a decrease in mobility of the articulations.

In particular, this has been found in cases of Sudeck osteodystrophy and delayed consolidation i.e. the formation of callus in fractures.

The research was carried out by *Hartenbach* [9], who showed that padutin led to the rapid formation of fracture callus and had a beneficial effect on Sudeck dystrophy.

Continual observation of some of our cases will show whether padutin also has a favourable influence on regeneration of the bone in lesions which appear at the site of this tissue as a result of radiological accidents.

The results of this investigation will be published later.

* * *

The clinical findings which we have reported above in the field of radiodermatitis and radionecrosis testify to the value of padutin in the treatment of radiation injuries, and in our view warrant the provision of substantial funds for more advanced investigations designed to ensure that the new technique will meet with the anticipated success.

We hope in this way to rid the nuclear worker of this "radiation phobia" by offering him, in addition to preventive methods, curative treatment which is both adequate and reassuring. By thus adding to the therapeutic resources of nuclear medicine, we aspire to make our modest contribution to the development of the peaceful use of nuclear energy, which is the paramount aim of our Community.

The present article is the fruit of team-work. We accordingly wish to thank all those who, near or afar, have afforded their assistance, and in particular:

Mlle Suzanne Simon, Professor at the Université Libre, Brussels, Head of the Radiotherapy Department of the Institut Jules Bordet, who very kindly placed her experience at our disposal and supplied us with the photographic material and the technical details concerning therapeutic radionecroses.

Dr. Nehr Korn and Dr. Grabiger, radiologists, of Remscheid, and Dr. Peters, Factory Inspection Physician, of Düsseldorf, to whom we are indebted for the documentary material on bullate radiodermatitis.

Dr. H. Beuchelt, of the Pharmaceutical and Scientific Department of the Bayer-Leverkusen Manufacturing Co, who generously provides all the pharmaceutical samples necessary for our research.

M. Parfait, Head of the Euratom Documentary Research Group, who rendered valuable assistance by undertaking the bibliographical research.

Finally, we would express our gratitude to all those who, in a spirit of international cooperation, placed their skill, help and experience at our disposal.

André MASSART,

*Dr. med. - Medical Adviser to Euratom -
One-time President of the Office Médico-Légal
of the Kingdom of Belgium*

Jean RODESCH,

*Dr. sc. Euratom - Former Head of the Radio-
biological Department of the Institute of Bio-
chemistry at the medical Faculty, University
of Strasbourg*

LITERATURE

- [1] McBRIDE W.W., LIEBEN J. — *Arch. of Environmtl. Hlth.* 1962, **4**, 191.
- [2] MASSART A., HENRY J., RODESCH J. — *Strahlenschutz in Forschung und Praxis*, Rombach and Co., Ed. Freiburg, 1962.
- [3] MASSART A., HENRY J. — *J. Belge de Radiologie*, 1961, **44**, 667.
- [4] FREY E.K., KRAUT H. — *Münch. med. Wschr.*, 1928, **75**, 763.
- [5] FREY E.K., KRAUT H., WERLE E. — *Kallikrein-Padutin*, F. Enke, Ed. Stuttgart, 1950.
- [6] WOLTER A. — *Roentgenpraxis*, 1935, **7**, 473.
- [7] DUPONT A., VAN CANEGHEM P., CIVATTE J. — *Lésions provoquées par les Radiations ionisantes*, Masson and Co., Ed. Paris, 1960.
- [8] FREY E.K., HARTENBACH W., SCHULTZ F. — *Münch. med. Wschr.*, 1953, **95**, 11.
- [9] HARTENBACH W. — *Deutsche med. Wschr.*, 1950, **75**, 751.

CDNA00125ENC