



EPiC Series in Health Sciences

Volume 1, 2017, Pages 363–368

CAOS 2017. 17th Annual Meeting of the International Society for Computer Assisted Orthopaedic Surgery



ACCURACY EVALUATION OF POST-OPERATIVE 3D IMPLANT POSITION BASED ON BI-PLANAR X-RAYS

Matthias Verstraete PhD ^{1,2,*}, Stefaan Van Onsem MD ¹, Jan Victor MD PhD ¹

¹ Department of Orthopaedic Surgery, Ghent University, Gent, Belgium

² FWO Flanders, Brussels, Belgium

* Matthias.Verstraete@UGent.be

INTRODUCTION

Thorough understanding and feedback of the post-operative implant position relative to the pre-operative anatomy is missing in today's clinical practice. However, three dimensional insights in the local under or oversizing of the implant can provide important feedback to the surgeon. For the knee for instance, to identify a shift in the sagittal joint line that potentially links to mid-flexion instability [1] or to identify zones at risk for soft tissue impingement [2].

Despite a proven inferior outcome, clinical post-operative implant evaluation remains primarily based on bi-planar, static 2D x-rays rather than 3D imaging [3]. Along with the cost, a possible reason is the increased radiation dose and/or metal artifact scatter in computed tomography (CT) and/or magnetic resonance imaging (MRI). These detrimental effects are now avoided by using recently released x-ray processing software. This technique uses standard-of-care post-operative x-rays in combination with a pre-operative CT and 3D file of the implant to determine the implant position relative to the pre-operative situation. The accuracy of this new technique is evaluated in this paper using patient cases. Therefore, the obtained implant position is benchmarked against post-operative CT scans.

MATERIALS & METHODS

Retrospectively, 19 patients were selected who underwent total knee arthroplasty and received pre- and post-operative CT of their diseased knee. The CT scans were performed with a pixel size of 0.39 mm and slice spacing of 0.60 mm (Somatom, Siemens, München, Germany). All patients underwent TKA surgery using the same bi-cruciate substituting total knee (Journey II, Smith&Nephew, Memphis, USA). Following surgery, standard bi-planar standing x-rays of the operated knee was additionally performed as standard of care.

To evaluate the implant position relative to the pre-operative situation, the 3D implants are first positioned on the post-operative CT slices. Using Mimics (Materialise NV, Leuven, Belgium), the pre-operative bone was subsequently automatically matched onto the post-operative scan to identify the implant location relative to the reconstructed pre-operative bone. This has been independently repeated by three observers to assess the inter-observer variability.

Second, the post-operative bi-planar x-rays are combined with the reconstructed pre-operative bone and 3D file of the implant. This combination is performed using the 2D-to-3D conversion integrated in the recently launched X-ray module of Mimics. This module uses a contour based registration method to determine the implant and bone position using the post-operative x-rays.

For both reconstruction methods, the implant position has been evaluated in six degrees of freedom using an automated Matlab routine; resulting in three translations and three rotations.

RESULTS

From the evaluated implant positions, the root mean square error was derived between subsequent measurements. For the CT reconstruction based inter-observer evaluation, the median RMS error for all degrees of freedom is below 1 mm and 1 degree for both the femoral and tibial implant (Figure 1).

Comparing the reconstructed CT implant position with the 2D-to-3D reconstruction, the median RMS difference between the implant positions remains below 1 mm and 1 degree except for the distraction/compression component and the internal/external rotation of the component (Figure 2).

DISCUSSION

On average, the RMS difference between the 2D-to-3D conversion and the reconstructed post-operative CT exceeds the inter-observer RMS difference obtained using reconstructed post-operative CT. The differences are in line with previous cadaveric studies using the same reconstruction technique [4]. The largest differences are seen for the femoral and tibial internal/external rotation. However, the obtained values are still within reasonable limits according to a recent review by De Valk et al. [5], who reported an inter-observer variation of 3° for the femur and 2° for the tibia.

In addition, the 2D-to-3D conversion displays a larger difference for the distraction/compression component. Since a true, golden standard measurement is lacking in our tests, it is not clear whether this error is attributed to the CT imaging or the 2D-to-3D conversion. Given the low inter-observer variation for this degree of freedom, it is hypothesized that this discrepancy is linked to the finite slice spacing for the CT scans.

Apart from the obtained accuracy, the use of the 2D-to-3D module has the advantage of significantly reducing the radiation dose with approx. a factor 20 [6]. In addition, the imaging procedure needs no more than the standard imaging required by clinical practice.

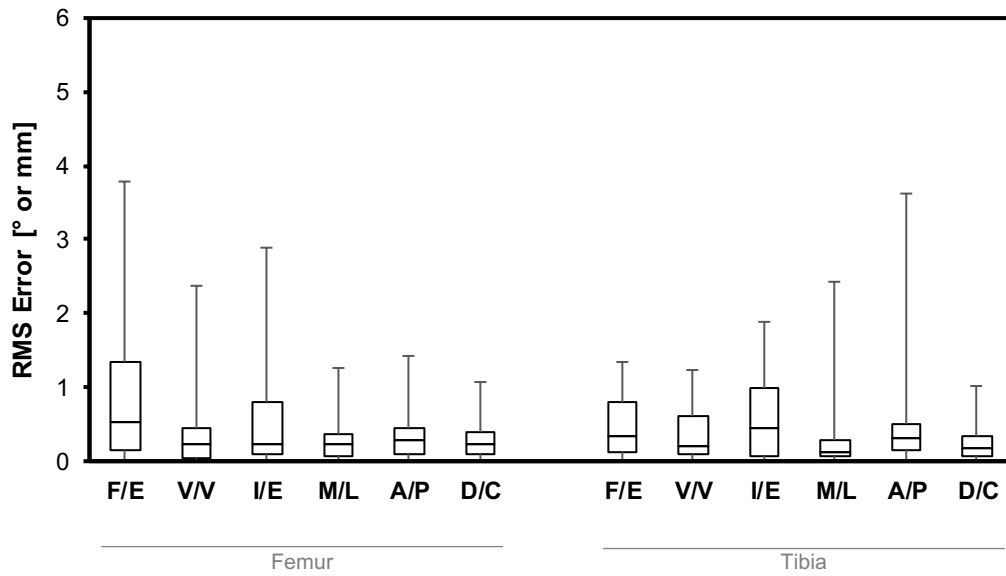


Figure 1 – Difference in femoral and tibial implant position between subsequent observers using post-operative CT data in combination with the 3D stl files of the implants for all degrees of freedom: Flexion / Extension (F/E), Varus/Valgus Rotation (V/V), Internal/External Rotation (I/E), Medial/Lateral Translation (M/L), Anterior/Posterior Translation (A/P) and Distraction/Compression (D/C).

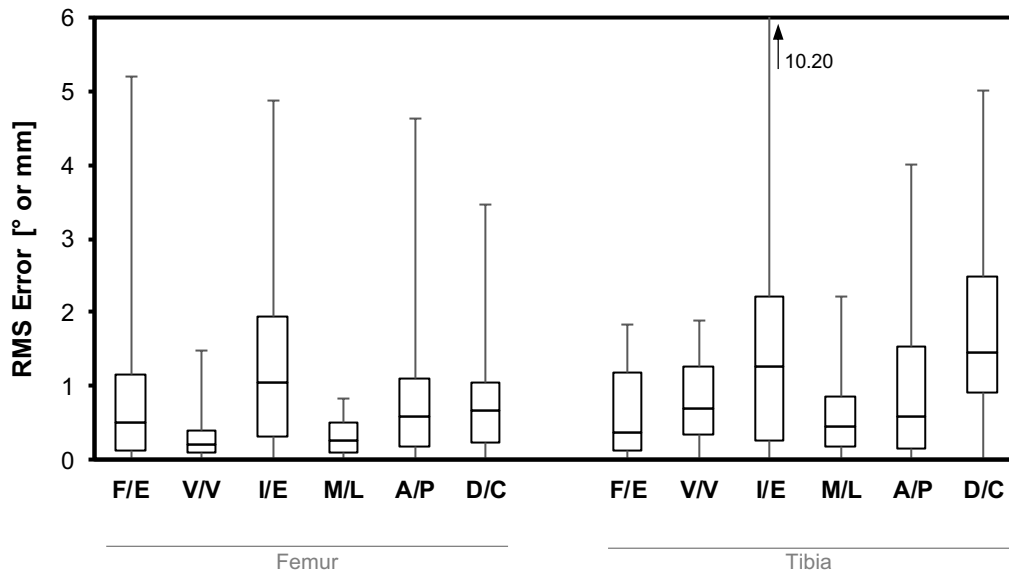


Figure 2 – Difference in femoral and tibial implant position using 2D-to-3D conversion from the Mimics x-ray module versus the implant position obtained using post-operative CT imaging for all degrees of freedom: Flexion / Extension (F/E), Varus/Valgus Rotation (V/V), Internal/External Rotation (I/E), Medial/Lateral Translation (M/L), Anterior/Posterior Translation (A/P) and Distraction/Compression (D/C).

REFERENCES

- [1] Martin J.W., Whiteside L., The influence of joint line position on knee stability after condylar knee arthroplasty, *Clin Orthop Relat Res*, 259, pp. 146-56, 1990.
- [2] Ishida K., Toda A., Shibanuma N. Matsumoto T, Kuroda R., Kurosaka M., Evaluation of implant alignment in navigated unicompartmental knee arthroplasty: a comparison of 2D and 3D imaging, *Acta Orthopaedica Belgica*, 81(4), pp. 654-61, 2015.
- [3] Bonnin M.P., de Kok A., Verstraete M., Van Hoof T., Van Der Straeten C., Saffarini M., Victor J., Popliteus impingement after TKA may occur with well-sized prostheses, *Knee Surg Sports Traumatol Arthrosc*, 2017.

[4] Van Haver A., Kolk S., De Boodt S. Valkering K., Verdonk P., Accuracy of total knee implant position assessment based on postoperative x-rays, registered to pre-operative ct-based 3d models,

Proceedings of International Society for Technology in Arthroplasty (ISTA), Boston, USA, 2016 .

[5] De Valk E.J., Noorduyn J.C.A., Mutsaerts E.L.A.R., How to assess femoral and tibial component rotation after total knee arthroplasty with computed tomography: a systematic review, *Knee Surg Sports Traumatol Arthrosc*, 24, pp. 3517-28, 2016.

[6] Koivisto J., Kiljunen T., Wolff J., Korteniemi M., Assessment of effective radiation dose of an extremity CBCT, MSCT and conventional X ray for knee area using MOSFET dosimeters, *Radiation Protection Dosimetry*, 157(4), pp. 514-24, 2013.

ACKNOWLEDGEMENTS AND DISCLOSURES

The first author acknowledges the financial support of the Research Foundation – Flanders (FWO) through grant number 12N5117N.