

Congenital anomalies of the vertebrae in dogs

Aangeboren afwijkingen van de wervels bij de hond

L. De Rycke, J.H. Saunders

Department of Small Animal Orthopedics and Medical Imaging, Faculty of Veterinary Medicine, Ghent University, Salisburylaan 133, 9820 Merelbeke, Belgium

lieve.derycke@Ugent.be

ABSTRACT

In this review article, an overview is given of the congenital pathologies of vertebrae in the dog. These pathologies are common in dogs and can be divided in two major groups: neural tube defects or spinal dysraphism, such as spina bifida with or without meningocele and dermal sinus tract, and congenital anomalies of the vertebral column. The latter group can be subdivided in malformations originating in the embryonic period of development, such as butterfly vertebra, mediolateral wedged vertebra and transitional vertebra, or in the foetal period, such as block vertebra and dorsoventral wedged vertebra. Congenital vertebral anomalies can be incidental findings on radiographs or CT, but sometimes they can be the underlying cause of a clinical, mostly neurological problem. Due to pressure on the spinal cord, symptoms, such as pelvic limb ataxia, paresis, loss of spinal reflexes, incontinence and atrophy of the pelvic limbs may occur.

SAMENVATTING

In dit artikel wordt een overzicht gegeven van aangeboren afwijkingen van de wervels bij honden. Vertebrale anomalieën komen geregeld voor bij deze dieren en kunnen onderverdeeld worden in twee grote groepen, namelijk spinaal dysrafisme zoals spina bifida met of zonder meningocele en dermale sinus, en anomalieën van de vertebrale kolom. Deze laatste groep kan worden opgesplitst in malformaties die hun ontstaan vinden in de embryonale ontwikkelingsperiode, zoals vlinderwervels, medio-laterale wigwervels en transitionele wervels, of in de foetale periode, zoals blokwervels en dorsoventrale wigwervels. Aangeboren anomalieën van de wervels kunnen toevallsbevindingen zijn op RX of CT, maar soms zijn ze de onderliggende oorzaak van klinische, meestal neurologische problemen. Door druk op het ruggenmerg kunnen symptomen zoals ataxie van de achterste ledematen, parese, verlies van spinale reflexen, kyfose, lordose, scoliose, incontinentie en atrofie van de spieren van de achterste ledematen optreden.

CLASSIFICATION

Spinal dysraphism

Spinal dysraphism is a broad term given to a group of anomalies with malformations in the dorsum of the embryo, including neural tube defects (NTD). NTD occur secondary to abnormal closure of the developing neural tube and result in a defective neural arch through which meninges or neural elements may herniate (Figure 1). Spinal dysraphism are categorized clinically into open and closed, based on whether the abnormal nervous tissue is exposed to the environment or covered by skin (Rossi et al., 2006, Song et al., 2016).

Open spinal dysraphism or spina bifida aperta includes meningoceles and myelomeningocele, whereby the spinal cord fails to fuse dorsally, and is open to the environment because it is not covered by skin. These severe dysraphisms in animal neonates usually result in death or early termination. Such entities have rarely been reported in dogs (Chesney, 1973; Clayton and Boyd, 1983).

Closed spinal dysraphism (CSD), also known as spina bifida occulta (SBO), includes various malformations of the spine that are covered by skin. The simplest form of CSD is dorsal spina bifida and is usually clinically insignificant, with no or minor neural anomalies (Figure 2). Occasionally, a subcutaneous mass may be present in SBO, which consists of a

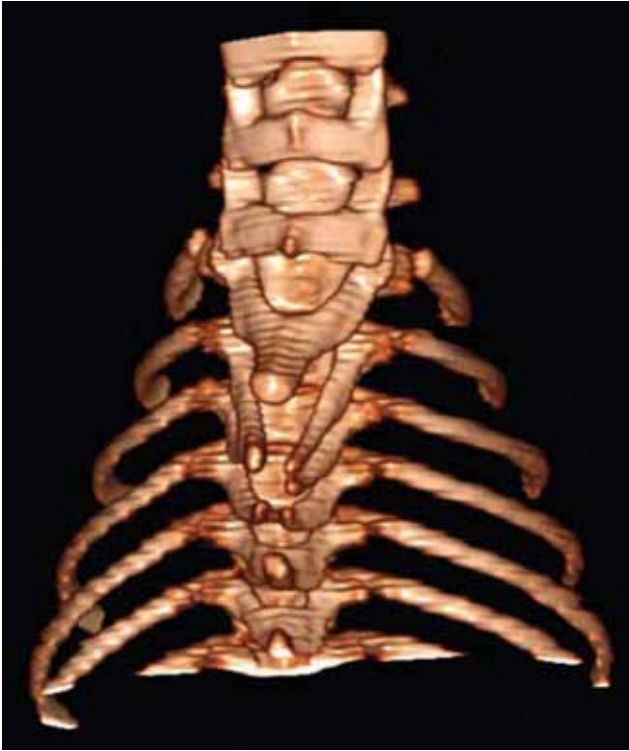

Figure 1. A three-dimensional computed tomography image of the cranial thoracic spine demonstrating a spina bifida and dorsal spinous process malformations at T2 to T4 in a Chinese crested dog with a dermoid sinus (Kiviranta, 2011).

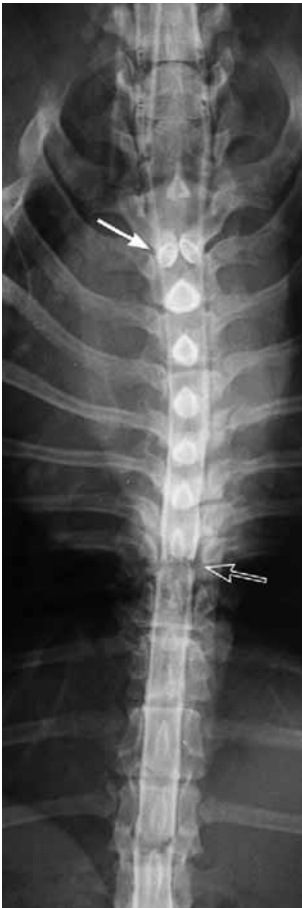

Figure 2. Ventrodorsal projection radiograph of the thoracic vertebral column. Dorsal spina bifida can be seen in this dog that presented with signs of a T3 to L3 myelopathy. Note the two spinous processes seen at T2 (solid white arrow). The restrictive band of fibrous tissue seen at T8 to T9 was the source of the clinical signs in this case (arrow) (Westworth, 2010).

meningocele (Parker et al., 1973; Wilson et al., 1979; Gómez et al., 2012; Song et al., 2014). Another form of SBO are dermal sinus tracts (Miller and Tobias, 2003, Kiviranta et al., 2011; Song et al., 2016).

SBO with meningocele (MC), meningomyelocele (MMC)

Moderate to severe forms of NTD, such as SBO with MMC or MC, are typically diagnosed in young animals. Although a congenital anomaly may be seen in any breed, certain breeds have been overrepresented with spina bifida occulta such as the English bulldogs (Parker and Byerly, 1973; Parker et al., 1973; Wilson et al., 1979; Fingeroth et al., 1989, Brunetti et al., 1993; Ployart et al., 2013) and the German shepherd dogs (Clayton, 1983; Song et al., 2014). A meningocele has also been described in a Collie (Wilson et al., 1979) (Figure 3). Bulldogs have been reported with L7 or sacral dorsal vertebral arch defects and subcutaneous meningoceles (Parker et al., 1973; Brunetti et al., 1993) midline caudal hair streaming, (Wilson et al., 1979) and apparent caudal tethering of the filum terminale by a fibrous cord (Fingeroth et al., 1989; Shamir et al., 2001). Although reports of attempted surgical repair are rare, three reports of bulldogs that had surgery included a dorsal surgical approach to the caudal spine, opening of the dura, and transection of a fibrous filum terminale, resulting in release of the caudal tether (Fingeroth et al., 1989; Shamir et al., 2001, Song et al., 2014). One dog was euthanized two weeks after surgery, although some sensory improvement was evident (Fingeroth et al., 1989). The second bulldog showed a decreased incidence of urinary incontinence. Physical and neurologic examinations were otherwise unchanged from prior to surgery. Four months postoperatively, only rare incidences of urine dribbling, a tail that was no longer deviated, and no evidence of pain or discomfort at the previous surgical site was seen (Song et al., 2014). In the third report, the dog's gait and hindlimb strength improved gradually over the following four months, by which time they appeared to be normal. Urinary dribbling and fecal incontinence persisted accompanied by hypoalgesia of the perineal area and tail (Shamir et al., 2001).

SBO with dermal sinus tracts

Dermal sinus tracts are a well-recognized form of SBO (Miller and Tobias, 2003). Dermal sinus tracts are tubular sacs extending ventrally from the dorsal midline of the skin into the underlying tissues, occurring most commonly in the cervical, cranial thoracic, and lumbosacral regions (Miller and Tobias, 2003). The most common breed affected is the Rhodesian ridgeback (Salmon et al., 2007; Hillbertz, 2005; Hillbertz and Andersson, 2006). Other reported breeds include the shih tzu, the boxer, the Siberian husky

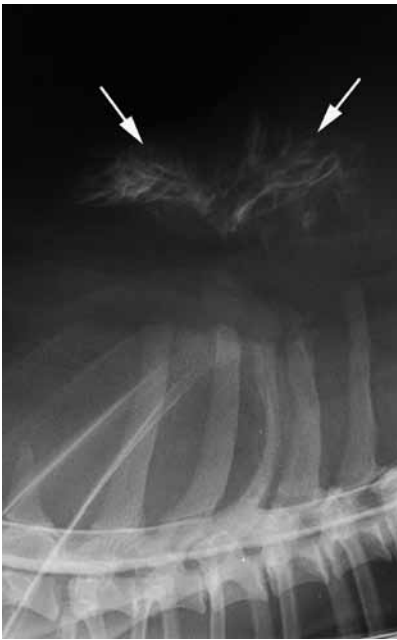

Figure 3. Lateral projection radiograph of the thoracic vertebral column post myelogram in a four-year-old Shetland sheepdog that was presented for acute paraplegia. A dorsal meningocele can be seen with subcutaneously arborizing tracts (white arrows) and a lipomatous mass was present at surgery extending through a laminal defect associated with T3 dorsal spina bifida (Westworth, 2010).

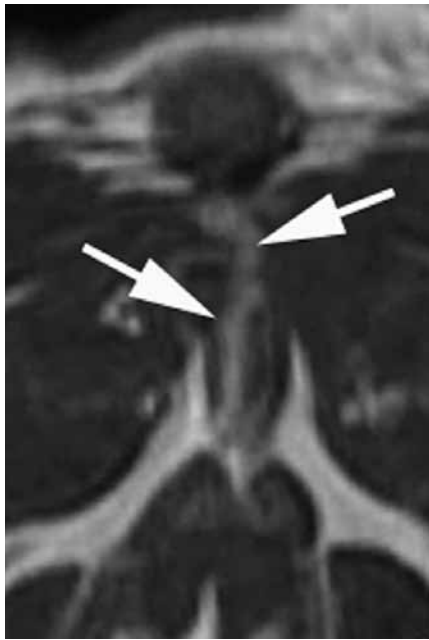

Figure 4. A cervical transverse T2-weighted MRI of a type IV dermal sinus tract is shown. Note the serpentine appearance of the tract as it courses ventrally (arrows) through a laminal defect to the dura mater (MRI courtesy of Dr. Jim Lavelly).

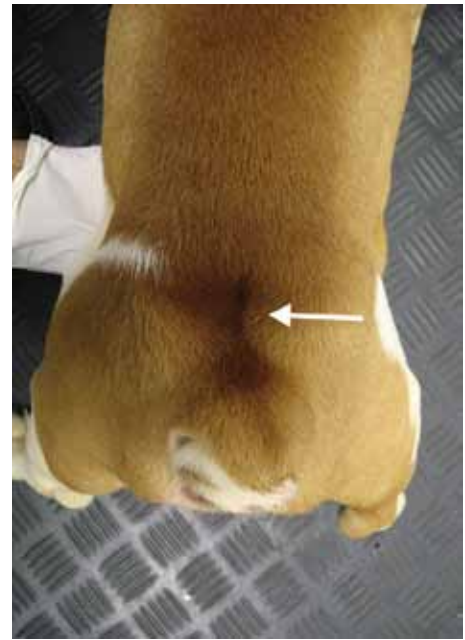


Figure 5. A dorsal view of the hind end of a six-month-old English bulldog that was presented for urinary and fecal incontinence. The hair on the dorsal midline has an abnormal appearance (arrow). At that site, there is a palpable indentation of the epaxial muscles. Radiographically, spina bifida was present. Given the neurologic deficits, meningo-myelocoele was presumed (Song, 2016).

(Conegliani and Ghibaudo, 1999), the chow chow (Booth, 1998), the American cocker spaniel, the Yorkshire terrier (Fatone et al., 1995), the English springer spaniel (Pratt et al., 2000), the great Pyrenees dog (Camacho et al., 1995), the wire fox terrier, the English springer spaniel (Pratt et al., 2000), the rottweiler (Bornard et al., 2007), the golden retriever (Conegliani et al., 2001; Miller and Tobias, 2003), the Chinese crested dog and the Swedish vallhund (Kiviranta et al., 2011) and the boerboel (Penrith et al., 1994). In Rhodesian ridgebacks, the sinus tract is especially found in the cervical region where it often extends to the spinous process of C2. In other breeds, the most common location is the cranial or mid-thoracic region. Four (Mann and Stratton, 1966) or five types (Miller and Tobias, 2003) have been proposed depending on the depth to which the tract extends (Figure 4). Only type IV extends to the vertebral canal and attaches to the dura mater (Figure 3). On the surface of the skin, the sinus tract may appear grossly as a small (1–5 mm) indentation/invasion. At the top of the tract, the hair on the dorsal midline may have an abnormal appearance (Figure 5). On palpation, it may feel like a subcutaneous cord or band of fibrous tissue. Histo-

logically, it is lined with squamous epithelium and adenexal structures, and is often filled with epithelial debris, sebum and hair, and/or inflammatory cells and bacteria. When inflamed or infected, it will enlarge and become painful (Marks et al., 1993, Scott et al., 2001; Miller and Tobias, 2003). With type IV dermal sinuses, neural structures may become infected or inflamed causing spinal pain and/or myelopathy due to spinal cord compression, empyema/abscess, and/or osteomyelitis (Selcer et al., 1984; Fatone et al., 1995; Pratt et al., 2000; Conegliani et al., 2001). In dogs with ridges, type IV cysts more often occur in the sacro-coccygeal region (Miller and Tobias, 2003).

Clinical diagnosis can be made by palpation, or clipping of the hair and visual inspection. Dermal sinus tracts may also be seen with other anomalies of the spine (Fatone et al., 1995).

When vertebral canal involvement is suspected, definitive diagnosis and characterization of spinal dysraphism are made with cross-sectional imaging, primarily magnetic resonance imaging (MR) (Figure 6). MR is especially advised prior to surgical exploration to provide adequate presurgical planning and limit the risk of inadvertent damage to the spinal cord.

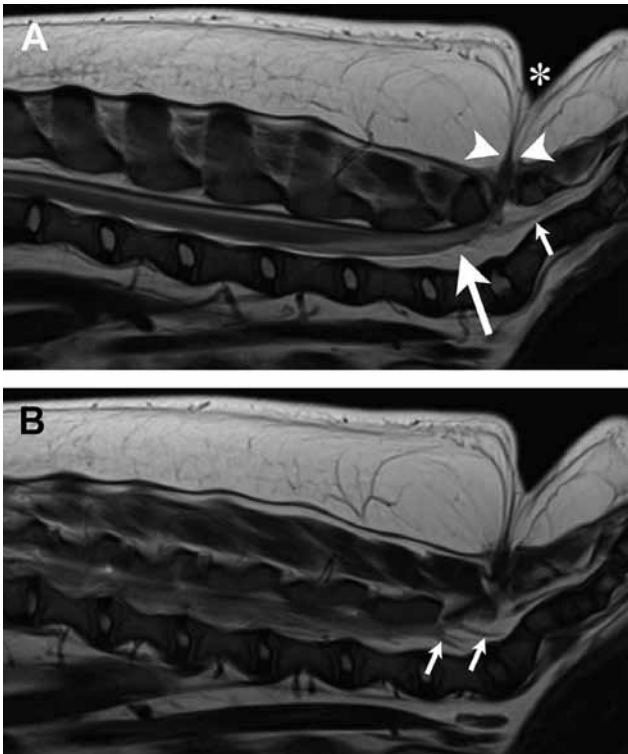


Figure 6A. A T2-weighted midline sagittal image of the lumbosacral vertebral column from the dog in Figure 4. The ‘dimple’ or indentation of the skin is visible (asterisk). There is meninges, which exit the vertebral column dorsally between the L7 and sacral laminae and connect to the skin (between the arrowheads). Notice the dorsal deviation of the spinal dura mater filaments (large arrow). **B.** In a sagittal image just lateral to midline, the nerve roots are visible coursing toward their foramina (arrows) (Song, 2016).

In recent reports however, MR did not clearly indicate the full extent of the tract (Rahal et al., 2008) and was misleading in another case of a single dermoid cyst without a tract (Davies et al., 2004). Other imaging modalities may also provide some diagnostic information. Apparent anomalous changes to the vertebrae on radiographs include bifid spinous processes of one or more vertebrae or an absent spinous process(es) or osteomyelitis. Myelogram and/or computed tomography (CT) may provide similar information in cases demonstrating a myelopathy. Fistulography is contraindicated because infection or dermal elements may be introduced into deeper tissues. Surgical excision without disruption of the sinus is the treatment of choice in clinically affected cases (Miller and Tobias, 2003; Kiviranta et al., 2011). Good visualization through appropriate exposure, knowledge of regional anatomy and experience handling neural tissues are needed when surgically excising dermal sinuses involving the meninges and/or spinal cord. Deep culture should be taken and broad-spectrum antibiotics used if there is apparent infection or contamination of surrounding structures.

Congenital anomalies of the vertebral column

Congenital anomalies of the vertebral column, such as transitional vertebrae, butterfly vertebrae, hemivertebrae and block vertebrae, are common in the dog and are often incidental findings with no clinical significance (Morgan, 1968; Done et al., 1975; Newitt et al., 2008; Westworth and Sturges, 2010; Moissonnier et al., 2011). Sometimes, due to pressure on the spinal cord, symptoms, such as pelvic limb ataxia, paresis, loss of spinal reflexes incontinence, atrophy of the pelvic muscles and atomy of the pelvic limbs may occur (Done et al., 1975, Bailey and Morgan, 1992; Aikawa et al., 2007; Jeffery et al., 2007, Westworth and Sturges, 2010; Moissonnier et al. 2011; Aikawa et al., 2014). Any breed can be affected; however, the brachycephalic ‘screw-tailed’ breeds, such as the English bulldog, French bulldog, Boston terrier and pug are overrepresented (Morgan, 1968; Done et al.,

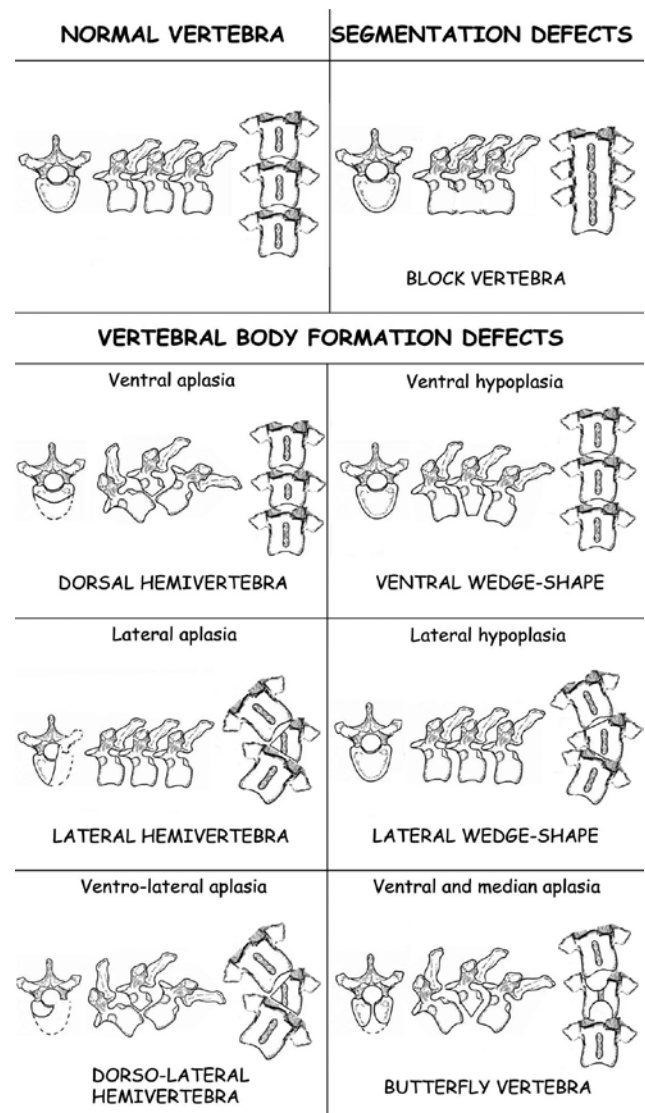


Figure 7. Schematic line drawing showing the radiographic appearance of the vertebral malformation classification system according to Guitierrez et al. (2014).

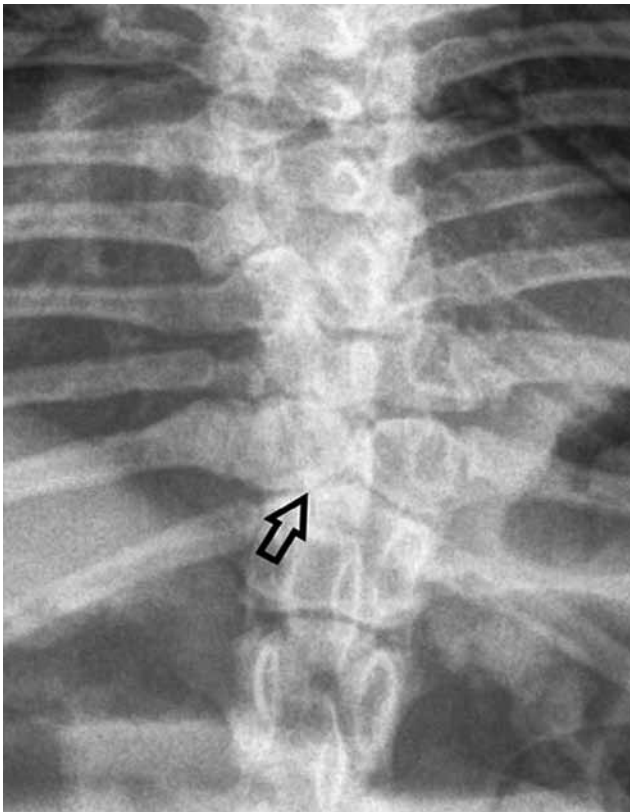


Figure 8. Congenital vertebral malformation identified on a ventrodorsal radiograph of the thoracic vertebral column. Ventral and median aplasia of the vertebral body or butterfly vertebra (arrow) (Gutierrez, 2014).

1975; Bailey and Morgan, 1992; Westworth and Sturges 2010; Moissionnier et al., 2011; Schlensker and Distl, 2013). These congenital vertebral malformations may occur in isolation or be multiple in an individual dog.

The diagnosis of many simple vertebral deformities can be readily made with screening survey vertebral column radiographs in orthogonal projections. However, CT or MR is needed to identify the degree and level of spinal cord involvement (Westworth and Sturges, 2010). The use of CT, particularly with three-dimensional reconstruction, may more clearly identify the degree of bone malformation in complex or multiple malformations, and has been recently proposed as the method of classification of these lesions in humans (Kawakami et al., 2009). Presurgical planning with advanced imaging is always advised.

Gutierrez et al. (2014) classified the congenital vertebral malformations into categories on the basis of their radiographic appearance (Figure 7). The first classification category includes failure of vertebral segmentation, in which portions of adjacent vertebral elements fail to divide (block vertebra or bars). The second category consists of failure of vertebral formation, in which a portion of a vertebral element is deficient (hemivertebra, wedge shape vertebra or butterfly vertebra).

Westworth et al. (2010) classified congenital vertebral malformations according to the period of ex-

istence, namely, embryonic (butterfly vertebra, true hemivertebra, mediolateral wedge vertebra, transitional vertebra) or foetal (block vertebra, dorsoventral hemi-/wedge vertebra, congenital stenosis, hypoplasia of the articular process) (Table 1).

Malformations originating in the embryonic period of development

Vertebral column anomalies originating in the embryonic period are caused by defects in formation, and may be associated with NTD. Segmentation de-

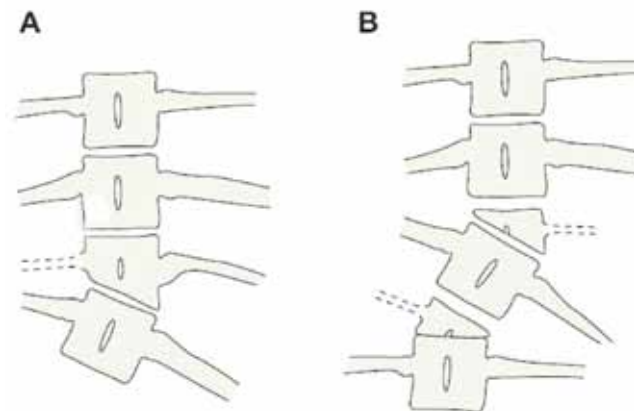


Figure 9. Vertebral malformations resulting in predominantly scoliotic angulation deformities. A. Wedge-shaped vertebra. B. Hemivertebra unsegmented (above) and contralateral partially segmented hemivertebra (below). Note that hemivertebra, unlike the wedge vertebra, have an incomplete neural arch. Segmentation may occur partially as shown here or fully (cranially and caudally) (Westworth, 2010).

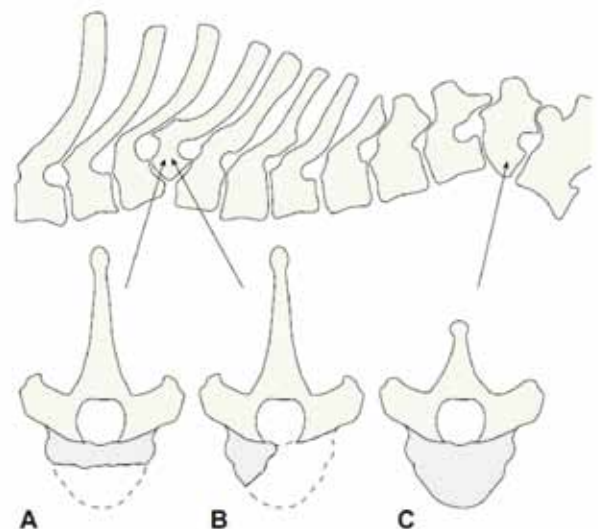


Figure 10. Vertebral malformations resulting in kyphotic or kyphoscoliotic angulation deformities due to centrum defects. Complex centrum defects may be seen where much of the ventral centrum is missing and severe angulation deformities result A., or B. ventrolateral centrum defect results in kyphoscoliosis. C. A wedge vertebra (ventrodorsal) with the apex ventral (Westworth, 2010).

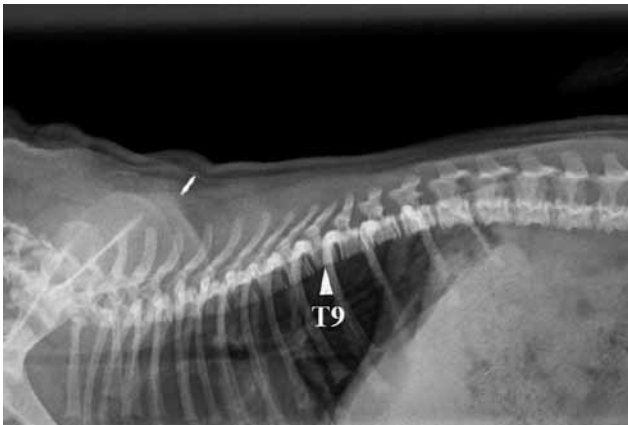


Figure 11. Right lateral thoracic radiograph of a pug showing no abnormalities of the thoracic vertebrae at the age of two months. The size of T9 is slightly smaller than the adjacent vertebrae (De Rycke, 2016).

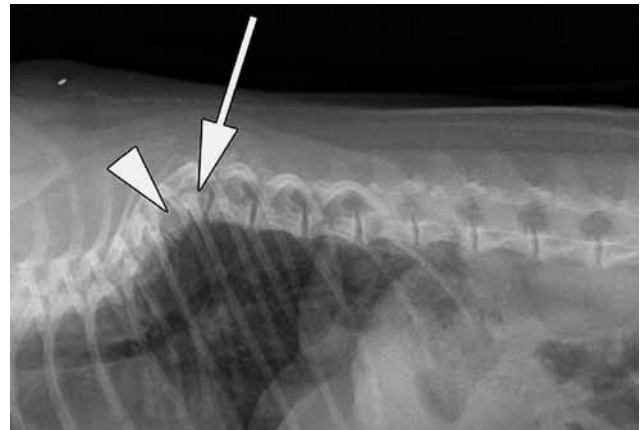


Figure 12. Right lateral thoracic radiograph of the pug at six months of age showing marked kyphosis of the thoracic vertebral column, centred on T9. The vertebral body of T9 is notably short in the craniocaudal plane, wedge-shaped, displaced dorsally and outlined by the white arrow. The arrowhead indicates the T8 vertebral body, which is also shortened and wedge-shaped (De Rycke et al., 2016).

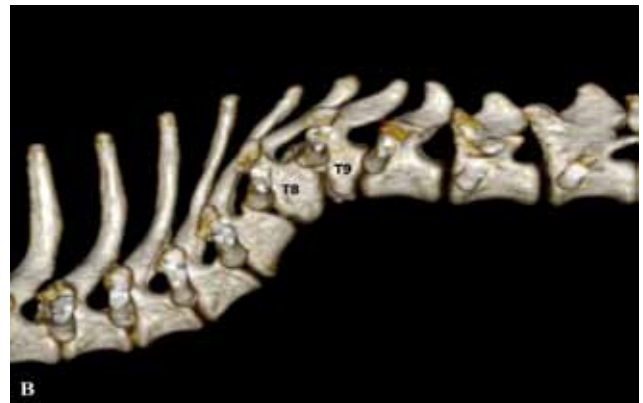
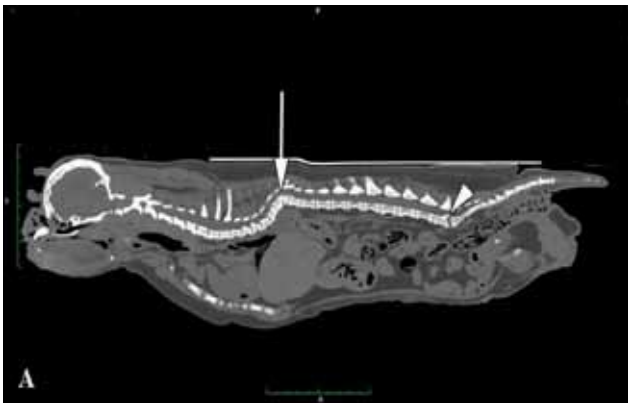
Figure 13. A. Sagittal reformatted whole-body CT of the pug at six months of age. Severe kyphosis of the thoracic vertebral column is present. The white arrow indicates T8 and T9, which are wedge-shaped and dorsally displaced. B. Three-dimensional CT image of the thoracic spine at the height of T8 and T9 (De Rycke et al., 2016)

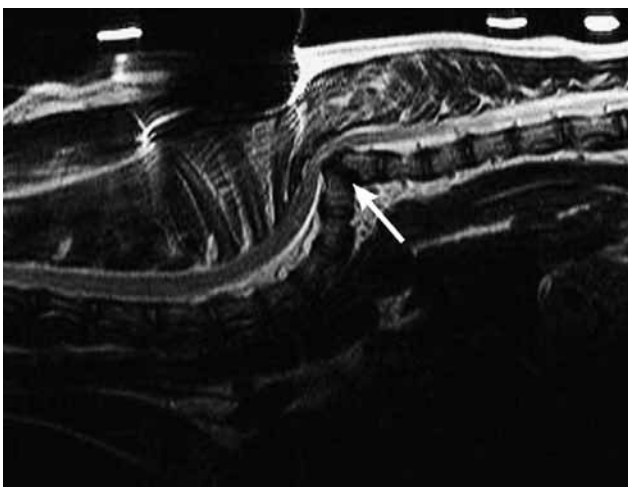


Figure 14. Sagittal T2-weighted MR of the thoracic region of a French bulldog. Note the severe kyphotic deformity and ventral compression of the spinal cord (arrow). T5 and T7 are wedge-shaped and T6 has a severe centrum defect (Westworth, 2010).

fects may occur secondarily. Those that involve only the vertebrae include butterfly vertebra and various forms of true or classic hemivertebra (Westworth and Sturges, 2010).

Butterfly vertebra

The term butterfly vertebra comes from the appearance of a sagittal cleft in the vertebral body on viewing a ventrodorsal radiographic projection (Figure 8). There is partial or complete failure of formation of the ventral and central portions of the vertebral body, leaving two dorsolateral fragments of bone attached to the neural arch (Westworth and Sturges, 2010). If the vertebral body is very diminutive, it may result in kyphotic angulation, especially if associated with centrum hypoplasia. This anomaly is most often seen in brachycephalic, screw-tailed breeds and is often not clinically significant (Morgan, 1968; Gutierrez et al., 2014).

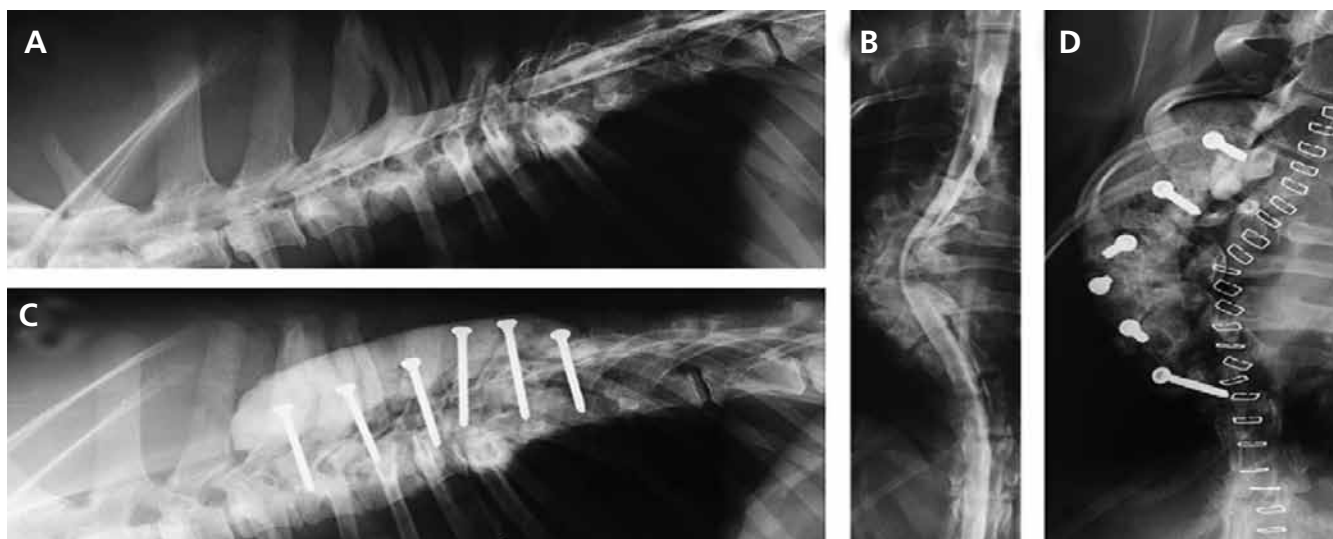


Figure 15. Radiographic study of a seven-month-old shepherd cross with progressive paraparesis. At the time of presentation, she was nonambulatory. **A.** Lateral projection myelogram showing multiple vertebral anomalies in the cranial and mid-thoracic spine. Note the meningocele at T4. **B.** Ventrodorsal projection myelogram showing marked scoliosis secondary to complex vertebral anomalies. **C and D.** Lateral ventrodorsal projection postoperative radiographs. Surgical decompression from T4 to T10 with stabilization using screws and bone cement was performed. The puppy was ambulatory again two weeks later (Westworth, 2010).

Hemivertebra (with or without segmental defects) / lateral wedge vertebra

Classic hemivertebra results from a failure to form one sagittal half of the vertebra, including the centrum and neural arch (Tsou et al., 1980; Hedequist and Emans, 2007) (Figure 9). Although the cause is unknown, it is most likely due to the congenital absence of vascularization unilaterally (Tsou et al., 1980), resulting in predominantly scoliotic angulation deformities. An incomplete failure of formation leads to a laterally wedged vertebra with a variable degree of unilateral hypoplasia; however, there are bilateral pedicles completing the vertebral arch (Tsou et

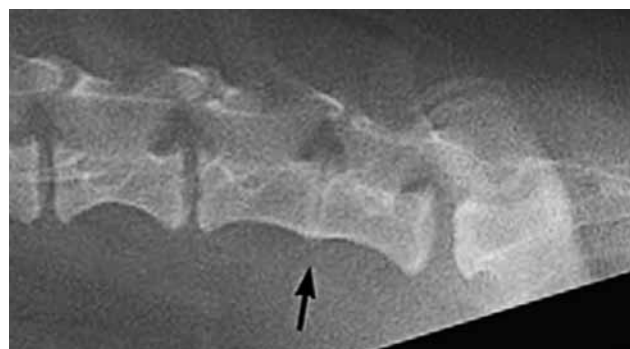

Figure 16. Lateral projection radiograph of the lumbar spine with a block vertebra. Note the partially fused L6 to L7 vertebrae (arrow) (Westworth, 2010).

Table 1. Classification of common congenital vertebral anomalies in dogs and cats (Tsou P.M., Yau A., Hodgson A.R., 1980).

<p>Embryonic period</p> <ul style="list-style-type: none"> Diastematomyelia and centrum median cleft Centrum median cleft only (butterfly vertebrae) True hemivertebrae with or without segmentation deformity Wedge vertebra (mediolateral wedged vertebrae) with or without segmentation deformity Transitional vertebra (embryonic or fetal period depending on anomaly)
<p>Fetal period</p> <ul style="list-style-type: none"> Failure of segmentation and or late formation Block vertebrae (partial or complete) Hypoplasia of articular processes Costovertebral joint failure of segmentation Centrum hypoplasia or aplasia (dorsoventral wedged vertebrae) <p>Complex anomalies are those not readily classifiable or unclassifiable, and may involve any multiple defects of formation and segmentation.</p>

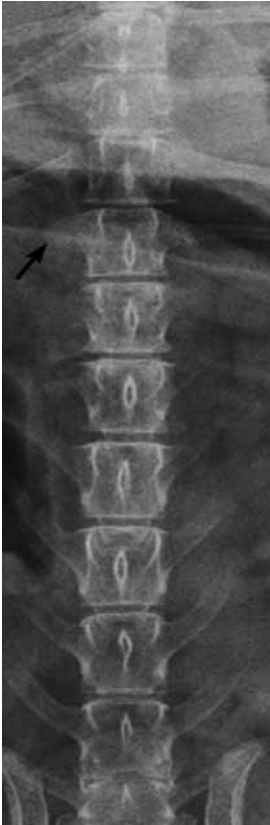

Figure 17. Ventrodorsal projection radiograph of the thoracolumbar vertebral column with a transitional vertebra. Note the missing costa and small perpendicular deformed transverse process on the right side of T13 (arrow) (Westworth, 2010).

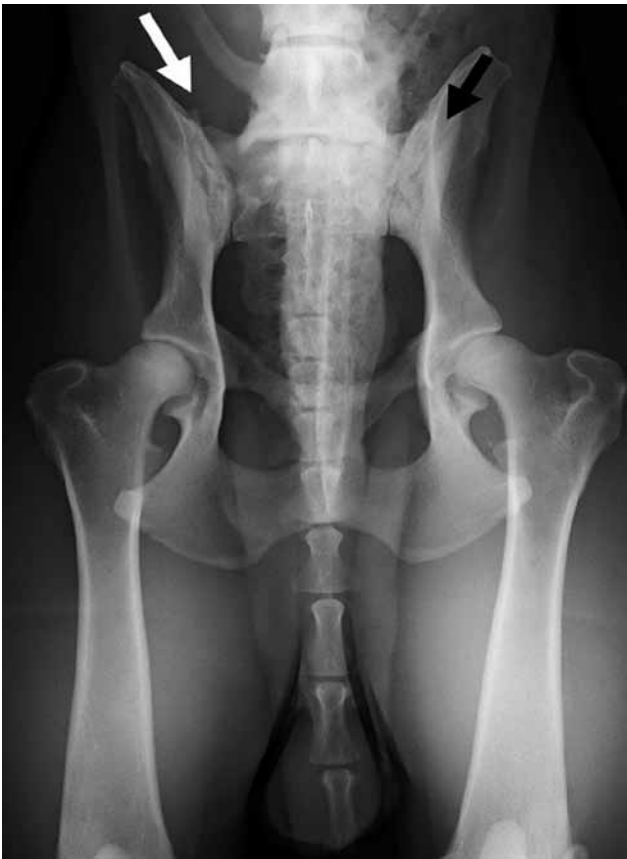

Figure 18. Ventrodorsal radiograph of a German shepherd dog with lumbosacral transitional vertebra of type 2 on the right side (white arrow) and type 3 on the left side (black arrow). On the right side, the tip of the transverse process is visible; on the left side it is not (Lappalainen, 2012).

al., 1980; Hedequist and Emans, 2007) (Figure 9A). Further classification of these anomalies is based on the degree of segmentation failure during the fetal period, resulting in the presence or absence of fusion to vertebral bodies cranially or caudally (Westworth and Sturges, 2010) (Figure 9B).

Defects of segmentation result in a concave angulation on the side of the lateral block with restricted growth, due to loss of growth plates on the affected side (Hedequist and Emans, 2007). Single or multiple ipsilateral anomalies may result in severe lateral angulation and hence in scoliosis. A hemi-metameric shift occurs if the angulation is counterbalanced with a contralateral hemivertebrae, with the resulting degree of scoliosis being less pronounced (Tsou et al., 1980). Mixed malformations may result in complex and not readily classifiable anomalies.

Malformations originating in the fetal period of development

Vertebral column anomalies originating in the fetal period are associated with defects in formation and particularly segmentation. Such deformities are well-differentiated and occur late in the chondrification and ossification stages, and are much less commonly associated with other defects and spinal cord anomalies because they occur after the formation of those structures (Tsou et al., 1980). Anomalies originating in this period of development include dorsoventral wedged vertebrae (centrum hypoplasia or aplasia), blockvertebrae, articular facet aplasia/dysplasia, transitional vertebrae and spinal stenosis (Tsou et al., 1980).

Vertebral anomalies of the centrum/ventral hemi- or wedge vertebra

Vertebral anomalies of the centrum result in predominantly kyphotic angulation deformities caused by diminished vertebral body longitudinal growth. These anomalies affect the vertebral body only (unless a mixed deformity), with normal or near normal neural arch development (McMaster and Singh, 1999), and are caused by a defect in formation or segmentation (Tsou et al., 1980).

Centrum hypoplasia or aplasia results in variable loss of the body, and bilateral or unilateral defects may occur (Figure 10). Unilateral centrum defects may result in a degree of scoliosis (kyphoscoliosis) (Westworth and Sturges, 2010) (Figure 10 B). The cause is unknown but severe forms may be due to congenital absence of vascularization or may be caused by any teratogenic insult to the very active cartilaginous proliferation in the ventral rim (Westworth and Sturges 2010; Moissionnier et al., 2011; Schlensker and Distl, 2013). The term hemivertebra is inappropriate for such malformations (Tsou, 1977). The resulting degree of kyphosis is related to the number of vertebrae

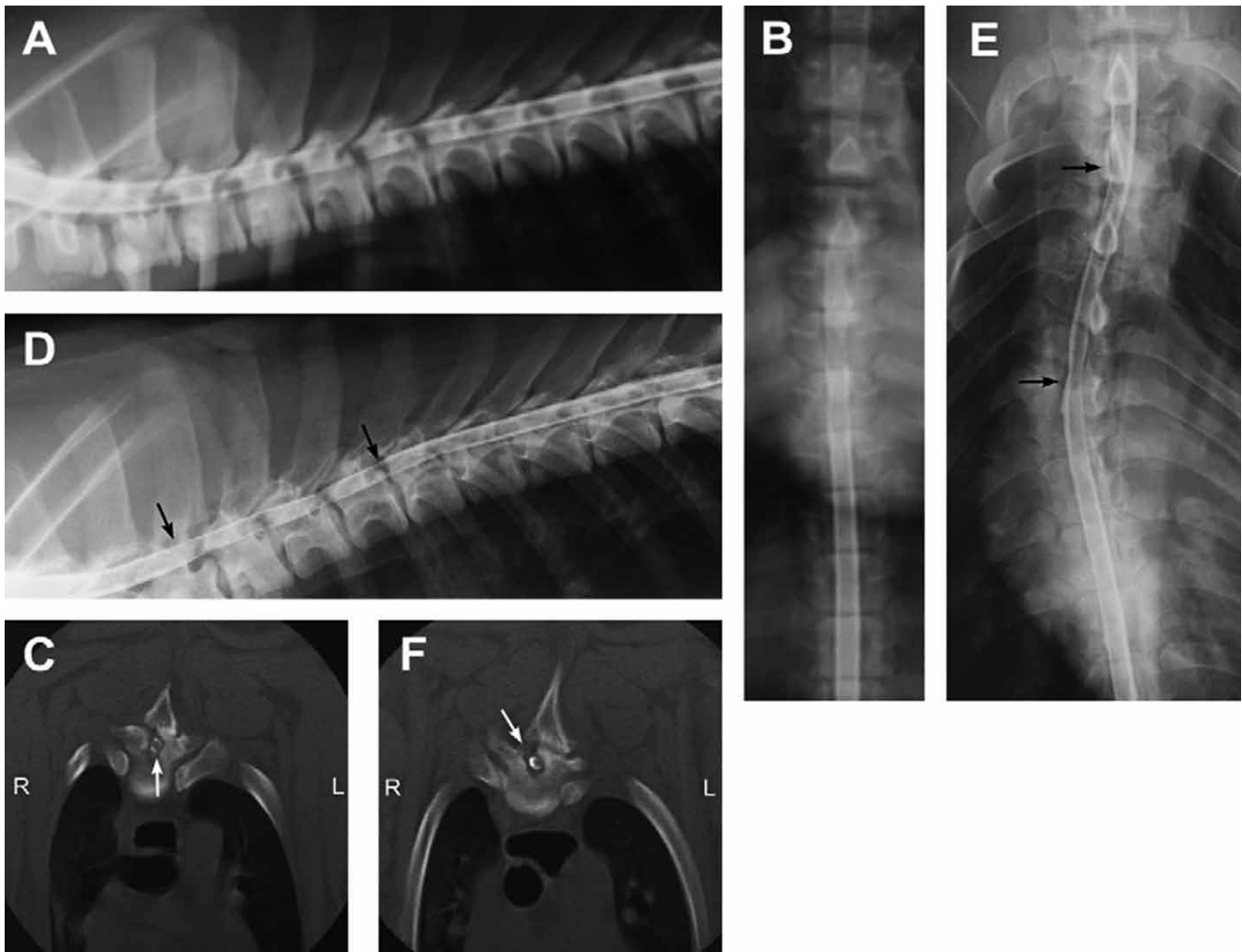


Figure 19. Myelogram images from a Doberman Rottweiler cross puppy with a progressive T3-L3 myelopathy. **A and B.** Lateral and ventrodorsal radiographs obtained at six months of age when the puppy first presented for nonambulatory paraparesis. A segmental stenosis can be seen from T2 to T5. **C.** Axial CT image at the level to T3. Note the profound osseous thickening of the vertebral arch compressing the spinal cord (arrow). Decompressive surgery was performed over the length of this region via hemidorsal laminectomy on the right side, and the puppy became ambulatory shortly thereafter. **D.** Four months later, the puppy again developed progressive paraparesis and diagnostic CT myelography was repeated. On this lateral radiograph, the stenosis is again evident over the same region (arrows), only more pronounced this time. **E.** Ventrodorsal images showed that scoliosis was occurring as well, possibly secondary to the ‘destabilizing’ effects of previous surgical procedure. **F.** Regrowth of bone over previous laminectomy site and ongoing stenosis on the unoperated side can be seen. A second decompressive surgery was done once the dog reached skeletal maturity, and the dog regained the ability to walk. Ten years later, the dog remained ambulatory without clinical reoccurrence of stenosis (Westworth, 2010).

affected and the severity of the centrum defect. The least deforming is the dorsoventral wedge (Westworth and Sturges, 2010) (Figure 10 C). Other forms have a greater propensity for instability, stenosis, and kyphosis with or without scoliosis as evident by their inherent ventral defect (Figures 10 A and B). Dorsal displacement of a severely affected vertebra (centrum aplasia or severe hypoplasia) above the main curvature of the spine may cause severe local angulation and spinal cord compression (Westworth and Sturges, 2010). The most commonly affected breeds are those with screw tails, namely bulldogs, French bulldogs, pugs, and Boston terriers (Morgan, 1968; Done et

al., 1975). It has been suggested that the kinked tail in these breeds is due to hemivertebra affecting the coccygeal region, and this trait has been selected as a desirable phenotype for many generations (Done et al., 1975; Schlensker and Distl, 2013; Kramer et al., 1982). Other breeds have been described, including the German short-haired pointer with an autosomal recessively inherited trait (Kramer et al., 1982). The most common area involved is the coccygeal segments in screwtail breeds and the mid to caudal thoracic region (T6-T9), (Done et al., 1975; Westworth and Sturges, 2010; Moissionnier et al., 2011; Schlensker and Distl, 2013; Gutierrez et al., 2014; De Rycke et al., 2016).

Although these defects are present at birth, often they are not clinically apparent until four to ten months of age (adolescence) when the most dramatic and rapid curvatures may be seen during periods of accelerated growth (McMaster and Singh, 1999; Aikawa et al., 2007; Westworth and Sturges, 2010; Moissionnier et al., 2011). Clinical signs are often progressive until skeletal maturity occurs, and the onset may be acute, chronic or intermittent (Westworth and Sturges, 2010; Moissionnier et al., 2011; Schlensker and Distl, 2013). If associated with a degenerative process, for example, intervertebral disc degeneration and subsequent protrusion/extrusion, ligamentous hypertrophy, or articular remodeling, the onset of neurologic signs may occur in mature animals (Westworth and Sturges, 2010).

Lateral projection radiographs may reveal ventrodorsal wedging of the body, with the apex orientated ventrally. De Rycke et al. (2016) described a pug, which showed radiographically normal vertebrae at birth (Figure 11), but developed severe kyphosis by the age of six months due to a wedge shaped vertebra (T9) (Figures 12 and 13). Probably, more young dogs with late-onset kyphosis due to wedge vertebrae show radiographically normal vertebrae at birth, and develop hemivertebrae during growth due to growth plate deficiency (De Rycke et al., 2016). Breeders of brachycephalic, 'screw-tailed' breeds should be advised that screening pups for wedge vertebrae should not be performed during the first months of life but rather when the vertebral length growth is more advanced.

Advanced imaging, especially MR, provides necessary information regarding both extrinsic (degree of compression) and intrinsic spinal cord changes (Figure 14). Surgical decompression or an attempt to realign the vertebral column in cases with clinical signs associated with hemivertebra can be challenging, and there are only a few reports of such cases in the veterinary literature (Aikawa et al., 2007, Jeffery et al., 2007, Meheust and Robert, 2010, Dewey 2013; Charalambous et al., 2014) (Figure 15). The two main methods of stabilizing kyphotic vertebral segments in these patients is via segmental spinal stabilization (often referred to as spinal 'stapling'), and vertebral body pin and polymethylmethacrylate (PMMA) fixation. Successful outcomes have been reported in most dogs treated with either of these methods.

Block vertebrae

Block vertebrae are another example of failure of segmentation during embryogenesis, and result from partial or complete fusion of two or more vertebrae (Westworth, 2010) (Figure 16). In some cases, this fusion may occur predominantly in one plane or unilaterally, resulting in a bony bar restricting growth, and may cause an angular deformity in that plane. Any adjoining part(s) of the vertebrae may be involved, that is, vertebral arch with fused non-articulated process-

es, or centrum with or without the intervertebral disc formed. The segments may be of normal length or shortened. Often, these anomalies are not associated with neurologic deficits, but may occur in cases of angular deformation, stenosis of the vertebral canal, or if there is abnormal loading of adjacent vertebra, leading to intervertebral disc degeneration/protrusion, instability or ligament hypertrophy (Malik et al., 2009).

Articular facet aplasia/dysplasia

Articular facet aplasia/dysplasia is an anomaly relating to reduced formation or absence of the articular processes or facets. In dogs, such entities are apparently frequent, but poorly reported (Morgan 1968). The pathogenesis has not been fully determined, but is postulated to result from either dysgenesis of the two neural arch centers of ossification or abnormal development of secondary ossification centers (Werner et al., 2004).

In 1968, Morgan observed in a series of 145 dogs that almost every case had some degree of anomalous change to the articular facet(s). In general, this involved just mild changes to shape and size. More severe changes were noted to include uni- or bilateral absence of the articular process, and most commonly the anomalies were found cranial to T10 in the thoracic region (Morgan, 1968). More recently, three other articles have also demonstrated such anomalies and have attempted to review their clinical significance. In 2002, Breit examined 140 spines in neurologically normal large, chondrodystrophic and small breed dogs, and found T1-T9 segments to be exclusively affected and in small breed dogs only. There was no apparent association of such anomalies and intervertebral disc disease or deformative spondylosis. A case of bilateral aplasia of the caudal T12, both cranial and caudal T13 and cranial L1 articular processes without apparent gross instability, has been reported in a small breed dog, showing a possible association with intervertebral disc extrusion (Werner et al., 2004). Another series of four dogs of varying size had either aplasia (3) or hypoplasia (1) of the caudal facets joints at the thoracolumbar junction (T12-L1) or L5. Associated with this was cranial articular process degeneration and proliferation of the joint capsule and ligamentum flavum, causing stenotic myelopathy in the three cases with aplasia (Penderis et al., 2005).

Transitional vertebrae

Transitional vertebrae are one of the most common anomalies, and have been well described in most breeds of dogs (Morgan, 1968; Morgan, 1999; Lapalainien et al., 2012). Transitional vertebrae are congenital anomalies usually found at the junction between two divisions of the vertebral column, that is, cervicothoracic, thoracolumbar, lumbosacral, or sacrocaudal, and may result in variations in the number of vertebrae found within a division (Westworth and Sturges,

2010). Characteristics of adjacent divisions are exhibited in a single vertebra, unilaterally or bilaterally. This condition most commonly involves the presence or absence of a costa or transverse process (Morgan, 1968). Examples are elongated C7 transverse process resembling a costa, absence of a rib at T13 and/or short misshapen transverse process (Figure 17), L7 attached to sacrum by fused transverse process and/or body (sacralization of L7) (Figure 18), or partially divided S1-S2 segment (lumbarization of S1) and variation in the level of the anticlinal vertebra (T10 or T11). The cause of these anomalies is unknown, but involves border shifts of somites and is a defect of segmentation. In general, animals remain asymptomatic except in cases of lumbosacral transitional vertebra (LTV) (Lappalainen et al., 2012). It predisposes to premature degeneration of the lumbosacral junction and disc herniation, and is a frequent cause of cauda equine syndrome, especially in German shepherd dogs. This is well described in the literature regarding lumbosacral involvement and associated stenosis (Morgan, 1993; Morgan, 1999; Damur-Djuric et al., 2006; Flückiger et al., 2006; Wigger et al., 2009; Lappalainen et al., 2012). Ventrodorsal hip radiographs are most often used in the diagnosis of LTV but laterolateral radiographs must be considered as an addition to ventrodorsal projections (Lappalainen et al., 2012). Also CT can be used for diagnosis of LTV. With this modality, the lumbosacral region can be seen without superimposition of other pelvic structures (Lappalainen et al., 2012).

Recognition of a transitional segment is especially important during surgery of the spine, because failure to do this may result in performing a procedure at a level cranial or caudal to that expected, particularly in the thoracolumbar spine (Westworth and Sturges, 2010).

Spinal stenosis

Spinal stenosis is a narrowing or stricture of the vertebral canal or intervertebral foramen in any plane or level. It can occur focally, segmentally or generalized throughout the spine.

Spinal stenoses recognized in domestic animals can be classified by presumed etiology into congenital/developmental and acquired causes (Westworth and Sturges, 2010).

Congenital spinal stenoses are malformations that are present at the time of birth but for which there is no active underlying cause. This type of stenosis may occur alone or in association with other congenital anomalies of the spine or spinal cord, including spinal dysraphism, hemivertebrae and block vertebrae (Verbiest, 1990) (Figure 19). A mid-sagittal vertebral canal diameter that is small enough to result in compression of neural elements directly is referred to as absolute stenosis, whereas a diameter that is less than normal (for the breed), but not causing neural compression or clinical signs, is termed relative stenosis. This type of

stenosis may become symptomatic if another space-occupying pathological condition is superimposed, such as disc protrusion or ligamentous hypertrophy (Verbiest, 1990).

Doberman pinschers have been described with cranial thoracic (T3–T6) dorsoventral diameter of the canal, often with impingement of the spinal cord without overt compression (Bailey and Morgan, 1992). The malformation is apparent on routine spinal radiographs and most commonly affects the T3 to T6 vertebrae associated with mild spinal curvature (kyphosis). On myelography or MR, the vertebrae show a decrease in the dorsoventral diameter of the vertebral canal as compared with adjacent vertebrae, but spinal cord compression is not usually present (Westworth and Sturges, 2010). Two unrelated five-month-old Dogues de Bordeaux have been reported with dorsolateral cranial thoracic stenosis (T2–4 and T4–6) and thickening of the pedicle, causing spinal cord compression. Decompressive dorsal laminectomy and medial pediculectomy without stabilization were done, with slow recovery to reasonable function (Stalin et al., 2009). The authors also have seen several giant breed puppies, usually Bull Mastiffs or Great Danes between eight and fifteen months of age that have segmental spinal stenosis commonly seen in the T2 to T4 region. These dogs generally have spinal cord compression on imaging studies. Additional similar case reports include a three-month-old basset hound with progressive paraparesis due to T12 to T13 stenosis and malformation of the lamina causing spinal cord compression (Stigen et al., 1990) and a bulldog with T3 to T4 bony dorsolateral stenosis (Wheeler, 1991). This dog also had wedged-shaped vertebrae, most likely due to ventral centrum hypoplasia at T9 and T10, without spinal cord compression at that level. Thoracic congenital spinal stenosis has also been reported in two English bulldogs (Knecht et al., 1979). In addition, transitional vertebrae may frequently be stenotic or may predispose to acquired stenosis, especially in the lumbosacral location.

Developmental stenoses are malformations that are present at the time of birth with an active underlying cause that remains present throughout the growth period until the vertebrae have reached maturity. In this condition, a disproportion between a narrowed vertebral canal and the volume of neural elements within the canal often leads to clinical signs, especially affecting the lower lumbar region (Verbiest, 1990). This condition is present in chondrodysplastic dogs (Morgan et al., 1987) and may be part of the reason that clinically significant disc disease is so common in these breeds.

Medical therapy in case of congenital vertebral column anomalies

Medical management is instituted in clinically affected dogs, whether or not surgical correction of the deformity is planned. Medical management typically

consists of anti-inflammatory doses of prednisone, strict exercise restriction (with potential crate confinement) and pain-relieving drugs. NSAIDs are appropriate for dogs experiencing clinical signs of back pain with minimal to no pelvic limb motor deficits (Dewey et al., 2016).

CONCLUSION

Congenital malformations of the vertebrae occur frequently in dogs. Many spinal anomalies do not produce overt neurologic disease and are detected as incidental findings on radiography or computed tomography. In animals with neurologic disease, any spinal malformation that is seen within the region of neuroanatomic localization must be investigated carefully to establish its clinical significance. Although severe malformations may result in poor quality of life and euthanasia, there are a large number of conditions that remain surgically treatable. Recent advances in imaging and surgical techniques have improved the understanding and treatment of these diseases.

REFERENCES

- Aikawa T., Kanazono S., Yoshigae Y., Sharp N.J., Muñana K.R. (2007). Vertebral stabilization using positively threaded profile pins and polymethylmethacrylate, with or without laminectomy, for spinal canal stenosis and vertebral instability caused by congenital thoracic vertebral anomalies. *Veterinary Surgery* 36, 432–441.
- Aikawa T., Shibata M., Asano M., Hara Y., Hara Y., Tagawa M., Orima H. (2014). A comparison of thoracolumbar intervertebral disc extrusion in French bulldogs and dachshunds and association with congenital vertebral anomalies. *Veterinary Surgery* 43, 301–307.
- Bailey C.S., Morgan J.P. (1992). Congenital spinal malformations. *Veterinary Clinics of North America* 22, 985–1015.
- Booth M. J. (1998). Atypical dermoid sinus in a chow chow dog. *Journal of the South African Veterinary Association* 69, 102–104.
- Bornard N., Pin D., Carozzo C. (2007). Bilateral parieto-occipital dermoid sinuses in a rottweiler. *Journal of Small Animal Practice* 48, 107–110.
- Breit S. (2002). Osteological and morphometric observations on intervertebral joints in the canine pre-diaphragmatic thoracic spine (Th1–Th9). *Veterinary Journal* 164, 216–223.
- Brunetti A., Fatone G., Cuomo A., Lorzio R., Potena A. (1993). Meningomyelocele and hydrocephalus in a bulldog. *Progress in Veterinary Neurology* 4, 54–58.
- Camacho A. A., Laus J. L., Valeri V., Valeri F. V., Nunes N. (1995). Dermoid sinus in a great Pyrenees dog. *Brazilian Journal of Veterinary Research and Animal Science* 32, 170–172.
- Charalambous M., Jeffery N. D., Smith P. M., Goncalves R., Barker A., Hayes G., Ives E., Vanhaesebrouck A.E. (2014). Surgical treatment of dorsal hemivertebrae associated with kyphosis by spinal segmental stabilisation, with or without decompression. *The Veterinary Journal* 202, 267–273.
- Chesney C.J. (1973). A case of spina bifida in a chihuahua. *Veterinary Record* 93, 120–121.
- Clayton H.M., Boyd J.S. (1983). Spina bifida in a German shepherd puppy. *Veterinary Record* 112, 13–135.
- Cornegliani L., Ghibaudo G. (1999). A dermoid sinus in a Siberian husky. *Veterinary Dermatology* 10, 47–49.
- Cornegliani L., Jommi E., Vercelli, A. (2001). Dermoid sinus in a golden retriever. *Journal of Small Animal Practice* 42, 514–516.
- Damur-Djuric N., Steffen F., Hässig M., Morgan J.P., Flückiger M.A. (2006). Lumbosacral transitional vertebrae in dogs: classification, prevalence, and association with sacroiliac morphology. *Veterinary Radiology & Ultrasound* 47, 32–38.
- Davies E.S., Transson B.A., Gavin P.R. (2004). A confusing magnetic resonance imaging observation complicating for a dermoid cyst in a Rhodesian ridgeback. *Veterinary Radiology & Ultrasound* 45, 307–309.
- De Rycke L.M., Crijns C., Chiers K., van Bree H.J., Gielen I.M. (2016). Late-onset wedge-shaped thoracic vertebrae in a six-month-old pug. *Veterinary Record Case Reports* 4, 1–7.
- Dewey C.W. (2013). Surgery of the thoracolumbar spine. In: Fossum T.W. (editor). *Small Animal Surgery*. Saunders Elsevier, St. Louis, Missouri, USA, p. 1508–1528.
- Dewey C. W., Davies E., Bouma J. L. (2016). Kyphosis and kyphoscoliosis associated with congenital malformations of the thoracic vertebral bodies in dogs. *Veterinary Clinics of North America: Small Animal Practice* 46, 295–306.
- Done S.H., Drew R.A., Robins G.M., Lane J.G. (1975). Hemivertebrae in the dog: clinical and pathological observations. *Veterinary Record* 96, 313–317.
- Fatone G., Brunetti A., Lamagna F., Potena A. (1995). Dermoid sinus and spinal malformations in a Yorkshire terrier: diagnosis and follow-up. *Journal of Small Animal Practice* 36, 178–180.
- Fingerroth J.M., Johnson G.C., Burt J.K., Fenner W.R., Cain L.S. (1989). Neuroradiographic diagnosis and surgical repair of tethered cord syndrome in an English bulldog with spina bifida and myeloschisis. *Journal of the American Veterinary Medical Association* 194, 1300–1302.
- Flückiger M.A., Damur-Djuric N., Hässig M., Morgan J.P., Steffen F. (2006). A lumbosacral transitional vertebra in the dog predisposes to cauda equina syndrome. *Veterinary Radiology & Ultrasound* 47, 39–44.
- Gómez M., Mieres M., Gutiérrez J.C., Jones J.C. (2012). CT myelography characteristics of spinal dysraphism in a young mixed breed dog. *Archivos de Medicina Veterinaria* 44, 191–194.
- Gutierrez-Quintana R., Guevar J., Stalin C., Faller K., Yeaman C., Penderis J. (2014). A proposed radiographic classification scheme for congenital thoracic vertebral malformations in brachycephalic “screw-tailed” dog breeds. *Veterinary Radiology & Ultrasound* 55, 585–591.
- Hedequist D., Emans J. (2007). Congenital scoliosis. *Journal of Pediatric Orthopaedics* 27, 106–116.
- Hillbertz N.H. (2005). Inheritance of dermoid sinus in the Rhodesian ridgeback. *Journal of Small Animal Practice* 46, 71–74.
- Hillbertz N. H., Andersson G. (2006) Autosomal dominant mutation causing the dorsal ridge predisposes for dermoid sinus in Rhodesian ridgeback dogs. *Journal of*

- Small Animal Practice* 47, 184–188.
- Hillbertz N.H., Isaksson M., Karlsson E.K. (2007). Duplication of FGF3, FGF4, FGF19 and ORAOV1 causes hair ridge and predisposition to dermoid sinus in ridgeback dogs. *Nature Genetics* 19, 1318–1320.
- Jeffery N.D., Smith P.M., Talbot C.E. (2007). Imaging findings and surgical treatment of hemivertebrae in 3 dogs. *Journal of the American Veterinary Medical Association* 230, 532–536.
- Kawakami N., Tsuji T., Imagama S. (2009). Classification of congenital scoliosis and kyphosis: a new approach to the three-dimensional classification for progressive vertebral anomalies requiring operative treatment. *Spine* 41, 1756–1765.
- Kiviranta A.-M., Lappalainen A.K., Hagner K., Jokinen T. (2011). Dermoid sinus and spina bifida in three dogs and a cat. *Journal of Small Animal Practice* 52, 319–324.
- Knecht C.D., Blevins W.E., Raffé M.R. (1979). Stenosis of the thoracic spinal canal in English bulldogs. *Journal of the American Animal Hospital Association* 15, 181–183.
- Kramer J. W., Schiffer S. P., Sande R. D., Rantanen N. W., Whitener E. K. (1982). Characterization of heritable thoracic hemivertebra of the German shorthaired pointer. *Journal of the American Veterinary Medical Association* 181, 814–815.
- Lappalainen A.K., Salomaa R., Junnila J., Snellman M., Laitinen-Vapaavuori O. (2012). Alternative classification and screening protocol for transitional lumbosacral vertebra in German shepherd dogs. *Acta Veterinaria Scandinavica* 54, 1–10.
- Malik Y., Konar M., Wernick M., Howart J., Forterre F. (2009). Chronic intervertebral disk herniation associated with fused vertebrae treated by lateral corpectomy in a cat. *Veterinary Comparative Orthopaedics and Traumatology* 22, 170–173.
- Mann G.E., Stratton J. (1966). Dermoid sinus in the Rhodesian ridgeback. *Journal of Small Animal Practice* 7, 631–642.
- Marks S. L., Harari J., Dernell, W.S. (1993). Dermoid sinus in a Rhodesian ridgeback. *Journal of Small Animal Practice* 34, 356–358.
- McMaster M.J., Singh H. (1999). Natural history of congenital kyphosis and kyphoscoliosis. *The Journal of Bone and Joint Surgery. American Volume* 81, 1367–1383.
- Meheust P., Robert R. (2010). Surgical treatment of a hemivertebra by partial ventral corpectomy and fusion in a labrador puppy. *Veterinary and Comparative Orthopaedics and Traumatology* 23, 262–265.
- Miller L, Tobias K. (2003). Dermoid sinuses: description, diagnosis and treatment. *Compendium on Continuing Education for the Practicing Veterinarian* 25, 295–299.
- Moissonnier P., Gossot P., Scotti S. (2011). Thoracic kyphosis associated with hemivertebra. *Veterinary Surgery* 40, 1029–1032.
- Morgan J.P. (1968). Congenital anomalies of the vertebral column of the dog: a study of the incidence and significance based on a radiographic and morphologic study. *Journal of the American Veterinary Radiology Society* 9, 21–29.
- Morgan J.P., Atilola M., Bailey C.S. (1987). Vertebral canal and spinal cord mensuration: a comparative study of its effect on lumbosacral myelography in the Dachshund and German shepherd dog. *Journal of the American Veterinary Medical Association* 191, 951–957.
- Morgan J.P., Bahr A., Franti C.E., Bailey C.S. (1993). Lumbosacral transitional vertebrae as a predisposing cause of cauda equina syndrome in German shepherd dogs: 161 cases (1987–1990). *Journal of the American Veterinary Medical Association* 202, 1877–1882.
- Morgan J.P. (1999). Transitional lumbosacral vertebral anomaly in the dog: A radiographic study. *Journal of Small Animal Practice* 40, 167–172.
- Newitt A., German A.J., Barr F.J. (2008). Congenital abnormalities of the feline vertebral column. *Veterinary Radiology & Ultrasound* 49, 35–41.
- Parker A.J., Byerly C.S. (1973). Meningomyelocele in a dog. *Veterinary Pathology* 10, 266–273.
- Parker A.J., Park R.D., Byerly C.S., Stowater J.L. (1973). Spina bifida with protrusion of spinal cord issue in a dog. *Journal of the American Veterinary Medical Association* 163, 158–160.
- Penderis J., Schwarz T., McConnell J.F., Garosi L.S., Thomson C.E., Dennis R. (2005). Dysplasia of the caudal articular facets in four dogs: results of radiographic, myelographic and magnetic resonance investigations. *Veterinary Record* 156, 601–605.
- Penrith M. L., Van Schouwenburg S. (1994). Dermoid sinus in a boerboel bitch. *Journal of the South African Veterinary Association* 65, 38–39.
- Ployart S., Doran I., Bomassi E., Bille C., Libermann S. (2013). Myelomeningocele and a dermoid sinus-like lesion in a French bulldog. *Canadian Veterinary Journal* 54, 1133–1136.
- Pratt J. N.J., Knottenbelt C.M., Welsh, E.M. (2000). Dermoid sinus at the lumbosacral junction in an English springer spaniel. *Journal of Small Animal Practice* 41, 24–26.
- Rahal S., Mortari A.C., Yamashita S. (2008). Magnetic resonance imaging in the diagnosis of type 1 dermoid sinus in two Rhodesian ridgeback dogs. *Canadian Veterinary Journal* 49, 871–876.
- Rossi A., Gandolfo C., Morana G., Piatelli G., Ravegnani M., Consales A., Pavanello M., Cama A., Tortori-Donati P. (2006). Current classification and imaging of congenital spinal anomalies. *Seminars in Roentgenology* 41, 250–273.
- Scott D. W., Miller H. M., Griffin C. E. (2001). Congenital and hereditary defects. In: Scott D.W., Miller W.H., Griffin C.E. (editors). *Muller & Kirk's Small Animal Dermatology*. Sixth edition, W.B. Saunders, Philadelphia, PA, USA, p. 936–937.
- Selcer E.A., Helman R.G., Selcer R.R. (1984). Dermoid sinus in a shih tzu and a boxer. *Journal of the American Animal Hospital Association* 20, 634–636.
- Schlenker E., Distl O. (2013). Prevalence, grading and genetics of hemivertebrae in dogs. *European Journal of Companion Animal Practice* 23, 119–123.
- Shamir M., Rochkind S., Johnston D. (2001). Surgical treatment of tethered spinal cord syndrome in a dog with myelomeningocele. *Veterinary Record* 48, 755–756.
- Song R.B., Glass E.N., Kent M., Sánchez M.D., Smith D.M., de Lahunta A. (2014). Surgical correction of a sacral meningomyelocele in a dog. *Journal of the American Animal Hospital Association* 50, 436–443.
- Song R.B., Glass E.N., Kent M. (2016). Spina bifida, meningomyelocele, and meningocele. *Veterinary Clinics of North America; Small Animals* 46, 327–345.
- Stalin C.E., Pratt J.N., Smith P.M., Jeffery N.D. (2009). Thoracic stenosis causing lateral compression of the spinal cord in two immature Dogues de Bordeaux. *Veteri-*

- nary *Comparative Orthopaedics and Traumatology* 22, 59–62.
- Stigen O., Hagen G., Kolbjornsen O. (1990). Stenosis of the thoraco-lumbar vertebral canal in a basset hound. *Journal of Small Animal Practice* 31, 621–623.
- Tsou P.M. (1977). Embryology of congenital kyphosis. *Clinical Orthopaedics and Related Research* 128, 18–25.
- Tsou P.M., Yau A., Hodgson A.R. (1980). Embryogenesis and prenatal development of congenital vertebral anomalies and their classification. *Clinical Orthopaedics and Related Research* 152, 211–231.
- Verbiest H. (1990) Lumbar spinal stenosis. In: Youmans J.R. (editor). *Neurological Surgery*. Third edition, Volume 4, WB Saunders, Philadelphia, USA, p. 2805–2855.
- Werner T., McNicholas T.W., Kim J., Baird D.K., Breur G.J. (2004). Aplastic articular facets in a dog with intervertebral disc rupture of the 12th to 13th thoracic vertebral space. *Journal of the American Animal Hospital Association* 40, 490–494.
- Westworth D.R., Sturges B.K. (2010). Congenital spinal malformations in small animals. *Veterinary Clinics of North America: Small Animal Practice* 40, 951–981.
- Wheeler S.J. (1991). Vertebral abnormalities in dogs. *Journal of Small Animal Practice* 32, 149–150.
- Wigger A., Julier-Franz C., Tellhelm B.; Kramer M. (2009). Lumbosakraler Übergangswirbel beim Deutschen Schäferhund: Häufigkeit, Formen, Genetik und Korrelation zur Hüftgelenksdysplasie. *Tierärztlicher Praxis* 37, 7–13.
- Wilson J.W., Kurtz H.J., Leipold H.W., Lees G.E. (1979). Spina bifida in the dog. *Veterinary Pathology* 16, 165–179.

Uit het verleden

HONDEN BIJ ARME STEDELINGEN

‘Hun huis is doorgaans te klein voor het getal mensen dat het bevat. De kinderen zijn onrein en zwak, het ontbreekt hen aan verschoon van linnen en beddegoed; en daarbij nog honden houden! Dat alles geeft een eigenaardige walgelijken geur aan die woningen. Maar indien gij u veroorlooft hier eene opmerking over te maken, dan begint de man of de vrouw met de lof van den hond te zingen: “Het is zulk een braaf beestje, een zacht en trouw dier, enz.”

Dat de hond een trouw en vernuftig dier is, willen wij niet betwisten, maar men vergete ook niet dat de kinderen meer waard zijn dan de honden.

Een hond neemt dagelijks het aandeel voedsel van een kind weg. Indien gij geen overvloed bezit, waarom wilt ge dan immers nog honden voeden? Nu hoort gij de vrouw die u opnieuw in de rede valt: “Maar Mijnheer, men kan toch zonder beesten niet zijn.”

Er bestaat een algemeen vooroordeel onder de werkende klas, namelijk dat men huisdieren moet houden ten einde de menschen van den huize tegen ziekten en plagen te bevrijden. De plagen die anders de menschen zouden aanranden, vallen op de dieren, zeggen zij. Indien gij naar bewijzen van dat gezegde vraagt, zal de vrouw u antwoorden dat zij nooit anders gehoord heeft; hare ouders hebben het haar zo geleerd, en nu leert zij dat aan hare kinderen. En op deze wijze worden dwaling en bijgeloof zonder onderzoek van hand tot hand overgeleverd en voortgezet.

In de steden zijn de huisdieren bij de werkende klas eene groote oorzaak van onreinheid; en verre van de plagen van de mensch af te weren, zetten zij integendeel soms wel ongedierte, plagen en ziekten aan den mensch over.’

Uit: Frederick C.A. (1867). *Handboek der Gezondheidsleer voor Alle Standen*. Gent, Annot - Braeckman, p. 13-14.

Luc Devriese