



Strathprints Institutional Repository

Hadoura, L. and Douglas, C. and McGarry, G.W. and Young, D. (2009) *Mapping surgical coordinates of the sphenopalatine foramen: surgical navigation study*. *Journal of Laryngology and Otology*, 123 (7). pp. 742-745. ISSN 0022-2151

Strathprints is designed to allow users to access the research output of the University of Strathclyde. Copyright © and Moral Rights for the papers on this site are retained by the individual authors and/or other copyright owners. You may not engage in further distribution of the material for any profitmaking activities or any commercial gain. You may freely distribute both the url (<http://strathprints.strath.ac.uk/>) and the content of this paper for research or study, educational, or not-for-profit purposes without prior permission or charge.

Any correspondence concerning this service should be sent to Strathprints administrator: <mailto:strathprints@strath.ac.uk>



Hadoura, L. and Douglas, C. and McGarry, G.W. and Young, D. (2009) Mapping surgical coordinates of the sphenopalatine foramen: surgical navigation study. *Journal of Laryngology and Otology*, 123 (7). pp. 742-745. ISSN 0022-2151

<http://strathprints.strath.ac.uk/18672/>

This is an author produced version of a paper published in *Journal of Laryngology and Otology*, 123 (7). pp. 742-745. ISSN 0022-2151. This version has been peer-reviewed but does not include the final publisher proof corrections, published layout or pagination.

Strathprints is designed to allow users to access the research output of the University of Strathclyde. Copyright © and Moral Rights for the papers on this site are retained by the individual authors and/or other copyright owners. You may not engage in further distribution of the material for any profitmaking activities or any commercial gain. You may freely distribute both the url (<http://strathprints.strath.ac.uk>) and the content of this paper for research or study, educational, or not-for-profit purposes without prior permission or charge. You may freely distribute the url (<http://strathprints.strath.ac.uk>) of the Strathprints website.

Any correspondence concerning this service should be sent to The Strathprints Administrator: eprints@cis.strath.ac.uk

Mapping surgical coordinates of the sphenopalatine foramen: surgical navigation study

L HADOURA*, C DOUGLAS*, G W MCGARRY*†, D YOUNG‡

Abstract

Objectives: To identify measurements that may help intra operative localisation of the sphenopalatine foramen.

Design: The study used three dimensional surgical navigation software to study radiological anatomy, in order to define the distances and angulations between identifiable bony landmarks and the sphenopalatine foramen.

Results: The distance from the anterior nasal spine to the sphenopalatine foramen was 59 mm (± 4 mm; inter observer variation = 0.866; intra observer variation = 0.822). The distance from the piriform aperture to the sphenopalatine foramen was 48 mm (± 4 mm; inter observer variation = 0.828; intra observer variation = 0.779). The angle of elevation from the nasal floor to the sphenopalatine foramen was 22° ($\pm 3^\circ$; inter observer variation = 0.441; intra observer variation = 0.499).

Conclusions: The sphenopalatine foramen is consistently identifiable on three dimensional, reconstructed computed tomography scans. Repeatable measurements were obtained. The centre point of the foramen lies 59 mm from the anterior nasal spine at 22° elevation above the plane of the hard palate and 48 mm from the piriform aperture. We discuss how these data could be used to facilitate intra operative location of the sphenopalatine foramen in difficult cases.

Key words: Epistaxis; Sphenopalatine Artery; Endoscopic Surgical Procedure; Ligation; Sphenopalatine Foramen; Surgical Navigation

Introduction

Epistaxis is a common ENT emergency, often requiring hospital admission. Its prevalence in the population is around 10 per cent. However, less than 10 per cent of these patients seek medical treatment. Only 1–2 per cent of epistaxis patients seeking medical care will require surgical treatment.¹

Most cases of epistaxis are managed conservatively with chemical cautery or packing. However, when this fails, ligation of vessels is required. Previously, ligation of the internal maxillary artery through a trans-antral approach was commonly used. However, this was often associated with a number of complications, including facial swelling, facial numbness and oro-antral fistula.² More recently, ligation of the sphenopalatine artery has been adopted, which is associated with fewer complications and a shorter hospital stay compared with ligation of the internal maxillary artery.³ Ligation of the sphenopalatine artery was first described in 1976 by Prades.⁴ Endoscopic sphenopalatine artery ligation is now a recognised and frequently used treatment for

control of intractable posterior epistaxis that has not been controlled by conventional methods.^{5,6} However, locating the sphenopalatine foramen in a bleeding patient can be difficult; thus, good knowledge of the local anatomy is essential.

The sphenopalatine artery is the main vessel supplying the mucosa of the nasal septum, fontanelle, superior, middle and inferior turbinates, and the lateral nasal wall.⁷ The sphenopalatine artery arises in the pterygopalatine fossa from the maxillary artery and divides either proximal to or within the sphenopalatine foramen. The sphenopalatine artery supplies about 90 per cent of the nasal mucosa.⁸ The operation relies on identification of the bony sphenopalatine foramen. This foramen is bounded superiorly by the body of the sphenoid, anteriorly by the orbital process of the palatine bone, posteriorly by the sphenoidal process of the palatine bone and inferiorly by the perpendicular plate of the palatine bone.⁵ There remains a debate in the literature about the exact position of the sphenopalatine foramen. Lee *et al.* showed that the foramen was

From the *Department of Otolaryngology Head and Neck Surgery, Glasgow Royal Infirmary, the †Department of Otolaryngology Head and Neck surgery, Gartnavel General Hospital, Greater Glasgow and Clyde Trust, and the ‡Department of Statistics and Modelling Science, University of Strathclyde, Glasgow, Scotland, UK.
Presented at the Scottish Otolaryngology Society Winter Meeting, 25 November 2005 in Edinburgh, Scotland, UK.

located within the superior meatus, between the middle turbinate and the posterior horizontal end of the lamella of the superior turbinate, attaching to the lateral nasal wall in 90 per cent of cases. This was a cadaveric study in an Asiatic population; therefore, its applicability to the UK is unclear. In 10 per cent of cases, the foramen extended superiorly beyond the posterior horizontal portion of the lamella of the superior turbinate.⁹ Wareing studied 238 lateral nasal walls and suggested an osteological classification for the position of the sphenopalatine foramen.¹⁰ These two articles highlight the natural anatomical variation of the sphenopalatine foramen and raise the possibility of ethnic variation.

Objectives

The aim of this study was to examine the distance between key bony landmarks and the sphenopalatine foramen, in order to derive surgically useful coordinates which could be used in clinical practice.

Materials and methods

Ethics

Ethical approval was gained from the Glasgow Royal Infirmary local research ethics committee.

Surgical navigation system

The BrainLAB[®] surgical navigation system (BrainLab Limited, Cambridge, UK) was used to take anatomical measurements. The computed tomography (CT) scans of 28 patients were used. The CT scans had been done for other clinical reasons and were loaded in the BrainLAB surgical navigation system. No CTs were done solely for the purpose of this study. No patient had undergone previous sphenopalatine artery ligation.

The BrainLAB system is a surgical navigation tool allowing the surgeon to make detailed measurements in millimetres and degrees. The computer software allows the surgeon to display the three different views of each CT scan (sagittal, coronal and axial) on one screen together with a three-dimensional reconstruction. This system allows identification of the sphenopalatine foramen on each view; this fixed anatomical landmark can then be identified on the other views using a 'drag and drop' facility.

The two fixed bony landmarks used were chosen for clinical applicability. These were the anterior nasal spine and the plane of the piriform aperture. Three measurements were taken on the right and left of each CT: the distance from the sphenopalatine foramen to the nasal spine; the angle of elevation from the nasal floor to the sphenopalatine foramen; and the distance from the sphenopalatine foramen to the piriform aperture. The distance measurements were taken from the centre of the sphenopalatine foramen and were recorded in millimetres to the nearest 0.1 mm. The angle of elevation was measured to the nearest degree. All measurements taken were to scale, as checked with the CT software.

Measurements

A full set of measurements was taken on two occasions by three different observers of varying experience (one consultant, one specialist registrar and one senior house officer). The measurements were then used to compute the average distance and angle of elevation from the entrance of the nose to the sphenopalatine foramen. Inter- and intra-observer agreement was assessed by calculating the intra-class correlations between measurements.¹¹ Between-group comparisons (comparing men versus women and left versus right) were done on the average measures using *t*-tests, with the results displayed as confidence intervals for the differences along with *p* values. All analyses were done using Minitab (version 14) software at a significance level of 5 per cent.

Comparison of BrainLAB and skull data

Prior to this study, research on this subject had mainly relied upon anatomical dissection. In order to determine the overall scale of measurements likely, we carried out a preliminary, benchmarking anatomical study.

Ten Caucasoid skulls obtained from the Glasgow University anatomy department were measured and studied. Two independent observers made 40 measurements on these skulls. Measurements of the distance from the nasal spine to the sphenopalatine foramen ranged from 52 to 63 mm, with a mean distance of 57.5 mm. Measurements of the distance from the piriform aperture to the sphenopalatine foramen ranged from 42 to 56 mm, with a mean distance of 48 mm. These figures were comparable to the data obtained from the BrainLAB study, and thus supported its use as an alternative to osteological studies.

Results and analysis

There were 28 patients, eight women and 20 men. The mean age was 49.9 years (range 20–83 years). A total of 1008 observations was made.

The mean distance from the nasal spine to the sphenopalatine foramen was 59.027 mm ($n = 336$, standard deviation (SD) = 3.978 mm, median = 59 mm, range = 50–69 mm). The mean distance from the piriform aperture to the sphenopalatine foramen was 48.481 mm ($n = 336$, SD = 3.512 mm, median = 48.2 mm, range = 40.5–57.5 mm). The mean angle of elevation from the nasal floor was 22.560° ($n = 336$, SD = 3.214°, median = 22°, range = 14–32°).

Table I shows the intra-observer correlations for each observer over the two assessments for each measure. Correlations were higher for the spine and piriform aperture measurements than for the angle measurements. Inter-observer agreement is shown in Table II. Again, inter-observer correlations were markedly higher for the spine and piriform aperture measurements than for the angle measurements.

Comparison of the average measures (over the two time points) for men and women are shown in

TABLE I
INTRA-OBSERVER CORRELATIONS FOR EACH OBSERVER OVER THE TWO ASSESSMENTS

Observer	R spine	L spine	R angle	L angle	R lateral	L lateral
1	0.794	0.733	0.259	0.293	0.796	0.779
3	0.849	0.782	0.420	0.393	0.664	0.701
2	0.884	0.851	0.735	0.548	0.834	0.815

R = right; L = left; spine = distance from anterior nasal spine to the sphenopalatine foramen; angle = angle of elevation from nasal floor to sphenopalatine foramen; lateral = distance from piriform aperture to sphenopalatine foramen

TABLE II
INTER-OBSERVER CORRELATION OVER THE TWO ASSESSMENTS

Observer comparison	Rating	R spine	L spine	R angle	L angle	R lateral	L lateral
1 vs 3	1st	0.858	0.702	0.453	0.237	0.744	0.677
	2nd	0.790	0.747	-0.078	0.069	0.798	0.801
1 vs 2	1st	0.768	0.760	0.408	0.220	0.748	0.776
	2nd	0.816	0.814	0.174	0.484	0.788	0.743
3 vs 2	1st	0.738	0.720	0.224	0.338	0.749	0.723
	2nd	0.903	0.875	0.399	0.074	0.727	0.778

R = right; L = left; spine = distance from anterior nasal spine to the sphenopalatine foramen; angle = angle of elevation from nasal floor to sphenopalatine foramen; lateral = distance from piriform aperture to sphenopalatine foramen

Table III. Spine and piriform aperture measurements were significantly less in women.

Table IV shows that there were no obvious differences between the left and right measurements.

Overall inter-observer correlation values were calculated using the average of the two measurements for each of the spine, angle and piriform aperture recordings.

The inter-observer correlations were as follows: 0.866 for sphenopalatine foramen to nasal spine measurements; 0.441 for angle of elevation measurements (between the nasal floor and the sphenopalatine foramen); and 0.828 for sphenopalatine foramen to piriform aperture measurements.

The intra-observer correlations were as follows: 0.822 for sphenopalatine foramen to nasal spine

measurements; 0.499 for angle of elevation measurements; and 0.779 for sphenopalatine foramen to piriform aperture measurements.

Between-group comparisons were calculated based on the average of measurements taken at the two time points.

Discussion

A number of recent publications have described the use of endoscopic sphenopalatine artery ligation for the arrest of posterior epistaxis that has failed to settle with conservative management.^{5,6} This procedure has replaced trans-antral ligation of the internal maxillary artery, as the sphenopalatine artery procedure has lower rates of morbidity,

TABLE III
COMPARISON OF WOMEN VS MEN FOR EACH MEASUREMENT

Measurement	Women	Men	95% CIs*	p^{\dagger}
R spine (mean (SD); mm)	55.52 (2.14)	60.69 (3.55)	-6.41, -3.92	<0.001
L spine (mean (SD); mm)	55.76 (2.43)	61.16 (3.34)	-6.69, -4.12	<0.001
R lateral (mean (SD); mm)	45.73 (1.88)	49.97 (3.00)	-5.31, -3.17	<0.001
L lateral (mean (SD); mm)	45.99 (1.73)	49.47 (3.28)	-4.56, -2.39	<0.001
R angle (mean (SD); °)	22.85 (2.68)	22.42 (3.45)	-0.95, 1.81	0.534
L angle (mean (SD); °)	22.22 (2.50)	21.85 (3.23)	-0.91, 1.66	0.566

*For men vs women. \dagger Calculated by t test. CIs = confidence intervals; R = right; L = left; SD = standard deviation; spine = distance from anterior nasal spine to the sphenopalatine foramen; lateral = distance from piriform aperture to sphenopalatine foramen; angle = angle of elevation from nasal floor to sphenopalatine foramen

TABLE IV
COMPARISON FOR RIGHT VS LEFT FOR EACH MEASUREMENT

Measurement	Right	Left	95% CIs*	p^{\dagger}
Spine (mean (SD); mm)	59.03 (3.98)	59.42 (3.97)	-0.64, -0.15	0.002
Lateral (mean (SD); mm)	48.61 (3.34)	48.35 (3.29)	-0.08, 0.59	0.134
Angle (mean (SD); °)	22.56 (3.21)	21.97 (3.01)	0.12, 1.06	0.014

*For right (R) vs left (L). \dagger Calculated by paired t test. CIs = confidence intervals; SD = standard deviation; spine = distance from anterior nasal spine to the sphenopalatine foramen; lateral = distance from piriform aperture to sphenopalatine foramen; angle = angle of elevation from nasal floor to sphenopalatine foramen

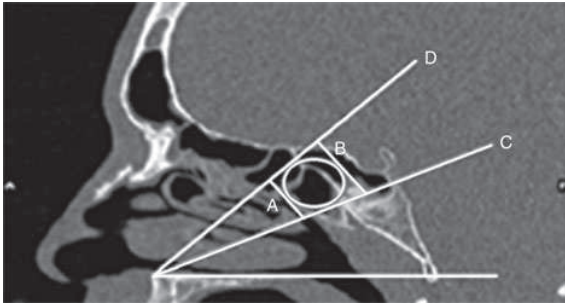


FIG. 1

Sagittal computed tomography scan showing the measurements taken and the most likely location of the sphenopalatine foramen. A = minimum distance from anterior nasal spine to sphenopalatine foramen (=55 mm); B = maximum distance from anterior nasal spine to sphenopalatine foramen (=63 mm); C = minimum angle of elevation from nasal floor to sphenopalatine foramen (=18°); D = maximum angle of elevation from nasal floor to sphenopalatine foramen (=26°); circle = most likely location of sphenopalatine foramen

hospital stay, complications and failure.^{12,13} There is continued debate in the literature about the exact position of the sphenopalatine foramen, with a recent Korean paper by Lee *et al.* reporting its position as within the superior meatus in 90 per cent of cases, and Wareing suggesting three different areas in which the foramen can arise anatomically.^{9,10} We propose that the measurements reported here represent useful surgical coordinates which may assist endoscopic sphenopalatine artery ligation.

- **Endoscopic sphenopalatine artery ligation is becoming the management of choice for refractory epistaxis**
- **Locating the sphenopalatine foramen can be surgically challenging**
- **The sphenopalatine foramen is clearly visible on computed tomography scans**
- **Coordinates derived from image guidance software may aid surgery of the sphenopalatine foramen**
- **This study used a mathematical model to provide clinically relevant and useful measurements for locating the sphenopalatine foramen during endoscopic sphenopalatine artery ligation**

The distance from the sphenopalatine foramen to the nasal spine had the highest inter- and intra-observer correlation coefficient for each assessment. It would therefore be the most reliable and clinically applicable measurement. The angle of elevation of the sphenopalatine foramen from the nasal floor had the lowest inter- and intra-observer correlation, and thus should be viewed as a rough guide only.

How could this knowledge be used?

Intra-operatively, the surgeon could advance a ball-ended probe 5.9 cm from the nasal spine, or 4.8 cm from the ipsilateral piriform aperture, along the nasal floor, then elevate it to an angle of 22° and move the probe's tip to touch the lateral nasal wall. The ball of the probe would then indicate the centre of a circle marking the most likely location of the sphenopalatine foramen (Figure 1).

We stress that the use of such parameters is not a substitute for detailed knowledge of the relevant anatomy, which remains essential.

We have also shown that the BrainLAB surgical navigation system is a useful and reliable tool for obtaining anatomical measurements, and could potentially be used for training and validation.

References

- 1 Shaheen OH. Epistaxis in the middle aged and elderly. Thesis, London: University of London, 1987
- 2 McDonald TJ, Pearson BW. Follow up on maxillary artery ligation for epistaxis. *Arch Otolaryngol* 1980;**106**:635-8
- 3 Feusi B, Holzmann D, Steurer J. Posterior epistaxis: systematic review on the effectiveness of surgical therapies. *Rhinology* 2005;**43**:300-304
- 4 Prades J. Abord endonasal de la fosse Pterygo Maxillaire LXXIII Cong. Franc. *Compt Rendus des Seanc* 1976;290-296
- 5 McGarry GW. Nasal endoscope in posterior epistaxis: a preliminary evaluation. *J Laryngol Oto* 1991;**105**:428-31
- 6 White PS. Endoscopic ligation of the sphenopalatine artery: a preliminary description. *J Laryngol Oto* 1996;**110**:27-30
- 7 Padgham N, Vaughan Jones R. Cadaver studies of the anatomy of arterial supply to the inferior turbinates. *J R Soc Med* 1991;**84**:728-30
- 8 Lang J. Clinical anatomy of the nose, nasal cavity and paranasal sinuses. New York: Thieme, 1989;47-57.
- 9 Lee HY, Kim HU, Kim SS, Son EJ, Kim JW, Cho NH, *et al.* Surgical anatomy of the sphenopalatine artery in lateral nasal wall. *Laryngoscope* 2002;**112**:1813-18
- 10 Wareing MJ, Padgham ND. Osteologic classification of the sphenopalatine foramen. *Laryngoscope* 1998;**108**:125-7
- 11 Bland MJ, Altman DG. Statistics Notes Measurement Error. *BMJ* 1996;**312**:1654
- 12 Feusi B, Holzmann D, Steurer J. Posterior epistaxis: systematic review on the effectiveness of surgical therapies. *Rhinology* 2005;**43**:300-304
- 13 Umapathy N, Quadri A, Skinner DW. Persistent epistaxis: what is the best practice? *Rhinology* 2005;**43**:305-308

Address for correspondence:

Miss Lubna Hadoura,
SpR in ENT,
Department of Otolaryngology Head and Neck Surgery,
Glasgow Royal Infirmary,
16 Alexandra Parade,
Glasgow G31 2ER, Scotland, UK.

Fax: 0141 575 2841
E mail: lubna0110@yahoo.com