



Strathprints Institutional Repository

Ahanathapillai, V. and Soraghan, J.J. and Sonecki, P. (2009) *Delaunay triangulation based image enhancement for echocardiography images*. In: 17th European Signal Processing Conference, 2009-08-24 - 2009-08-28, Glasgow, Scotland.

Strathprints is designed to allow users to access the research output of the University of Strathclyde. Copyright © and Moral Rights for the papers on this site are retained by the individual authors and/or other copyright owners. You may not engage in further distribution of the material for any profitmaking activities or any commercial gain. You may freely distribute both the url (<http://strathprints.strath.ac.uk/>) and the content of this paper for research or study, educational, or not-for-profit purposes without prior permission or charge.

Any correspondence concerning this service should be sent to Strathprints administrator: <mailto:strathprints@strath.ac.uk>

DELAUNAY TRIANGULATION BASED IMAGE ENHANCEMENT FOR ECHOCARDIOGRAPHY IMAGES

V Ahanathapillai¹, J. J. Soraghan¹, P. Sonecki²

¹Department of Electronics and Electrical Engineering, University of Strathclyde, 204 George Street, Glasgow - G1 1XW

²Department of Cardiology, Western Infirmary, Glasgow - G11 6NT

email: viji@eee.strath.ac.uk,

ABSTRACT

A novel image enhancement approach for automatic echocardiography image processing is proposed. The main steps include undecimated wavelet based speckle noise reduction, edge detection, followed by a regional enhancement process that employs Delaunay triangulation based thresholding. The edge detection is performed using a fuzzy logic based center point detection and a subsequent radial search based fuzzy multiscale edge detection. The edges obtained are used as the vertices for Delaunay triangulation for enhancement purposes. This method enhances the heart wall region in the echo image. This technique is applied to both synthetic and real image sets that were obtained from a local hospital.

1. INTRODUCTION

Echocardiography (or Echo) is one of the most widely used medical imaging techniques for the diagnosis of heart conditions, such as wall motion abnormality, and help diagnose the possible presence of damaged tissue in the heart wall. Echo scan is a movie captured over time, to cover a complete cardiac cycle. Although Echo scans are low quality images, these scans are preferred to that of the other cardiac imaging techniques (such as MRI, CT). This is due to the fact that they are: reliable; harmless; painless; cost effective and non-invasive. Additionally, the echo images are suitable for determining left ventricle (LV) wall thickness, and regional wall motion abnormalities. Despite advancements in the ultrasonic imaging technique, the captured images may still contain various imaging artefacts, such as, large amount of noise, missing structures (those parallel to the ultrasound beam), false echoes, shadowing, and restricted echo windows [1]. Also, the quality of the echo images is both patient dependent (the images taken in obese patients have more noise and lower contrast) and clinician dependent.

Manual interpretation of echo images by an expert is a laborious process due to the poor contrast resolution, a high level

of noise and other artefacts. Due to the nature of these images, there is significant inter-observer and intra-observer variability in the diagnosis of heart conditions. This results in the need for research in the field of echocardiography image enhancement techniques.

A new algorithm to enhance the heart wall region in low quality echocardiograph scans is presented in this paper. A detailed description of the various stages involved is described in section 2. The experimental results are presented in section 3, and section 4 contains concluding remarks and suggestions for future work.

2. METHODOLOGY

A high level overview of the proposed enhancement algorithm is presented in Fig.1. The proposed algorithm reduces speckle noise and enhances the features of diagnostic importance, such as the heart wall in short axis (SA) and long axis (LA) views. Undecimated wavelets are known to smooth signal-independent noise [2, 3] and are used to reduce speckle noise in the echo scans.

Various image processing techniques have been applied to segment the heart wall boundaries to assist the interpretation of echo images [4]. The segmentation of the heart wall in the echo image is strongly influenced by the quality of the image and the presence of speckle noise (a characteristic of coherent images like ultrasound images which reduce the contrast of the image). Enhancement of features in echocardiography images, performed in [5] involves phase congruency based feature detection, followed by nonlinear post processing. 2D feature asymmetry used here to detect the features, does not yield clean features, in noisy images, if the signal to noise ratio is low. Contrast enhancement of the echocardiograph images by multiscale wavelet analysis along with wavelet shrinkage technique is performed in [6].

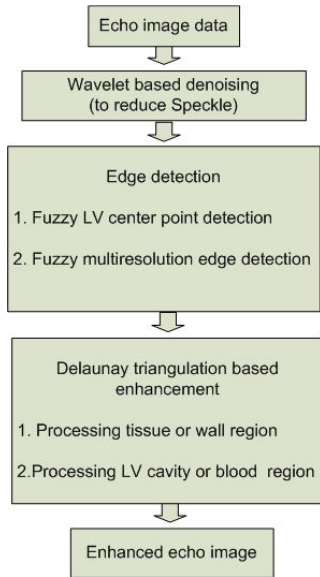


Fig. 1 Enhancement Algorithm Overview

In our work, prior knowledge of the images is taken into account for enhancing the echo scan. To determine the region of interest, the center point and wall boundaries are detected by performing fuzzy center point detection [7] and fuzzy multiscale edge detection [8]. Then, a triangular meshing technique called Delaunay triangulation [9] is used to divide the region of interest into smaller regions using the edges obtained in the previous step. This triangulation technique divides a surface into regions with common characteristics that are particularly well-suited for image processing applications [9]. Delaunay has been used to represent shapes in images and used for image segmentation [10] and also used to form high resolution image from low resolution frames [11].

2.1 Speckle noise reduction

Speckle noise caused by backscattering, is a random, interference pattern in coherent images such as ultrasound images. The texture of the observed speckle pattern does not correspond to the underlying anatomical structure of the heart. In this algorithm, undecimated wavelets are used to decompose the image (up to 4 levels) into approximation and details. An average filtering is applied to the approximation and mean based smoothing is applied to the details, which is defined mathematically for an image $I(x, y)$ as

$$I(x, y) = \begin{cases} I(x, y) & \text{if } |I(x, y)| \leq N \\ N & \text{if } |I(x, y)| > N \end{cases} \quad (1)$$

where N is the mean value of row of the pixel $I(x, y)$ and x, y are the pixel coordinates.

The above representation can be explained as follows. Firstly the mean value (N) of each row is computed. If the absolute value of a coefficient in the row exceeds the mean value then it is replaced by the mean. This operation is used to smooth the sudden changes of coefficient values. The same operation

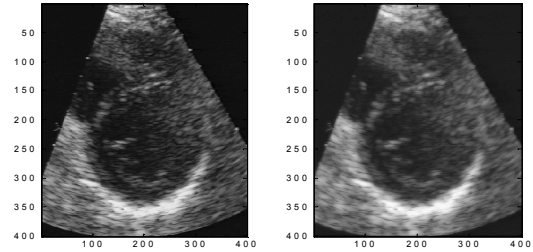


Fig. 2 Original Image (left) and image after speckle noise reduction (right)

is applied to all rows of the sub-bands. Then the image is reconstructed using all the modified sub bands to get the noise reduced image as shown in Fig. 2.

2.2 Edge detection

The multiresolution-based algorithm proposed by [7] is used in this work for cardiac left ventricular (LV) epicardial and endocardial boundary detection. It is a center-based approach, where the edges are searched along the radial lines starting from the LV center. The advantage of using this approach is that the processing time is reduced as the boundary search problem is transformed from two dimensions to one dimension. This fuzzy multiscale edge detection technique comprises of two main stages, the automatic LV center point detection for all the echo frames, LV boundary detection on radial lines and spatial/temporal processing of the extracted boundaries and Cubic B-Spline LV boundary approximation [8]. These stages are described in the following sections.

2.2.1 Left Ventricle Centre Point (LVCP) detection:

The automatic LVCP detection is performed using the knowledge that the LV is close to the center of the image plane and the grey level of LV cavity is dark with characteristic dark neighbourhood pattern. The local and global knowledge of the echo images are represented by fuzzy membership functions and the candidate LVCP pixels are obtained by using fuzzy logic operators. In other words, fuzzy membership functions are used to represent

- Spatial information (LVCP is in the center part of the image),
- Morphological information (LVCP is close to the vertical diameter of the LV passing through the lowest point of the posterior epicardial boundary), and
- Intensity information (LVCP is a dark pixel).

These membership functions are combined by applying fuzzy operator for intersection to select the higher membership degree at the output. After obtaining most probable candidates for the LVCP, a template matching is performed for these candidate pixels to obtain the most likely LVCP. Template matching is used here to search for specific patterns (dark neighbourhood pattern) within the LV cavity [7].

2.2.2 Left Ventricle Boundary detection:

The reason for using the center-based and radial search based approach, proposed by [8] is the observation of radial ori-

ented motion of the LV boundary in the echo movie. In this approach, the edges are searched along the radial lines starting from the LV center. The radial lines through the anterior wall are combined to determine the epicardial, endocardial edges and their difference to get the LV wall thickness. Using these edges along with the LVCP, a region of interest (ROI) is defined for both endocardial and epicardial boundaries. A rough estimate of the epicardium is estimated. Other than the first radial line, a ROI is modelled by including a region on either side of the detected edge in the previous radial line. Similar ROI is modelled for the endocardial edges. The endocardial and epicardial edge points are extracted from these radial lines in the ROI using Fuzzy Multiscale Edge Detection (FMED) [8]. The wavelet transform (WT) of the radial line profile is performed. Local maximum at a given WT scale represents the positive step edge in the signal. Fuzzy membership functions are used to represent the WT scales. Appropriate membership value is assigned to all the points coincident with the local maxima. The different scales are combined by applying fuzzy operator for intersection to extract the edge in the ROI. The extracted endocardial and epicardial boundaries are refined by applying cubic B-spline approximation to get a continuous and smooth boundary.

2.3 Delaunay triangulation

The tissue or wall region in the echo images is represented as bright regions due to strong reflection, while the left ventricle cavity or the blood region is a dark region. The contrast enhancement is achieved by brightening the wall region and darkening the blood region, by dividing the echo image into smaller regions and performing non-linear processing in those regions. Dividing the entire image into uniform regions does not work as different regions have to be processed differently. It is also computationally expensive and unnecessary.

Delaunay triangulation, introduced by Boris Delaunay in 1934 is used in this work to divide a surface into triangular regions with common characteristics that are particularly well-suited for image processing applications. This triangulation is performed by using the points or edges obtained from the image. For a set of points, V in a plane, Delaunay triangulation is performed in such a way that there is no point in the circumcircle of the triangles (that is, no point is within the circle passing through three vertices of triangle) in the network.

Delaunay triangulation is advantageous over other meshing based techniques as it maximizes the minimum vertex angles of the triangles in the network, so that the triangles formed tend towards equiangular triangles, avoiding sharp and stretched triangles. This triangulation is suitable for interpolation as the pixel values within the region in the final image is directly related to the triangle region in the network. Delaunay triangulation is performed in the heart wall region between the endocardium and the epicardium to divide it into triangular regions and these regions are processed by applying a thresholding technique. This is followed by a processing the blood region on a similar fashion.

2.3.1 Processing tissue or wall region:

To select the wall region for processing, the endocardial and epicardial boundary edges along with 2 other set of edges formed, 3 pixels and 6 pixels away from both the edges are considered as vertices for triangulation. The wall region closer to the edges is divided into smaller regions by forming 2 bands with 3 pixels width from the inner and outer wall and the region in-between them is divided into a comparatively larger triangles. The triangulation performed in the wall region can be seen in Fig. 3(b). The triangles formed in the blood region are not considered for processing in this stage. After performing the triangulation, a thresholding is applied within the triangular region. In the tissue region, a mean based thresholding is applied, which is defined mathematically for a triangular region $I_i(x, y)$ as

$$I_i(x, y) = \begin{cases} I_i(x, y) + \frac{M_i}{5} & \text{if } I_i(x, y) \leq M_i \\ I_i(x, y) & \text{if } I_i(x, y) > M_i \end{cases} \quad (2)$$

where $I_i(x, y)$ and M_i are the pixel value and the mean of the pixels within the triangular tissue region, x and y are the pixel coordinates. The above representation can be explained as follows. Each pixel within the triangular region is compared with mean of the pixels within the region. If the actual pixel value is less than or equal to the mean, then the pixel value is incremented by 1/5th of the mean, otherwise the pixel is retained.

2.3.2 Processing LV cavity or blood region:

The blood region is divided into triangular regions by considering the center of the LV cavity and the endocardial boundary as vertices for triangulation, followed by thresholding which is defined mathematically for a triangular region $I_i(x, y)$ as

$$I_i(x, y) = \begin{cases} I_i(x, y) - 5 & \text{if } I_i(x, y) \leq M_i \\ I_i(x, y) - \frac{|M_i|}{2} & \text{if } M_i \leq I_i(x, y) \leq M_i + 20 \\ I_i(x, y) & \text{if } I_i(x, y) > M_i + 20 \end{cases} \quad (3)$$

where $I_i(x, y)$ and M_i are the pixel value and the mean of the pixels within the triangular blood region, x and y are the pixel coordinates. In other words, if the actual pixel value is less than or equal to the mean, then the pixel value is decremented by 5. If the pixel lies between the mean M_i and $M_i + 20$, then the pixel value is decremented by half of the mean. If the pixel is greater than $M_i + 20$, the pixel is retained so that the heart wall tissue structure if encountered while processing the blood region, will not be affected. The contrast improvement is performed based on the local information so that weak regions (lateral wall region) of the image are enhanced more than strong regions (top and bottom wall region).

The new modified image is reconstructed as follows:

$$I_{\text{modified}}(x, y) = (P_1(x, y) + P_2(x, y)) / 2 \quad (4)$$

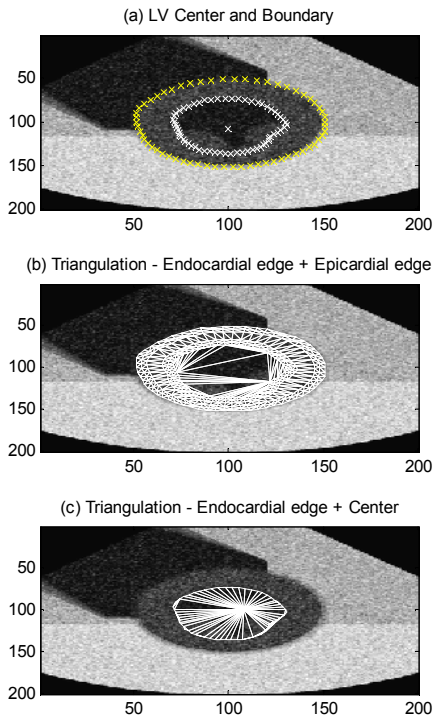


Fig. 3 Shows the different stages in enhancement step for the synthetic Short Axis heart image. (a) Original image with extracted LVCP and wall boundary, (b) Delaunay triangulation for only the wall region (using the extracted wall boundaries) and (c) triangulation for the blood region region (using the extracted inner wall and center)

where $P_1(x, y)$ is the image after processing the wall region and $P_2(x, y)$ is the image after processing the blood region in the original image. Averaging the processed images is performed to reduce the effect of incorrect modifications to the anatomical structures if an incorrect boundary is detected.

3. EXPERIMENTAL RESULTS

This section presents experimental results of the system for automated diagnosis of abnormal wall motion. Echo images can be recorded in different views, each of which is important to identify critical parameters to evaluate different heart conditions. Here, short axis view (SA) and long axis (LA) views are considered. The echo movies are captured over a time period; to cover a complete cardiac cycle consists of an average of 25 frames. The number of the radial lines used for edge detection in one frame is empirically selected as 60. Synthetic images models and real image data are used for the experiment. Synthetic images are generated using the method used in [8] and consists of 25 frames of 400 x 400

images. The pixel value in the image varies from 0 and 128 which is defined using Rayleigh distribution with different reflectivity factor for the reflected ultrasound signal due to

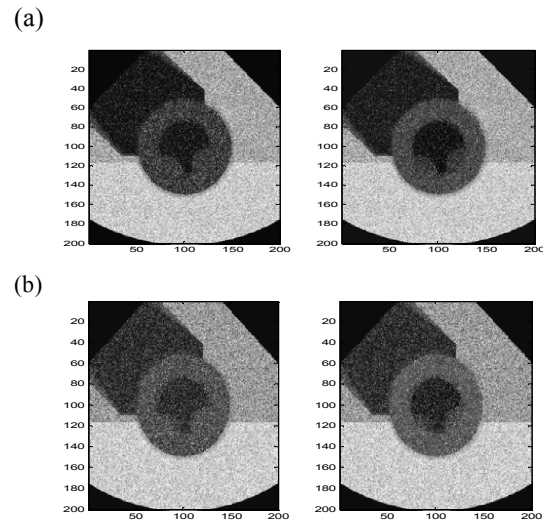


Fig. 4 Synthetic Short Axis image (left) and enhanced image showing the contrast improvement (right).

- (a) $\sigma_1 / \sigma_2 = \sigma_2 / \sigma_3 = 0.33$ and $\sigma_2 / \sigma_4 = 0.25$.
- (b) $\sigma_1 / \sigma_2 = \sigma_2 / \sigma_3 = 0.5$ and $\sigma_2 / \sigma_4 = 0.33$.

blood, heart wall and tissue other than heart. A Rayleigh distribution with reflectivity factor σ is given as

$$R(n) = \left(\frac{n}{\sigma^2} \right) \exp \left[-\frac{1}{2} \left(\frac{n}{\sigma} \right)^2 \right] \quad (5)$$

In the first synthetic image, reflectivity factors defined in the left and right ventricular regions representing blood with $\sigma_1=20$, heart wall region with $\sigma_2=40$, tissue outside the heart in the two lateral regions with $\sigma_3=80$ and the lung tissue outside the posterior wall region with $\sigma_4=120$. The relative contrast between the regions is $\sigma_1 / \sigma_2 = \sigma_2 / \sigma_3 = 0.5$ and $\sigma_2 / \sigma_4 = 0.33$. For the second synthetic image, the relative contrast between the regions is $\sigma_1 / \sigma_2 = \sigma_2 / \sigma_3 = 0.33$ and $\sigma_2 / \sigma_4 = 0.25$.

The enhanced image results for the synthetic images are shown in Fig. 4 and the results for the real images (both SA and LA views) are shown in Fig. 5. The images on the left are the original images and the images on the right are the enhanced images. It can be seen that the contrast between the tissue and the blood region is improved and the wall region (which is of diagnostic importance) is well defined in the enhanced images. The contrast resolution (CR) between the tissue region, S_T and the blood region, S_B is measure by [12]

$$CR = (S_T - S_B) / (S_T + S_B)$$

where S_T is the pixel average in a small section of tissue region and S_B is the pixel average in a small section of the blood region.

The CR in a section of the image is measured to give a quantitative measure of the image enhancement, as well as the subjective measure. Table. 1 shows the contrast resolution for sample original images, after applying Median filter, Weiner filtering and the proposed Delaunay triangulation based Enhancement algorithm. From the table, it can be seen that the contrast resolution is improved for the proposed method when compared to the original image, Median and Weiner filter.

Table 1: Comparison of Contrast Resolution measures

Image	Original	Median	Weiner	Proposed
1	0.719	0.716	0.714	0.955
2	0.875	0.877	0.877	0.948
3	0.473	0.478	0.468	0.853
4	0.325	0.349	0.339	0.560
5	0.569	0.584	0.559	0.694

4. CONCLUSION AND REMARKS

In this paper, a novel echocardiography image enhancement algorithm which combines undecimated wavelet based speckle noise reduction, edge detection, followed by a regional enhancement process that employs Delaunay triangulation based thresholding is presented. The algorithm is applied to both synthetic and real image data sets of short axis and long axis view echocardiography sequence. The initial results are encouraging and suggest that this region based enhancement improves contrast near the edges, which are of diagnostic importance. The contrast improvement is performed based on local information so that weak regions of the image are enhanced more than strong regions. This could be beneficial to experts when manually defining the edges for diagnosing purposes and also as a pre-processing stage for the automated analysis of heart function.

ACKNOWLEDGMENT

The authors would like to thank the Cardiology Department of the Western Infirmary in Glasgow for providing the echo images.

REFERENCES

[1] S. Kaddoura, "Echo Made Easy", Churchill Livingstone, (2001).
 [2] D. Gnanadurai, V. Sadasivam, "Undecimated wavelet based speckle reduction for SAR images", Pattern Recognition Letters, 26, pp. 793-800 (2005)
 [3] F. Argenti, G. Torricelli, "Speckle Suppression in Ultrasonic Images Based on Undecimated Wavelets", EURASIP Journal on Applied Signal Processing, 5, 470-478 (2003)
 [4] J. A. Noble, D. Boukerroui "Ultrasound Image Segmentation: A Survey", IEEE Transaction on Medical Imaging, vol. 25(8), pp. 987 - 1010 (2006)
 [5] D. Boukerroui, J. A. Noble, M. Brady, "Feature enhancement in low quality images with application to echocardiography", Lecture Notes in Computer Science; Vol.

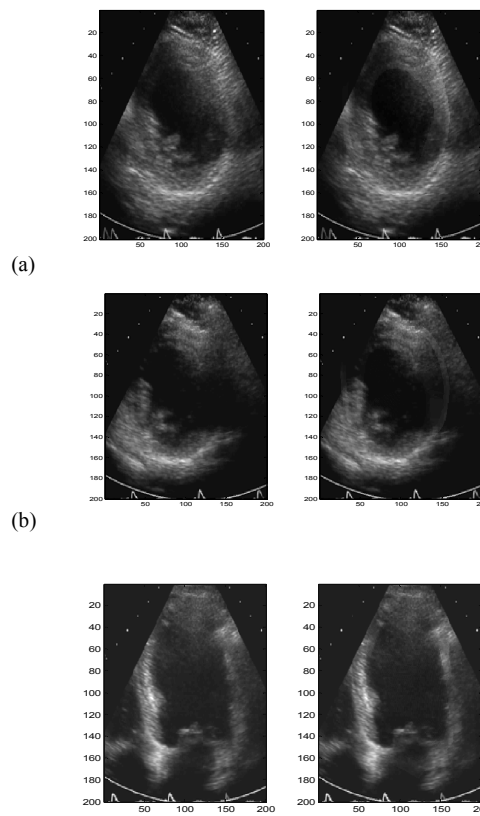


Fig. 5. Sample real images (left) and enhanced image (right) showing the contrast improvement. (a) and (b) are sample short axis view echo images and (c) is a sample long axis view echo image.

2082, Proceedings of the 17th International Conference on Information Processing in Medical Imaging, pp. 453 - 460 (2001)
 [6] X. Zong, A. F. Laine, E. A. Geiser, "Speckle reduction and contrast enhancement of echocardiograms via multi scale nonlinear processing", IEEE Transaction on Medical Imaging, vol. 17 (4), pp. 532 - 540 (1998)
 [7] S. K. Setarehdan, J. J. Soraghan, "Automatic left ventricular Center point extraction in echocardiographic images", Signal Processing, 61, pp. 275 -288, (1997).
 [8] S. K. Setarehdan, J. J. Soraghan, "Automatic left ventricular feature extraction and visualisation from echocardiographic images", Computers in Cardiology, 23, pp.9-12, (1996)
 [9] J. R. Shewchuk, "Lectures Notes on Delaunay Mesh Generation," University of California at Berkeley, 1999.
 [10] L. Prasad, A. N. Skourkhine, "Vectorized image segmentation via trixel agglomeration", Pattern Recognition, 39, pp. 501-514,(2006)
 [11] S. Lertrattanapanich, N. K. Bose "High resolution image formation from low resolution frames using Delaunay Triangulation" IEEE Transaction on Image processing, 11(12), pp. 1427-1441, (2002).
 [12] <http://www.nationmaster.com/encyclopedia/Contrast-resolution>