

Mémoire de Maîtrise en médecine

Treatment of Barrett's Esophagus by radiofrequency ablation: a monocentric study

Etudiant

Natalie Geider

Tuteur

Dr med. Gian Dorta, Prof. associé
Dpt de médecine, service de gastro-entérologie et d'hépatologie,
CHUV

Co-tuteur

Dr med. Christopher Doerig
Dpt de médecine, service de gastro-entérologie et d'hépatologie,
CHUV

Expert

Dr med. Nermin Halkic, Docteur PD, MER
Dpt des services de chirurgie et d'anesthésiologie,
service de chirurgie viscérale, CHUV

Lausanne, Novembre 2015

Table of contents:

1. Abstract:	3
2. Acknowledgements	4
3. Introduction	5
4. Methods	6
4.1. Study design.....	6
4.2. Treatment and follow-up:	7
4.3. Data collection and analysis.....	7
4.4. Primary outcomes	7
4.5. Secondary outcomes	8
5. Results	8
5.1. Primary outcome	8
5.2. Secondary outcome	10
6. Discussion	12
7. Conclusion	14
8. Tables and figures	15
9. Bibliography	19

1. Abstract:

Background and aims:

Barrett's esophagus (BE) is a frequent disease. Therapy by radiofrequency ablation (RFA) has been shown in literature to be an effective eradication therapy of BE, with a reasonable frequency of complications. The aim of our study is to compare the efficacy and complications of the treatment of BE by RFA in our center to those of literature, as a quality control.

Methods:

We collected the data of patients who underwent RFA treatment of BE between January 1st 2011 and July 31st 2015. This included 32 patients, 20 of which completed the therapy by the end of the study period. The data was taken from histological and endoscopic medical reports as well as clinical follow-up reports for certain patients. The primary outcome was the efficacy of treatment, including whether there was a complete eradication of intestinal metaplasia (CE-IM) or of dysplasia (CE-D). The secondary outcome was to assess any post-RFA complications. These included progression to adenocarcinoma under treatment, upper gastro-intestinal (GI) hemorrhage, stenosis and pain. We compared our results to those of literature.

Results:

CE-D was achieved in 93.8% of the patients, whereas CE-IM was achieved in 61.1% of the patients. However, there were 11.11% of the patients who only had microislets of residual metaplasia. In a meta-analysis from Orman and al, CE-D was achieved in 91% of patients and CE-IM in 78% of patients. In our cohort, one patient progressed to adenocarcinoma, 4 patients had upper-GI hemorrhage and 2 patients had esophageal stenosis. Of the 17 patients who benefitted from a systematic clinical follow-up, 2 patients had fever after the RFA session and 10 described pain (odynodyphagia, epigastralgia or retrosternal pain). These complications were all previously described in literature.

Conclusion:

The efficacy of radiofrequency ablative therapy of Barrett's esophagus in the University hospital of Lausanne is comparable to that described in literature in terms of CE-D, but not in terms of CE-IM. The post-RFA complications were qualitatively comparable to those of literature.

Key-words:

RFA, radiofrequency ablation, Barrett's, treatment, efficacy, side-effects, intestinal metaplasia.

2. Acknowledgements

I would like to express my gratitude to Prof. Dorta for his guidance and availability during the course of writing my master's thesis, as well as for letting me observe the radiofrequency ablation therapy sessions in the endoscopic center of the University hospital of Lausanne.

Furthermore, I would like to thank Dr. Doerig for his precious time, whether it be in explaining technical procedures, finding relevant articles or correcting thoroughly my text.

I am grateful to Dr. Maillard, who more than once gave me advice on writing my paper.

I would also like to thank Valérie Cerantola for her assistance at setting up the database as well as taking care of the clinical follow-up of our patients.

Special thanks go to Isabelle Noir for her help with all the administrative aspects of my work, as well as her moral support through coffees and wonderful conversations.

Last but not least, I would like to thank my parents Hilda and Ernst Geider for their unconditional support throughout every step of my life, including this work.

3. Introduction

Barrett's Esophagus (BE) is a condition affecting the distal esophagus, in which the esophageal squamous mucosa is replaced by a metaplastic columnar epithelium due to gastroesophageal reflux disease (GERD). The molecular mechanisms behind this change are not yet clear, though several hypotheses have been suggested by different studies. The most prevailing hypothesis is that the damage due to GERD exposes stem cells in the basal layers of the epithelium to acid and bile. The gastric juices in the esophagus stimulate the metaplastic differentiation of these vulnerable basal stem cells.(1) A study suggests that the stem cells might originate from the bone marrow and migrate to the esophagus through the blood circulation in a rat model, though this hypothesis has not been confirmed for human BE(2). The presence of this metaplastic tissue is a major risk factor for esophageal adenocarcinoma, through the sequence of intestinal metaplasia (IM), low-grade dysplasia (LGD) and high-grade dysplasia (HGD). The prevalence of BE is estimated around 1.6% in the general population in Europe(3,4). The estimated risk of cancer in non-dysplastic Barrett esophagus is between 0.12% and 0.33% per year (5). However, according to Curvers and al., LGD progresses into HGD or Esophageal Adenocarcinoma (EAC) at a rate of 13.4% per person-year, as long as the diagnosis of LGD was confirmed by expert pathologists (6), and the risk of progression of HGD to EAC per year is 6%(5). Risk factors for BE are well described in the literature. BE is typically diagnosed in men older than 50, Caucasian, suffering from reflux symptoms. Obesity with a high hip to waist ratio(7) and cigarette smoking seem to also be important risk factors of BE.(8) In order to be diagnosed, BE needs to be clearly visible endoscopically (≥ 1 cm) above the gastro-esophageal junction and confirmed histopathologically from esophageal biopsies.(9). BE's is measured by the Prague classification, in which the circumferential (C) and maximum (M) extent of the endoscopically visualized BE segment are measured(10) The current recommendations for endoscopic screening are patients with chronic GERD symptoms associated to another risk factor for adenocarcinoma, such as being older than 50, of male sex, Caucasian, having a hiatal hernia, an elevated body mass index with intra-abdominal fat distribution, or tobacco use.(8) If this examination is negative for BE, there is no need to investigate more. If intestinal metaplasia without dysplasia is found, endoscopic surveillance should be performed every 3 to 5 years.(8) This measure has been found to be cost-effective by Kastelein and al. in their article on the cost-effectiveness of surveillance of BE.(11) If dysplasia is found, it should be confirmed by a second gastrointestinal pathologist. The grade of dysplasia then determines the type of management. If high-grade dysplasia (HGD) is confirmed, endoscopic eradication therapy is recommended.(8) If low-grade dysplasia is confirmed, Spechler and al recommend either surveillance every 6 to 12 months or endoscopic eradication therapy (8). However, it was shown that this type of surveillance is not cost-

effective.(11) Moreover, a randomized clinical trial showed that the risk of progression of confirmed low-grade dysplasia (LGD) to HGD or adenocarcinoma was much higher in a group of patients under surveillance (26.5%) than in the group of patients treated by endoscopic eradication therapy, in this case radiofrequency ablation (1.5%)(3) Hence, if two pathologists confirm LGD, endoscopic eradication therapy should be offered to the patient as an alternative to a bi-annual or annual surveillance (12).

There are several options for the management of Barrett's Esophagus. These can be pharmacological (proton pump inhibitors), surgical (Nissen fundoplication) or endoscopic. However it has been shown that anti-reflux therapy, whether it be pharmacological or surgical, does not eradicate existing BE or dysplasia. (13).

The RFA system (Covidien, Sunnyvale, CA, USA) is an ablation technique using ultra-short pulse radiofrequency energy. This ablation will reach a depth of maximum 1mm, which preserves the submucosa, thus preventing complications(14,15) Different catheters can be used depending on the size and disposition of the BE : Barrx™ 360 RFA Balloon Catheter, Barrx™ 90 RFA Focal Catheter, Barrx™ 60 RFA Focal Catheter, Barrx™ Ultra Long RFA Focal Catheter and Barrx™ Channel RFA Endoscopic Catheter. In a meta-analysis from Orman and al, CE-D was achieved in 91% of patients and CE-IM in 78% of patients who underwent treatment by RFA.(16)

4. Methods

At the University hospital of Lausanne, the division of gastroenterology and hepatology has been offering to treat BE with radiofrequency ablation (RFA) since 2011. In this paper, we compare the primary and secondary outcomes of our patients to those of the literature, as a quality control of our interventions. The primary endpoint was to assess the efficacy of treatment of BE by RFA in our center and the secondary endpoint was to report the complications of treatment.

4.1. Study design

This retrospective study was conducted in the division of gastroenterology and hepatology of the University hospital of Lausanne, Switzerland. The protocol was approved by the cantonal ethics committee for research on human (CER-VD). This allowed us to collect the data of patients between January 1st 2011 and July 31st 2015. The database was based on the medical files of the patients, including endoscopic reports, histology reports, anesthesiology reports and any related document in the medical file.

All patients with BE, treated by RFA between January 1st 2011 and July 31st 2015 in our center were included. All the patients who underwent a treatment by RFA were included in the

secondary outcome results. Only the patients who finished therapy were included in the analysis of the primary endpoint result.

4.2. Treatment and follow-up:

Typically patients with long segment Barrett's disease (> 3cm) were treated with a first treatment with Barrx™ HALO 360°, and would have additional treatments with Barrx™ HALO 90° or through the scope RFA. There was generally a period of 3 months between treatment sessions or before an endoscopical follow-up. For very small residual zones of residual metaplasia, HALO 90° or Argon plasma was used to the discretion of endoscopist. However, we did not follow a systematic therapeutical protocol as every patient had a different profile and treatment procedure evolved during the time course (i.e. some had EMR or Argon therapy before the RFA, some alternated between RFA and EMR and some had RFA without any other endoscopical treatment associated). From March 2012, patients followed a meal and pharmaceutical protocol following treatment with RFA. This consisted in a liquid diet 24 hours post-intervention followed by a soft diet for two days (according to the patient's own comfort). Each patient was given a prescription for 40 mg Esomeprazol 2x/d (standard dose PPI BID) and Ranitidin 300 mg, as well as 1 g Paracetamol effervescent tablets max. 4x/d p.r.n. and Tramadol drops 100 mg/ml, 10-20 drops max. 4x/d p.r.n. A clinical follow-up was organized for certain patients from March 2012.

4.3. Data collection and analysis

We collected data between January 1st 2011 and July 31st 2015. In the database, we included the following variables: age, sex, BE initial length, histological grading (intestinal metaplasia (IM), low-grade dysplasia (LGD), high-grade dysplasia (HGD)) endoscopic resection before and after RFA treatment (with its histology), complete eradication of dysplasia (CE-D) or metaplasia (CE-IM), number of treatments before eradication, recurrence of intestinal metaplasia, dysplasia or adenocarcinoma, treatment complications. The duration of therapy was defined by the first treatment date to the first follow-up with negative biopsies for dysplasia and/or metaplasia. Treatment duration considered patients achieving CE with or without recurrence in between (successful therapy at the end of follow-up). For the patients who failed complete eradication we considered the duration between the first therapy and the last follow-up biopsy before the decision to stop treatment. For the patients who underwent a surgical esophagectomy, the duration was the time between the first treatment and the surgery. Non-responders to treatment were defined as patients who did not achieve the expected reduction of the visible Barrett's esophagus as well as histological after treatment by RFA, and for which the treatment was discontinued, as the risks of treatment were more important than the benefits of the treatment.

4.4. Primary outcomes

The primary outcome of the study was to assess the efficacy of the therapy of BE and neoplasia in our center. This was done reviewing the macro- and microscopical reports before and after

therapy. Treatment efficacy was described as « the absence of IM on endoscopy and histology after RFA »(16) in the case of CE-IM ; and for CE-D, as « the absence of dysplasia on histology»(16)

4.5. Secondary outcomes

The secondary outcome of the study was to report complications in patients who underwent radioablation therapy. These included minor complications such as fever or pain, and major complications such as stenosis, hemorrhage or progression to adenocarcinoma.

5. Results

The demographics of the patients are shown in Table 1. All the patients who underwent an RFA of BE or neoplasia in our center were Caucasian. There were 4 women and 28 men. The average age was 61.1 years old. All patients were over 40 years old, except for one patient who was 26 years old at the time of his first RFA treatment. This particular patient had a congenital diaphragmatic hernia in his medical history. On average our patients were overweight with a mean BMI of 26 kg/m². Thirteen patients had hiatal hernias, and 4 patients had esophageal alteration. These alterations were prior esophageal surgery in one case, a gastric ring in another case, one patient with an unclear lower esophageal congenital malformation and the congenital diaphragmatic hernia mentioned above. According to the Prague classification (10), the mean length was 4.5cm for circular (C) Barrett's and 6.1cm for the mean maximum (C+M) length . Three of our patients had IM without dysplasia at diagnosis, 20 had LGD and 9 had high-grade dysplasia. Twelve patients were treated by EMR before RFA and 6 patients required EMR during the course of the RFA treatment period. As for argon plasma coagulation therapy, one patient was treated before RFA and 11 were treated during the RFA therapy period. The mean duration of therapy was 12.3 months, the longest therapy lasting 37 months, but with only two treatments by RFA. This patient had a CE-IM and CE-D 3 months after the first RFA session, but then had a recurrence of metaplasia after 22 months. After a second RFA 34 months after the beginning of the treatment, he achieved CE-IM, which gives a total of 37 months. The shortest duration of therapy was 10 days. In this case, the patient suffered from a post-RFA hemorrhage, which led to an emergency esophagectomy (see complications).

5.1. Primary outcome

Figure 1 shows the general outcome of the patients included in the study. Between January 1st 2011 and July 31st 2013, 32 patients with BE or neoplasia underwent an endoscopic treatment by RFA in the Centre Hospitalier Universitaire Vaudois. Of these 32, 12 still had interventions planned after July 2015. Two patients were treated surgically after RFA (one for an esophageal

adenocarcinoma, the other for esophageal hemorrhage post-RFA). Two patients were non-responders to the therapy and it was decided to discontinue ablative treatment. Three patients had a CE-D but persistent IM. Two patients had a CE-D but residual microislets of metaplasia.

Overall, 61.1% of the patients achieved CE-IM and 93.8 of the patients with dysplasia prior to treatment achieved CE-D. In the two patients presenting IM without dysplasia at diagnosis, CE-IM was achieved in the first patient and persistent IM was present in the second patient after 3 RFA sessions (non-responder). The majority of our patients (11/18) had LGD at diagnosis. Three of these patients had had EMR prior to the treatment by RFA, only one of these three achieved CE-IM, the two other having residual metaplasia by the end of the treatment. Eight patients with LGD at diagnosis did not have prior EMR. Of these 8, seven of which achieved CE-D. Six patients with initial LGD without prior EMR achieved CE-IM, and one had residual microislets of metaplasia. No patients had persistent dysplasia after treatment by RFA. The only patient in our center who developed esophageal adenocarcinoma during the course of the treatment period that required surgery had an initial diagnosis of LGD without prior EMR. Three patients in our center had HGD with EMR prior to RFA therapy. They all achieved CE-IM. Two patients with HGD did not undergo EMR prior to RFA therapy (non-visible lesions). They also did not necessitate EMR during the course of RFA therapy. Both patients achieved CE-D. However, one had microislets of residual IM and the other had frank persistence of IM. In the patients who did not finish treatment by the end of the study, one patient achieved CE-D and was then lost to follow-up for 40 months, time at which there was a recurrence of HGD that was then successfully treated by EMR. His treatment with RFA is still ongoing.

Table 2 shows the detail of the therapy in the 20 patients who completed or discontinued therapy. There was at most one HALO 360° session except for one patient in the fail to treat group who had two 360° sessions. Patients who underwent EMR during the RFA treatment period all had an EMR prior to the RFA therapy except in the case of one patient in the esophagectomy group. None of the patients in the partial eradication and fail to treat groups underwent EMR during the RFA treatment period. The patients with a CE-IM had between 1 and 3 RFA sessions with an average of 1.36 sessions per person. 45.5% of patients with CE-IM results group had an EMR at one point during the therapy. This ranged between 0 and 5 total EMR sessions. (The 2 patients with microislets had 3 RFA sessions, one with a session combining HALO 360° and HALO 90°, the other with a session combining HALO 90° and through the scope technique). The 3 patients with persistent IM underwent between 2 and 3 RFA sessions (1x HALO 360°/pers., between 1-2 HALO 90°/pers.). The 2 patients who were considered failure to treat had 2 and 3 RFA sessions (one session combining HALO 360° and 90°). They did not have any EMR. One of the patients in the esophagectomy group was operated after the first RFA session, which was a HALO 360°. The other patient who had an adenocarcinoma with surgical resection underwent 4 RFA sessions

before the appearance of a pop-up lesion. The average duration of therapy in the CE-IM was 10.8 months, ranging between 2 and 37 months. In the partial eradication group the average duration of therapy was 15 months, ranging between 3 and 33 months. The duration of therapy in the group of patients in whom treatment failed ranged from 0.3 to 24 months.

5.2. Secondary outcome

Table 2 summarizes the complications of RFA of BE in our center. We only had a clinical follow-up of 17 patients. Of these 17, 2 had a fever episode. One of these patients had fever the evening after the RFA session. This was put on the account of the anesthesia, and the following sessions were without any febrile episode. The other had fever 2 weeks post-RFA. She had also had severe pain, which required a high dose of analgesic therapy. Ten out of the 17 patients who had clinical follow-up suffered from some sort of pain. In most cases this was odynophagia or retrosternal pain. Some patients also described epigastralgia and abdominal pain. In most cases these complaints were tolerable with the pain therapy. Two of the 32 patients who underwent RFA therapy had a visible stenosis post-RFA, but only 1 required dilatation. There were 4 cases of post-RFA hemorrhage, only one which required additional measures. These are described in the following section. One patient had a progression to adenocarcinoma during the RFA therapy (see below).

The following section details the complications of RFA therapy for BE in our center.

Patient 1: This patient achieved a CE-D, with persistent microislets of metaplasia after 2 RFA sessions. After 18 months, there was a recurrence of metaplasia, with 2 subsequent sessions of RFA. At the follow up there was an elevated lesion, which was then removed by EMR. The histology showed a little to well-differentiated adenocarcinoma. The endosonographical staging showed a uT1N0Mx. The patient then underwent a Lewis trans-thoracic esophagectomy. The staging post-op was pT2N0. Following this intervention, the patient suffered of post-operative complications (anastomosis leakage, broncho-gastric fistula, leading to revision surgery as well as enterococcus pneumonia).

Patient 2: After 3 sessions of RFA leading to CE-D and CE-IM for 28 months, the patient had a recurrence of microislets of LGD and 2 months later a progression to HGD. This led to further RFA sessions (the patient was still in treatment by the end of our study period).

Patient 3: 8 days post-RFA (HALO 90°), this patient felt faint and had retrosternal pain. He was transferred to the ER, where melena was observed. An emergency gastroscopy confirmed distal esophageal bleeding in the area of the previous RFA treatment. The bleeding could not be stopped by endoscopical means. In the presence of a severe hemorrhagic shock (Hemoglobin

40g/l after 4 red blood cells transfusions), an emergency esophagectomy was performed. Failure to identify a GI bleeding led to very late endoscopy in this patient

Patient 4: This patient had a history of repaired congenital diaphragmatic hernia. This was a patient with a very symptomatic GERD, with regular pain pre-therapy. He underwent 3 RFA sessions, each followed by certain complications. Session 1: Combined HALO 360° and 90°, there was some light bleeding which spontaneously stopped during the intervention. The patient suffered from odynodysphagia, retrosternal and abdominal pain as well as nausea, inappetence and fatigue after the therapy. He consulted our center 2 weeks post-RFA for these complaints. The patients had not taken the reserve pain medications that were prescribed. We proceeded to do an endoscopic control, which showed a normal status after RFA. We recommended that the patient take the paracetamol as well as tramadol if the pain did not go away with the latter. The patient did not contact us for further complaints. Session 2: After a RFA treatment with HALO 90°, the patient suffered from retrosternal pain during each meal as well as during gastro-esophageal reflux after the treatment. He also had a hard time sleeping, and could not participate in his daily activities. The compliance to therapy was not good, as the patient stopped taking Ranitidin after a few days. We recommended that the patient take the full treatment until the next follow-up. The patient did not contact us for further complaints. Session 3: One month post-RFA HALO 90°, the patient consulted us for brown colored emesis associated with epigastralgia. We performed an emergency thoracic x-ray as well as an endoscopy to exclude a perforation of the esophagus. An upper GI series was organized which showed no signs of perforation or alteration in the esophageal motility. The patient finally discontinued the RFA therapy, as he was a non-responder and had important complications.

Patient 5: Three days after the first RFA session (HALO 360°), this patient suffered from epigastric pain, dyspnoea and emesis as well as melena. The patient was hemodynamically stable and a blood count was done which showed no anemia. We increased the PPI treatment and at a two-week clinical follow-up, the patient still had retrosternal pain and dyspnoea but no new episodes of emesis or blood in his stool. The patient underwent another RFA session at the regular planned interval, and finally achieved CE-IM.

Patient 6: After the 3rd RFA session (HALO 90°), this patient experienced odynodysphagia. Eleven days post-RFA the patient experienced strong abdominal pain during a bowel movement and lost consciousness. He then vomited black blood twice, and at the ER melena was noted after an enema. An endoscopic control showed ulcerations compatible with a post-RFA lesion. The patient was hospitalized for 4 days. An endoscopic follow-up was planned 2 months later. The patient did not have any renewed episode of melena or hematemesis. The patient underwent further RFA sessions, and was not done with the therapy by the end of our study period.

Patient 7: This patient experienced odynodysphagia after the first RFA session (HALO 360°). At the endoscopic follow-up 3 months later, a light stenosis was assessed, which did not require dilatation. The patient achieved CE-IM.

Patient 8: Two days after the first RFA session (HALO 360°), this patient experience dysphagia. An endoscopic control was done which assessed an esophageal stenosis. At the 3-month follow-up, the patient underwent a dilatation of the stenosis without immediate complications. The patient was planned for further RFA session after the end of the study period.

6. Discussion

This paper is the first quality control study for RFA of BE in the Centre Hospitalier Universitaire Vaudois. Due to the prevalence of BE in the population (1.6%), as well as that of the risk factors for BE, it was important for us to assess the efficacy of RFA, to see if our outcome is comparable to that of the literature as a quality control of our therapy. CE-D was attained in 93.8% of the patients, whereas CE-IM was achieved in 61.1% of the patients. However, there were 11.11% of the patients who only had microislets of residual metaplasia. In a meta-analysis from Orman and al, CE-D was achieved in 91% of patients and CE-IM in 78% of patients.(16) Our primary outcome results are comparable to those of literature in terms of eradication of dysplasia. However they differ from those of literature in terms of eradication of metaplasia. This is certainly due to the small number of our cohort, where any failure in the treatment had a major impact on the statistical result, as well as the fact that we did not consider patients with residual microislets of metaplasia as a successful eradication of metaplasia. Importantly, RFA enable an eradication of dysplasia successfully. In several cases the yearly follow-ups were done in private practices after an initial follow-up in our center. Some of these patients were then lost to follow-up for a certain amount of time before coming back into our center for further follow-up. During the study period, treatment protocol was modified according to best current practice. Therefore RFA ablation itself was not always performed identically for a same presentation throughout the study (combined versus sequential RFA with HALO 360+90). The difference between the initial and later protocols might influence the efficacy of the treatment results. After the serious hemorrhagic complication in one of our patients, we decided to ablate only patients with confirmed LGD or HGD or patients with a successful resection of localized adenocarcinoma with residual Barrett. We noticed that patients with esophageal alterations or previous surgeries do not respond as well as the other patients and are more prone to recurrent BE. This has been described in literature in the case of congenital diaphragmatic hernia (17) as well as in partial esophagectomy(18). We also noticed that in patients with prior EMR, the results are not as good as in other groups. However, in the case of prior EMR as well as of esophageal malformation, we still consider that RFA should be the primary treatment option.

As for the secondary outcome, in which we assessed any post-RFA complications, we could not compare our results to those of literature in a quantitative way because of the small number of patients in our cohort. In the literature according to Orman and al.(16). There were two cases of patients who suffered from upper gastro-intestinal hemorrhage in the second week following RFA. In one case the patients suffered from hemorrhagic shock and an emergency esophagectomy was necessary to stop the bleeding. The patient was admitted in a state of shock and the investigations for the cause of the shock delayed therapy. By the time the upper gastrointestinal bleeding was identified, surgical removal of the esophagus was the only possible therapy. Hemorrhagic complications occasionally happen after RFA treatment and were previously described in literature.

We had one case of pop-up lesions after CE-D with persistent microislets of metaplasia during RFA therapy that required surgical management of an esophageal adenocarcinoma. This case is a confirmation of the importance of long-term follow-up even after CE-D, because of the risk of recurrence. In their meta-analysis, Orman and al. noted a recurrence rate of dysplasia of 0.9% and of EAC of 0.7% over 1.5 years after CE-IM. Though this rate is low, surveillance is important because of the impact of EAC(16) especially in patients with initial HGD and no visible lesion. By the end of the study period, stenosis was assessed in two cases (6.7%), one for whom a dilatation was necessary. This result is comparable to that of the literature, which showed a frequency of stenosis post-RFA between 3% and 7%. (16)In our center there were a higher number of patients who were suffering from pain (58.8%), whether it be retrosternal pain, odynophagia or epigastric pain. Literature showed pain in 3% of cases, and in retrospective studies this value was 2%(16). This is certainly due to the fact that in our study we considered all pain reported from the patients who benefitted from a clinical follow-up without distinguishing patients with expected pain after an RFA treatment from patients with exacerbated pain requiring extra management. Prior to the instauration of the systematic post-RFA pharmacological treatment as well as diet recommendations, several patients complained of pain or discomfort post-RFA. After the instauration, we observed less complaints post-RFA.

All the percentages we calculated are just indicative, to help us visualize the different variables. However, these should not be taken as statistically relevant values, since our population as well as our therapy protocol was very inhomogeneous. In our study we did not consider the association of length of initial BE with the efficacy of treatment, the frequency of recurrences or the post-RFA complications. This would be an interesting association to consider in further studies, as literature has shown that the risk of cancer progression correlates significantly with the length of BE(9). As previously discussed, the accurate diagnosis of dysplasia requires an expert pathologist's confirmation. However, this was not done for all the patients we classified as LGD or HGD, since our study period begins before these recommendations were published(8).

Currently the follow-up protocol is well established in our center. However in order to make a statistically relevant study, it would be interesting to make prospective study which would have a fixed protocol of therapy as well as a systematic clinical follow-up to re-assess complications post-RFA. It is also important to consider that there are still a dozen of patients who are currently undergoing treatment of BE by RFA in our center with the more recent treatment and follow-up protocol. Should a long-term study be made, the results might differ from those we present in this paper.

7. Conclusion

The efficacy of radiofrequency ablative therapy of Barrett's esophagus in the Centre Hospitalier Universitaire Vaudois is comparable to that described in literature in terms of CE-D, but not in terms of CE-IM. CE-D was attained in 93.8% of the patients as compared to 91%, whereas CE-IM was achieved in 61.1% of the patients as compared to 78%. The post-RFA complications were qualitatively comparable to those of literature. They included upper gastrointestinal hemorrhage, esophageal stenosis, progression to esophageal adenocarcinoma and pain. The selection of patients who will undergo treatment of BE by RFA is essential, due to the known complications of treatment. In order to have statistically relevant results, a larger scale multicenter study would be necessary.

8. Tables and figures

Table 1 Patient demographics (N=32)		
Age, years	mean \pm SD	61.1 \pm 12.5
	range	26-79
Gender, n (%)	female	4 (12.5%)
	male	28 (87.5%)
BMI	mean \pm SD	26 \pm 4.2
	range	17-36
Hiatal hernia, n (%)		13 (40.6%)
Esophageal alterations*, n (%)		4 (12.5%)
Length of BE, C (Prague Class.) cm	mean \pm SD	4.6 \pm 4
	range	0-15
Total length of BE (C+M Prague Class.) cm	mean \pm SD	6.1 \pm 4.1
	range	1-16
IM at diagnosis, n		3
LGD at diagnosis, n		20
HGD at diagnosis, n		9
Treatment before RFA, n (%)	EMR	12 (40%)
	Argon	1 (3.3%)
Other Barrett's treatment during RFA, n (%)	EMR	6 (20%)
	Argon	11 (36.7%)
Therapy duration, months (excluding patients still in therapy by July 31st 2015)	mean	12.3 \pm 11.5
	range	0.3†-37
*Esophageal malformation, previous esophageal surgery † patient who underwent a esophagectomy 10 days after RFA		

Figure 1 Outcome of patients who underwent an RFA therapy at the CHUV

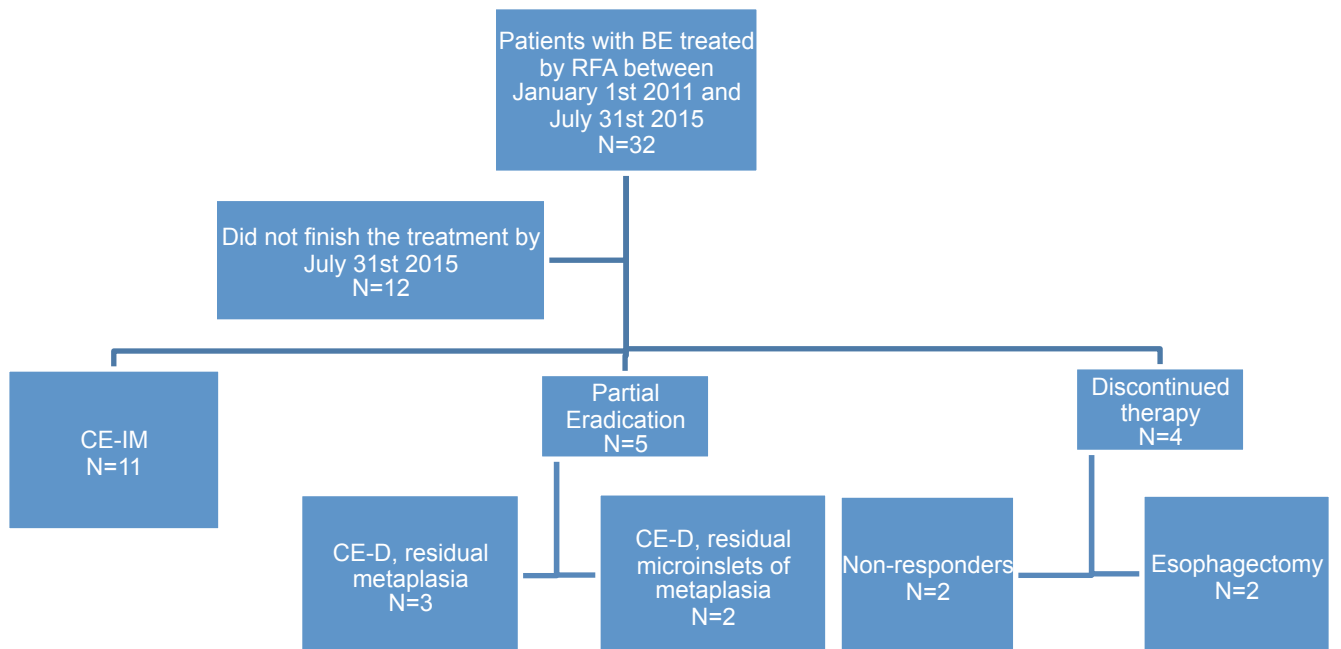
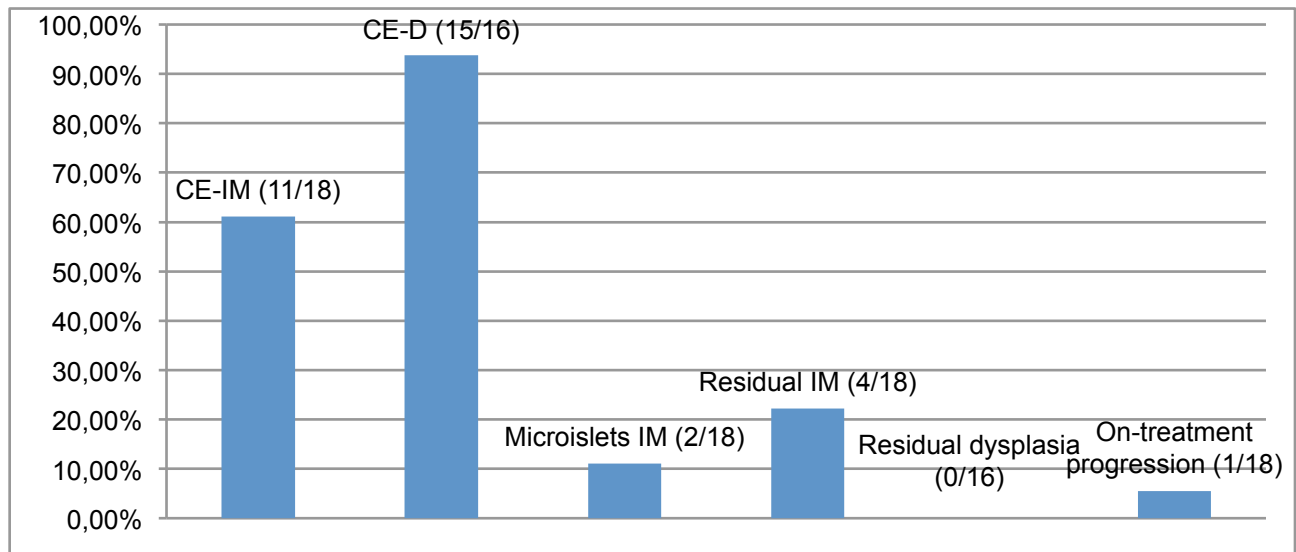


Figure 2 Treatment efficacy in patients with complete treatment, with initial dysplasia (N=16) or without initial dysplasia (N=2)



CE-IM: complete eradication of intestinal metaplasia; CE-D: complete eradication of dysplasia; IM: intestinal metaplasia

Table 2 Complications (N=32)		
Complications	absolute	%
Fever	2	* 11.8
Pain	10	* 58.8
Minor stenosis	1	3.1
Major stenosis	1	3.1
Minor hemorrhage	3	9.4
Major hemorrhage	1	3.1
Progression to adenocarcinoma	1	3.1
Includes patients who did not finish the therapy		
* Of the patients 17 patients who underwent a clinical follow-up		

9. Bibliography

1. Spechler SJ, Fitzgerald RC, Prasad GA, Wang KK. History, Molecular Mechanisms, and Endoscopic Treatment of Barrett's Esophagus. *Gastroenterology*. 2010 Mar;138(3):854–69.
2. Sarosi G, Brown G, Jaiswal K, Feagins LA, Lee E, Crook TW, et al. Bone marrow progenitor cells contribute to esophageal regeneration and metaplasia in a rat model of Barrett's esophagus. *Dis Esophagus Off J Int Soc Dis Esophagus ISDE*. 2008;21(1):43–50.
3. Phoa KN, van Vilsteren FGI, Weusten BLAM, Bisschops R, Schoon EJ, Ragnunath K, et al. Radiofrequency ablation vs endoscopic surveillance for patients with Barrett esophagus and low-grade dysplasia: a randomized clinical trial. *JAMA J Am Med Assoc*. 2014 Mar 26;311(12):1209–17.
4. Ronkainen J, Aro P, Storskrubb T, Johansson S-E, Lind T, Bolling-Sternevald E, et al. Prevalence of Barrett's esophagus in the general population: an endoscopic study. *Gastroenterology*. 2005 Dec;129(6):1825–31.
5. Spechler SJ. Barrett esophagus and risk of esophageal cancer: a clinical review. *JAMA J Am Med Assoc*. 2013 Aug 14;310(6):627–36.
6. Curvers WL, ten Kate FJ, Krishnadath KK, Visser M, Elzer B, Baak LC, et al. Low-grade dysplasia in Barrett's esophagus: overdiagnosed and underestimated. *Am J Gastroenterol*. 2010 Jul;105(7):1523–30.
7. Edelstein ZR, Bronner MP, Rosen SN, Vaughan TL. Risk factors for Barrett's esophagus among patients with gastroesophageal reflux disease: a community clinic-based case-control study. *Am J Gastroenterol*. 2009 Apr;104(4):834–42.
8. Spechler SJ, Souza RF. Barrett's esophagus. *N Engl J Med*. 2014 Aug 28;371(9):836–45.
9. Fitzgerald RC, di Pietro M, Ragnunath K, Ang Y, Kang J-Y, Watson P, et al. British Society of Gastroenterology guidelines on the diagnosis and management of Barrett's oesophagus. *Gut*. 2014 Jan;63(1):7–42.
10. Sharma P, Dent J, Armstrong D, Bergman JJG, Gossner L, Hoshihara Y, et al. The Development and Validation of an Endoscopic Grading System for Barrett's Esophagus: The Prague C & M Criteria. *Gastroenterology*. 2006 Nov;131(5):1392–9.
11. Kastelein F, van Olphen S, Steyerberg EW, Sikkema M, Spaander MCW, Looman CWN, et al. Surveillance in patients with long-segment Barrett's oesophagus: a cost-effectiveness analysis. *Gut*. 2014 Jul 18;
12. Duits LC, Phoa KN, Curvers WL, Ten Kate FJW, Meijer GA, Seldenrijk CA, et al. Barrett's oesophagus patients with low-grade dysplasia can be accurately risk-stratified after histological review by an expert pathology panel. *Gut*. 2015 May;64(5):700–6.

13. Rees JR, Lao-Sirieix P, Wong A, Fitzgerald RC. Treatment for Barrett's oesophagus. *Cochrane Database Syst Rev.* 2010;(1):CD004060.
14. Haidry RJ, Dunn JM, Butt MA, Burnell MG, Gupta A, Green S, et al. Radiofrequency ablation and endoscopic mucosal resection for dysplastic barrett's esophagus and early esophageal adenocarcinoma: outcomes of the UK National Halo RFA Registry. *Gastroenterology.* 2013 Jul;145(1):87–95.
15. Sharma VK. Ablation of Barrett's esophagus using the HALO radiofrequency ablation system. *Tech Gastrointest Endosc.* 2010 Jan;12(1):26–34.
16. Orman ES, Li N, Shaheen NJ. Efficacy and durability of radiofrequency ablation for Barrett's Esophagus: systematic review and meta-analysis. *Clin Gastroenterol Hepatol Off Clin Pract J Am Gastroenterol Assoc.* 2013 Oct;11(10):1245–55.
17. Peetsold MG, Heij HA, Kneepkens CMF, Nagelkerke AF, Huisman J, Gemke RJJ. The long-term follow-up of patients with a congenital diaphragmatic hernia: a broad spectrum of morbidity. *Pediatr Surg Int.* 2009 Jan;25(1):1–17.
18. Wolfsen HC, Hemminger LL, DeVault KR. Recurrent Barrett's esophagus and adenocarcinoma after esophagectomy. *BMC Gastroenterol.* 2004 Aug 25;4:18.