



Tarlov Cyst: A diagnostic of exclusion



Cyril Andrieux^{a,*}, Pietro Pogli^a, Pietro Laudato^b

^a CHUV, Service d'orthopédie et de traumatologie – CHUV, 1012 Lausanne, Switzerland

^b CHUV, Unité Spinale – CHUV, 1012 Lausanne, Switzerland

ARTICLE INFO

Article history:

Received 3 February 2017

Received in revised form 21 July 2017

Accepted 22 July 2017

Available online 25 July 2017

Keywords:

Case report

Low back pain

Sacral perineural cyst

Sciatica

Tarlov cyst

Hip osteonecrosis

ABSTRACT

Tarlov cysts were first described in 1938 as an incidental finding at autopsy. The cysts are usually diagnosed on MRI, which reveals the lesion arising from the sacral nerve root near the dorsal root ganglion. Symptomatic sacral perineural cysts are uncommon and it is recommended to consider Tarlov cyst as a diagnostic of exclusion.

We report a case of a patient with voluminous bilateral L5 and S1 Tarlov cyst, and right hip osteonecrosis to increase the awareness in the orthopaedic community.

A 57-year-old female, in good health, with chronic low back pain since 20 years, presented suddenly right buttock pain, right inguinal fold pain and low back pain for two months, with inability to walk and to sit down.

X-ray of the lumbo-sacral spine revealed asymmetric discopathy L5-S1 and L3-L4. X-ray of the right hip did not reveal anything. We asked for an MRI of the spine and it revealed a voluminous fluid-filled cystic lesion, arising from the first sacral nerve root on both side and measuring 3,3 cm in diameter. The MRI also show a part of the hip and incidentally we discovered an osteonecrosis Ficat 3 of the right femoral head.

The patient was taken for a total hip arthroplasty, by anterior approach. Patient appreciated relief of pain immediately after the surgery. The current case show that even if we find a voluminous cyst we always have to eliminate other diagnosis (especially the frequent like osteonecrosis of the femoral head) and mostly in the case of unclear neurological perturbation.

© 2017 The Author(s). Published by Elsevier Ltd on behalf of IJS Publishing Group Ltd. This is an open access article under the CC BY-NC-ND license (<http://creativecommons.org/licenses/by-nc-nd/4.0/>).

1. Introduction

Tarlov cysts, also known as perineural cysts [1], are type II inner-vated meningeal cysts, cerebrospinal-fluid-filled (CSF) sacs most frequently located in the spinal canal of the S1-to-S5 region of the spinal cord (much less often in the cervical, thoracic or lumbar spine). Tarlov cysts were first described in 1938 as an incidental finding at autopsy [2]. The cysts are usually diagnosed on MRI, which reveals the lesion arising from the sacral nerve root near the dorsal root ganglion [3].

Paulsen reported the incidence of Tarlov cysts as 4.6% in back pain patients (n = 500). Only 1% of back pain patients (n = 500) were symptomatic [4]. The patient may present as low back pain, sciatica, coccydynia or cauda equina syndrome.

Symptomatic sacral perineural cysts are uncommon and it is recommended to consider tarlov cyst as a diagnostic of exclusion, in opposition to the avascular necrosis of the femoral head which is a common diagnosis.

We report a case of a patient with voluminous bilateral L5 and S1 Tarlov cyst, and right hip osteonecrosis, treated in a university hospital in Switzerland, to increase the awareness of this rare entity in the orthopedic community. This work is in line with the SCARE criteria [10].

2. Presentation of case

A 57-year-old female, in good health, with a history of chronic low back pain since 20 years, presented suddenly right buttock pain, right inguinal fold pain and low back pain for two months, with inability to walk and to sit down on the right buttock. The pain was not associated with specific time, posture or activity and it was not relieved by non steroidal anti-inflammatory drugs (NSAID).

Clinical examination at this stage did not reveal any findings at spine; at right hip we found internal rotation limited at 10°, flexion limited at 90°, pain on palpation of the inguinal fold, the greater trochanter. We found also hypoesthesia on the L4 and L5 territory. Walk with lameness discharge of the right leg. Paresis M4+ of the extensors of the right foot associated with pain during testing.

X-ray of the lumbo-sacral spine revealed asymmetric discopathy L5-S1 and L3-L4 (Fig. 1). X-ray of the right hip did not reveal anything (Fig. 2). We asked for an MRI of the spine and it revealed:

* Corresponding author at: Avenue Pierre Decker 4,1012, Lausanne, Switzerland.
E-mail address: cyril.andrieux.sw@gmail.com (C. Andrieux).

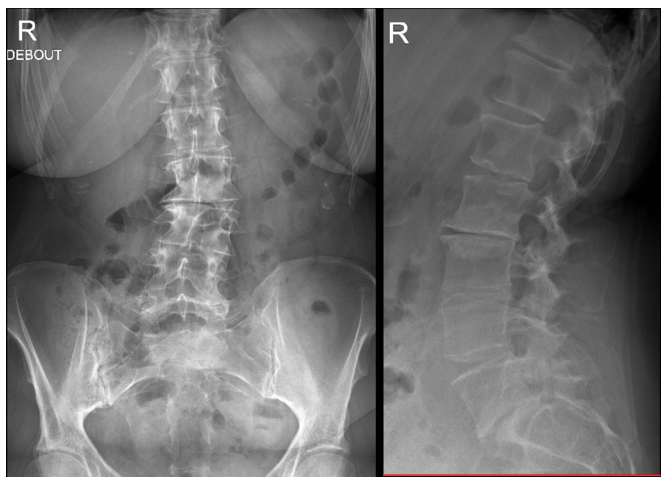


Fig. 1. X-ray of the lumbosacral.

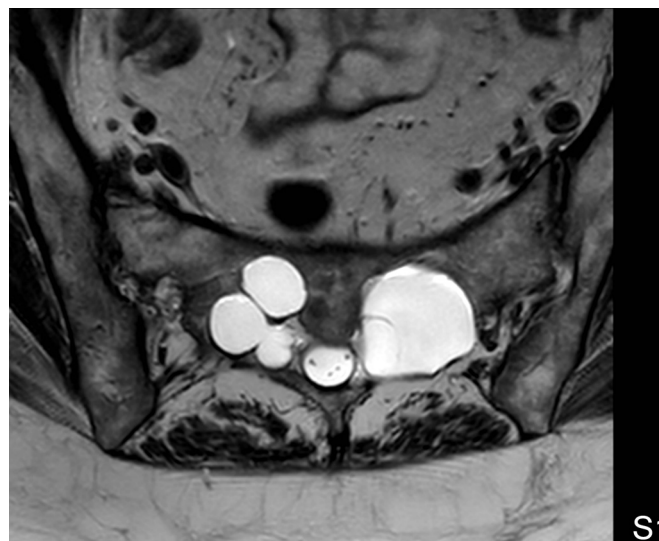

Fig. 4. MRI Axial cut at S1 Level.

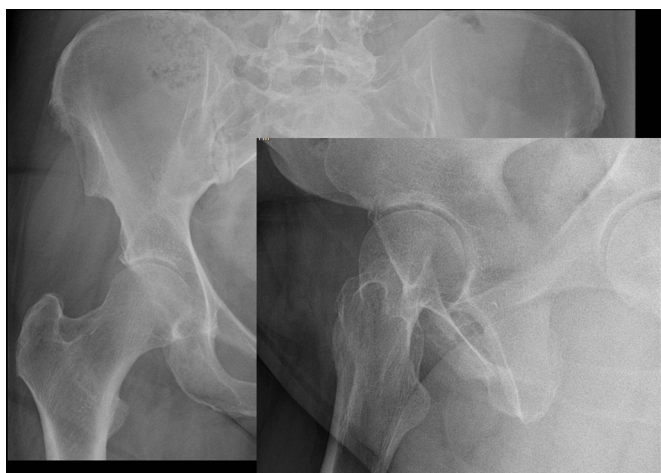

Fig. 2. X-ray of the right hip.

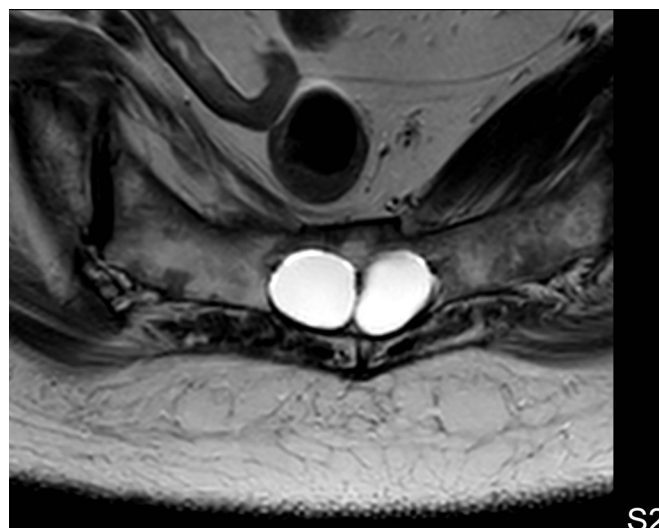


Fig. 5. MRI Axial cut at S2 Level.

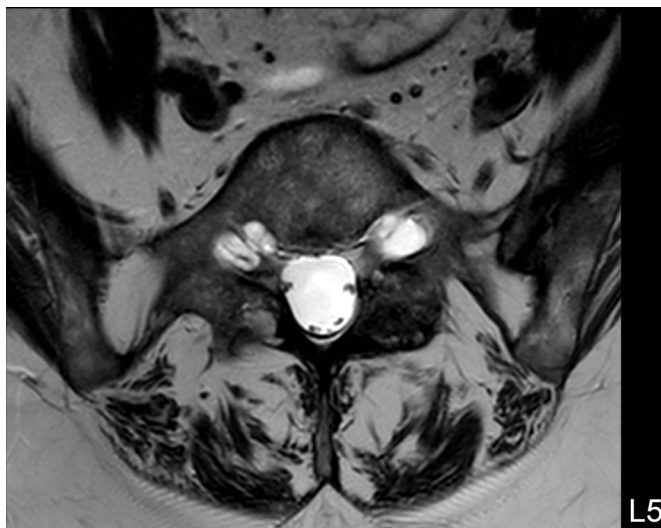


Fig. 3. MRI Axial cut at L5 Level.

- Voluminous fluid-filled cystic lesion, arising from the fifth lumbal nerve root on both side and measuring 1,2 cm in diameter (Fig. 3), from the first sacral nerve root on both side and measuring 3,3 cm

in diameter (Fig. 4) and from the second sacral nerve root on both side and measuring 1,8 cm in diameter (Fig. 5).

The MRI also show a part of the hip and incidentally we discovered:

- Osteonecrosis Ficat 3 of the right femoral head (Fig. 6).

The patient was taken for a total hip arthroplasty, by anterior approach, by an orthopaedic surgeon in a university hospital (Uncemented Stem Symbios SPS evolution, uncemented cup Symbios April, bearing couple ceramic-ceramic) (Fig. 7).

Patient appreciated relief of pain immediately after the surgery. Postoperative period was uneventful and the patient made prompt recovery. On 6 months follow-up, the patient had no pain in lower limbs and back. The patient is back at her job and is asymptomatic.

3. Discussion

Perineural cysts begin in the perineural space, between the endoneurium derived from the pia matter and the perineurium formed by the arachnoidal matter [5]. They happen along the nerve

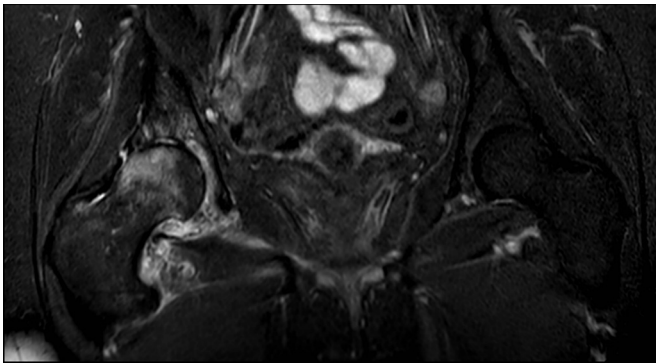


Fig. 6. MRI Coronal cut on the pelvis.

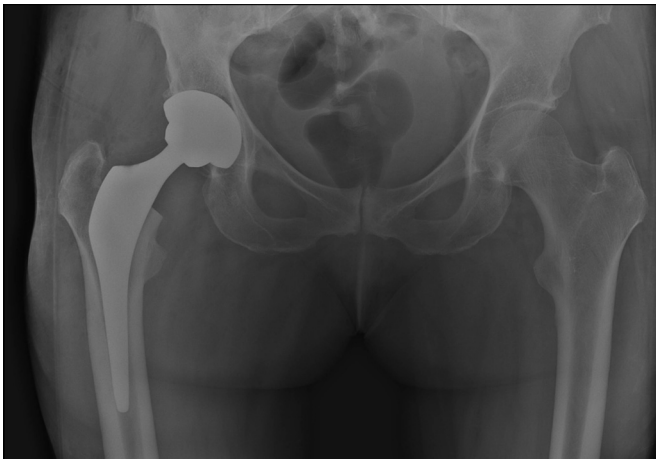


Fig. 7. X-ray on the pelvis after THA.

roots, at or distal to the intersection of the posterior root and the dorsal ganglion [5]. They are regularly found in the sacral spine with a predominance of 4.6% in the overall population [4]. When Tarlov cysts compress the nerve root, they can be symptomatic [5], and those symptoms depend on their location. For instance, the prevailing symptom of a sacral perineural cyst is referable to the caudal nerve roots, either sacral, sciatica, or buttock pain, or sensory changes over the buttocks, perineal area and lower extremity [5].

MRI is currently excellent for the diagnosis of perineural cysts. Findings suggestive of the diagnosis of a perineural cyst are low signal on T-1 weighted images and high signal on T-2 weighted Images [6]. Both Computed Tomography (CT) without contrast and MRI are thought to be good studies for finding extradural spinal masses.

As Tarlov cysts are often incidental findings, three different diagnostic possibilities exist: 1) another pathology is causing the manifestation (the tarlov cyst is not related to symptoms), 2) another pathology is probably causing manifestation, but the Tarlov cyst could be a secondary cause of the symptoms (double phenomenon), or 3) the Tarlov cyst is the only finding that can explain the symptoms. Obviously, we have to be careful when we evaluate the correlation between clinical and radiological findings [7].

In this case we discovered incidentally an Osteonecrosis of the femoral head, but it was not an active research, however this is a common diagnosis [8]: extrapolation from the published data propose an incidence of 0.01% in the German-speaking countries [9]. We found it thanks to the wide range of MRI cut. About symptoms of our patient, low back pain is very unspecific and we should focus

on the right fold pain, which was, in this case, a minor symptom but is a red flag for a hip pathology.

4. Conclusion

The current case show that even if we find a voluminous cyst we always have to eliminate other diagnosis (especially the frequent like osteonecrosis of the femoral head) and mostly in the case of unclear neurological perturbation. However, in the case of our patient we discovered the hip osteonecrosis incidentally and in front of pain of the inguinal fold we should have request immediately an MRI of the hip in addition to the spine MRI, even if she hadn't any risk factors.

Conflict of interest

We have no conflict of interest.
Cyril Andrieux – Pietro Poggia – Pietro Laudato.

Funding

We no funding for this research.
Cyril Andrieux – Pietro Poggia – Pietro Laudato.

Ethical approval

The patient have given us her approval for publish this case report.

Author contributions

Andrieux Cyril: i received the patient at my consultation, i made the diagnose of tarlov cyst and femoral head osteonecrosis ficat 3. I addresss the patient to the hip team (pietro poggia). I decided to published this case.

Pietro poggia: He realized the total hip arthroplasty and followed the patient.

Pietro Laudato: My chief in the spinal unit, he reviewed my submission, and supervised me on this case.

Guarantor

Cyril andrieux: I accept the full responsibility for this work.

SCARE guidelines

Compliant.

Consent

“Written informed consent was obtained from the patient for publication of this case report and accompanying images”.

References

- [1] C.I. Ju, H. Shin, S.W. Kim, H.S. Kim, Sacral perineural cyst accompanying disc herniation, *J. Korean Neurosurg. Soc.* 45 (March (3)) (2009) 185–187.
- [2] I.M. Tarlov, Perineural cysts of the spinal nerve roots, *Arch. Neural Psychiatry* 40 (1938) 1067–1074.
- [3] G.S. Rodziewicz, B. Kaufman, R.F. Spetzler, Diagnosis of sacral perineural cysts by nuclear magnetic resonance, *Surg. Neurol.* 22 (1984) 50–52.
- [4] R.D. Paulsen, G.A. Call, F.R. Murtagh, Prevalence and percutaneous drainage of cysts of the sacral nerve root sheath (Tarlov cysts), *AJNR Am. J. Neuroradiol.* 15 (1994) 293–299.
- [5] I.M. Tarlov, Spinal perineural and meningeal cyst, *J. Neurol. Neurosurg. Psychiatry* 33 (1970) 833–843.

- [6] K. Kim, S.W. Chun, S.G. Chung, A case of symptomatic cervical perineural (Tarlov) cyst: clinical manifestation and management, *Skeletal Radiol.* 41 (2012) 97–101.
- [7] C. Lucantoni, K.D. Than, A.C. Wang, J.M. Valdivia-Valdivia, C.O. Maher, F. La Marca, et al., Tarlov cysts: a controversial lesion of the sacral spine, *Neurosurg. Focus* 31 (2011) E14.
- [8] M.M. Mukisi, K. Bashoun, F. Burny, Sickle-cell hip necrosis and intraosseous pressure, *Orthop. Traumatol. Surg. Res.* 95 (2) (2009) 134–138.
- [9] L. Gullihorn, R. Karpman, L. Lippiello, Differential effects of nicotine and smoke condensate on bone cell metabolic activity, *J. Orthop. Trauma* 19 (2005) 17–22.
- [10] R.A. Agha, A.J. Fowler, A. Saeta, I. Barai, S. Rajmohan, D.P. Orgill, for the SCARE Group, The SCARE statement: consensus-based surgical case report guidelines, *Int. J. Surg.* 34 (2016) 180–186.

Open Access

This article is published Open Access at sciedirect.com. It is distributed under the [IJSCR Supplemental terms and conditions](#), which permits unrestricted non commercial use, distribution, and reproduction in any medium, provided the original authors and source are credited.