


**SAGO HYDROGEL AS DRESSING
FOR PARTIAL THICKNESS WOUND
IN RABBITS**

by

**DR. MOHD. TARMIZI BIN MD NOR
MD(USM)**



**Dissertation submitted in partial fulfillment
of the requirements for the degree of
Master of Medicine (General Surgery)**

UNIVERSITI SAINS MALAYSIA

DECEMBER 2001

Acknowledgements

This dissertation owes its creation to many people, especially my lecturers, fellow colleagues and my family. They were very helpful in guiding and helping me to complete this dissertation.

My special thanks and appreciation to my supervisors Dr. Ahmad Sukari Halim, Associate Prof. Dr. Md. Radzi Johari, Dr Gurjeet Kaur, Dr Afifi Shikh A. Bakar and Dr Mohd Kamal Yatiban for their guidance, advice and their time spent in reviewing and correcting this dissertation. I would also like to thank Dr Syed Hatim Nor, Dr Aryub bin Mohd. Saddiq and Dr. Rosli Abdullah from the Department of Community Medicine for their advice and suggestions in the methodology and statistical analyses for this dissertation. Without their enthusiastic support, this dissertation could not have been completed.

I would also like to thank The Malaysian Institute of Nuclear Technology for providing us a grant for this study and in particular to Dr. Kamaruddin Hashim who has developed this material.

I have been very fortunate to be working under the guidance of other lecturers namely, Dr Abdul Hamid Mat Sain (Head, Department of Surgery), Prof. Madya Dr Hashim Ibrahim, Prof Madya Dr Jafri Malin, Prof. Madya Dr Myat Thu Ya, Dr Myint Tun, Dr Ahmad Zahari, Dr Anas, Dr Zainal Mahmood, Dr Saiful Bahrin Hussin, Dr A. Farouk Musa and Dr Syed Hassan. Great effort and assistance were given to

me during the study by En. Maarof and En Amran from the Animal House, En Ali from the Microbiology Laboratory and Pn Jamaliah Lim from the Histology Laboratory. To all of them I would like to express my thanks and appreciation.

I would not forget the continuous support given by my colleagues, Dr Mohd. Ashraf, Dr Khairuzi, Dr Nor Azam, Dr Vasantha, Dr Bambang and the other members of the surgical department. To others who are not mentioned by name, many thanks are due for their continuous support.

I would also like to record my appreciation to Dr Hasim Mohammad, Dr Nik Mohd Sukri, Dr Imran, Dr Othman, Dr Faisal and Dr Nik Azim from the Department of Surgery, Hospital Kota Bharu, for their guidance during my posting there.

Last but not least, I would like to convey my deepest thanks to my beloved wife, Dr Anees Abdul Hamid and my children who have been very cooperative and understanding in helping me finish the dissertation and to complete the Master of Surgery program.

Preface

For more than a century, the practice of wound dressing has had as one of its major rationale, the prevention of infection and to promote healing. Theoretically, dressing will protect wounds from gross microbial contamination. It also provides pharmacological agents that can play a major role in modifying the microenvironment of the wounds. Beginning in 1960's, new concept of wound healing began to emerge. Scientists found that wounds will heal better in moist environment. Later on, it was found that exudate plays a major role in promoting wound healing by stimulating greater number of fibroblast proliferation. From these observations, various types of dressings using the concept of occlusive dressing appeared in the market such as Vigilon, Duo DERM, Tegaderm and Op-site.

All of them were found to be effective in promoting wound healing, but most of the studies found that they grew bacteria higher than conventional dressing. Although colonization of bacteria was noted to be higher, there was no evidence of wound infection. In earlier days, many surgeons refused to use occlusive dressing because of this reason and also due to the fact that exudative substance appeared like pus. Exudate frightens both medical and pharmaceutical community as well as the public regarding occlusive dressing. However, those negative opinions had changed and at present a lot of wounds are being covered with occlusive dressing.

The problem with occlusive dressings available in the market is their cost which are very expensive and all of them are imported. Taking this into consideration, The Malaysian Institute of Nuclear Technology (MINT) came out with a new product of hydrogel dressing. They called it 'Sago Hydrogel' dressing. The main composition is sago starch, which is easily available in Sarawak especially in the Mukah area. This hydrogel is basically similar to the other conventional hydrogel dressing except for its sago content.

Since this hydrogel is new, The Malaysian Institute of Nuclear Technology (MINT) entrusted us to conduct an animal study to prove its efficacy. We made a comparison between two groups of wounds, one group was covered with Sago Hydrogel and the other group with conventional paraffin gauze (Jelonet®).

Table of contents

Contents	page numbers
I Frontispiece	i
II Acknowledgements	ii
III Preface	iv
IV Table of Contents	vi
V List of Figures	ix
VI List of Tables	xii
VII Abstrak	xiii
VIII Abstract	xv
1.0 Introduction and Literature Review	
1.1 History of wound treatment	1
1.2 Definition of the wound	3
1.2.1 Partial thickness wound	3
1.2.2 Full thickness wound	4
1.3 Definition of wound healing	4
1.4 Moist environment and wound healing	5
1.5 Types of occlusive dressing	7
1.6 Occlusive dressing and bacteria invasion	9
1.7 Pain and occlusive dressing	11

1.8	Uses of occlusive dressing in acute wound	12
1.9	Introduction to hydrogel	13
1.10	Sago hydrogel dressing	14
2.0	Objectives of study	16
3.0	Material and methods	17
3.1	Wound inspection	31
3.2	Wound photography	35
3.3	Microbiological assay	35
3.4	Microscopic examination	35
3.5	Statistical analysis	36
4.0	Result	39
4.1	Macroscopic appearance of the wound	39
4.2	Microscopic examination	48
4.3	Microbiology	53
4.4	Other clinical observation	55
5.0	Discussion	59
6.0	Conclusion	68
7.0	References	69

List of figures

FIGURE	TITLE	PAGE
Figure 1:	Back and both flanks were shaved	19
Figure 2:	Anaesthetic agents were injected intramuscularly (Buttock area)	20
Figure 3:	All procedures were performed under aseptic technique.	21
Figure 4:	The area for wounding was marked with sterile marker	22
Figure 5:	Humby knife sliced skin till 0.6 mm deep to create a partial thickness wound	23
Figure 6:	Wound size was approximately 5X2.5 cm	24
Figure 7:	The wound was swabbed for culture of organism	25
Figure 8:	Swab was inoculated directly on culture media (Blood agar)	26

Figure 9:	Biopsy specimen was taken from the wound, using scalpel blade size 11	27
Figure 10:	The wound covered with Jelonet® (Control dressing)	28
Figure 11:	The wound covered with Sago hydrogel (test dressing)	29
Figure 12:	TG-fixed ® was applied	30
Figure 13:	Swab for culture was taken on the day of inspection	32
Figure 14:	The area of wound that had healed was mapped on sterile plastic	34
Figure 15:	Histology of epidermal and subepidermal region of the rabbit skin	37
Figure 16:	Polymorphonuclear, macrophages, fibroblast and endothelial cells under 400X magnification in the rabbit skin	38
Figure 17:	Gross exudate present after removal of the dressing	41

Figure 18:	Inflammatory exudate still present at day 10 postoperatively	42
Figure 19:	Percentage of clinical wound healing at day 10 postoperatively	44
Figure 20:	Wound healed completely without clinical infection	45
Figure 21:	Percentage of clinical wound healing on post-operative day 14	46
Figure 22:	Graph plotting number of inflammatory cell (median of neutrophils and macrophages) per unit area against days after surgery.	51
Figure 23:	Graph plotting number of proliferative cells (median of fibroblast and endothelial cells) per unit area against days after surgery.	52

List of tables

TABLE	TITLE	PAGE
Table 1:	Number of wounds covered by exudate according to days	43
Table 2:	Mean percentage of clinical wound healing according to day	47
Table 3:	Differential Cell counts Median Values and Statistical Test of cells in the wound	50
Table 4:	Types of organism isolated at day 10 postoperatively	54
Table 5:	Types of organism isolated at day 14 postoperatively	57
Table 6:	Types of organism isolated at day 21 postoperatively	58

ABSTRAK/ABSTRACT

Abstrak

Pada masa kini bergai jenis pembebat luka kedapatan dipasaran. Banyak kajian menunjukkan pembebat yang berjaya mempertahankan kelembapan pada permukaan luka dapat menyembuh luka dengan lebih cepat. Semua nya dihasilkan dari negara luar. Oleh hal demikian Malaysian Institute of National and Technology telah menghasilkan pembebat dari jenis tersebut yang dihasilkan dari sago.

Tujuan penyelidikan ini adalah untuk menilai Sago hydrogel:

- 1: Dapat digunakan sebagai pembebat luka
- 2: Dapat menggalakkan proses penyembuhan luka dengan kadar lebih baik berbanding dengan pembebat standard
3. Dapat menghalang jangkitan kuman keatas luka pembebat standard

Dua belas ekor arnab dari baka New Zealand telah digunakan. Arnab tersebut telah dicukur di kedua-dua bahagian belakang. Secara rawak, satu bahagian diletakkan selapis pembebat sago hydrogel dan di sebelah lagi diletakkan tiga lapisan pembebat gause berparaffin (Jelonet®) . Pemeriksaan luka dilakukan pada hari ke 4, 10, 14 dan 21 selepas pembedahan. Swab untuk kultur dan biopsi telah diambil pada hari yang sama. Secara klinikal, luka mula sembuh pada hari ke 10. Ianya juga menunjukkan tiada perbezaan diantara kedua-dua jenis pembebat luka dari segi klinikal. Histologi menunjukkan sel proliferaatif (endothelial dan fibroblas) tiada menunjukkan perbezaan signifikan. Tiada kejadian morbiditi berlaku kepada

kedua-dua kumpulan. Di peringkat awal, banyak exudat kelihatan menutupi luka di bawah pembebat sago hydrogel. Jangkitan klinikal tidak dikesan pada kesemua luka. Mikrobiologi menunjukkan luka yang ditutupi dengan pembebat sago hydrogel mempunyai koloni gram positif pada peringkat awal. Ianya berubah ke mikroorganism dari jenis gram negatif. Walaubagaimanapun, koloni ini tidak menyebabkan jangkitan klinikal. Pembebat luka sago hydrogel senang ditanggalkan. Semasa menanggal pembebat, haiwan tidak memerlukan analgesik tambahan.

Kesimpulannya, pembebat sago hydrogel boleh digunakan sebagai pembebat luka yang standard kerana tiada perbezaan dari sudut penyembuhan luka dari segi histologi dan klinikal. Tiada bukti berlaku jangkitan klinikal pada luka yang ditutupi dengan sago hydrogel dan juga luka yang ditutupi oleh pembebat standard meskipun terdapat organisma.

Abstract

Brief background.

At present there are various wound dressing available. Occlusive dressing is believed to promote better wound as healing compared to dry dressing. However, all the occlusive dressings available are not produced locally. In an attempt to promote our local, The Malaysian Institute of Nuclear Technology (MINT) has come out with a sago starch based occlusive dressing.

The aims of this study are:

1. To assess whether locally produced hydrogel is useful as a wound dressing
2. To assess whether it has any advantages over conventional dressing
3. To determine tissue response and infection control properties of the locally produced hydrogel used as wound dressing infection in comparison with paraffin gauze dressing.

Twelve healthy New Zealand rabbits were used based on 2 proportional sample size calculation. The rabbit's were shaved at both flanks. One side was randomly dressed with a single layer of Sago Hydrogel and the opposite side dressed with three layers of paraffin gauze (Jelonet®). Wound inspection was done at day 4, 10, 14 and 21 postoperatively. Swabs for culture and biopsies were taken during wound inspection. Clinically, the wound started to heal at day 10. Wound inspection revealed no clinically significant difference between both types of dressing. Histologically, proliferative cells (endothelial and fibroblast) were not

significantly different. No morbidity was noted in both groups. At the initial stage, more exudates were seen in wound covered with Sago Hydrogel dressing. All wounds covered by both dressings were free from clinical infection. Microbiologically, wound covered with Sago Hydrogel grew gram positive organisms at an early stage, but at later time shifted to gram negative microorganisms. This colonization did not cause any clinical infection. Sago Hydrogel dressing was easily peeled off. During removal of Sago Hydrogel dressing, the animal did not require any extra analgesic.

In conclusion, Sago hydrogel dressing can be used as a conventional dressing because there was no significance difference in histological (proliferative and granulation tissue) changes and clinical wound healing. There was also no evidence of clinical infection on the wounds, which were covered by Sago hydrogel as compared to wound covered by conventional dressing.

INTRODUCTION AND LITERATURE REVIEW

1.0 INTRODUCTION AND LITERATURE REVIEW

1.1 History of wound treatment.

Since the prehistoric era, man has discovered the use of a variety of wound coverings by trial and error. They probably observed that the wound had less bleeding, became less painful and healed faster when bandaged. At that time leaves and grass were often used.

The first written records which contained information on early wound management dated back to about 2500 BC (namely clay tablets used in Mesopotamia). They used bandage made from cotton and linen. Later, in 1650 BC the Egyptian's surgeon discovered that the closed wound healed faster than an opened wound. They invented the adhesive bandage by applying gum to linen strips and using it to draw wound edge together.

Hippocrates (460-377 BC) advised that the wound should be exposed. He suggested that, contused wound should be treated aggressively in order to remove necrotic tissue and reduce inflammation. This teaching further emphasised the humoral theory of disease in the mind of physicians. On the other hand, Accilius Cornelius (7BC-AD37) recommended the importance to control bleeding. Application of cobwebs was used to stop ooze from wounds, whereas more active bleeding were filled with dry pledgets following which moist sponges were used to

press over the wound. Claudius Galen (129-200) also used cobwebs and red clay on the dressing.

Paulus Aegineta's seven volume 'Epitome's (607-690) summarised medical knowledge after Galen. He advocated using a sponge or wool squeeze of wine, vinegar as dressing for wounds. Theodoric (1205-1296) proposed that the common practice of promoting suppuration in a wound by probing, packing and dressing was contrary to natural wound healing and actually prolonged the healing process. He advocated that wounds should be kept dry.

Guy de Chaulic (1300-1368), one of the most important medical figures of the medical period reasserted Galen's teaching. He recommended use of plaster. He also proposed principles of wound treatment: removal of foreign bodies, reapproximation of separated parts, maintenance of their apposition, conserving of substance and the treatment of complications.

Two hundred years later, Cesare Magati (1579-1647) advocated bandaging wounds with plain woven, which was changed only after six days. Later Vincenz Van Kern (1760-1829) improved wounds care by using bandages moistened with water.

In 1779, Thomas Baynton published methods in management of ulcers by applying overlapping strip of adhesive and covering the area with a soft cotton bandage. In case of inflamed ulcers, cold water was poured on the outside of the dressing. In

early 1950, investigators began to realise that blistered skin would reepithelize more rapidly if the blister roof was left intact, and the dead epidermis that form the roof of blister functions as a dressing. Later experiments on animals (Winter, 1962) as well as on human (Hinman & Maibach; Winter & Scales, 1963) supported these findings (Forrest 1982).

1.2 Definition of a wound

A wound can be defined as a bodily injury caused by physical means, which lead to disruption of the normal continuity of the structure. For cutaneous wound it can be divided into:

1.2.1 Partial thickness wound.

It is produced when the epidermis and some portion of the dermis are lost. This type of wound are commonly created by shave excision, curettage and electro-degradation, dermabrasion, chemical peels and CO₂ laser surgery. Healing in case of partial thickness wound progresses relatively quickly with re-epithelization by keratinocytes from wound edges and adnexial structures. The amount of granulation, wound contraction, and scarring in the wound depends on the depth of dermal injury. Scarring may be minimal if injury is very superficial or clinically obvious if injury involves deeper portion of the dermis.

1.2.2 Full thickness wounds.

It is created when both the epidermis and full thickness dermis are lost, revealing subcutaneous fat. This type of wound will be created by full thickness excision or severe injury to the subcutaneous area. Such wound, will heal by secondary intention. This type of wound will heal slower than partial thickness wounds and subsequently with ugly scar.

1.3 Definition of wound healing

The response to injury has been divided into three overlapping phases: inflammation (early and late phases), granulation tissue formation and matrix formation and remodelling (Richard & Denver, 1985).

During inflammatory phase, blood vessel disruption leads to the extravasation of blood constituents and concomitant platelet aggregation, blood coagulation and generation of bradykinin and complement. Activated platelets trigger cell migration to the site of injury. Neutrophils are considered to be the first leukocyte to infiltrate an area of inflammation and injury, however it has been shown that monocytes begin to emigrate at the same time. Both types of phagocytes digest pathogenic organisms and tissue debris.

Granulation started at day three, consist of macrophages, fibroblasts, fibrin and neovasculature in a loose matrix of collagen. Fibroblast and fibrin proliferate into the wound space and followed by deposition of loose cellular matrix.

Re-epithelization occurs within hours after injury by movement of epithelial cells from the original edge of the wound

The third and final phase of wound healing is matrix formation and remodelling. This phase overlaps with previous phases (Richard et. al 1985 & Cho et. al. 1998).

1.4 Moist environment and wound healing

Moist environment is found to accelerate wound healing as compared to dry environment. Moist wounds epithelialized more rapidly than dry wounds. Studies have shown that there was only about half as much new epidermis under the normal dry scab as compared to moist dressing (Winter. 1963). The explanation for this finding that, when the wound was exposed to the air (no dressing was used), the wound covered by a dry serous scab within 24 hours. Within the dermis under the wound, extravasated polymorphonuclear leukocytes migrate upward and accumulate within fibrous tissue immediately below wound surface. Migration of epidermis from hair follicles and the wound edges has just begun at 24 hours. The moving sheet of epidermal cells passes through the fibrous tissue below the leucocytic layer. Therefore a superficial layer of the fibrous tissue of the dermis is included in the scab above the new epidermis. On the other hand, when the wound

is kept moist under an occlusive dressing, epidermis migrate through the serous exudate on the wound surface above the fibrous tissue of the dermis. A normal scab including fibrous tissue is not formed, and therefore the leukocytes migrate out from the dermis into the exudate. In contrast to the normal dry wound the original wound surface is below the new epidermis.

Comparison of the effect of moist and dry conditions on dermal repair was studied by Mary et al. (1988). They observed that, 3 days after injury there were 90% more macrophages and 50% fewer neutrophils in the moist wound than the dry wounds. They suggested that there was an acceleration of the inflammatory phase of repair in the moist wound, or that the late inflammatory phase began more rapidly. The presence of significantly more fibroblast cells which is a characteristic of the proliferative phase of the repair, in moist than the dry wound by 3 days after injury also indicate an accelerated healing process. At day 5, the re-epitheliazation was delayed in dry wound associated with the presence of wound debris, which appeared to be impeding epidermal advance. Dry environment may induce further local damage after surgically induced injury. At day 7 there were decrease in number of neutrophils, and increase in the number of fibroblasts and blood capillaries in the moist wound when compared to dry wound. This suggests that the healing advanced into the proliferative phase, when the granulation tissue, rich in fibroblast and blood capillaries developed. On day 10 of injury, moist wounds was completely covered by a fully differentiated, keratinized stratified squamous epithelium; whereas in the dry wound, epithelization was still incomplete and the

dressing were often adherent to the scab. Total cell count was still higher in the moist wound due to the higher fibroblast count.

There is a lower total cell count in moist wounds than in dry wounds by 28 days after surgery, which may suggest a more rapid remodelling phase in the former. In conclusion, moist wounds heal more rapidly compared to dry wound.

Young et al. (1991) noted that cell characteristic of the inflammatory phase (polymorphonuclear and macrophages) decreased in relative number from 5 days to 60 days; whereas the proportion of proliferative phase cell (fibroblast and endothelial cells) increased from 5 to 21 days. The number of fibroblast decreased from 7 days onwards as the phase of repair moved from proliferation phase to remodelling in semi-occlusive permeable dressed wounds.

In average, contraction of wound is better in occlusive dressing compared to gauze dressing. Occlusive dressing had shown faster contraction at 2 weeks compared with ordinary dressing. (Hien et al., 1988)

1.5 Types of occlusive dressing.

To keep a moist environment, occlusive dressing should be used. Currently, several types of occlusive dressings and powder are available. They can be classified into few groups like polymers, biomembranes, hydrogels, hydrocolloids

and absorbers. Although quite dissimilar clinically and physically, they all have one mission in common: keeping the ulcer surface moist.

Types of occlusive dressing include:

1. Polymers

-Polyvinylidene e.g. Soran Wrap

-Polyethylene e.g. Glad Wrap

-Polyurethane e.g. Op-site. Tegaderm

2. Biomembranes

-Amnions

-Xenograft

3. Hydrogel of water and polyethylene oxide reinforced with polyethylene film

-Vigilen

4. Hydroactive particles in hydrophobic polymer

-DuoDERM dressing

5. Absorbing polymer

-Dextran polymer

-DuoDERM granules

-Graft copolymer starch

1.6 Occlusive dressing and bacterial invasion.

As discussed previously, occlusive dressing will keep the wounds moist. In the past people feared to use occlusive dressing for the reason of infection.

Mertz et al. (1986) suggested that infections are probably due to:

1. Proliferation of micro-organism that occur on normal skin beneath occlusive dressing
2. Anti microbial effect of tissue desiccation (tissue desiccation is specifically avoided by occlusive dressing)
3. Suppurative exudate that frequently occurs in occlusive dressing.

In addition, occlusive dressing provides an environment that is conducive to the growth of residence and pathogenic bacteria. Because of that, Katz et al. (1986) suggested that extreme caution must be taken in using occlusive dressing for extended period. Bacterial proliferation with infection clearly can occur, particularly with prolonged occlusion.

In contrast to the above findings, Mertz et al. (1986) claimed that occlusive dressing may protect a wound from invasion by pathogenic bacteria, assuming that the organism responsible for many wound infections are delivered to wound site from exogenous source. In his study, he found that at least normal flora will usually be found in wound covered by occlusive dressing.

Gilchrist & Reed et al. (1989) found that in cases of chronic ulcers, occlusive dressing maintained fairly stable microbial flora.

Madden et al. (1989) found that none of the donor site of partial thickness wound covered with occlusive dressing develops clinical infection. In cases of occlusive dressing, final swab cultures revealed pathogenic organisms such as *Staphylococcus aureus* compared to before dressing, which grew *Staphylococcus epidermidis*. None of the donor site dressed with occlusive dressing develops cellulitis, whereas six out of twenty patients treated with fine mesh gauze developed surrounding donor site cellulitis.

Levenson et al. (1983) came out with a surprising finding, he found that certain microorganism would accelerate wound healing namely *Staphylococcus aureus* infection. He demonstrated that seven strains of *Staphylococcus aureus* accelerated wound healing but it did not occur on the wound which inoculated with three strains of *Staphylococcus epidermidis* and two strains of *Pseudomonas aeruginosa*. He also found that wound-healing effect of *Staphylococcus aureus* was more marked when applied directly on incision wound but with modest effect when *Staphylococcus aureus* was injected intravenously.

1.7 Pain and occlusive dressing

Pain is one of the important factors when choosing the type of dressing. This should be considered especially in paediatric. Nemeth et al. (1991) found that pain was less common in wound treated with occlusive dressing.

Joseph et al. (1986) suggested that hydrogel was more effective than other types of occlusive dressing in the aspect of pain relief because of its cooling effect. In cutaneous ulcers, occlusive dressing will produce a good result provided the underlying systemic, regional and local factors for wound healing are corrected. It acts by protecting the surrounding skin, removing necrotic debris, minimising bacterial growth and promoting granulation tissue formation. In addition to that it maintains hydration, prevents further contamination and reduces the pain.

Barnett et al. (1983) made a comparison between synthetic adhesive vapour permeable dressing and fine mesh gauze dressing for split-thickness skin-graft donor site. Pain was almost non-existence in occlusive dressing but not for fine mesh gauze dressing. This relationship was also true, both between patients and between different sites on the same patient.

In cases of second-degree burn, pain was less in occlusive dressing compared to silver sulfadiazine cream application. Itchiness was also noted to be more severe among patients dressed with silvadene cream patients compared to occlusive dressing. All patients who were treated with occlusive dressing felt their dressing

were easier to apply and remove in contrast to only 85% among patients dressed with Sulfadiazine cream. (Wyatt et al. 1990)

1.8 Uses of occlusive dressing in acute wound

Many studies previously mentioned have repeatedly showed the beneficial effects of occlusion on healing. They suggested that epidermal migration is physically facilitated in moist condition and the absence of crust.

Madden et al. (1989) showed that occlusive dressing with Duo DERM healed 100% by day 9 whereas fine mesh gauze took up to 18 days before it completely separated from the wound. He also made a conclusion that partial thickness wound that were covered by occlusive dressing healed significantly faster than those covered with silver sulfadiazine.

Barnett et al. (1983) found that split-thickness skin graft donor site completely healed with a mean time of 6.8 days in occlusive dressing whereas in fine gauze dressing it took 10.5 days.

In case of second-degree burn wound, statistically better healing were seen among wounds covered with occlusive dressing compared to sulfadiazine cream.

Hien et al. (1988) used occlusive dressing following Mohs micrographic surgery (fresh tissue technique) for basal cell carcinoma on the face or scalp. The median number of days to healing was 20 days for occlusive dressing and 26 days for gauze dressing. Superiority was also noted with regards to induration, deformity, and improvement of the scar, and cosmetic at six months follow-up in areas of occlusive dressing. In addition to these findings, the size of scar also reduced to 50%

1.9 Introduction to Hydrogel

Hydrogel consists of hydrophilic polymers, which is commonly hydrated almost to saturation. Generally, they are highly biocompatible and are used in many biomedical applications i.e. in venous prosthesis, contact lenses and wound dressing. At present there are various different brands of hydrogel dressing available. All of them have been found useful in wound treatment. There are much evidence to show that hydrogel promotes granulation and re-epithelization. Hydrogel maintain moist environment on wound surface. It is gentle to the wound during dressing changes. Some of them are transparent; therefore visualization of the wound is possible and makes assessment easier. In some product, topical agents such as antiseptic, antibiotic and growth factors are added.

1.10 Sago hydrogel dressing

Sago, is a dible starch extracted from the pithlike center of sago palms (*Metroxylon sagu*). For our study the sago was obtained from sago trees grown in wetland of Mukah area in Sarawak, East Malaysia. This starch is an important item in the diet of some Sarawak natives. Hydrogel as wound dressing is not new but the manufacturing from material sago as a raw material is an innovation. The product contains polymers derived from polysaccharides originated from by product of sago production. The gels are mostly water and keep the wound moist.

The dressing is prepared in plastic mould and / or covered with plastic sheet and packed in airtight plastic package. The dressing is made of clinically safe materials and is exposed to ionizing radiation (either gamma rays or electron beams) to crosslink the materials as well as to sterilize the gel. The product is ready to be used without any quarantine period after radiation. Its sterility is maintained until the package is opened or damaged. The contents of hydrogel are polyvinyl pyrrolidone (medical grade), polyvinyl alcohol 117, carboxymethyl cellulose (CMC), distilled water and sago starch food grade. The product is flexible and elastic gel. It is designed for dressing of wound. It covers any skin contour/surface very well. It does not strongly adhere to the wound. The gel can keep the wound moist while acting as a biological barrier, prevents penetration of microorganism from outside.



Sago palms (*Metroxylon sagu*) in wetland of Sarawak.

OBJECTIVES

2.0. Objectives of study

In general, wounds are dressed with an artificial dressing or non-biological material. Therefore with the availability and the advantages of locally produced biomaterial (Sago Hydrogel), it is important to assess scientifically the efficacy of this new product.

The aims of this study are:

1. To assess whether locally produced hydrogel is useful as a wound dressing
2. To assess whether it has any advantages over conventional dressing
3. To determine tissue response and infection control properties of the locally produced hydrogel used as wound dressing in comparison with paraffin gauze dressing.

MATERIAL AND METHODS

3.0. Material and Methods

The study was carried out at the Animal House, School of Medical Sciences, Universiti Sains Malaysia, Kubang Kerian after approval by the university's Ethical Committee on the 14th February 2001. Twelve healthy rabbits were bought from the animal house. Their weights ranged from 2.0 – 3.5 kg. The rabbits were cared for by staffs of the animal house under the supervision of a Veterinarian. They were kept in separate cages. The animals were labeled from 1 to 12 by clipping the number on the ear. On the day of wounding, the rabbits were shaved on the back and both flanks (figure 1). Immediately before operation the rabbit were anaesthetized with intramuscular injection of Ketamine 35.0 mg/kg and Xylazine 5.0 mg/kg on buttock area (figure 2). When fully anaesthetized, the shaved area was cleaned three times with povidone iodine. The operations site was then isolated with sterile cataract towel (figure 3). The area for wounding was marked with sterile ink (Figure 4). Wounds were created under sterile technique with Humby knife (Figure 5). This knife was adjusted to slice skin 0.6 mm thick and therefore creating a partial thickness wounds. The area of the wound was approximately 5.0 x 2.5 cm in size (Figure 6).

Subsequently, the wounds were covered with gauze wet with normal saline for two minutes to facilitate hemostasis. After removal of the wet gauze, swabs for culture were taken by swabbing ten times longitudinally and ten times transversely on the wound (Figure 7). The swabs were immediately inoculated on culture media (blood agar Figure 8). Subsequently, biopsies of the wounds were taken with a No 21-

scalpel blade. The biopsy must be at least one cm from the skin margin to prevent contamination from the outside wound (Figure 9). The biopsy sites were closed with plain 3/0 catgut sutures.

Then, the wounds were covered randomly with Jelonet® as a control dressing (Figure 10) or Sago hydrogel as test dressing (Figure 11). A single sheet of Sago Hydrogel was used, but for the control (Jelonet®) three layers were used. The purpose of using 3 layers of Jelonet® was to prevent adherence to the wound surface. Then two pieces of gauze wet with normal saline were used to cover the dressing. On top of the wet gauze, a single layer of dry gauze was applied. The dressings were anchored with silk 3/0 to prevent dislodgement. On the other flank the same procedure was performed but with another type of dressing. TG-grip® was applied as a second protective layer to keep the dressing in place (Figure 12). After completing the procedures, the rabbits were placed back into their respective cages to allow for spontaneous recovery without any reversal agent. All rabbits were kept in the same room and under similar condition. Prophylactic antibiotic was not given in this study.

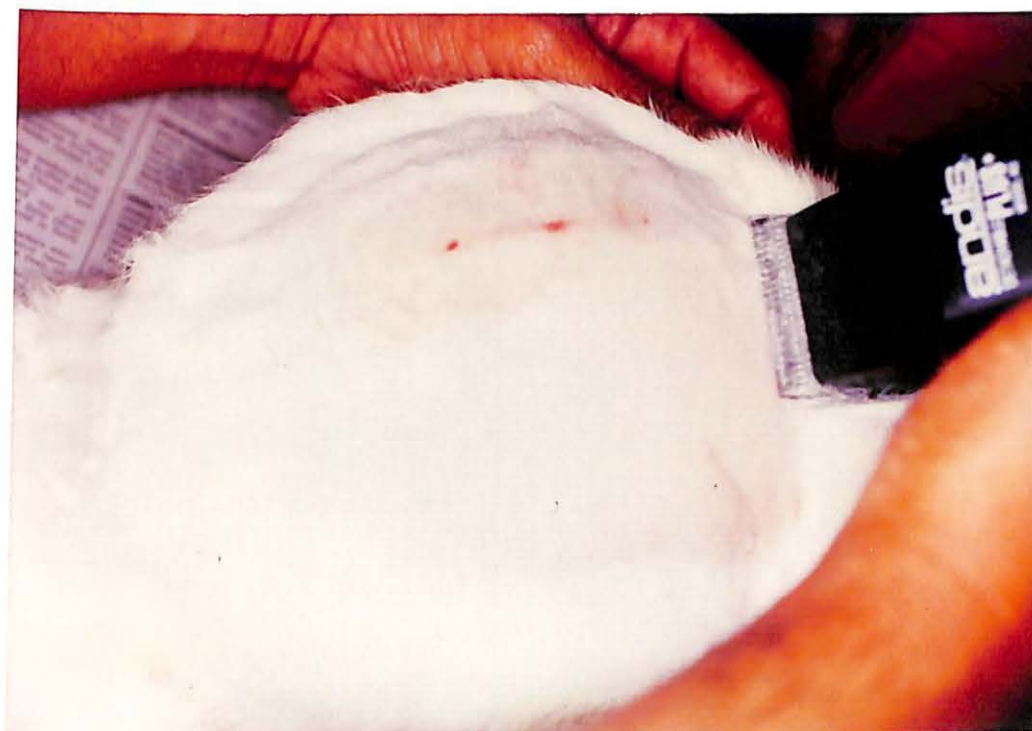

Figure 1: Back and both flanks were shaved .

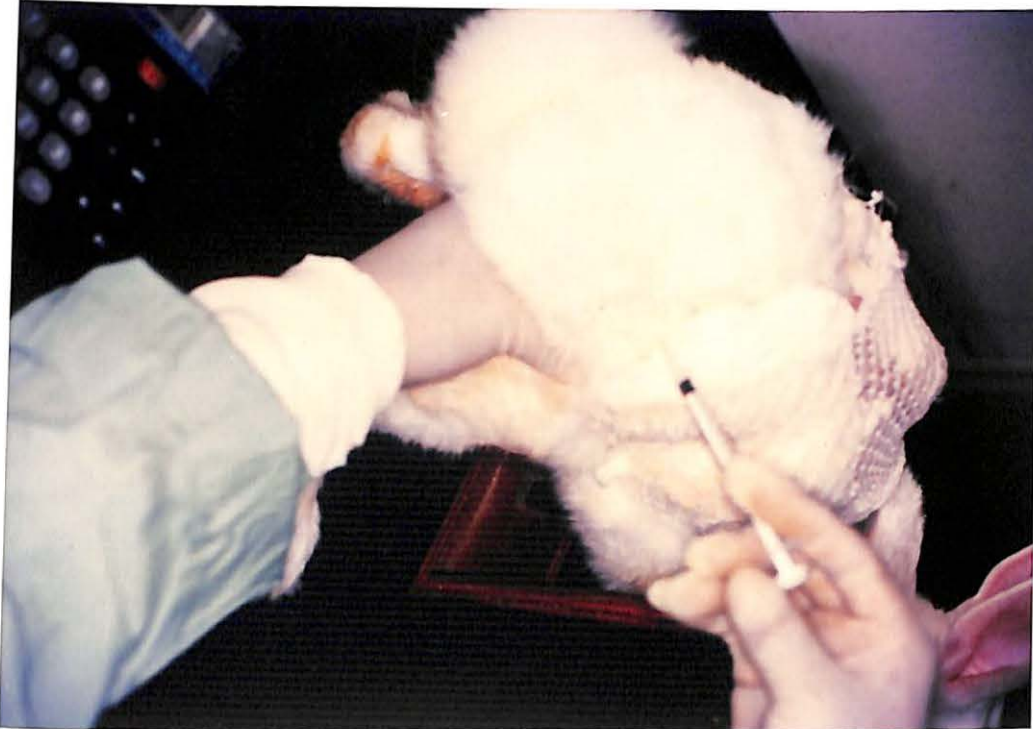

Figure 2: Anaesthetic agents was injected intramuscularly (buttock area)

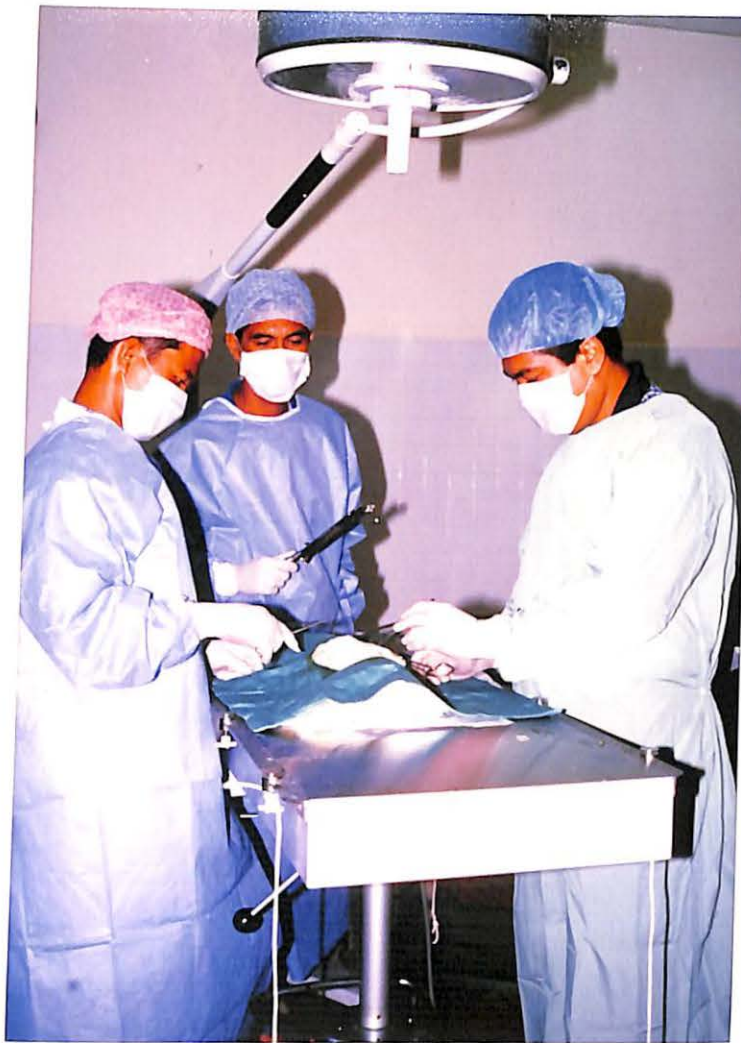

Figure 3: All procedures were performed under aseptic technique.

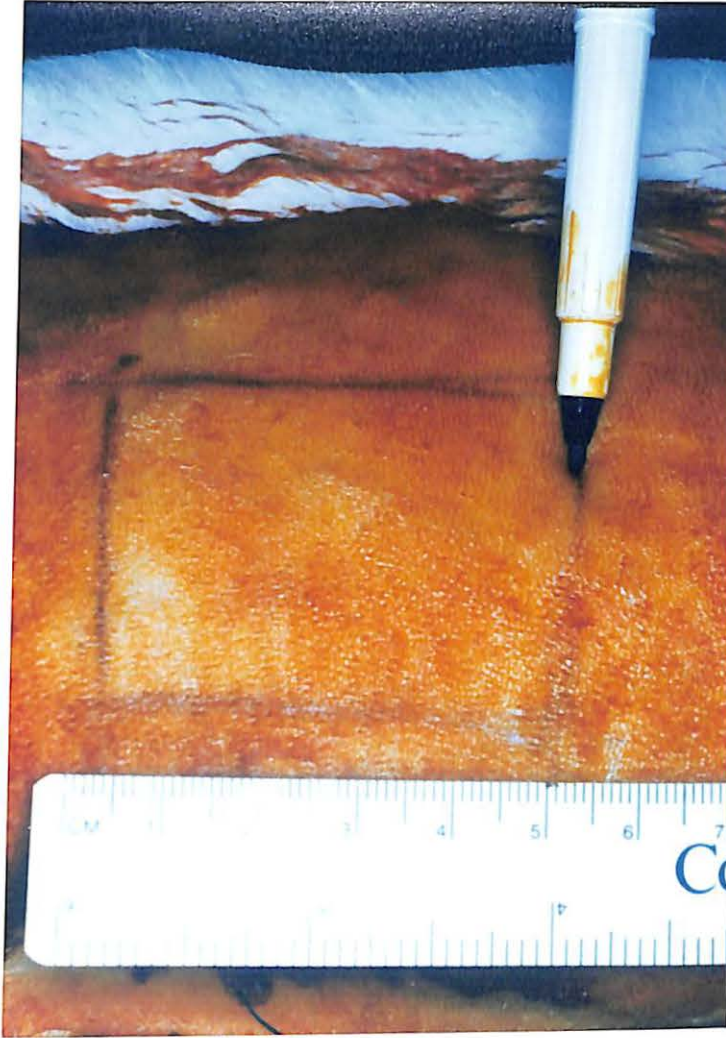


Figure 4: The area for wounding was marked with sterile marker

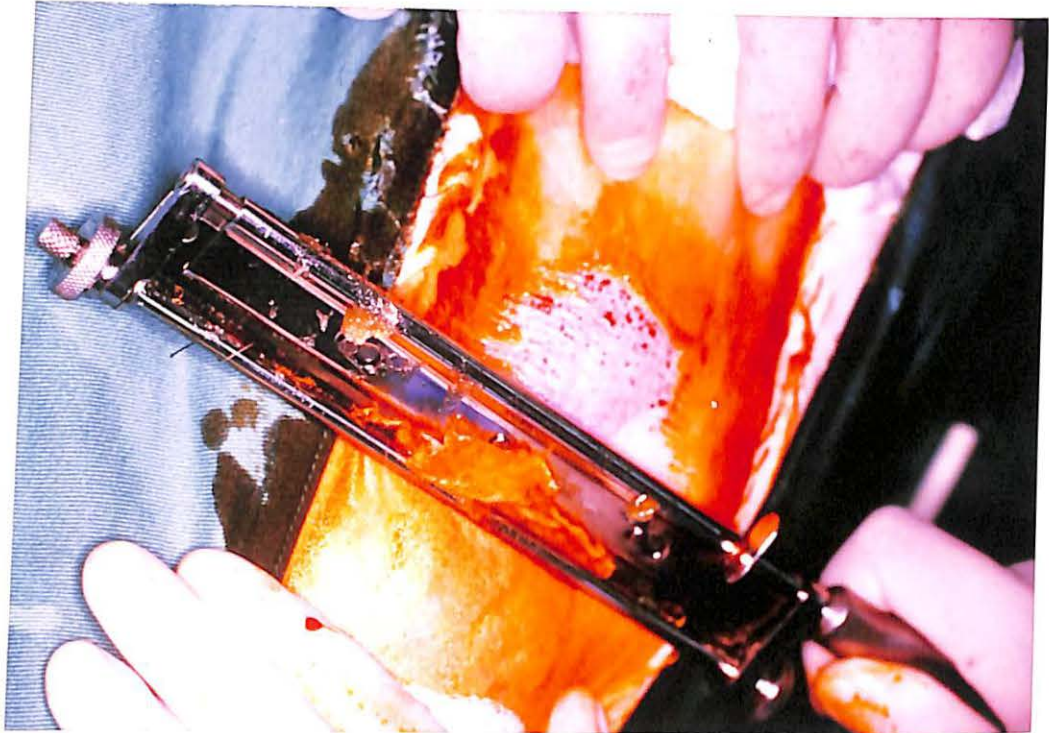

Figure 5: Humby knife sliced the skin till 0.6 mm deep to create a partial thickness wound

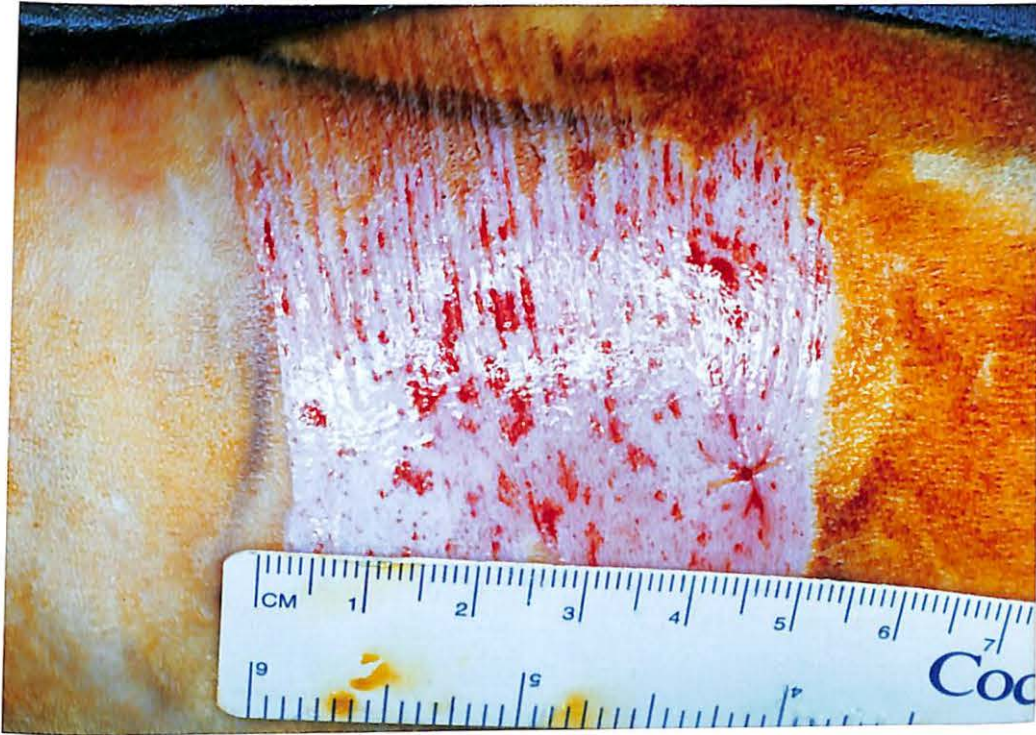

Figure 6: Wound size was approximately 5X2.5 cm