

Case Report

Iranian Journal of Otorhinolaryngology, Vol.29(3), Serial No.92, May 2017

Congenital Vomer Agenesis: Report of Two Cases

Mehdi Bakhshae¹, Sherwin Tavakol¹, *Yeganeh Teimouri²

Abstract

Introduction:

Congenital vomer agenesis is an extremely rare condition in which the vomer bone does not fully develop, which can lead to septal perforation.

Case Report:

We report two cases with a defect in the vomer bone in the posteroinferior portion of the septum, found accidentally while performing a pre-operative CT scan for nasal obstruction evaluation. They were diagnosed with congenital vomer agenesis.

Conclusion:

There are a few reports of vomer agenesis in literatures. By increasing usage of sinonasal endoscopic examination, we expect to address more cases in the future.

Keywords:

Congenital, Endoscopic examination, Nasal septum, Vomer agenesis.

Received date: 28 Apr 2016

Accepted date: 7 Nov 2016

¹*Sinus and Surgical Endoscopic Research Center, Faculty of Medicine, Mashhad University of Medical Sciences, Mashhad, Iran.*

²*Department of Otorhinolaryngology, Mashhad University of Medical Sciences, Mashhad, Iran.*

***Corresponding Author:**

Department of Otorhinolaryngology, Mashhad University of Medical Sciences, Mashhad, Iran.

Tel: +98 915 5190411, E-mail: yeganeteimouri@yahoo.com

Introduction

The nasal septum is made up of crests of both the palatine and the maxillary bones, the perpendicular plate of the ethmoid bone, the quadrangular septal cartilage, as well as the vomer and its two point ossification centers (with one on either side)(1). The palatal shelves shift at either side of the inferior edge of the precartilaginous nasal septum with the nasopalatine nerve on the 8th gestational week(2). A U-shaped bony formation is formed due to the fusion of the paired bony centers on both sides of the septal cartilage on the 17th week of gestation. During the 19th through the 23rd gestational weeks, the U-shape transforms to a Y-shaped vomer bone (3). In subsequent fetal stages of development, the radial spread of bony trabeculae leads to lateral widening of the inferior parts of the vomer. During development, the vomer's mineralization foci begin to appear subsequent to the fusing of the cartilaginous nasal septum with the palatal shelves (2). The ossification of the vomer begins prior to that of the perpendicular plate, directly after coming into contact with the ossification line next to the vertical plane to a horizontal plane to meet the nasal septum just above the tongue (4). Agenesis of the vomer bone is a rare condition that can lead to a defect in the posterior of nasal septum, but more common causes include trauma, irritation, tuberculosis, infection, irritation, neoplasia, and chronic inflammatory diseases (5). In vomer agenesis the defect is normally located in the posteroinferior region of the septum. In this report we want to describe a rare condition that surgeon may incidentally encountered and should be differentiate from septal perforation and defect.

Cases Report

Case 1: Patient was 48-year-old man who presented with a 10-year history of bilateral nasal obstruction. He did not have any history of trauma, nasal surgery, cauterization, tuberculosis, or syphilis. A clinical endoscopic examination detected bilateral mild polyposis and anterior septal spur in the left side. Further examination of the ear, oral cavity, and pharynx were normal. In a pre-operative CT scan we found a defect in the posteroinferior portion of the septum and bilateral sinonasal polyposis (Fig.1).

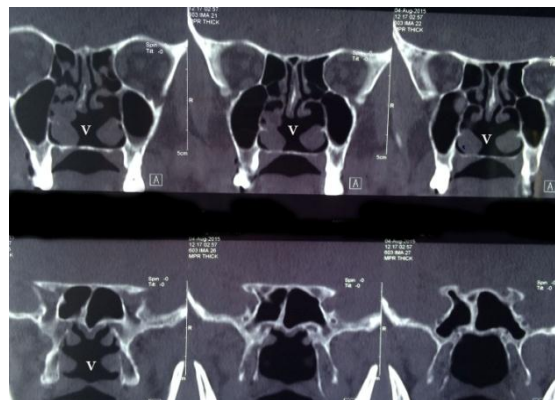


Fig1: CT Scan of case 1 that shows a defect in posteroinferior part of septum. This part is in accordance to vomerian part of nasal septum (V).

After removing the polyps during surgery, we were able to identify the nature of this defect which compatible with vomerian part of nasal septum. The margins were smooth and the mucosa was intact and normal (Fig.2).

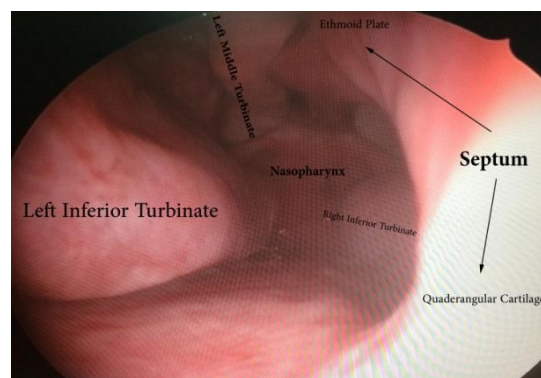


Fig 2: Endoscopic view of septal nasal defect with neighbor structure and smooth mucosal margin.

This condition was compatible with vomer agenesis. After surgery we examined the posterior part of soft palate from the point of the occult palate and there was an oval muscle that we could ruled out submucosal cleft palate.

Case 2: Another case was a 27-year-old man with congenital maxillofacial deformity who was a candidate for nasal reconstruction from the points of cosmetic as well as functional view. He did not have any history of trauma, surgery or systemic diseases. During endoscopic examination, we found a bilateral narrowing of the nasal valve area and a defect in the posteroinferior part of the septum with smooth margins and healthy mucosa around it (Fig.3).

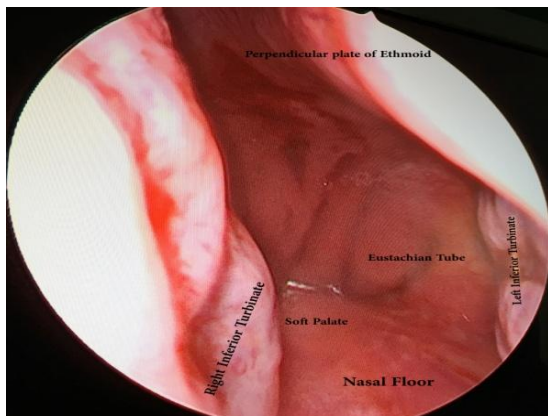


Fig3: Endoscopic view of smooth posteroinferior nasal septum defect with intact margin and other nasal structures.

There was not any submucosal cleft palate. A preoperative CT scan showed and confirmed this defect in the posteroinferior part of the septum and septal thickening (Fig.4).

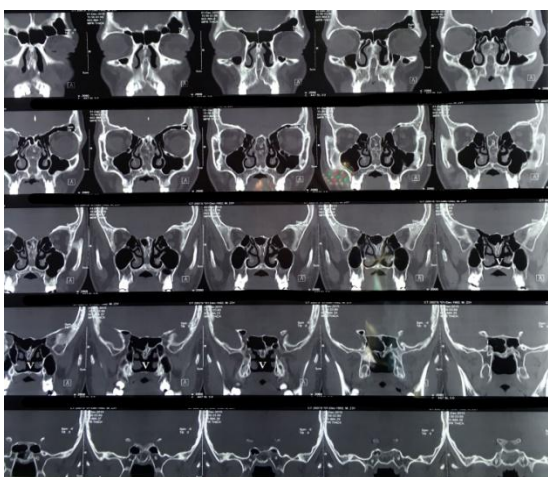


Fig 4: CT scan of case 2 that shows posteroinferior nasal septum defect in proposed vomerian part (V) and also thickening of the rest of septum.

Discussion

The vomer and the perpendicular plate of the ethmoid form the osseous septum. The vomer is created by intramembranous ossification, while the ethmoid bone forms via endochondrial ossification (6). During development, the vomer's mineralization foci appear subsequent to the fusing of the cartilaginous nasal septum with the palatal shelves (2). The ossification of the vomer begins prior to that of the perpendicular plate, directly after coming into contact with the ossification line next to the vertical plane to a horizontal plane to meet the nasal septum just above the tongue (4).

Mineralization of the vomer will be interrupted by any suspending of the ossification line to meet with the mesenchymal tissue of the future vomer (3). This theory is known as the "Incomplete Touch Theory," which describes the incomplete joining of the ossification line of the septal cartilage with the nearby tissue (7). Another theory proposed by Mohri is immature ossification and incomplete downward of the vomer itself (8).

Vomer agenesis has been described in the literature frequently with other concomitant diseases. Many of these are otolaryngological, but the largest concomitant disease type in patients with vomer agenesis in the literature has been ontological. Of the 6 patients that Mohri and Amatsu reported of in 2000, three of them had otitis media, and another had cholesteatoma (8).

Yilmaz and Altuntas also report of a 19-year-old man with bilateral otitis media with effusion, as well as hypertrophy of the posterior ends of both turbinates, septal deviation, and adenoid hypertrophy (9). Other reports commonly show vomer agenesis developing with concomitant sinonasal diseases. For example, both Lee and Kang et al. have reported of patients with concomitant sinusitis (10,11). Yorgancila et al. reported a 28-year-old woman with vomer agenesis who had a maxillary retention cyst (12). In 2015, Ucar et al. reported two cases of vomer agenesis with a concomitant deviated septum and inferior turbinate hypertrophy (13). The reports of concomitant sinonasal conditions coincide more closely with the case report outlined in this paper. The literature only shows one case of a concomitant laryngeal condition (laryngeal polyp), which was reported by Mohri and Amatsu in 2000 (8). There are also a group of patients who had vomer agenesis with concomitant non-otolaryngological diseases. For example, Mohri and Amatsu reported in 2000 of a 39-year-old man with pituitary adenoma (8). Additionally, in 2004, Dogru et al. reported 2 cases of vomer agenesis in the south of Turkey where there is a high prevalence of thalassemia. One had thalassemia and another had thalassemia accompanied with sensorineural hearingloss (14).

Finally, there have been multiple articles that describe patients without any concomitant disease (12,13,15). Additionally, in 2012, Verim

et al. proposed a hereditary basis for isolated congenital vomer agenesis. They discovered the same rare condition in the father, uncle, and two siblings of the same patient. Verim et al. had 5 cases at first and 9 cases after discovering the aforementioned ones. They proposed that this anomaly could possibly be attributed to a multifactorial hereditary disease (16). All reported cases is listed on Table 1.

Table 1: A list of reported cases by different authors

Author	Sex	Age	Concomitant disease
Mohn and Amatsu, 2000	F	44	Chronic otitis media
	M	55	Laryngeal polyp
	M	61	Acute otitis media
	M	4	Otitis media with effusion
	M	39	Pituitary adenoma
Dogru et al, 2004	F	24	Cholesteatoma
	M	16	Thalassemia
Yilmaz and Altunta, 2005	F	43	Thalassemia and sensorineural hearing loss
	M	19	Otitis media with effusion
Lee, 2006	M	10	None
Kang et al, 2007	F	62	Maxillary sinusitis
	M	13	Chronic sinusitis and nasal polyp
HerreroCalvo et al, 2008	F	43	None
Yorgancilar et al, 2012	M	28	Retention cyst in the maxillary sinus
Ozlay et al, 2013	F	14	Nasal Obstruction
Ucar et al, 2015	M	34	Septal deviation ,inferior turbinate hypertrophy
	M	34	Maxillofacial Truma
Bakhshae et al, 2016	M	48	Sinonasal polyposis &Septal deviation
	M	27	Congenital midline maxillofacial deformity

Conclusion

We know that this defect is likely more prevalent than that which has been reported in the literature, and by increasing the usage of sinonasal endoscopic examinations in otolaryngology we expect to find more cases in the future. The prevalence of concomitant otolaryngological diseases in these patients

could suggest a related mechanism between the development of such diseases and vomeragenesis.

References

- Davies J, Duckert L. Embryology and anatomy of the head, neck, face, palate, nose and paranasal sinuses. In: Paparella MM, Shumrick DA, Gluckman JL, Meyeroff WM, eds. Otolaryngology. 3rd ed. Philadelphia: W.B. Saunders; 1991:59-90.
- Sandikcioglu M, Molsted K, Kjaer I. The prenatal development of the human nasal and vomeral bones. J Craniofac Genet Dev Biol. 1994; 14: 124:34.
- Sakizlioglu I, Frommer J, Shiere FR. Prenatal development of the vomer in normal and cleft palate mice. Am J Anat. 1974; 141: 433: 9.
- Kang HJ, Lim HW, Hwang SJ, Lee HM. Congenital defect of the vomerbone: A rare cause of the septal perforation. International Journal of Pediatric Otorhinolaryngology Extra. 2007; 2(1): 17-9.
- Dudek Ronald W. Embryology BRS. 5th ed. Philadelphia: Lippincott Williams and Wilkins; 2009:1-240.
- Kjaer I. Human prenatal palatal closure related to skeletal maturity of the jaw. J Craniofac Genet Dev Biol. 1989; 9: 265:70.
- Hansen L, Nolting D, Holm G, Hansen BF, Kjaer I. Abnormal vomer development in human fetuses with isolated cleft palate. Cleft Palate Craniofac J. 2004; 41: 470:3.
- Mohri M, Amatsu M. Congenital defects of the vomer. Ann OtolRhinolLaryngol. 2000; 109: 497:9.
- Dogru H, Yasan H, Tüz M. Congenital vomeral bone defect in two thalassemia trait cases. Eur Arch Otorhinolaryngol. 2004; 261: 136: 8.
- Yilmaz MD, Altuntas A. Congenital vomeralbone defect. Am J Otolaryngol. 2005; 26: 64:6.
- Lee JH. Congenital vomeral bone defect: report of two cases and a review of the literature. Acta Otolaryngol. 2006; 126: 1229:31.
- Kang HeeJoon, Lim Hyun-Woo, Hwang Soon Jae, Lee Heung-Man. Congenital defect of the vomer bone: A rare cause of septal perforation. Int J of PedOtorhinolaryngol Extra. 2007; 2: 17:9.
- Yorgancilar E, Yildirim M, Gun R, Meric F, Topcu I. Congenital osvomer agenesis. Ear Nose Throat J. 2012; 91(4):164-71.
- Ucar S, Aydın Ö, Öztürk M. Congenital vomer agenesis. Kulak Burun Bogaz Ihtis Derg. 2015; 25(3): 182:4.
- Dogru H, Yasan H, Tüz M. Congenital vomeral bone defect in two thalassemia trait cases. Eur Arch Otorhinolaryngol. 2004; 261: 136:8.
- HerreroCalvo D, CuetosAzcona M, Vallejo Valdezate LA, Gil-CarcedoGarcía LM. Agnesis of the vomer bone. Acta Otorrinolaringol Esp. 2008; 59: 148:9.
- Aysegül Verim, Ömer Faruk Çalım, Alper Yenigün, Gamze idem Kocagöz, Numan Kökten, Haluk Özkul. Hereditary characteristic of isolated congenital vomer aplasia. Journal of Cranio-Maxillo-Facial Surgery. 2012; 40: 392: 6.