

## Reconstruction of Pretibial Defect Using Pedicled Perforator Flaps

In Soo Shin, Dong Won Lee, Dong Kyun Rah, Won Jai Lee

*Institute for Human Tissue Restoration, Department of Plastic and Reconstructive Surgery, Yonsei University College of Medicine, Seoul, Korea*

**Background** Coverage of defects of the pretibial area remains a challenge for surgeons. The difficulty comes from the limited mobility and availability of the overlying skin and soft tissue. We applied variable pedicled perforator flaps to overcome the disadvantages of local flaps and free flaps on the pretibial area.

**Methods** Eight patients who had the defects in the anterior tibial area were enrolled. Retrospective data were obtained on patient demographics, cause, defect location, defect size, flap dimension, originating artery, pedicle length, pedicle rotation, complication, and postoperative result. The raw surface created following the flap elevation was covered with a split thickness skin graft.

**Results** Posterior tibial artery-based perforator flaps were used in five cases and peroneal artery-based perforator flaps in three cases. The mean age was 54.3 and the mean period of follow-up was 6 months. The average size of the flaps was 63.8 cm<sup>2</sup>, with a range of 18 to 135 cm<sup>2</sup>. There were no major complications. No patients had any newly developed functional deficit of the lower leg.

**Conclusions** We suggest that pedicled perforator flaps can be an alternative treatment modality for covering pretibial defects as a simple, safe and versatile procedure.

**Keywords** Leg / Pedicled flap / Reconstructive surgical procedures

**Correspondence:** Won Jai Lee  
 Institute for Human Tissue Restoration, Department of Plastic and Reconstructive Surgery, Yonsei University College of Medicine, 250 Seongsan-ro, Seodaemun-gu, Seoul 120-752, Korea  
 Tel: +82-2-2228-2219  
 Fax: +82-2-393-6947  
 E-mail: pswjlee@yuhs.ac

This article was presented at the 1st Research and Reconstructive Forum on May 12, 2011 in Daejeon, Korea.

No potential conflict of interest relevant to this article was reported.

Received: 30 Apr 2012 • Revised: 31 May 2012 • Accepted: 12 Jun 2012

pISSN: 2234-6163 • eISSN: 2234-6171 • <http://dx.doi.org/10.5999/aps.2012.39.4.360> • Arch Plast Surg 2012;39:360-366

### INTRODUCTION

Soft tissue reconstruction of the pretibial area is challenging. Traumatic wounds, burns, and tibial fractures frequently expose the bone. Due to limited mobility and a paucity of overlying skin, even a small defect in the pretibial area generally needs flap coverage. A random pattern flap has an indistinct perfusion pattern and is limited in size and mobility [1]. Local fasciocutaneous flaps have limited availability in the distal leg. Musculocutaneous flaps and muscle flaps with skin grafts such as from the gastrocnemius, soleus, and tibialis anterior can be used in the proximal

and middle thirds of a pretibial defect [2-4]; these flaps come from the posteromedial or posterolateral region and require extensive dissection, which leads to increased donor site morbidity and causes functional deficit. Free microvascular transfer is time-consuming, and requires microsurgical facility.

Recent advances in anatomical knowledge on cutaneous, subcutaneous, and intramuscular circulation have led to more refined reconstruction, and have allowed for development of several types of perforator flaps [5,6]. Perforator flaps composed with skin and subcutaneous fat are nourished by perforators rising from the deep vascular systems. There are several reliable

perforators from the anterior tibial, posterior tibial, and peroneal arteries in the lower leg within intermuscular septa [7]. Perforator flaps have several obvious advantages. The source artery, underlying muscles, and fascia are preserved. They are easy to approach and can be performed expeditiously for the management of soft tissue defects in the elderly, systemically-compromised patients, and multiply-injured patients. They are technically less demanding, and the need for microvascular anastomosis is avoided. The recipient site has a similar texture, thickness, pliability, and pigmentation to that which has been lost. Additionally, pedicled perforator flaps limit scars and morbidity to one extremity. However, pedicled perforator flaps have some possible drawbacks. Pedicled perforator flaps require more tedious flap dissection, additional clinical acumen for perforator selection, and increase venous congestion, which may lead to complete or partial flap loss. Another significant disadvantage is related to the fact that the perforator can be within the zone of injury, which can threaten the viability of the flap.

This report describes the results of pedicled perforator flaps based on the posterior tibial artery or peroneal artery to cover soft tissue defects in the pretibial area in eight patients.

## METHODS

A retrospective study was performed between February 2005 and March 2012 on 8 patients who underwent reconstruction with pedicled perforator flaps. The patients' charts were reviewed and information regarding patient demographics, cause, defect location, defect size, flap dimension, originating artery, pedicle

length, pedicle rotation, any complications, and the postoperative result was recorded.

Out of eight patients, five were males and three were females. The average age of the patients was 54.3 years (range, 21 to 72 years). Among the 8 patients, 3 had diabetes mellitus. The defects originated from trauma (3 patients), a pressure sore (1 patient), excision of malignancy (2 patients), unstable scarring after a gunshot injury (1 patient), and postoperative skin necrosis (1 patient) (Table 1).

Eight patients with moderately-sized soft tissue defects from 5×2 cm to 14×8 cm were treated. The defects were located on the proximal (n=3), middle (n=3), and distal third (n=2) of the lower leg. The average size of the flaps was 63.8 cm<sup>2</sup> (range, 18 to 135 cm<sup>2</sup>). All of the flaps were harvested from the anteromedial or anterolateral region of the lower leg, and the raw surface created following the flap elevation was covered with a split thickness skin graft. The size and shape of the flaps were almost identical to those of the defects. The source vessels of the perforator were the posterior tibial artery (n=5) and peroneal artery (n=3). Careful dissection of the perforator pedicle was performed to obtain a sufficient length for flap rotation without tension, twisting, or kinking. The average length of the pedicle was 2.75 cm (range, 2 to 4 cm). The flaps were rotated from 70° to 180° to cover the defects. Routine preoperative arteriography was not performed, except in four patients. Two had soft tissue defects caused by major trauma; one was a patient with poorly controlled diabetes and one was a 70-year-old patient in whom the arteriogram was performed as a precaution due to her advanced age.

Table 1. Clinical results of the patients and the flaps

Case	Sex/ Age	Cause	Location	Defect size (cm <sup>2</sup> )	Comor- bidities	Angiog- raphy	Flap size (cm <sup>2</sup> )	Originating artery	Pedicle length (cm)	Pedicle Rotation (°)	Compli- cations	Follow- up (mo)
1	M/54	Pressure sore	Proximal third	7×5	HTN, DM	-	8×6	PTA	2	90		2
2	F/68	Unstable scar	Middle third	5×3	DM	-	6×4	PTA	2	70		8
3	M/50	Trauma	Middle third	6×8	-	Yes	7×9	PTA	2	80	Skin graft partial loss, superficial epidermolysis	9
4	M/44	Trauma	Distal third	14×8	-	Yes	15×9	PA	3	110		8
5	M/56	Post- operative skin necrosis	Distal third	5×2	HTN, DM	Yes	6×3	PTA	2.5	90		4
6	M/21	Trauma	Proximal third	6×3	-	-	7×4	PTA	2	60		2
7	F/72	Malignancy	Proximal third	9×8	-	-	10×9	PA	4	180	Venous congestion	13
8	F/70	Malignancy	Middle third	12×7	-	Yes	13×8	PA	4	180	Venous congestion	2

HTN, hypertension; DM, diabetes mellitus; PTA, posterior tibial artery; STSG, split thickness skin graft; PA, peroneal artery.

## Surgical techniques

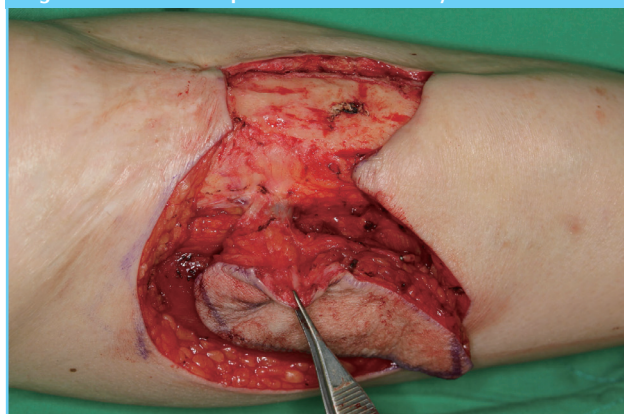
Preoperatively, the soft tissue defects were prepared for some days to avoid infection and to induce growth of healthy granulation tissue using saline soaked gauze dressing except the two cases with malignancy. The cutaneous perforators were identified and marked using a hand-held Doppler flow meter (ES-1000SPM Smartdop, Koven Technology Inc., St. Louis, MO, USA), and the axis of the flap was marked in between the perforators. The vascular axis of the three main vessels of the leg was also marked as follows. For the posterior tibial artery, a reference line was drawn by joining the tibial tuberosity and the midmalleolar point. The vascular axis lies approximately 4.5 cm medial and parallel to the reference line or 1.5 cm from the medial border of the tibia. For the peroneal artery, the reference line was drawn by joining the head of the fibula and tip of the lateral malleolus. The vascular axis lies 2.5 cm posterior and parallel to the reference line.

All procedures were performed under general endotracheal anesthesia with the patient in the supine position. A tourniquet was applied to the thigh, and the leg was exsanguinated by elevation and compression of the popliteal artery for one minute. To raise a flap based on the posterior tibial artery perforator, the leg was slightly abducted and externally rotated. To raise a flap based on the peroneal artery perforator, the hip was flexed and internally rotated.

A provisional flap design was drawn as follows. First, the distance between the perforator and the distal edge of the defect was measured. This value was then transposed either proximally or distally, again measured from the perforator, and one centimeter was added to it to form the limit of the flap. The width of the defect was measured and half a centimeter was added to it. This value was used for the flap width to allow for tissue contraction and to facilitate easy closure without tension.

Meticulous debridement was performed just before the flap was elevated. The exploratory initial incision was made on the distal or proximal part of the flap. The flap elevation was subfascially performed, indentifying and preserving the reliable perforators encountered. A number of potentially useful perforators are usually exposed. Visual assessments of the perforators were then made to choose the most reliable pedicle for the flap. The choice of the perforator was based on its location, size, and any potential injury to the pedicle. After the largest suitable perforator was chosen, all of the other perforators were ligated (Fig. 1). Careful dissection around the pedicle was necessary, but we did not perform skeletonization of the perforator or exposure of the posterior tibial artery and peroneal artery, reducing the risk of damage to the perforator and venae comitantes. All the fascial strands that could potentially cause vascular compromise

Fig. 1. Perforator of posterior tibial artery



through kinking of the vessels were dissected. Once the flap had been completely isolated, it was left in its original position and the tourniquet was released and then a vasodilator such as papaverine or lidocaine was instilled around the pedicle. After 10 to 15 minutes, the flap was rotated to the defect. If there were any signs of kinking of the pedicle by any residual fascial strands, they might have needed further division. The inset of the flap and wound closure was performed using 3-0 or 4-0 nylon half-buried sutures with a suction drain or penrose drains in situ. In all cases, a secondary raw area created following the raising of the flap was covered with a split thickness skin graft.

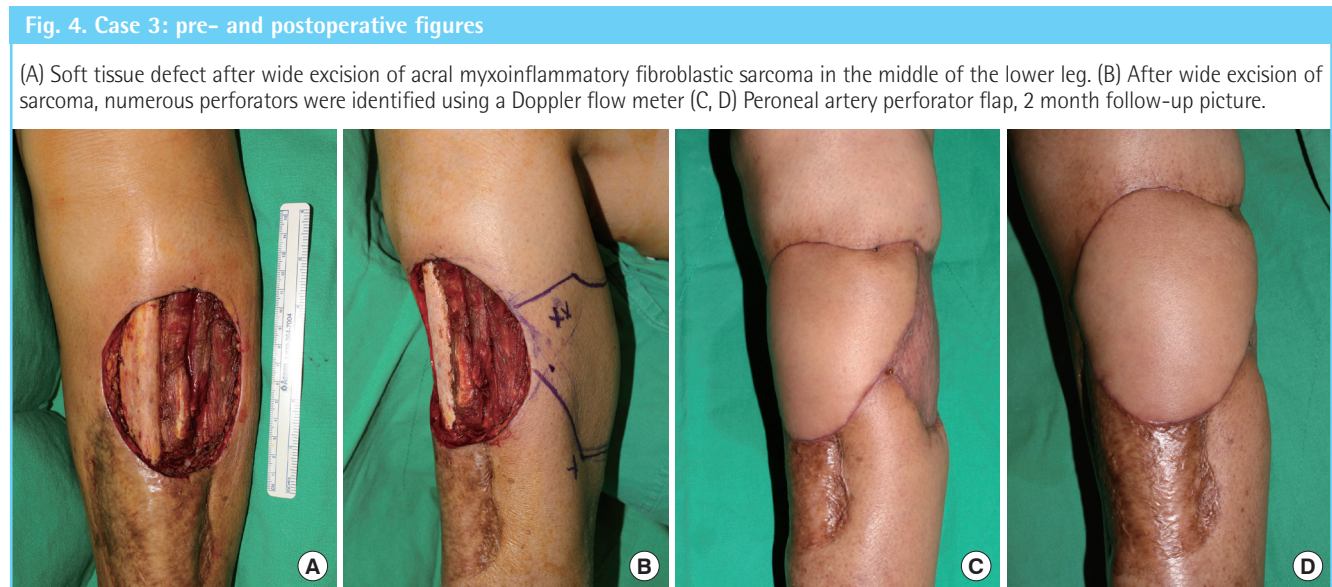
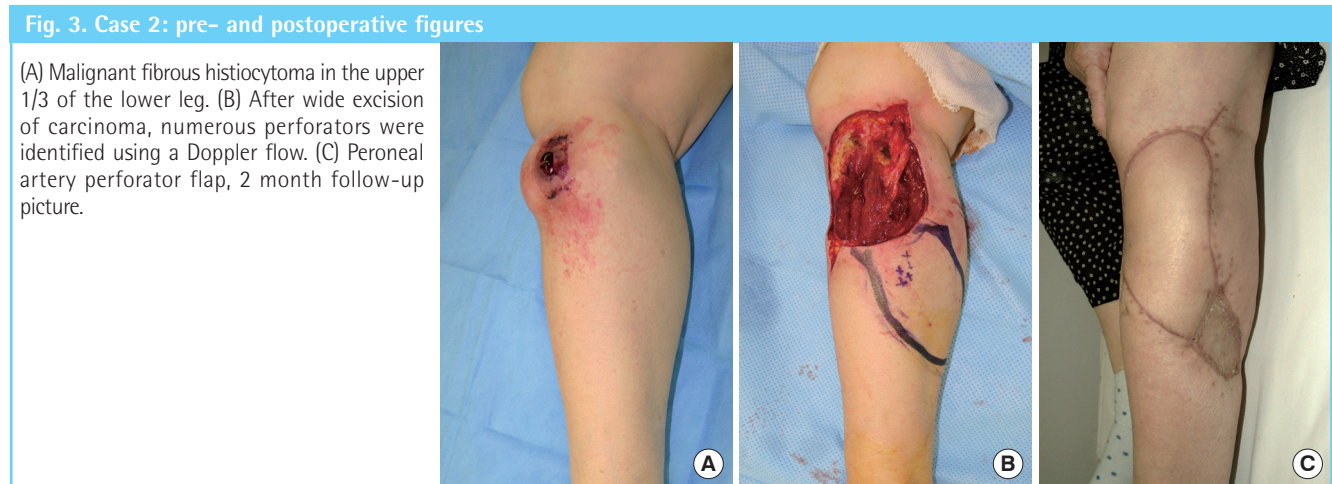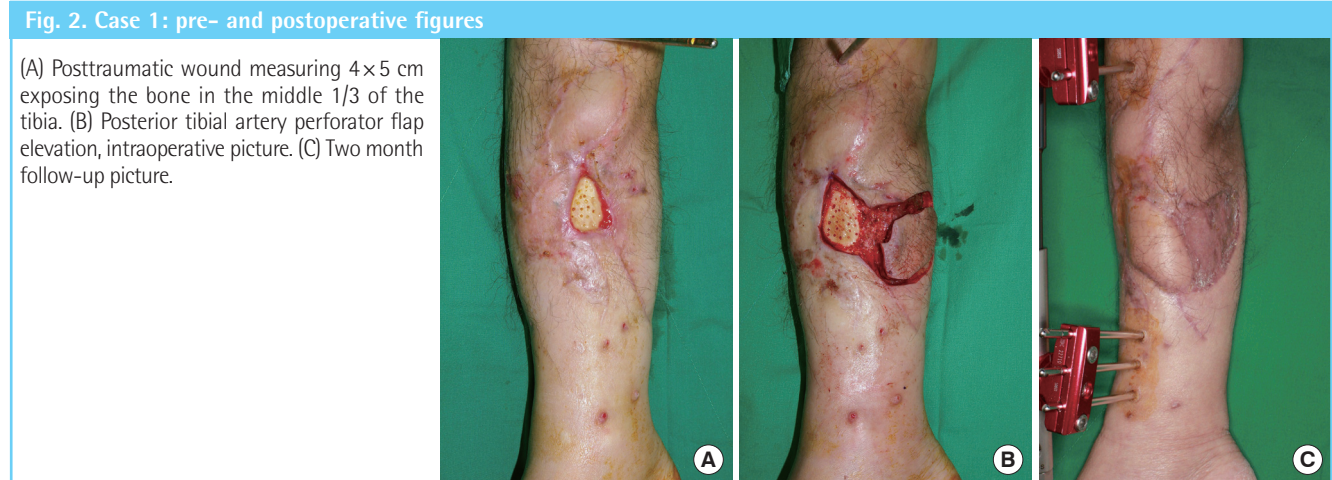## RESULTS

The length of the flap ranged from 6 to 15 cm, and the width from 3 to 9 cm. Superficial epidermolysis occurred in one patient (case 3), which healed without further intervention. Partial loss of the skin graft occurred in same patient, but it healed completely with saline soaked gauze dressing. There was postoperative venous congestion in two cases. The congestion subsided within days after removal of the partial sutures without necrosis. The patients were followed for an average period of 6 months, ranging from 2 to 13 months. All of the flaps were well taken without major complications and all of the donor sites healed completely with a split thickness skin graft. There was minimal scarring along the flap boundaries and no distortion of adjacent normal tissue anatomy on the follow-up periods (Figs. 2-4). No patient had any newly developed functional deficit of the lower leg.

## Case report

### Case 1 (patient 3)

A 50-year-old man was admitted with a crushing injury to his right lower leg as a result of a falling container box and presented with a 6 × 8 cm chronic ulcer with tibia exposure. Complete de-



bridement was performed on the necrotic tissues. After a posterior tibial artery perforator flap (7×9 cm) based on one perforator, 9 cm proximal to the tip of the medial malleolus, was raised

and rotated 80° to cover the defect. A split thickness skin graft (9/1,000 inch thickness) was performed on the donor site. Postoperative superficial epidermolysis occurred on the distal tip of

the flap, but subsided within days without further management. Partial loss of the skin graft occurred, but it healed completely with saline soaked gauze dressing. Two months after surgery, the flap and the recipient site were well matched (Fig. 2).

#### Case 2 (patient 7)

A 72-year-old woman was admitted with a left knee mass that had been rapidly growing for three months. The mass was located on the lateral aspect of proximal fibula. The mass was pathologically confirmed to be a malignant fibrous histiocytoma by incisional biopsy. Wide excision including partial removal of the lateral head of the gastrocnemius and soleus was performed without injury of the common peroneal nerve. The final defect measured 9 × 8 cm. A peroneal artery perforator flap (10 × 9 cm) based on one perforator, 18 cm proximal to the tip of the lateral malleolus was harvested and rotated 160° to cover the defect. A split thickness skin graft (9/1,000 inch thickness) was performed on the donor site. The flap and the donor site healed well, without complications. Two months after surgery, the flap and the recipient site matched well (Fig. 3).

#### Case 3 (patient 8)

A 70-year-old woman was admitted with a recurrent pretibial mass of the left lower leg that had been rapidly growing for five months. The patient had undergone surgery including wide excision, a hemisoleus muscle flap, and a split thickness skin graft on the pretibial area a year earlier. The mass was pathologically confirmed as acral myxoinflammatory fibroblastic sarcoma by incisional biopsy. Wide excision, including partial removal of tibialis anterior, extensor digitorum longus, and gastrocnemius, was performed. The final defect measured 12 × 7 cm. A peroneal artery perforator flap (13 × 8 cm) based on one perforator, 16 cm proximal to the tip of the lateral malleolus was harvested and rotated 110° to cover the defect. A split thickness skin graft (9/1,000 inch thickness) was performed on the donor site. The flap and the donor site healed well, without complications. Two months after surgery, the flap and the recipient site matched well (Fig. 4).

## DISCUSSION

The pretibial area of the lower leg has inherent characteristics that can make even a small defect a challenge. Soft tissue defects of this region are usually accompanied by exposed bone or tendon, and of the metal fixation device of any prosthesis. In addition, any coinciding problem, such as an infection, will further complicate the situation.

Various reconstructive choices, either local flaps or free flaps,

can be used for coverage of the pretibial defect [1-4]. A random pattern flap is limited in size and mobility [1]. Local fasciocutaneous flaps have limited availability in the distal leg. Local and regional flaps from the calf are versatile, but increase morbidity due to greater dissection to gain the long arc of rotation [2,3]. The split skin grafting on the secondary raw surface on the posterior or dependent position of the calf must be carefully secured in the early postoperative period. Local muscle flaps including medial or lateral gastrocnemius [2], soleus [3], and tibialis anterior [4] are too bulky to cover skin defects in the anterior tibial area and are usually associated with aesthetic concern. Additionally, muscle flaps scarify the important muscles, leading to functional deficits. The poor condition of the soft tissue around wounds limits use of local and regional flaps for wound repair in complex soft tissue injuries. Moreover, soft tissue defects on the distal third of the lower limb are difficult to cover with local flaps. Free flaps can be used to cover the defects, but they require time-consuming microvascular anastomosis and should be avoided in patients with comorbidities. Postoperative care is also more difficult in patients who have undergone microsurgical reconstruction. Furthermore, the initial appearance of free flaps is often too bulky. Pedicled perforator flaps are reliable and have minimal donor morbidity, and the advantages of the simplified and versatile flap design yield a better match to the defect and increased arc of rotation of the flap, which can be up to 180° [1]. From the aesthetic perspective, a pedicled perforator flap leads to optimal results due to the like-with-like reconstruction by using donor-tissue areas located near the defect.

Recently, several clinical studies reported on the application and results of pedicled perforator flaps in lower leg reconstruction. Sananpanich et al. [8] used pedicled perforator flaps for lower limb reconstruction in 25 patients. They reported one total flap loss in a diabetic patient, one superficial epidermolysis healed without further intervention, and one partial flap loss that needed debridement and resuture. Lu et al. [9] treated 18 patients with defects in the lower leg and foot with 180° propeller flaps based on perforators from peroneal vessels. A partial flap loss that required further reconstruction with skin grafts was encountered in one patient. Mateev et al. [10] described 11 patients with defects located in the distal leg and foot. In one case (a smoker), total flap necrosis was observed as a result of venous stasis. In two cases, the flap was revised because of infection and partial necrosis, and finished with a skin graft. In this study, no flap necrosis was registered even in diabetic patients.

Pedicled perforator flaps are best suited for small and medium defects in the lower leg, but their dimensions have to be larger to cover these defects. Koshima et al. [11] used a posterior tibial artery-based perforator flap of 19 × 13 cm, while Rad et al. [12]

reported a peroneal artery-based perforator flap of 22 × 8 cm. We used pedicled perforator flaps measuring up to 15 × 9 cm to cover the soft tissue defects without complications. This large flap territory can be raised on a single perforator due to extensive axial communications between the perforators within the flap. Hyperperfusion in a perforator allows the capture of multiple adjacent perforasomes through direct and indirect lining vessels [13]. These characteristics make pedicled perforator flaps predictable and reliable for coverage of pretibial defects.

Out of our 8 cases, there were 5 propeller flaps. Advantages of propeller flaps include their versatile design and freedom of inseting. However, venous compromise is usually a major concern for propeller flaps. Wong et al. [14] advocated that the perforator should be approximately 1 mm in diameter and more than 30 mm in length. According to anatomical studies, the average distance of the perforator to the posterior tibial artery is 3.2 to 4 cm, whereas the average distance of the perforator to the peroneal artery is 3.7 to 5.4 cm [7]. The diameter of the posterior tibial artery perforator is around 0.9 mm, whereas the diameter of the peroneal artery perforator is around 0.8 mm [7]. Therefore, the posterior tibial artery perforator and the peroneal artery perforator are safe for the design of a propeller flap. In this study, the length of the perforator pedicle in 5 propeller flaps was 2 to 4 cm; all flaps healed well without complications such as complete or partial flap necrosis.

However, pedicled perforator flaps have several disadvantages, such as the fact that the perforator can be within the zone of injury, which can prejudice the viability of the flap. In this study, the secondary raw surface following the raising of the flap was covered with a split thickness skin graft. This operative technique leaves a significant cosmetic defect. Therefore, whenever possible, we avoid using pedicled perforator flaps in women and in any individual where cosmesis is an issue. Primary closure of the secondary defect, when possible, avoids the cosmetic deformity caused by a split thickness skin graft. Jakubietz et al. [15] reported that the donor site can be primarily closed for defects less than 6 cm wide. Another disadvantage of pedicled perforator flaps is that the flaps are mostly insensate. However, most non-innervated local flaps eventually develop slight sensory recovery due to peripheral innervations. Venkataramakrishnan et al. [16] reported a sensate flap including a sensory nerve, which had the limitation of advancement for small-sized soft tissue defects in the neighboring area.

We used a handheld Doppler flow meter for detecting the perforator vessels [17]. Preoperative Doppler flowmetry is used to rapidly identify the perforator in the anatomical area of interest. However, this procedure is operator-dependent, time consuming, and not always accurate in localizing the perforating vessels.

Other imaging methods, such as Doppler flowmetry, magnetic resonance imaging, and computed tomogram angiography can facilitate the preoperative localization of the vessels in this procedure [18-20]. In our studies, preoperative arteriography was performed in four patients with existing comorbidities to detect possible injuries or impatency of source arteries.

This study has proven that small and moderately-sized soft tissue defects in the pretibial area can be covered easily and safely, using locally available versatile pedicled perforator flaps. Also, the uncomplicated intraoperative supine position simplifies the work of surgeons and the anesthetist, thereby minimizing the cost and effort of surgery. Most importantly, this technique allows early mobilization.

The weaknesses in this study are that it is a descriptive retrospective study with a small number of patients. However, our report presents a variety of options for pedicle flaps in pretibial defects based on perforator vessels even in the distal third of the lower leg. We have reliable results without major complications such as complete or partial flap necrosis or any functional deficit. The design and application of pedicled perforator flaps for wound coverage in the pretibial area were very successful, providing a high quality reconstruction with minimal morbidity. The pedicled perforator flap may be an alternative modality for reconstruction of small and moderately-sized skin and soft tissue defects in the pretibial area. Disadvantages of these perforator flaps are their limited application to large defects and the variable location of the perforators.

## REFERENCES

1. Quaba O, Quaba A. Pedicled perforator flaps for the lower limb. *Semin Plast Surg* 2006;20:103-11.
2. Salibian AH, Menick FJ. Bipedicled gastrocnemius musculocutaneous flap for defects of the distal one-third of the leg. *Plast Reconstr Surg* 1982;70:17-23.
3. Fayman MS, Orak F, Hugo B, et al. The distally based split soleus muscle flap. *Br J Plast Surg* 1987;40:20-6.
4. Moller-Larsen F, Petersen NC. Longitudinal split anterior tibial muscle flap with preserved function. *Plast Reconstr Surg* 1984;74:398-401.
5. Taylor GI, Pan WR. Angiosomes of the leg: anatomic study and clinical implications. *Plast Reconstr Surg* 1998;102:599-616.
6. Taylor GI. The angiosomes of the body and their supply to perforator flaps. *Clin Plast Surg* 2003;30:331-42.
7. Schaverien M, Saint-Cyr M. Perforators of the lower leg: analysis of perforator locations and clinical application for pedicled perforator flaps. *Plast Reconstr Surg* 2008;122:161-70.

8. Sananpanich K, Tu YK, Kraissarin J, et al. Reconstruction of limb soft-tissue defects: using pedicle perforator flaps with preservation of major vessels, a report of 45 cases. *Injury* 2008;39 Suppl 4:55-66.
9. Lu TC, Lin CH, Lin YT, et al. Versatility of the pedicled peroneal artery perforator flaps for soft-tissue coverage of the lower leg and foot defects. *J Plast Reconstr Aesthet Surg* 2011;64:386-93.
10. Mateev MA, Kuokkanen HO. Reconstruction of soft tissue defects in the extremities with a pedicled perforator flap: series of 25 patients. *J Plast Surg Hand Surg* 2012;46:32-6.
11. Koshima I, Moriguchi T, Ohta S, et al. The vasculature and clinical application of the posterior tibial perforator-based flap. *Plast Reconstr Surg* 1992;90:643-9.
12. Rad AN, Singh NK, Rosson GD. Peroneal artery perforator-based propeller flap reconstruction of the lateral distal lower extremity after tumor extirpation: case report and literature review. *Microsurgery* 2008;28:663-70.
13. Saint-Cyr M, Wong C, Schaverien M, et al. The perforasome theory: vascular anatomy and clinical implications. *Plast Reconstr Surg* 2009;124:1529-44.
14. Wong CH, Cui F, Tan BK, et al. Nonlinear finite element simulations to elucidate the determinants of perforator patency in propeller flaps. *Ann Plast Surg* 2007;59:672-8.
15. Jakubietz RG, Jakubietz MG, Gruenert JG, et al. The 180-degree perforator-based propeller flap for soft tissue coverage of the distal, lower extremity: a new method to achieve reliable coverage of the distal lower extremity with a local, fasciocutaneous perforator flap. *Ann Plast Surg* 2007;59:667-71.
16. Venkataramakrishnan V, Mohan D, Villafane O. Perforator based V-Y advancement flaps in the leg. *Br J Plast Surg* 1998;51:431-5.
17. Yu P, Youssef A. Efficacy of the handheld Doppler in preoperative identification of the cutaneous perforators in the anterolateral thigh flap. *Plast Reconstr Surg* 2006;118:928-33.
18. Masia J, Kosutic D, Cervelli D, et al. In search of the ideal method in perforator mapping: noncontrast magnetic resonance imaging. *J Reconstr Microsurg* 2010;26:29-35.
19. Blondeel PN, Beyens G, Verhaeghe R, et al. Doppler flowmetry in the planning of perforator flaps. *Br J Plast Surg* 1998;51:202-9.
20. Alonso-Burgos A, Garcia-Tutor E, Bastarrika G, et al. Preoperative planning of deep inferior epigastric artery perforator flap reconstruction with multislice-CT angiography: imaging findings and initial experience. *J Plast Reconstr Aesthet Surg* 2006;59:585-93.